

# Cervical epidural puncture guided by fluoroscopy in comparison to acoustic signals: Clinical results

## ABSTRACT

**Background and Aim:** The increasing cases of the cervical epidural but the practitioners in need for a new method to decrease the safety of the injection and to improve the learning curve of the trainee. Furthermore, it should replace the potentially hazards, conventional one, which is the fluoroscope. Acoustic signals were tested for this purpose.

**Methods:** Thirty-two patients were assigned to have a cervical epidural for pain management using both acoustic signals and fluoroscopy simultaneously.

**Results:** The incidence of success was 100% with no complications. Likewise, the decrease in fluoroscopy shots number was 70%.

**Conclusions:** Acoustic signals are a simple, effective method of cervical epidural insertion. It reduces the usage of fluoroscopy and can be used as a learning tool.

**Key words:** Acoustic signals; cervical epidural; fluoroscopy

## Introduction

Nowadays, cervical epidural is a frequent practice in the pain management of cervical radicular pain.<sup>[1,2]</sup> It is usually an easy procedure. However, because of its important anatomical surroundings, it needs an expert pain physician (that did 400 or more lumbar epidural injections), health-care team, and equipment such as fluoroscopy. This setting causes wasting of time, more workforce recruitment, prolonged learning time, and high running cost.<sup>[3,4]</sup> Acoustic puncture assist device (APAD) has been tested and used successfully over the past decade. It has shown reliable results to detect epidural space in both lumbar and thoracic

area.<sup>[5-8]</sup> It provides an objective end point using both visual and auditory senses. Furthermore, it allows the usage of both hands for needle insertion. In this study, we assume that APAD if used probably in cervical epidural injection, it will be safe, reliable, training tool and will decrease the running cost.


## Methods

This is an observational study, 32 patients were scheduled. All patients signed informed consent after detailed discussion before the procedure.

This is an open access article distributed under the terms of the Creative Commons Attribution-NonCommercial-ShareAlike 3.0 License, which allows others to remix, tweak, and build upon the work non-commercially, as long as the author is credited and the new creations are licensed under the identical terms.

**For reprints contact:** reprints@medknow.com

**How to cite this article:** Ali HM, Toble Y, Tolba Y. Cervical epidural puncture guided by fluoroscopy in comparison to acoustic signals: Clinical results. Saudi J Anaesth 2017;11:305-8.

Access this article online	
<b>Website:</b> <a href="http://www.saudija.org">www.saudija.org</a>	<b>Quick Response Code</b> 
<b>DOI:</b> 10.4103/sja.SJA_52_17	

## ALI HM, TOBLE YMR<sup>1</sup>, TOLBA YYA<sup>2</sup>

Department of Anesthesia, Cairo University, Cairo , <sup>1</sup>Department of Anesthesia, National Cancer Institute Cairo University,

<sup>2</sup>Department of Anesthesia, Pain and Critical Care, King Faisal Specialist Hospital and Research Centre, National Cancer Institute Cairo University, Cairo, Egypt

**Address for correspondence:** Dr. Ali HM, Department of Anesthesia, Faculty of Medicine, Cairo University, Kasr Elaine Street, Cairo, Egypt. E-mail: hassan364@hotmail.com

### Inclusion criteria

Adult patients presented to the pain clinic between February 2014 and November 2015 in Security Forces Hospital, Riyadh, KSA requiring cervical epidural injection with no restriction to gender or level of injection.

### Exclusion criteria

All patients with coagulopathy, allergy to any of the used medications, septic focus, refusal, neuromuscular disease, or previous cervical spine surgery that may disturb the anatomy or patient refusal.

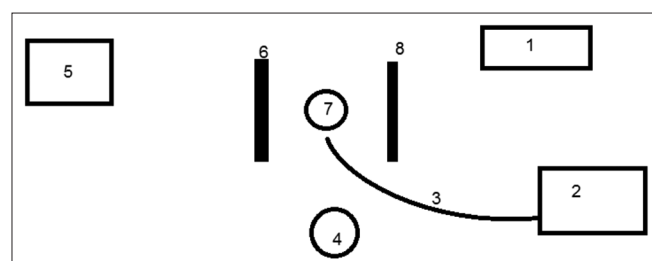
An intravenous access was inserted, and vital signs were monitored (noninvasive blood pressure, oxygen saturation, and electrocardiograph).

The procedure was performed while the patient is in the sitting position with slight neck flexion to expose 7<sup>th</sup> cervical spinous process as a consistent anatomical landmark.

The procedure room settings and ergonomics are shown in Figures 1 and 2, the fluoroscopy C-arm was encircling the patient cervical area, and the image was checked before cleaning. The pain physician was standing behind the patient after complete cleaning and aseptic precautions. The procedure was performed by an expert pain physician.

The APAD system was connected as shown in Figure 3 with a 120 cm tube connected to the needle from one side and to the transducer on the other side, then another tube from the transducer to the syringe pump which was loaded with 20 ml syringe filled with saline and adjusted to rate of 100 ml/h. The full length of the tubes was filled with a continuous column of saline with no air bubbles. The APAD system performance was checked for high and low pressure by occlusion and release of its tubing with reflection on the sound pitch.

After the skin was prepared with ChloraPrep, local anesthetic (lidocaine 1%) was infiltrated then a Tuohy needle 17 gauge was advanced in C7–T1 space, then



**Figure 1: Intraoperative setting.** 1 - Patient monitor, 2 - acoustic puncture assist device monitor, 3 - acoustic puncture assist device connections and needle, 4 - pain physician, 5 - fluoroscopy screen, 6 - C-arm tube, 7 - patient in sitting position, 8 - C-arm tube

the stylet was removed. The needle was flushed with saline and connected to the APAD system, as illustrated in Figure 2. Then, it was advanced gradually guided by fluoroscopy, APAD sounds (objective monitoring), and by feeling the loss of resistance sensation (the pop) (subjective monitoring) to detect entry to the epidural space. The pressure inside the needle and the APAD tube was related only to tissue resistance as the saline infusion in the needle was constant (100 ml/h), as the needle was advanced. On entering the epidural space, a sudden decrease in the pressure occurred and a subsequent sudden decrease in the sound intensity. Entry to the epidural space was further confirmed by injecting radiopaque dye under fluoroscopy. The medications were injected, and the patient was kept monitored for the next 3 h for his or her vital signs, motor power, and conscious level.

The primary outcome is the reliability and accuracy of the APAD system in detecting the cervical epidural space.

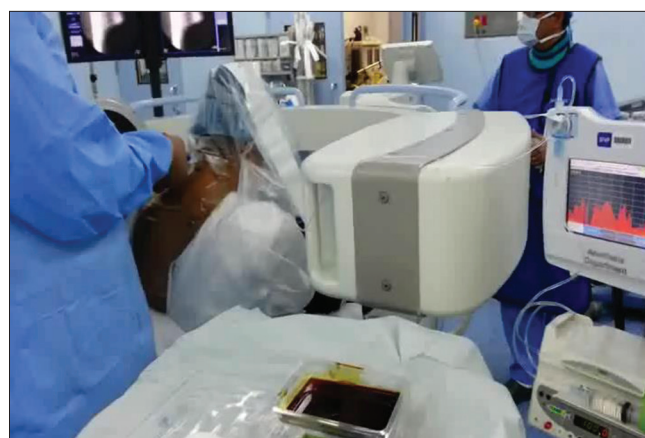The secondary outcomes are a reduction of exposure to X-ray fluoroscopy.

### Data collected

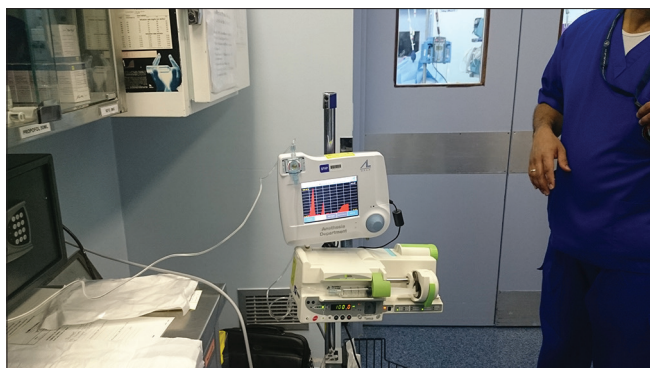Age, weight, height, APAD graphs and pressures, APAD-fluoroscopy correlation, time of exposure to fluoroscopy before and after entry to epidural space, and the number of X-ray shots before and after location of epidural space.

### Results

In this study, 32 cases were included [Figure 4] in the study, their mean body mass index was  $35.43 \pm 5.1$  (mean  $\pm$  standard deviation [SD]), their mean age was  $40 \pm 10.397$  (mean  $\pm$  SD), and 25 of them were American Society of Anesthesiologists (ASA) II and 7 of them were ASA III (two chronic renal failures, three



**Figure 2: Operating room setting**



**Figure 3: Acoustic puncture assist device machine connections and setting**

stable angina, one controlled congestive heart failure, and one morbidly obese patient).

In all of the cases, the epidural space was detected using both fluoroscopy and APAD with 100% correlation.

Total time of C-arm fluoroscopy (including setting up and positioning) was  $15.83 \pm 3.75$  min (mean  $\pm$  SD) with an actual exposure time of  $62.978 \pm 0.53$  s. Fluoroscopy time of  $4.82 \pm 1.73$  min with an actual exposure time of  $21.7148 \pm 0.69$  s (30.448%) was consumed to confirm the level and to confirm the epidural space; this time is considered mandatory exposure time to confirm procedure.

On the other hand,  $11.01 \pm 1.25$  min of time was used to follow up needle advancement by fluoroscopy with an actual exposure time of  $41.263 \pm 0.161$  s (69.551%) which is considered nonmandatory and can be omitted from the procedure to decrease the time of exposure to the fluoroscopy.

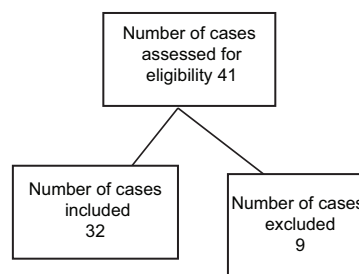
The usage of APAD greatly reduced the exposure time to fluoroscopy by around 70% (69.55%), despite that in this study, we used the fluoroscopy all through the procedure to show the correlation with the APAD system.

## Discussion

In this study, APAD has shown a great reliability and accuracy. It has a simple setup and objective hearing and visual end point.

Because of the graph that appears on the screen, it adds another advantage as it gives double documentation by the pressure graph and fluoroscopy image.

APAD is reliable and safe. The pain physician can use both hands and concentrate on the technique while hearing the tone of the machine. It also allows triple checking of entry



**Figure 4: Flowchart**

of epidural space using hearing, loss of resistance sensation, and fluoroscopy. Moreover, it decreased markedly the need of fluoroscopy and the time of exposure which subsequently will decrease the effects of the hazard of X-ray exposure and will decrease the running cost.

The APAD machine was tested in many studies before and it has proved a great efficacy. It was tested first in the lumbar area then in the thoracic area<sup>[3-5]</sup> which has a greater risk than the lumbar area. Furthermore, it was tested in the insertion of an epidural catheter in women in labor.<sup>[6]</sup>

Up to our knowledge, APAD has not been used before in detecting cervical epidural space.

Although APAD showed a great success, it has some limitations. APAD cannot be used alone; it still needs the usage of fluoroscopy to confirm final needle position and to rule out the intravascular injection. If pain physicians master APAD to become a standard practice, there is a hope it can replace fluoroscopy in the future. Obviously, this needs further research and studies.

## Financial support and sponsorship

Nil.

## Conflicts of interest

There are no conflicts of interest.

## References

1. Jørgensen SH, Ribergaard NE, Al-Kafaji OH, Rasmussen C. Epidural steroid injections in the management of cervical disc herniations with radiculopathy. *Scand J Rheumatol* 2015;44:315-20.
2. Woods BI, Hilibrand AS. Cervical radiculopathy: Epidemiology, etiology, diagnosis, and treatment. *J Spinal Disord Tech* 2015;28:E251-9.
3. Manchikanti L, Pampati V, Falco FJ, Hirsch JA. Assessment of the growth of epidural injections in the medicare population from 2000 to 2011. *Pain Physician* 2013;16:E349-64.
4. Manchikanti L, Benyamin RM. Key safety considerations when administering epidural steroid injections. *Pain Manag* 2015;5:261-72.
5. Lechner TJ, van Wijk MG, Maas AJ. Clinical results with a new acoustic device to identify the epidural space. *Anaesthesia* 2002;57:768-72.
6. Lechner TJ, van Wijk MG, Maas AJ, van Dorsten FR, Drost RA,

- Langenberg CJ, *et al.* Clinical results with the acoustic puncture assist device, a new acoustic device to identify the epidural space. *Anesth Analg* 2003;96:1183-7.
7. Lechner TJ, van Wijk MG, Maas AJ, van Dorsten FR. Thoracic epidural puncture guided by an acoustic signal: Clinical results. *Eur J Anaesthesiol* 2004;21:694-9.
8. Lechner TJ, van Wijk MG, Jongenelis AA, Rybak M, van Niekerk J, Langenberg CJ. The use of a sound-enabled device to measure pressure during insertion of an epidural catheter in women in labour. *Anaesthesia* 2011;66:568-73.