

Case Report

Negative cerebrospinal fluid β -d-glucan levels as an indicator for treatment cessation ahead of biochemical resolution: A case report of *Candida glabrata* meningitis

Liang En Wee^{a,b,*}, Crystal Shie Lyeen Wong^c, Ai Ling Tan^d, Helen May-Lin Oh^b

^a SingHealth Infectious Diseases Residency, Outram Road, 169608, Singapore

^b Department of Infectious Diseases, Changi General Hospital, Simei St 3, 529889, Singapore

^c Department of Microbiology, Changi General Hospital, Simei St 3, 529889, Singapore

^d Department of Microbiology, Singapore General Hospital, Outram Road, 169608, Singapore



ARTICLE INFO

Keywords:

Candida
Candida glabrata
Meningitis
Fluconazole
B-d-glucan
Hypercalcemia

ABSTRACT

Candida infections of the central nervous system (CNS) are rare. We report a case of *Candida glabrata* meningitis successfully treated with combination antifungal therapy followed by step-down therapy with fluconazole. New-onset hypercalcaemia, an uncommon side effect of the prolonged fluconazole treatment, prompted early treatment cessation. A negative cerebrospinal fluid (CSF) β -d-glucan supported the decision of treatment cessation despite incomplete resolution of CSF biochemical parameters. No disease relapse was encountered after 2 years post-treatment.

1. Introduction

Candida infection of the central nervous system (CNS) is an uncommon manifestation of invasive candidiasis, with *Candida albicans* being the most commonly identified species [1,2]. The populations most at risk are low birth weight neonates, patients with CNS ventriculostomies, or immunocompromised hosts [3,4]. Due to the rarity of these infections, no randomised controlled trials exist to evaluate the appropriate choice and duration of antifungal treatment. Current guidance recommends antifungal treatment until resolution of all radiological abnormalities and biochemical parameters in the cerebrospinal fluid (CSF), as microbiological relapse is not uncommon [4]. While various biochemical parameters, including CSF β -d-glucan, have been utilised as a marker of fungal disease, the role of such biomarkers in guiding treatment is still unclear [3,5]. We present a case of *Candida glabrata* meningitis successfully treated with fluconazole therapy, in which negative CSF β -d-glucan was used as a marker for treatment cessation despite persistence of other CSF biochemical abnormalities. The patient was followed up for more than 2 years post-treatment without clinical evidence of relapse.

2. Case presentation

An elderly Singaporean Chinese female presented to our institution with a 1-week history of fever. She has been a nursing home resident since suffering a debilitating hemorrhagic stroke 2 years ago, for which she underwent a right frontotemporal lobectomy and decompressive craniectomy. No intracranial device or prosthetic material was inserted. At baseline, the patient was bedbound and minimally communicative, with a temperature of 38.5° Celsius on admission. No obvious CNS signs were elicited but on examination, an infected right heel ulcer was detected. Despite empirical antibiotics, the infected ulcer worsened with spreading cellulitis complicated by an underlying osteomyelitis and an above-knee amputation was performed under spinal anaesthesia. During the administration of spinal anaesthesia, the anaesthetist observed that the cerebrospinal fluid (CSF) appeared cloudy. Due to the suspicion of infection, CSF specimens were sent off for culture. Gram stain performed on the culture showed 2+ growth of blastoconidia; cultures grew heavy growth of *Candida glabrata*. Antifungal susceptibilities were tested for the isolate, with the following results: minimum inhibitory concentrations (MIC) for amphotericin B = 0.5 mg/L; 5-flucytosine \leq 0.06; fluconazole = 2 mg/L. The initial CSF specimen at day 0 (D0) had a protein level of 2.60 g/L; a glucose level of 0.2 mmol/L; and a cell count of 9000

* Corresponding author. SingHealth Infectious Diseases Residency, Outram Road, 169608, Singapore.

E-mail address: ian.wee@mohh.com.sg (L.E. Wee).

<https://doi.org/10.1016/j.mmcr.2021.03.003>

Received 21 November 2020; Received in revised form 17 February 2021; Accepted 1 March 2021

Available online 5 March 2021

2211-7539/© 2021 The Authors. Published by Elsevier B.V. on behalf of International Society for Human and Animal Mycology. This is an open access article

under the CC BY-NC-ND license (<http://creativecommons.org/licenses/by-nc-nd/4.0/>).

cells/mm³ (neutrophil percentage: 80%) (Fig. 1). Blood cultures on admission were negative.

The patient was started on intravenous liposomal amphotericin B (Ambisome) on D1 of treatment at a dose of 5 mg/kg, as well as oral flucytosine at a dose of 25 mg/kg 4 times daily, for 2 weeks. An abdominal and pelvic computed tomography scan (CT-scan) was performed to search for potential sources; the scan showed a severe left hydronephrosis arising from a persistent stricture at the left vesicoureteric junction, with patchy areas of hypoenhancement in the right kidney suggestive of focal right pyelonephritis. While urine cultures on this admission were negative, urine specimens in previous admissions had mixed growth of *Candida*. Prior to this admission, the patient had not received any antifungal treatment nor had any indwelling urinary catheter inserted.

At D7 and D14 of treatment, CSF cultures were both sterile with improvement in biochemical parameters (glycorrhachia and CSF protein) on D14. The CSF sample at D14 was sent to an external institution for qualitative β -d-glucan testing, using a commercially available diagnostic kit (Fungitell; Cape Cod Inc., East Falmouth, MA, USA), with positive results (≥ 80 μ g/ml). Given sterile cultures, the patient was switched to fluconazole at a dose of 600 mg once-daily (12 mg/kg/day). However, despite continuous antifungal treatment, patient continued spiking daily fevers, raising concern for persistent infection. Magnetic resonance imaging (MRI) of the brain did not demonstrate evidence of meningitis, meningoencephalitis or intracranial abscesses. Transthoracic echocardiogram did not show vegetations, and ophthalmic review did not detect fungal endophthalmitis. Repeat lumbar puncture at D28 of treatment showed further improvement in the CSF parameters (protein level of 0.85 g/L; glucose level of 3.8 mmol/L; cell count of 5 cells/mm³), though fever continued to persist. Given that intracranial abscesses had been excluded on imaging, and CSF cultures remained sterile, a trial of IV micafungin was initiated for 5 days to assess if the fever could be drug-related. However, the trajectory of the patient's fevers did not change, and hence fluconazole was resumed, given concerns regarding penetration of echinocandins into the CSF. Repeat CT-scan of the abdomen and pelvis at D32 of treatment showed interval improvement in the pyelonephritis, with no new intrabdominal focus of infection. Repeat MRI-brain at D33 of treatment did not show any abnormal meningeal enhancement, intracranial abscess or focal collection. Fluconazole treatment was continued; the patient's fevers finally resolved at D35 of treatment. However, at D40 of treatment, the patient developed significant new-onset hypercalcemia (serum calcium: 3.40 mmol/L) requiring intravenous hydration and bisphosphonate treatment with intravenous pamidronate. Parathyroid hormone levels were not elevated (1.22 pmol/L). The possibility of drug-induced hypercalcemia was raised, with fluconazole being the most likely culprit, as no

other new drugs had been initiated in the interim. At D42 of treatment, lumbar puncture was repeated. While CSF cultures remained sterile, biochemical parameters had not fully resolved (protein level of 1.38 g/L; glucose level of 3.1 mmol/L; cell count of 22 cells/mm³). Repeat qualitative testing of the CSF for β -d-glucan returned negative (< 60 μ g/ml). With sterile CSF cultures, absence of fever and a negative β -d-glucan, a decision was made to discontinue antifungal treatment on D49 in view of the new-onset hypercalcemia, although the patient's CSF parameters had not fully normalised. Patient was kept under close monitoring given the unresolved CSF parameters. The hypercalcemia subsequently resolved 2 days after fluconazole was stopped. Lumbar puncture was not repeated due to patient's poor premorbid function and the absence of fever or altered mental status. Patient was discharged on D59 with no evidence of clinical relapse on outpatient follow-ups. Unfortunately, the patient passed away 2 years after the initial diagnosis of *Candida glabrata* meningitis, from unrelated causes (*Escherichia coli* urosepsis).

3. Discussion

We present a case of *Candida glabrata* meningitis treated for 49 days, who whilst on step-down fluconazole, developed a rare side effect of hypercalcemia from prolonged triazole therapy. Negative CSF β -d-glucan in conjunction with serial sterile CSF cultures was used as a marker for treatment cessation despite persistence of other CSF biochemical abnormalities. Culture yield is known to be variable especially after treatment initiation [3]. Furthermore, clinical and microbiological relapses have been encountered in multiple cases of *Candida* meningitis even after attaining sterile cultures [5,6]. A sensitive and non-invasive fungal marker for diagnostic and monitoring of fungal CNS infections is much needed. β -d-glucan is a polysaccharide glucose polymer and a component of the fungal cell wall. Measurement of CSF β -d-glucan has emerged as a valuable diagnostic marker for fungal meningitis [3], but its clinical utility in treatment monitoring has been limited to case reports [5,7]. Lyons et al. provided the first case report of β -d-glucan detected in CSF specimens of a patient with *Candida albicans* meningitis [7]; Ceccarelli et al. described persistent CSF β -d-glucan as a marker of treatment failure in a case of *Candida tropicalis* meningitis in the setting of negative CSF culture and resolution of biochemical abnormalities in the CSF [5].

In our case, while the side effects of prolonged antifungal therapy provided the impetus for treatment cessation, concerns of inadequate treatment remained, given persistence of biochemical abnormalities in the CSF. While these biochemical abnormalities could potentially still represent residual inflammation instead of infection, the variable sensitivity of CSF culture yield made it challenging to rule out residual infection, despite persistently negative CSF cultures. Guidelines for

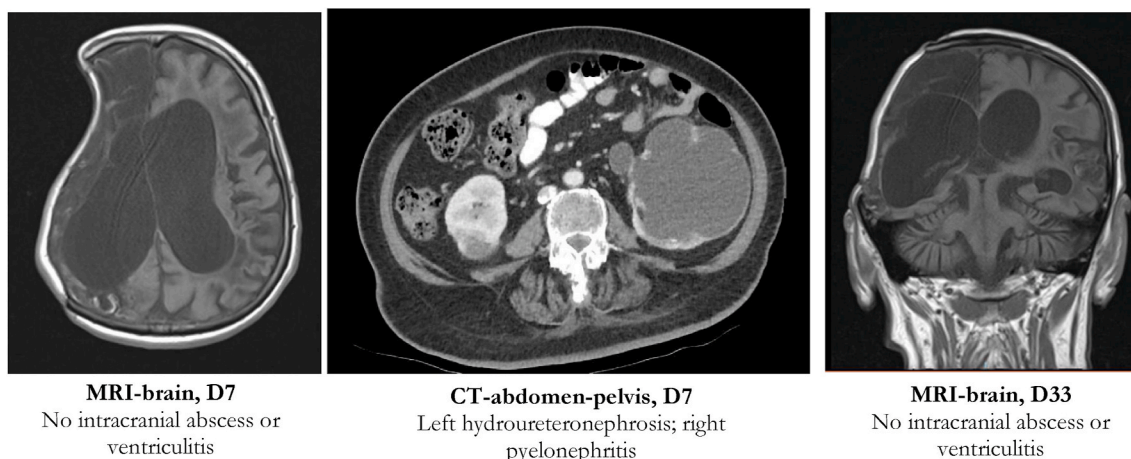


Fig. 1. Imaging findings in a case of *C. glabrata* meningitis.

Candida meningitis treatment generally suggest continuation of antifungal treatment until resolution of all radiological and CSF abnormalities [4]. Case reports have demonstrated detectable CSF β -d-glucan levels even before *Candida* is culturable in CSF [5,7]. Its clinical utility as an early surrogate biomarker supported our decision in treatment cessation in conjunction with clinical improvement and sterile CSF culture. While a limitation of our study was that only qualitative CSF β -d-glucan results were available, many clinical factors, including total fungal burden, site of infection and type of fungus, can cause the reactivity of β -d-glucan to vary and hence β -d-glucan results should always be interpreted in conjunction with other diagnostic procedures. The patient was subsequently followed up for more than 2 years post-treatment without clinical evidence of relapse.

Candida glabrata as a cause of *Candida* meningitis is uncommon [1, 2]. Risk factors for *Candida* meningitis in this particular patient included previous neurosurgical intervention, although no intracranial device had been previously inserted. *Candida glabrata* may be more challenging to treat compared with other *Candida* species because of its intrinsically higher fluconazole MIC with approximately 20% of strains developing resistance during fluconazole therapy [8]. Successful treatment relies on a higher fluconazole dose regimen, and in our case fluconazole was used as a step-down treatment after a 2-week course of liposomal amphotericin B and flucytosine treatment. Previous successes have been reported with similar antifungal combinations [8,9] whilst others used voriconazole for more resistant isolates as salvage treatment [1,6]. Triazole-associated hypercalcemia is rare. A case report of symptomatic hypercalcemia associated with high-dose fluconazole has been published in the literature [10]. Our patient developed new-onset hypercalcemia after more than a month of fluconazole therapy, during which no new medication was introduced throughout this period. Calcium levels normalised soon after treatment with pamidronate and cessation of fluconazole, and hypercalcemia did not recur.

In conclusion, we report a successfully treated case of *Candida glabrata* meningitis despite cessation of treatment due to triazole-associated hypercalcaemia while biochemistry of the CSF was not yet normalised. β -d-glucan was a useful biomarker in guiding treatment decisions. A 2-year post-treatment follow up of the patient revealed no evidence of disease relapse. More research is necessary into the usage of novel biomarkers, such as CSF β -d-glucan, in the monitoring and treatment of rare fungal CNS infections.

Declaration of competing interest

The authors declare no conflicts of interest.

Acknowledgements

We acknowledge the assistance of our endocrinology colleagues in the management of this case.

References

- [1] M. Chen, C. Chen, Q. Yang, R. Zhan, *Candida* meningitis in neurosurgical patients: a single-institute study of nine cases over 7 years, *Epidemiol. Infect.* 148 (2020) 1–5, <https://doi.org/10.1017/S0950268820001144>, e148.
- [2] R.A. Voice, S.F. Bradley, J.A. Sangeorzan, C.A. Kauffman, Chronic candidal meningitis: an uncommon manifestation of candidiasis, *Clin. Infect. Dis.* 19 (1) (1994 Jul) 60–66, <https://doi.org/10.1093/clinids/19.1.60>.
- [3] C. Davis, L.J. Wheat, T. Myint, D.R. Boulware, N.C. Bahr, Efficacy of cerebrospinal fluid beta-d-glucan diagnostic testing for fungal meningitis: a systematic review, *J. Clin. Microbiol.* 58 (4) (2020 Mar 25), <https://doi.org/10.1128/JCM.02094-19> e02094-19.
- [4] P.G. Pappas, C.A. Kauffman, D.R. Andes, C.J. Clancy, K.A. Marr, L. Ostrosky-Zeichner, A.C. Reboli, M.G. Schuster, J.A. Vazquez, T.J. Walsh, T.E. Zaoutis, J. D. Sobel, Clinical practice guideline for the management of candidiasis: 2016 update by the infectious diseases society of America, *Clin. Infect. Dis.* 62 (4) (2016 Feb 15) e1–50, <https://doi.org/10.1093/cid/civ933>.
- [5] G. Ceccarelli, M.C. Ghezzi, G. Raponi, et al., Voriconazole treatment of *Candida tropicalis* meningitis: persistence of (1,3)- β -D-glucan in the cerebrospinal fluid is a marker of clinical and microbiological failure: a case report, *Medicine (Baltim.)* 95 (31) (2016), e4474, <https://doi.org/10.1097/MD.0000000000004474>.
- [6] S. Tsakiri, C. Aneji, C. Domonoske, L. Mazur, D.K. Benjamin Jr., S.H. Wootton, Voriconazole treatment for an infant with intractable *Candida glabrata* meningitis, *Pediatr. Infect. Dis. J.* 37 (10) (2018 Oct) 999–1001, <https://doi.org/10.1097/INF.0000000000002073>.
- [7] J.L. Lyons, M.G. Erkkinen, I. Vodopivec, Cerebrospinal fluid (1,3)- β -D-glucan in isolated *Candida* meningitis, *Clin. Infect. Dis.* 60 (1) (2015 Jan 1) 161–162, <https://doi.org/10.1093/cid/ciu737>.
- [8] C. Colomba, M. Trizzino, C. Imburgia, S. Madonia, L. Siracusa, G.M. Giammanco, *Candida glabrata* meningitis and endocarditis: a late severe complication of candidemia, *Int. J. Infect. Dis.* 29 (2014 Dec) 174–175, <https://doi.org/10.1016/j.ijid.2014.04.032>.
- [9] E. Anhalt, J. Alvarez, R. Berg, *Candida glabrata* meningitis, *South. Med. J.* 79 (7) (1986 Jul) 916, <https://doi.org/10.1097/00007611-198607000-00037>.
- [10] N.H. Chan, J.E. Blair, S.A. Westphal, L.K. Tehrani, M.T.A. Seville, Fluconazole-associated hypercalcemia in patients with coccidioidomycosis, *J. Clin. Case Rep.* 6 (2016) 800, <https://doi.org/10.4172/2165-7920.1000800>.