

CASE REPORT

Scirrhou carcinoma: A previously undescribed tumor of the oral cavity

Jacquelyn DeVries¹  | Andrey Finegersh¹ | Kathryn A. Gold^{2,3} | Andrew B. Sharabi^{3,4} | Jingjing Hu⁵ | Ryan K. Orosco^{1,3} 

¹Department of Surgery, Division of Otolaryngology-Head & Neck Surgery, University of California, San Diego, CA, USA

²Department of Medical Oncology, University of California, San Diego, CA, USA

³Moore's Cancer Center, La Jolla, CA, USA

⁴Department of Radiation Oncology, University of California, San Diego, CA, USA

⁵Department of Pathology, University of California, San Diego, CA, USA

Correspondence

Ryan Orosco, University of California San Diego Division of Otolaryngology, San Diego, CA, USA.
Email: rorosco@health.ucsd.edu

Abstract

This patient was found to have a scirrhou carcinoma with extensive perineural invasion and without any evidence of minor salivary gland carcinoma. To our knowledge, this is the first report of isolated scirrhou carcinoma of the oral cavity. Treatment was surgery and adjuvant chemoradiation, and there was complete disease response.

KEYWORDS

adenocarcinoma, operative chemoradiation, scirrhou carcinoma, surgical procedures

1 | INTRODUCTION

Scirrhou carcinoma of the oral cavity has only previously been described in the setting of salivary gland carcinoma. This patient with a lower lip mass was found to have a scirrhou carcinoma with extensive perineural invasion and without any evidence of minor salivary gland carcinoma.

Scirrhou carcinomas are characterized by hard, fibrous tumors consisting of rare malignant cells surrounded by dense connective stromal tissue.^{1,2} It is thought that poorly cohesive neoplastic cells trigger fibrosis, but scirrhou tumors have been reported to arise in a background of moderately differentiated adenocarcinoma.³ This pathology is rare and most commonly associated with gastric carcinoma in the form of *linitis plastica*. In gastric carcinoma, scirrhou pathology is attributed to abundant cancer-associated fibroblasts.³ We present here the first reported case of oral

scirrhou carcinoma without an underlying salivary gland carcinoma.

2 | CASE REPORT

A 44-year-old male with prior history of actinic keratoses and a small squamous cell carcinoma of the left cheek excised 1 year prior presented with a several year history of a right lower lip mass with associated right chin numbness. The mass was about 1-cm, centered in the right gingivobuccal sulcus. An excisional biopsy was performed that was originally read as carcinoma with perineural invasion, associated perineural chronic inflammation, and fibrosis. Adenoid cystic carcinoma was favored as a diagnosis, but the salivary gland captured in the original excisional biopsy was benign.

This is an open access article under the terms of the Creative Commons Attribution-NonCommercial-NoDerivs License, which permits use and distribution in any medium, provided the original work is properly cited, the use is non-commercial and no modifications or adaptations are made.

© 2021 The Authors. *Clinical Case Reports* published by John Wiley & Sons Ltd.

He was referred to our tertiary care institution for further management. On examination, he had a palpable 2-cm submucosal mass was in the right gingivolabial sulcus and extended from the gingiva to the skin of the chin. The dry lip was not involved. A CT scan neck with contrast showed a residual 1.8 cm mass at the right lower lip extending to the right mandible at the right mental foramen (Figure 1). Multidisciplinary tumor board recommendation was for primary surgery with the goal of achieving negative margins. Sentinel lymph node biopsy was considered an option as it may provide prognostic and possibly therapeutic implications.

The patient underwent resection of the lower lip tumor from the gingiva and oral mucosa, through to the chin skin, with preservation of the vermilion and pink lip (Figure 2A,B). Although the tumor felt well-demarcated on physical examination, the actual feel and appearance of the deep tissues were similar to that of operating on a tumor in a radiated field. There was extensive fibrosis that extended more than 1-cm beyond what could be felt as the edges of the tumor based on clinical examination. It was evident that a negative margin resection would have required mandibulectomy and resection of excess of 50% of the lower lip and commissure. A facial artery musculomucosal flap was used for reconstruction (Figure 2C). Preoperative lymphoscintigraphy was performed, demonstrating uptake at bilateral submandibular lymph nodes, and left neck lymph nodes as well as mild uptake at the left palatine tonsil. Intraoperatively, sentinel node biopsy was attempted but was nonlocalizing on gamma probe so no nodal tissue was removed.

Pathology revealed narrow cords of tumor cells infiltrating subcutaneous tissue and a desmoplastic response with focal extension. There was an abundant inflammatory response associated with the tumor (Figure 3A). Higher power view of the tumor showed pleomorphic tumor cells with irregular nuclear

membrane, prominent nucleoli, and inconspicuous cytoplasm (Figure 3B). The tumor showed extensive perineural invasion with cords and small nests of tumor cells in the neural bundle (Figure 3C). The tumor presence was confirmed by pancytokeratin immunostain (Figure 3D). Intraoperative frozen section from the mental foramen demonstrated nerve with crushed cells, favoring inflammation, with no definitive malignancy seen on initial examination. Final pathology of the specimen taken from the mental nerve at the mental foramen showed carcinoma with perineural invasion. Lymphocytic infiltrate was present. The tumor did not appear to be arising from the skin based on pathological examination of chin skin and subcutaneous margins, which demonstrated benign skin, fibromuscular, and adipose tissue with negative Pankeratin IHC. The skin surface showed no dysplasia. Desmoplastic squamous cell carcinoma and morphea-type basal cell carcinoma were considered as they can show similar infiltrative morphology, but no primary lesion was identified in the overlying squamous mucosa or skin, making these unlikely. There was no evidence of background adenoid cystic carcinoma in surrounding minor salivary glands. These findings were consistent with scirrhous carcinoma.

Systemic imaging via PET scan did not reveal any regional or distant metastasis. Due to extensive perineural invasion into the mandible and the morbidity of re-resection to clear margins, tumor board recommendation was for adjuvant concurrent chemoradiation. The patient received 66 Gy in 33 fractions of IMRT (intensity-modulated radiotherapy) with 7 cycles of cisplatin (40 mg/m^2). Repeat PET scan 5 months postoperatively revealed decreased metabolic activity in the surgical bed and was again negative for regional or distant metastasis. He is doing well with no evidence of disease 7 months out from surgery, and he continues to be monitored for recurrence.

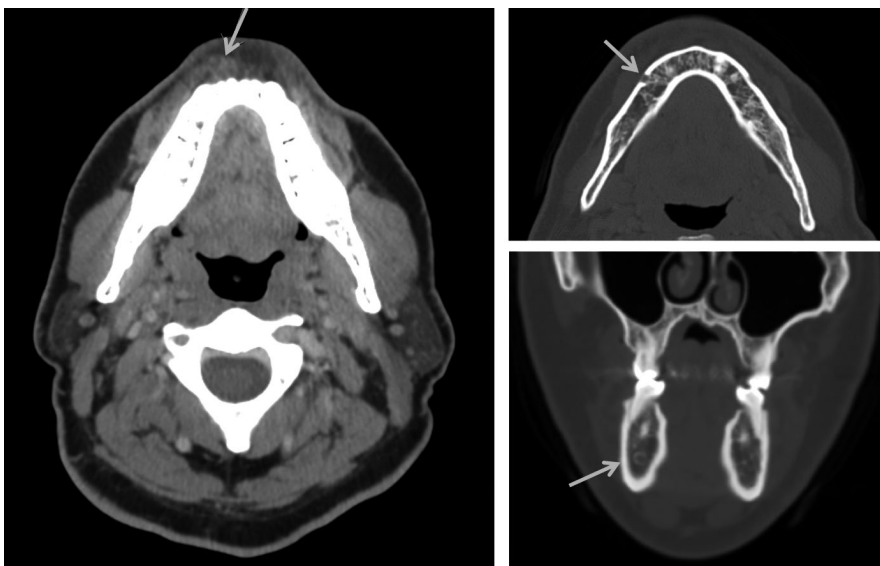


FIGURE 1 A, Axial image of R lower lip mass, measuring 1.8 cm. B, Axial view of widened right mental foramen due to perineural invasion of tumor. C, Coronal view of widened right mental foramen

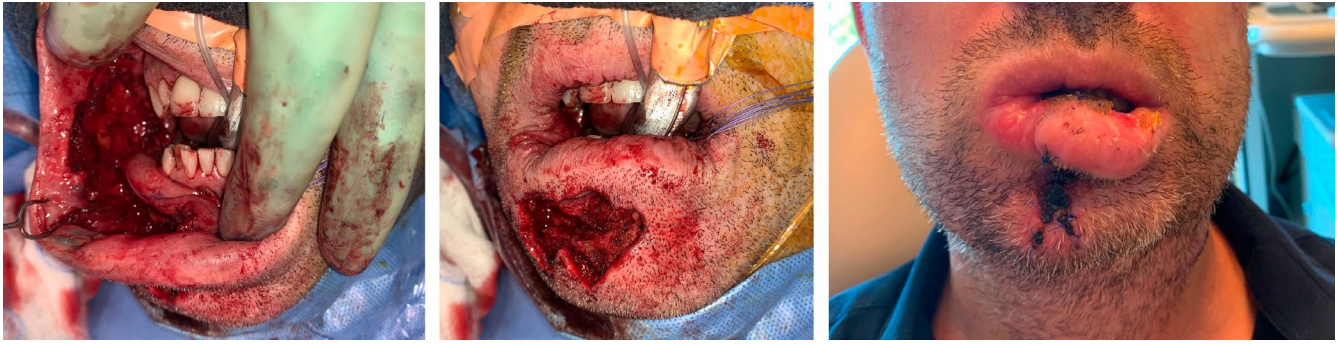
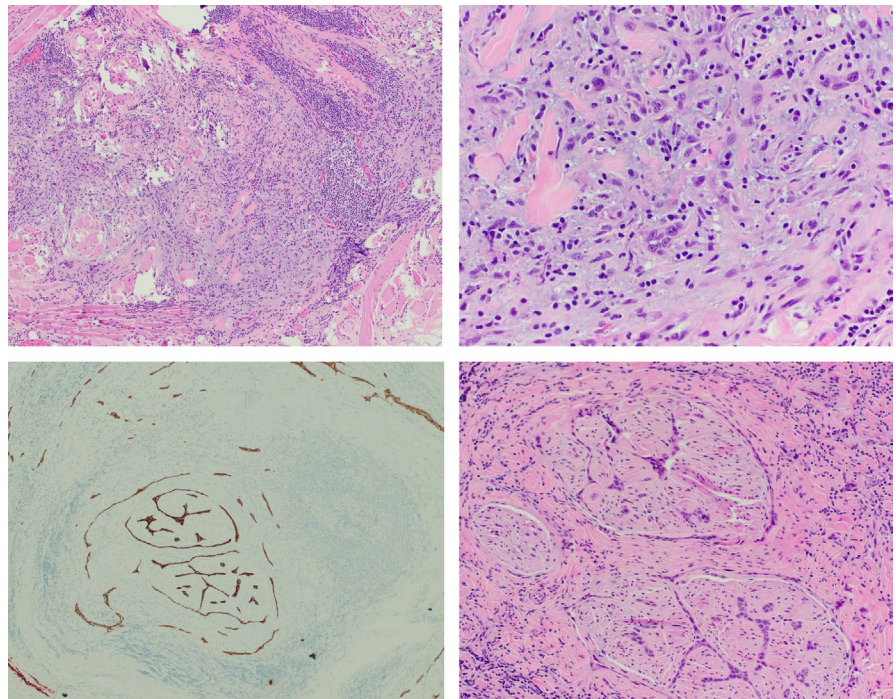


FIGURE 2 A, Intraoperative image of intraoral resection B, Intraoperative image of external resection before flap advancement. C, Postoperative healing of facial artery musculomucosal flap

FIGURE 3 A, Inflammatory response to tumor visible at 10× magnification. B, Tumor cells visible at 40× magnification. C, Perineural invasion at 20× magnification. D, Pan-cytokeratin stain confirms perineural invasion at 10× magnification



3 | DISCUSSION

Scirrhous pathology is rare and most commonly associated with diffuse-type gastric cancer. It has rarely been associated with invasive ductal carcinoma of the breast, and there are case reports of scirrhous carcinoma of the liver, rectum, and lacrimal glands.^{2,4,5} These tumors are characterized by cords of tumor cells in fibrous stroma, as seen in this patient.^{2,4}

In gastric cancer where this scirrhous pathology is well-known, the molecular pathology has not been fully elucidated but is thought to be mediated by microsatellite instability and upregulation of extracellular matrix genes and TGF- β leading to fibrosis.¹ In scirrhous gastric carcinoma, 5-year survival is 11.3%, poorer than in other gastric cancers largely due to the high incidence of serosal invasion and peritoneal metastasis.¹ Surgery alone is likely not curative for gastric scirrhous carcinoma. Gastric resection followed by chemoradiation

has been demonstrated to improve median time to relapse as well as overall survival.¹ Various neoadjuvant chemotherapy regimens have also been described as improving curative resection rate but not overall survival.¹ Peritoneal spread is common, and distant metastasis has been reported in 57.9% of patients at the time of presentation.⁶

In breast cancer, scirrhous carcinoma is also a well-established subtype of invasive ductal carcinoma, and lymphatic invasion is more commonly seen than perineural or vascular invasion.² The intense desmoplastic reaction seen in scirrhous ductal carcinoma of the breast is thought by some to inhibit local angiogenesis and slow tumor growth, meaning that these tumors may be long-standing at the time of diagnosis and thus have a poorer prognosis.⁷ Ill-defined tumor margins have been defined in scirrhous carcinoma of the liver, and prognosis is generally very poor.^{1,4} The literature describes management of breast scirrhous carcinoma as

surgical excision followed by radiation and possibly chemotherapy depending on hormone receptors and nodal status.⁸

In the oral cavity, scirrhous growth pattern has been described in the setting of hybrid salivary duct carcinoma.^{2,9} These rare tumors have primarily been described in the parotid glands and were treated by surgical excision and adjuvant radiation.⁹ In our case, there was no evidence of salivary duct carcinoma or adenoid cystic carcinoma. Primary dermatologic malignancy was also considered. Desmoplastic squamous cell carcinoma, desmoplastic melanoma, and morphea-type basal cell carcinoma can show similar infiltrative morphology to this tumor but in the absence of a primary lesion of the overlying squamous mucosa and skin, these possibilities were unlikely.^{2,10,11}

This pathology is rare, and therefore, clinicians lack established management guidelines. For anatomic imaging, contrast-enhanced computed tomography was used in this case since it is often first line for suspected salivary gland tumors, as was initially thought to be the cause of this patient's mass.¹² Due to uncertainty regarding propensity for distant metastasis, PET imaging was employed and was negative.

As there is no established treatment paradigm for scirrhous carcinoma in the head and neck, we followed the contemporary approach to oral cavity cancers—primary surgery with adjuvant therapy for high-risk factors such as positive margins and advanced T-category.¹³ This treatment approach aligns with scirrhous carcinoma of the breast and stomach. The efficacy of our trimodality approach is uncertain. We are following a cautious surveillance approach consisting of physical examination every 2–3 months for the first year. A cosmetic lip revision is anticipated about 6 months out from completion of chemoradiation, and we are considering imaging prior to that.

4 | CONCLUSION

To our knowledge, this is the first reported scirrhous tumor of the oral cavity without associated salivary gland malignancy. Based on scirrhous carcinoma from other subsites and following oral cavity cancer treatment paradigms, our approach was surgery followed by concurrent chemoradiation. Experience from other isolated cases, or series are necessary to help determine oncologic behavior and to guide management of the rare, aggressive malignancy.

ACKNOWLEDGMENTS

We thank the patient described for allowing us to share his interesting case. Published with written consent of the patient.

CONFLICT OF INTEREST

The authors declare no conflicts of interest.

AUTHOR CONTRIBUTIONS

RKO: is a practicing head and neck surgeon at Moores Cancer Center/University of California, San Diego, and was the operating surgeon in this case. JH: is a practicing pathologist at University of California, San Diego, and was the pathologist in this case. AS: is a practicing radiation oncologist at Moore Cancer Center/University of California, San Diego, and was the radiation oncologist in this case. KG: is a practicing medical oncologist at Moore Cancer Center/University of California, San Diego, and was the medical oncologist in this case. AF: is an otolaryngology resident at University of California, San Diego, that assisted in writing the manuscript. JKD: is a medical student at University of California, San Diego, who wrote the manuscript with support from the names mentioned above. All authors reviewed and approved the final version of the manuscript.

ETHICAL APPROVAL

The authors declare human ethics approval was not needed for this study.

IRB APPROVAL

This report is exempt from IRB approval at our institution.

DATA AVAILABILITY STATEMENT

The authors confirm that the data supporting the findings of this study are available within the article.

ORCID

Jacquelyn DeVries  <https://orcid.org/0000-0001-5667-4280>

Ryan K. Orosco  <https://orcid.org/0000-0002-7885-4327>

REFERENCES

1. Ikeguchi M, Miyake T, Matsunaga T, et al. Recent results of therapy for scirrhous gastric cancer. *Surg Today*. 2009;39(4):290–294.
2. Weidner N, Cote R, Suster S, Weiss L. *Modern surgical pathology*, 2nd ed. Philadelphia, PA: Saunders - Elsevier; 2009; 1.
3. Agnes A, Estrella JS, Badgwell B. The significance of a nineteenth century definition in the era of genomics: linitis plastica. *World J Surg Oncol*. 2017;15(1):123.
4. Kim SH, Lim HK, Lee WJ, Choi D, Park CK. Scirrhous hepatocellular carcinoma: comparison with usual hepatocellular carcinoma based on CT-pathologic features and long-term results after curative resection. *Eur J Radiol*. 2009;69(1):123–130.
5. Ishige T, Nishimura M, Satoh M, et al. Combined secretomics and transcriptomics revealed cancer-derived GDF15 is involved in diffuse-type gastric cancer progression and fibroblast activation. *Sci Rep*. 2016;6:21681.
6. Chang JM, Lara KA, Gray RJ, Pockaj BA, Wasif N. Clinical outcomes after surgery for linitis plastica of the stomach: analysis of a population cancer registry. *Am Surg*. 2017;83(1):23–29.
7. Lacout A, Marcy PY, Lesec G. Long-standing scirrhous breast carcinoma en cuirasse. *Breast Care (Basel)*. 2010;5(5):327–329.

8. Network NCC. Breast cancer (Version 06.2020). https://www.nccn.org/professionals/physician_gls/default.aspx. Accessed December 01, 2020.
9. Nagao T, Sugano I, Ishida Y, et al. Hybrid carcinomas of the salivary glands: report of nine cases with a clinicopathologic, immunohistochemical, and p53 gene alteration analysis. *Mod Pathol*. 2002;15(7):724-733.
10. East E, Fullen DR, Arps D, et al. Morpheaform basal cell carcinomas with areas of predominantly single-cell pattern of infiltration: diagnostic utility of p63 and cytokeratin. *Am J Dermatopathol*. 2016;38(10):744-750.
11. Velazquez EF, Werchniack AE, Granter SR. Desmoplastic/spindle cell squamous cell carcinoma of the skin. A diagnostically challenging tumor mimicking a scar: clinicopathologic and immunohistochemical study of 6 cases. *Am J Dermatopathol*. 2010;32(4):333-339.
12. Seeburg DP, Baer AH, Aygun N. Imaging of patients with head and neck cancer: from staging to surveillance. *Oral Maxillofac Surg Clin North Am*. 2018;30(4):421-433.
13. National Comprehensive Cancer Network. Head and Neck Cancer (Version 2.2020). https://www.nccn.org/professionals/physician_gls/pdf/head-and-neck.pdf. Accessed September 17, 2020.

How to cite this article: DeVries J, Finegersh A, Gold KA, Sharabi AB, Hu J, Orosco RK. Scirrhous carcinoma: A previously undescribed tumor of the oral cavity. *Clin Case Rep*. 2021;9:e03864. <https://doi.org/10.1002/ccr3.3864>