

## Pneumothorax due to COVID-19: Analysis of case reports

David Alejandro Cabrera Gaytán<sup>a,\*</sup>, Yadira Pérez Andrade<sup>b</sup>, Yuridia Espíritu Valenzo<sup>c</sup>

<sup>a</sup> *Coordinación de Investigación en Salud, Instituto Mexicano del Seguro Social, Av. Cuauhtémoc # 330 Block "B" 4° Floor, Annex to the Unidad de Congresos del Centro Médico Nacional Siglo XXI, Neighborhood Doctores, Alcaldía Cuauhtémoc, CP. 06720, Mexico City, Mexico*

<sup>b</sup> *Coordinación de Vigilancia Epidemiológica, Instituto Mexicano del Seguro Social, Mier y Pesado No. 120, Neighborhood Del Valle Benito Juárez, CP. 03100, Mexico City, Mexico*

<sup>c</sup> *Hospital General Regional No. 72, Instituto Mexicano del Seguro Social, Av. Gustavo Baz Prada S/N, Neighborhood Centro Industrial Tlalnepantla, CP 54000, Tlalnepantla de Baz, Estado de México, Mexico*

### ARTICLE INFO

#### Keywords:

SARS-CoV-2  
COVID-19  
Pneumothorax  
Pneumomediastinum

### ABSTRACT

Cases of pneumothorax/pneumomediastinum have been reported in patients with severe acute respiratory syndrome coronavirus 2 (SARS-CoV-2); however, the time to onset and hospital stay have rarely been studied. Coronavirus disease 2019 (COVID-19) patients with these complications are described to determine the time to onset, associated comorbidities, and location and duration of pneumothorax. A search in PubMed yielded simple frequencies and a bivariate analysis of deaths. There were 113 confirmed cases in 67 articles. The median time from the date of hospital admission to the presence of pneumothorax was 8 days. Right hemithorax was the most frequent form of pneumothorax. Almost half of the patients required intubation for invasive mechanical ventilation. Although the frequency of this phenomenon was not high among hospitalized patients with confirmed SARS-CoV-2, it was high among those who developed acute respiratory distress syndrome (ARDS). This study contributes to the literature because it presents a large number of patients who developed pneumothorax after admission, which was characterized by clinical deterioration (dyspnea, tachypnea, pleuritic chest pain, and subcutaneous emphysema) and low oxygen saturation levels. Pneumothorax/pneumomediastinum is recommended as a differential diagnosis, even without considering the presence of chronic pulmonary comorbidities or invasive mechanical ventilation.

## 1. Background

One year after coronavirus disease 2019 (COVID-19) was declared a pandemic, the understanding of the range of clinical respiratory manifestations as well as those in other organs and systems, including both acute manifestations and sequelae, is continuing. Within the respiratory system, the most common manifestation has been the development of pneumonia, often characterized as bilateral and involving the periphery toward the center with marked leukopenia and lymphopenia [1]. Similarly, COVID-19 cases with pneumothorax and pneumomediastinum at hospital admission have been reported, which pose a diagnostic and therapeutic challenge. Therefore, the present study analyzes the published case reports of patients affected by COVID-19 who presented with these complications to determine the time of onset, associated comorbidities, location and duration of the pneumothorax,

and outcomes.

## 2. Materials and methods

### 2.1. Origin and selection of studies

A PubMed search was performed with the following search terms on February 27, 2021: COVID and pneumothorax. Articles that were case reports and case series were selected (Fig. 1). Articles and case descriptions with as much information as possible were selected for analysis; therefore, not all case studies were selected [2–68].

### 2.2. Variables recorded

A database was constructed to store the following information:

\* Corresponding author. Av. Cuauhtémoc # 330, Block "B" 4° Floor, Annex to the Unidad de Congresos del Centro Médico Nacional Siglo XXI, Neighborhood Doctores, Alcaldía Cuauhtémoc, CP 06720, Mexico City, Mexico. Tel.: +52 55 55 56 27 69 00 ext. 21216.

E-mail addresses: [david.cabrera@imss.gob.mx](mailto:david.cabrera@imss.gob.mx), [dcpreventiva@gmail.com](mailto:dcpreventiva@gmail.com) (D.A. Cabrera Gaytán), [yadira.perezan@imss.gob.mx](mailto:yadira.perezan@imss.gob.mx) (Y. Pérez Andrade), [yuridia21@live.com](mailto:yuridia21@live.com) (Y. Espíritu Valenzo).

<https://doi.org/10.1016/j.rmcr.2021.101490>

Received 10 May 2021; Received in revised form 14 July 2021; Accepted 23 July 2021

Available online 26 July 2021

2213-0071/© 2021 Published by Elsevier Ltd. This is an open access article under the CC BY-NC-ND license (<http://creativecommons.org/licenses/by-nc-nd/4.0/>).

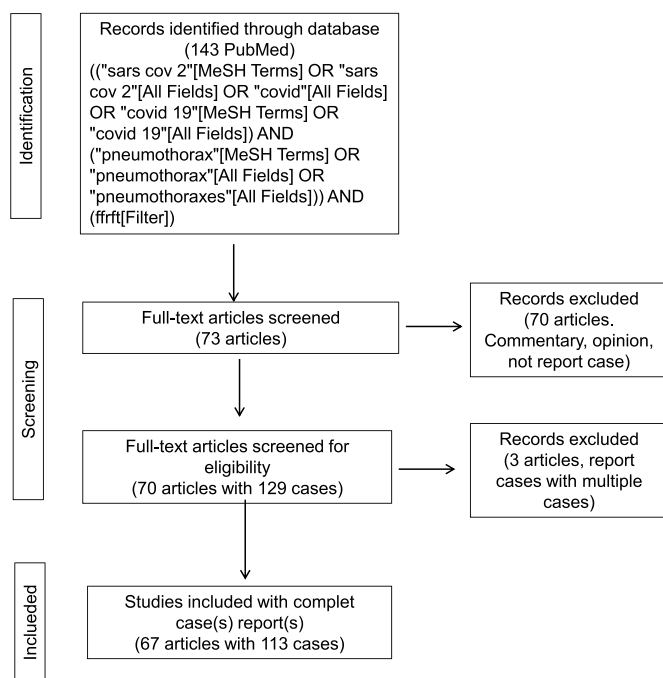


Fig. 1. Flow diagram.

country, age, sex, clinical manifestations, underlying diseases, time to onset, duration and location of the pneumothorax, length of hospital stay (days), and outcome.

### 2.3. Statistical analysis

The analysis was performed using simple descriptive statistics, as well as the *t*-test for two independent samples, the Wilson score for continuity correction for population size proportions, Hartley's test to assess the homogeneity of variance, and bivariate analysis to estimate risks using Open Source Epidemiological Statistics for Public Health software [69].

## 3. Results

A total of 113 laboratory-confirmed COVID-19 cases in 22 countries were identified, and the highest proportions of reported cases were in the United States of America (47/113, 41.6%), China (19/113, 8.8%), and Mexico (3,113, 2.7%).

Pneumothorax associated with COVID-19 was more common among men (92/113, 81.5%; 95% CI 73.26–87.51,  $p < 0.001$ ). The median age was 57.0 years (IQR = 21.0, 22 to 90); the median age was 57.0 years (IQR = 19.5, SD = 14.1) among women and 56.5 years (IQR = 22.3, SD = 14.7) among men, with no significant difference between men and women ( $p = 0.887$ ). The median number of days between the date of hospital admission and the presence of pneumothorax could be determined in 110 of the 113 cases (8 days, 0 to 54, IQR = 15.0, SD 10.2). Sex was a factor in the time of onset of pneumothorax; among women, the median time was 2 days, and among men, the median time was 9 days ( $p = 0.001$ ), with unequal variance ( $p = 0.0412$ ). In 70 patients, the presence of pneumothorax was identified at least 1 day after the date of admission (mode, 11 days). Initially, clinical and imaging signs of pneumonia were documented in these patients, and subsequently, at least some of the following signs and symptoms appeared: pleuritic chest pain, subcutaneous emphysema, and low levels of oxygen saturation; thus, new imaging data were warranted.

The most frequent comorbidities were systemic arterial hypertension (27.4% with 31 patients), 20 persons with overweight/obesity (17.7%

(95%CI 1.7–25.7), 19 cases with diabetes mellitus (16.8%, 95%CI 11.0–24.7), and 15 patients with smoking (13.3%, 95%CI 8.2–20.8). The following diseases were recorded only in women: upper gastrointestinal bleeding, meningioma, hypothyroidism, and sarcoidosis. Records of underlying disease were lacking in 45 patients; in additive terms, a quarter of the patients presented 1 comorbidity (28 patients), 15.9% presented 2 underlying diseases (18 patients), 13.3% presented 3 underlying diseases (15 patients), 4.4% presented 4 underlying diseases (5 patients), and 1.8% presented 6 underlying diseases (2 patients).

Regarding clinical manifestations, 22 clinical data points were reported, and the most frequent were dyspnea in 93 patients (82.0%, 95% CI 74.3–88.3), fever in 69 patients (61.1%, 95% CI 51.9–69.5), dry cough in 65 patients (57.0% CI 95% 48.3–66.2), chest pain in 39 patients (34.5%, 95% CI 26.4–43.6), and 32 patients subcutaneous emphysema (28.3%, 95% CI 20.8–37.2).

Regarding the diagnostic imaging methods, chest radiography was used in 67 cases, and computerized axial tomography was used in 61 cases. Among the imaging findings, 11.5% (95% CI 5.7–21.8) of the patients had bullae, and 36 patients had pneumomediastinum (31.8%, 95% CI 23.9–40.9). Regarding the location of the pneumothorax, the right side was the most predominant location and was observed in 43 patients (38.1%, 95% CI 29.6–47.3), with the left side predominant in 28 patients (24.8%, 95% CI 17.7–33.5), and bilateral pneumothorax was observed in 23 patients (20.4%, 95% CI 13.9–8.7); however, in 4 patients, the pneumothorax started ipsilaterally (3 right and 1 left) and subsequently covered both lungs. For 13.3% of cases, the affected side was not specified. Ipsilateral right pneumothorax was predominant in both men and women. Almost half of the patients required intubation for invasive mechanical ventilation (47.8%, 95% CI 38.8–56.9). Pneumothorax management occurred through the usual surgical treatment is pleurostomy, and imaging controls were used to remove the installed probe. The duration of the pneumothorax could be determined in 58 patients, either by imaging or by tube removal, with a median of 6.5 days (1–92 days, IQR = 14.0, SD = 16.1). The median time until resolution was 14 (2–25) days ( $p = 0.0178$ ) in 12 women, and that for 48 men was 5.5 (1–92) days. The duration of hospital stay was obtained for 60 patients, with a median of 19.5 days (1–97, IQR = 23.5, SD = 20.3), and was longer for men (22 vs 14 days,  $p = 0.042$ ).

Healthcare-associated infections were documented in 7 patients, including 5 of bacterial origin and 2 cases of fungemia.

The reasons discharge was mentioned for 79 patients; for 51 patients, discharge resulted from improvement (64.6%), and 26 patients died (32.9%). Although the median age was higher among the deceased group, there was no statistically significant difference between patients who died and those discharged because of improvement (median 59 vs. 54 years,  $p = 0.139$ ). When considering all cases, the mortality rate was 23% (26 deaths).

Three patients, 2 from Italy and 1 from India, presented resolution of the pneumothorax, and subsequently, a new event occurred on the same affected side, with 1, 3, and 28 days between each episode.

In the bivariate analysis, patients who received mechanical ventilation had a 72-fold higher risk of dying than nonintubated patients (OR 73.08, 95% CI 8.989–594.1,  $p < 0.001$ ). Patients with pneumomediastinum were twice as likely to die (OR 3.007, 95% CI 1.062–8.512,  $p 0.044$ ), while  $\geq 7$  days of pneumothorax evolution had no influence on death (OR 0.9018, 95% CI 0.2444–3.258,  $p < 0.877$ ).

## 4. Discussion

There were 113 confirmed cases of pneumothorax or pneumomediastinum in 67 reports, and the median time from the date of hospital admission to the presence of pneumothorax was 8 days. However, determining the interval from the date of symptom onset was not possible due to the absence of data in the publications. The presentation of progressive deterioration of respiratory function in people with severe acute respiratory syndrome coronavirus 2 (SARS-CoV-2) infection has

been linked to the presence of spontaneous pneumothorax and/or pneumomediastinum in isolated or associated form. Similarly, the development of pneumothorax is predominant in men, older adults, and those with a history of chronic lung disease, smoking, or invasive mechanical ventilation [70,71]. In the present compilation, male sex and age older than 50 years were consistent with the findings of other studies [70–72]. Although the presence of pneumothorax is more common in patients under invasive mechanical ventilation with acute respiratory distress syndrome (ARDS), advanced ventilatory management requires great *expertise* in the management of ventilatory parameters, as it can promote the formation of cysts and emphysema [75]. The mechanical effect of the persistence of pronounced cough most likely contributes to the development of pneumothorax and pneumomediastinum [74].

The description of the clinical picture was indicative of patient symptoms, with the most frequent being dyspnea, dry cough, and fever; therefore, these symptoms composed the operational definition of a suspected case of viral respiratory disease in Mexico [76], although these complications were not considered for epidemiological surveillance. Likewise, these clinical manifestations were reported in a case-control study [77].

Regarding comorbidities, although varying marginally in terms of percentage, systemic arterial hypertension and diabetes mellitus coincided among patients with SARS-CoV-2 [78]. Overweight/obesity was present in 17.7% of patients; therefore, it was assumed that the remaining patients had a normal weight, indicating that pneumothorax is more common in thin and tall people because they have a higher pressure gradient in the pulmonary vertices and that alternate routes of air leakage are present due to alveolar ruptures of the interstitium.

Regarding the presentation of hemithorax, 38.1% were on the right side, which is likely related to anatomical conditions at the level of the tracheal bifurcation, where the right bronchus is more vertical and shorter than the left. The median hospital stay was 19.5 days; among patients with COVID-19, barotrauma was associated with a longer hospital stay (25 days versus 18 days for patients who did not present this complication) [78]. Similarly, barotrauma is an independent risk factor for death in COVID-19 [79]; the effect of barotrauma is evident in this disease, barotrauma occurred in 0.5% of patients who had invasive mechanical ventilation for reasons other than COVID-19 and in 10% of patients who had ARDS during the period from 2016 to 2020 [79], what represents the challenge for the care of the patient in life support.

Pneumothorax is one of the main causes of ARDS, which increases the probability of dying. The challenge of pneumothorax in patients infected with SARS-CoV-2 is that despite ventilatory care and administration of neuromuscular blockers, patients still present a high frequency of pneumothorax [78,80]. This high frequency occurs because patients with SARS-CoV-2 require high positive end-expiratory pressure (PEEP). When compiling the cases, it was evident that if a patient presented with pneumomediastinum, the probability of dying increased; this finding differed from that of a series of 71 cases in 16 centers, where no difference was found [72].

Wang, in a series of 248 COVID-19 cases, reported that 2% of patients presented pneumothorax, which increased to 80% when ARDS was present; therefore, in that series, 80% of patients died [71]. The presence of pneumothorax with COVID-19 was diagnosed in 92% of patients who underwent invasive mechanical ventilation and in 13.72% of those who presented ARDS [78]; as well as in a multicenter retrospective analysis of all adult critically ill patients with COVID-19 infection, the overall incidence of pneumothorax in mechanically ventilated patients with COVID-19 infection was 13% [81]. In a retrospective study in China, pneumothorax occurred in 1% of patients [14]. In this study, pneumothorax occurred in 47.7% of those who required this invasive approach. Therefore, the differences in results are based on the method used to estimate disease frequency. COVID-19-related pneumothoraxes are associated with prolonged hospitalization, but in this case series, this phenomenon was not observed. Furthermore, the onset of pneumothorax that occurs after admission suggests a sustained period of lung

inflammation with extensive parenchymal injury and likely a severe course of COVID-19 infection.

Of the total cases, 7 presented healthcare-associated infection, mainly by bacteria and less frequently by fungi. Although the median hospital stay was 19.5 days, patients underwent invasive therapeutic methods, even though the collection of biological samples for respiratory microbiological cultures was decreased due to the risk of generating aerosols in hospital units. Therefore, the presence of infection is likely underestimated, especially due to the damage caused primarily by the virus, which promotes additional bacterial infections [8] and the formation of fibromyxoid exudates [73]. Likewise, the presence of pneumothorax has been associated with the appearance of pneumatoceles and bullae related to pneumonia, which are usually not observed in the early stages of the disease [56].

The limitations of this study were related to data collection, including the date of symptom onset and patient outcome. Although it was not possible to determine the time between the date of symptom onset and the appearance of pneumothorax in the present compilation, Zantah et al. documented this parameter in their report of 6 cases (median, 12 days) [67]. In a series of cases in China, the interval between dyspnea and pneumothorax ranged from 15 to 40 days, without any patient having chronic pulmonary comorbidities [71]. Other limitations include the inability to obtain the duration of the pneumothorax, length of hospital stay, and outcome at discharge from the hospital. For example, Chong found that the time to pneumothorax diagnosis was approximately 9.0–19.6 days from admission [82]. However, that study had the same limitation, the inability to determine the date of symptom onset. Additionally, in our study of 70 patients, the presence of pneumothorax was identified at least 1 day after the date of admission. Although the frequency of this phenomenon was not as high among hospitalized patients confirmed with SARS-CoV-2, it was high among those who developed ARDS. Therefore, this study contributes to the literature because it presents a large number of patients who presented pneumothorax after admission, which is characterized by clinical deterioration (dyspnea, tachypnea, pleuritic chest pain, and subcutaneous emphysema) and low oxygen saturation levels. In addition, the articles published in this clinical series show the importance of recording events based on the date of symptom onset will result in an increased understanding of the natural history of the disease. Another limitation was that some mildly symptomatic COVID-19 patients with undiagnosed pneumothorax could have been advised to remain at home during the outbreak due to the fear of further COVID-19 transmission during hospitalization and exhaustion of the current healthcare system; this again emphasizes the importance of knowing the date of symptom onset. Third, most of the published studies that we reviewed were in English. Finally, we recommend pneumothorax as a differential diagnosis in patients with SARS-CoV-2 infection, even without considering the presence of chronic pulmonary comorbidities or invasive mechanical ventilation. Finally, men and older adults, in particular, are the most likely to present pneumothorax.

## Funding

This research did not receive any specific grant from funding agencies in the public, commercial, or not-for-profit sectors.

## Declarations of competing interest

None.

## Acknowledgments

None.

## References

- [1] N. Chen, M. Zhou, X. Dong, et al., Epidemiological and clinical characteristics of 99 cases of 2019 novel coronavirus pneumonia in Wuhan, China: a descriptive study, *Lancet* 395 (2020) 507–513.
- [2] A. Abushahin, J. Degliuomini, W.S. Aronow, T.G. Newman, A case of spontaneous pneumothorax 21 Days after diagnosis of coronavirus disease 2019 (COVID-19) pneumonia, *Am J Case Rep* 21 (2020), e925787, <https://doi.org/10.12659/AJCR.925787>.
- [3] B. Agridag Ucpinar, C. Sahin, U. Yanc, Spontaneous pneumothorax and subcutaneous emphysema in COVID-19 patient: case report, *J Infect Public Health* 13 (2020) 887–889.
- [4] A. Alhakeem, M.M. Khan, H. Al-Soub, Z. Yousaf, Case report: COVID-19 – associated bilateral spontaneous pneumothorax – a literature review, *Am. J. Trop. Med. Hyg.* 103 (3) (2020) 1162–1165, <https://doi.org/10.4269/ajtmh.20-0680>.
- [5] S.D. Al-Shokri, A.O.E. Ahmed, A.O. Saleh, M. AbouKamar, K. Ahmed, et al., Case report: COVID-19-Related pneumothorax—case series highlighting a significant complication, *Am. J. Trop. Med. Hyg.* 103 (3) (2020) 1166–1169.
- [6] A. Alharthy, G.H. Bakirova, H. Bakheet, A. Balhamar, P.G. Brindley, S.A. Alqahtani, et al., COVID-19 with spontaneous pneumothorax, pneumomediastinum, and subcutaneous emphysema in the intensive care unit: two case reports, *J Infect Public Health* 14 (2021) 290–292.
- [7] A.S. Ahluwalia, T. Qarni, N. Narula, W. Sadiq, M.N. Chalhoub, Bilateral pneumothorax as possible atypical presentation of coronavirus disease 2019 (COVID-19), *Respir Med Case Rep* 31 (2020) 101217.
- [8] R.E. Akdogan, T. Mohammed, A. Syeda, N. Jiwa, O. Ibrahim, et al., Pneumothorax in mechanically ventilated patients with COVID19 infection, *Case Rep Crit Care* (2021). Article ID 6657533.
- [9] K. Amoah, K. Gunasekaran, M.S. Rahi, M.G. Buscher, A case of secondary tension pneumothorax in COVID-19 pneumonia in a patient with no prior history of lung disease, *SAGE Open Medical Case Rep* 8 (2020) 1–4.
- [10] S. Ayazi, J. Zebarjadi, A.D. Grubic, H. Tahmasbi, K. Ayazi, et al., Pneumothorax as the presenting manifestation of COVID-19, *J. Thorac. Dis.* 12 (12) (2020) 7488–7493, <https://doi.org/10.21037/jtd-20-1687>.
- [11] R. Bellini, M. Salandini, S. Cuttin, S. Mauro, P. Scarpazza, C. Cotsoglou, Spontaneous pneumothorax as unusual presenting symptom of COVID-19 pneumonia: surgical management and pathological findings, *J. Cardiothorac. Surg.* 15 (2020) 310, <https://doi.org/10.1186/s13019-020-01343-4>.
- [12] Capleton P, Ricketts W, Lau K, Ellis S, Sheaff M, Giaslaktiotis K, Uys S, Tchraikian N. Pneumothorax and Pneumatocele Formation in a Patient with COVID-19: a Case Report. *SN Compr Clin Med* <https://doi.org/10.1007/s42399-020-00689-z>.
- [13] Caviezel C, Weiss L, Haessig G, Alfari C, et al. Case report of sequential bilateral spontaneous pneumothorax in a never-ventilated, lung-healthy COVID-19-patient. *Int J Surg Case Rep*, <https://doi.org/10.1016/j.ijscr.2020.09.148>.
- [14] X. Chen, G. Zhang, Y. Tang, Z. Peng, H. Pan, The coronavirus diseases 2019 (COVID-19) pneumonia with spontaneous pneumothorax: a case report, *BMC Infect. Dis.* 20 (2020) 662, <https://doi.org/10.1186/s12879-020-05384-x>.
- [15] M.A. Al Kaisy, Chest drain insertion following pneumothorax due to CPR in a COVID – 19 patient, *Vis J Emerg Med* 21 (2020) 100862.
- [16] J. Dennisona, S. Carlsona, S. Faehlinga, M. Lieba, A. Mubarik, Case report: spontaneous pneumothorax in resolved, uncomplicated COVID-19 Pneumonia-A literature review, *Respir Med Case Rep* 31 (2020) 101291.
- [17] C. Elder, S. Bawa, D. Anderson, S. Atkinson, J. Etzel, et al., Expectant management of pneumothorax in intubated COVID-19 positive patients: a case series, *J. Cardiothorac. Surg.* 15 (2020) 263.
- [18] T.S. Elhakim, H.S. Abdul, C. Peláez-Romero, Y. Rodríguez-Fuentes, Spontaneous pneumomediastinum, pneumothorax and subcutaneous emphysema in COVID-19 pneumonia: a rare case and literature review, *BMJ Case Rep.* 13 (2020), e239489, <https://doi.org/10.1136/bcr-2020-239489>.
- [19] B. Eperjesiova, E. Hart, M. Shokr, et al., Spontaneous pneumomediastinum/pneumothorax in patients with COVID-19, *Cureus* 12 (7) (July 03, 2020), e8996, <https://doi.org/10.7759/cureus.8996>.
- [20] Q. Fan, F. Pan, L. Yang, Spontaneous pneumothorax and subpleural bullae in a patient with COVID-19: a 92-day observation, *Eur. J. Cardio. Thorac. Surg.* 58 (2020) 858–860.
- [21] L. Flower, J.P. Carter, J. Rosales-López, A.M. Henry, Tension pneumothorax in a patient with COVID-19, *BMJ Case Rep.* (2020), e235861, <https://doi.org/10.1136/bcr-2020-235861>, 0.
- [22] M. Gillespiea, N. Dinchera, P. Fazioc, O. Okorjia, J. Finklea, A. Canb, Coronavirus disease 2019 (COVID-19) complicated by spontaneous pneumomediastinum and pneumothorax, *Respir Med Case Rep* 31 (2020) 101232.
- [23] H. González-Pacheco, R. Gopar-Nieto, G.M. Jiménez-Rodríguez, D. Manzur-Sandoval, J. Sandoval, et al., Bilateral spontaneous pneumothorax in SARS-CoV-2 infection: a very rare, life-threatening complication, *Am. J. Emerg. Med.* 39 (2021) 258, <https://doi.org/10.1016/j.ajem.2020.07.018>, e1–258.e3.
- [24] J. Guimarães Ferreira, C. Rappariní, B. Moreno Gomes, A.E. Cabral Pinto, M.S. da Silva, et al., Pneumothorax as a late complication of COVID-19, *Rev. Inst. Med. Trop. Sao Paulo* 62 (2020) e61.
- [25] M. Hameeda, W. Jamal, M. Yousaf, M. Thomas, et al., Pneumothorax in covid-19 pneumonia: a case series, *Respir Med Case Rep* 31 (2020) 101265.
- [26] V. Hazariwala, H. Hadid, D. Kirsch, C. Big, Spontaneous pneumomediastinum, pneumopericardium, pneumothorax and subcutaneous emphysema in patients with COVID-19 pneumonia, a case report, *J. Cardiothorac. Surg.* 15 (2020) 301.
- [27] T. Horri, T. Fujioka, M. Takahashi, M. Mori, J. Tsuchiya, et al., Late-onset pneumothorax in a COVID-19 patient treated with ventilation and ECMO: a case report and literature review, *Radiol Case Report* 15 (2020) 2560–2564.
- [28] I. Muhammad, E.J. Boynton, S. Naureen, COVID-19 with bilateral pneumothoraces- case report, *Respir Med Case Rep* 31 (2020) 101254.
- [29] M.L. Janssen, M.J.G. van Manena, S.E. Cretier, G.J. Braunstahl, Pneumothorax in patients with prior or current COVID-19 pneumonia, *Respir Med Case Rep* 31 (2020) 101187.
- [30] Kasturi S, Muthirevula A, Reddy RR, Lingaraju VC. Delayed recurrent spontaneous pneumothorax post-recovery from COVID-19 infection. *Indian J. Thorac. Cardiovasc. Surg.* <https://doi.org/10.1007/s12055-021-01145-w>.
- [31] R. Khurram, F.T.F. Johnson, R. Naran, S. Hare, Spontaneous tension pneumothorax and acute pulmonary emboli in a patient with COVID-19 infection, *BMJ Case Rep.* 13 (2020), e237475, <https://doi.org/10.1136/bcr-2020-237475>.
- [32] K. Liu, Y. Zeng, P. Xie, X. Ye, G. Xu, J. Liu, H. Wang, J. Qian, COVID-19 with cystic features on computed tomography: a case report, *Medicine* 99 (2020) 18, e20175.
- [33] T. Mallick, A. Dinesh, R. Engdahl, et al., COVID-19 complicated by spontaneous pneumothorax, *Cureus* 12 (7) (July 09, 2020), e9104, <https://doi.org/10.7759/cureus.9104>.
- [34] Manna S, Maron SZ, Cedillo MA, Voutsinas N, ToussieD, et al. Spontaneous subcutaneous emphysema and pneumomediastinum in non-intubated patients with COVID-19. *Clin. Imag.* 2020(67): 207–213.
- [35] S. Marsico, L.A. Del Carpio-Bellido, F. Zuccarino, Spontaneous pneumothorax in COVID-19 patients, *Arch. Bronconeumol.* 57 (S1) (2021) 66.
- [36] A.M. Marza, A. Petrica, F.N. Buleu, O.A. Merdele, Case report: massive spontaneous pneumothorax—a rare form of presentation for severe COVID-19 pneumonia, *Medicina* 57 (2021) 82, <https://doi.org/10.3390/medicina57020082>.
- [37] A.F. Muhi, A.A. Mohammad, H.A. Al-Khalidi, A.S. Alshewered, Spontaneous pneumothorax as a complication in COVID-19 male patient: a case report, *Clin. Case Rep* 8 (2020) 3115–3118, <https://doi.org/10.1002/ccr3.3378>.
- [38] K. Nakatsutsumi, K. Sekiya, N. Urushibata, M. Hosoi, H. Arai, et al., A successful case of extracorporeal membrane oxygenation treatment for intractable pneumothorax in a patient with COVID-19, *Acute Med Surg* 7 (2020) e612.
- [39] K. Nunna, A.B. Braun, *BMJ Case Rep.* 14 (2021), e238863, <https://doi.org/10.1136/bcr-2020238863>.
- [40] M. Oye, A. Ali, F. Kandah, N. Chowdhury, Two cases of spontaneous pneumomediastinum with pneumothorax in patients with COVID-19 associated pneumonia, *Respir Med Case Rep* 31 (2020) 101308.
- [41] K.P. Pérez-López, L.G. Moreno-Madrigal, Neumotórax y neumomediastino espontáneos en pacientes con neumonía por COVID-19, *Med. Int. Mex.* 37 (1) (2021) 152–156, <https://doi.org/10.24245/mim.v37i1.4755>.
- [42] L. Perice, Z. Roit, I. Lovera, M.G. Flanagan-Kundle, Spontaneous pneumothorax as a complication of COVID-19 pneumonia: a case report, *Clin Pract Cases Emerg Med* 4 (4) (2020) 521–523.
- [43] E. Poggiali, A. Vercelli, T. Iannicelli, V. Tinelli, L. Celoni, A. Magnacavallo, COVID-19, chronic obstructive pulmonary disease and pneumothorax: a frightening triad, *EJCRIM* 7 (2020), [https://doi.org/10.12890/2020\\_001742](https://doi.org/10.12890/2020_001742).
- [44] A. Quincho-Lopez, D.L. Quincho-Lopez, F.D. Hurtado-Medina, Case report: pneumothorax and pneumomediastinum as uncommon complications of COVID-19 pneumonia—literature review, *Am. J. Trop. Med. Hyg.* 103 (3) (2020) 1170–1176, <https://doi.org/10.4269/ajtmh.20-0815>.
- [45] M.J. Rafiee, F.B. Fard, K. Samimi, H. Rasti, J. Pressacco, Spontaneous pneumothorax and pneumomediastinum as a rare complication of COVID-19 pneumonia: report of 6 Cases, *Radiol Case Rep* 16 (2021) 687–692.
- [46] L. Rampa, A. Miceli, F. Casilli, T. Biraghi, et al., Lung complication in COVID-19 convalescence: a spontaneous pneumothorax and pneumatocele case report, *J Respir Dis Med* 2 (2020) 1–3, doi:10.15761/JRDM.1000115.
- [47] T. Rehman, G. Josephson, M. Sunbuli, A.R. Chadaga, Spontaneous pneumothorax in an elderly patient with coronavirus disease (COVID-19) pneumonia, *Ochsner J.* 20 (2020) 343–345.
- [48] Redondo-Sendino A, Gómez-Cunarro M, Jenkins-Sánchez CP, et al., Neumotórax Asociado a COVID-19, *Med Fam SEMERGEN*, <https://doi.org/10.1016/j.semerg.20.11.004>.
- [49] S. Rohailla, N. Ahmed, J. Gough, *CMAJ (Can. Med. Assoc. J.)* 192 (2020 May 11) E510, <https://doi.org/10.1503/cmaj.200609>.
- [50] Salah O, Faisal M, Alshahwani I, et al. (September 08, 2020) bilateral hemopneumothorax in COVID-19. *Cureus* 12(9): e10314. DOI 10.7759/cureus.10314.
- [51] R.R. Sanivarapu, K. Farraj, N. Sayedi, F. Anjum, Rapidly developing large pneumatocele and spontaneous pneumothorax in SARS-CoV-2 infection, *Respir Med Case Rep* 31 (2020) 101303.
- [52] S. Shan, L. Guangming, L. Wei, Y. Xuedong, Spontaneous pneumomediastinum, pneumothorax and subcutaneous emphysema in COVID-19: case report and literature review. *Rev. Inst. Med. Trop. Sao Paulo* 62 (2020) e76.
- [53] T. Shirai, T. Mitsumura, K. Aoyagi, T. Okamoto, M. Kimura, et al., COVID-19 pneumonia complicated by bilateral pneumothorax: a case report, *Respir Med Case Rep* 31 (2020) 101230, <https://doi.org/10.1016/j.rmcr.2020.101230>.
- [54] F. Sonia, M. Kumar, A complication of pneumothorax and pneumomediastinum in a non-intubated patient with COVID-19: a case report, *Cureus* 12 (8) (August 26, 2020), e10044, <https://doi.org/10.7759/cureus.10044>.
- [55] J.E. Spiro, S. Sisovic, B. Ockert, W. Böcker, et al., Secondary tension pneumothorax in a COVID-19 pneumonia patient: a case report, *Infection* 48 (6) (2020) 941–944, <https://doi.org/10.1007/s15010-020-01457-w>.
- [56] R. Sun, H. Liu, X. Wang, Mediastinal emphysema, giant Bulla, and pneumothorax developed during the course of COVID-19 pneumonia, *Korean J. Radiol.* 21 (5) (2020) 541–544.
- [57] L. Tucker, S. Patel, C. Vatsis, A. Poma, A. Ammar, et al., Pneumothorax and pneumomediastinum secondary to COVID-19 disease unrelated to mechanical

- ventilation, *Case Rep Crit Care* (2020), <https://doi.org/10.1155/2020/6655428>. Article ID 6655428, 5 pages.
- [58] A. Vahidirad, A. Jangjoo, M. Ghelichli, A. Arian-Nia, et al., Tension pneumothorax in patient with COVID-19 infection, *Radiol Case Rep* 16 (2021) 358–360.
- [59] R.M. Vela-Colmenero, P. Gallego de Guzmán, M.C. Molina de la Torre, Neumomediastino y neumotórax espontáneo en neumonía bilateral por COVID-19, *Med. Intensiva* 44 (9) (2020) 591–592.
- [60] S. Volpi, J.M. Ali, A. Suleman, R.N. Ahmed, Pneumomediastinum in COVID-19 patients: a case series of a rare complication, *Eur. J. Cardio. Thorac. Surg.* (2020), <https://doi.org/10.1093/ejcts/ezaa222>.
- [61] W. Wang, R. Gao, Y. Zheng, L. Jiang, COVID-19 with spontaneous pneumothorax, pneumomediastinum and subcutaneous emphysema, *J. Trav. Med.* 27 (5) (2020) 1–2, doi:10.1093/jtm/taaa062.
- [62] C. Xiang, G. Wu, SARS-CoV-2 pneumonia with subcutaneous emphysema, mediastinal emphysema, and pneumothorax, *Medicine* 99 (2020), e20208, 20.
- [63] W. Xu, X. Luo, H. Wang, C. Shen, Y. Song, et al., Pulmonary emphysema, bullae, and pneumothorax in COVID-19 pneumonia, *Case Report* 16 (2021) 995–998.
- [64] T. Yamaya, T. Baba, E. Hagiwara, S. Ikeda, T. Niwa, et al., Pneumothorax in a COVID-19 pneumonia patient without underlying risk factors, *Intern. Med.* (59) (2020) 2921–2925, <https://doi.org/10.2169/internalmedicine.5731-20>.
- [65] K. Yasukawa, A. Yamadevan, R. Rollins, Bulla formation and tension pneumothorax in a patient with COVID-19, *Am. J. Trop. Med. Hyg.* 103 (3) (2020) 943–944, <https://doi.org/10.4269/ajtmh.20-0736>.
- [66] Younes I, Mohammadian M, Elkattawy S, et al. (December 20, 2020) SARS-CoV-2 associated with pneumothorax: a case report and literature review. *Cureus* 12(12): e12191. DOI 10.7759/cureus.12191.
- [67] M. Zantah, E. Domínguez-Castillo, R. Townsend, F. Dikengil, G.J. Criner, Pneumothorax in COVID-19 disease incidence and clinical characteristics, *Zantah et al. Respir Res* 21 (2020) 236, <https://doi.org/10.1186/s12931-020-01504-y>.
- [68] S. Zayet, T. Kolpfenstein, C. Mezher, V. Gendrin, T. Conrozier, A. Abdallah, Coronavirus disease 2019 with spontaneous pneumothorax, pneumomediastinum and subcutaneous emphysema, France. *New Microbe New Infect* 38 (2020) 100785.
- [69] Dean AG, Sullivan KM, Soe MM. OpenEpi: open-source epidemiologic statistics for public Health, versión. [www.OpenEpi.com](http://www.OpenEpi.com), actualizado 2013/04/06, accedido 2021/03/24.
- [70] E. Terzi, K. Zarogoulidis, I. Kougioumtzi, et al., Acute respiratory distress syndrome and pneumothorax, *J. Thorac. Dis.* 6 (Suppl 4) (2014) S435–S442, <https://doi.org/10.3978/j.issn.2072-1439.2014.08.34>.
- [71] X. Wang, J. Duan, X. Han, X. Liu, J. Zhou, et al., High incidence and mortality of pneumothorax in critically ill patients with COVID-19, *Heart Lung* (50) (2021) 37–43.
- [72] A.W. Martinelli, T. Ingle, J. Newman, et al., COVID-19 and pneumothorax: a multicenter retrospective case series, *Eur. Respir. J.* 56 (2020) 2002697, <https://doi.org/10.1183/13993003.02697-2020>.
- [73] K. Liu, Y. Zeng, P. Xie, X. Ye, G. Xu, J. Liu, et al., COVID-19 with cystic features on computed tomography: a case report, *Medicine (Baltim.)* 99 (18) (2020), e20175.
- [74] B.A. Ucpinar, C. Sahin, U. Yanc, Spontaneous pneumothorax and subcutaneous emphysema in COVID-19 patient: case report, *J Infect Public Health* 13 (6) (2020) 887–889.
- [75] W.R. Henderson, L. Chen, M. Amato, L.J. Brochard, Respiratory mechanics in acute respiratory distress syndrome, *Am. J. Respir. Crit. Care Med.* 196 (7) (2017) 822–833, <https://doi.org/10.1164/rccm.201612-2495CI>.
- [76] Secretaría de Salud, Lineamiento estandarizado para la vigilancia epidemiológica y por laboratorio de la enfermedad respiratoria viral, Enero de México, 2021. Disponible en: <https://www.gob.mx/salud/documentos/manuales-para-la-vigilancia-epidemiologica-102563>.
- [77] Miró Ò, P. Llorens, S. Jiménez, P. Piñera, G. Burillo-Putze, et al., Frequency, risk factors, clinical characteristics, and outcomes of spontaneous pneumothorax in patients with coronavirus disease 2019: a case-control, emergency medicine-based multicenter study, *Chest* 159 (3) (2021 Mar) 1241–1255, <https://doi.org/10.1016/j.chest.2020.11.013>. Epub 2020 Nov 20.
- [78] Wong K, Kim D, Iakovou A, et al. (November 28, 2020) pneumothorax in COVID-19 acute respiratory distress syndrome: case series. *Cureus* 12(11): e11749. DOI 10.7759/cureus.11749.
- [79] G. McGuinness, C. Zhan, N. Rosenberg, L. Azour, et al., Increased incidence of barotrauma in patients with COVID-19 on invasive mechanical ventilation, *Radiology* 297 (2) (2020) E252–E262, <https://doi.org/10.1148/radiol.2020202352>.
- [80] M.L. Parra-Gordo, G. Buitrago Weiland, M. Grau García, G. Arenaza Choperena, Aspectos radiológicos de la neumonía COVID-19: evolución y complicaciones torácicas, *Radiología* (63) (2021) 74–88.
- [81] A. Chopra, A.H. Al-Tarbsheh, N.J. Shah, H. Yaqoob, K. Hu, et al., Pneumothorax in critically ill patients with COVID-19 infection: incidence, clinical characteristics and outcomes in a case control multicenter study, *Respir. Med.* 184 (2021 Aug) 106464, <https://doi.org/10.1016/j.rmed.2021.106464>. Epub 2021 May 13.
- [82] W.H. Chong, B.K. Saha, K. Hu, A. Chopra, The incidence, clinical characteristics, and outcomes of pneumothorax in hospitalized COVID-19 patients: a systematic review, *Heart Lung* 50 (5) (2021 May 1) 599–608, <https://doi.org/10.1016/j.hrtlng.2021.04.005>.