

## Case Report

# A Rare Coincidence of Two Coronary Anomalies in an Adult

**Cesar Cruz,<sup>1,2</sup> Dalton Mclean,<sup>2</sup> Matthew Janik,<sup>2</sup> Paolo Raggi,<sup>2</sup> and A. Maziar Zafari<sup>1,2</sup>**

<sup>1</sup>Division of Cardiology, Atlanta Veterans Affairs Medical Center, Decatur, GA 30033-4004, USA

<sup>2</sup>Division of Cardiology, Emory University, Atlanta, GA 30322, USA

Correspondence should be addressed to A. Maziar Zafari, azafari@emory.edu

Received 24 October 2009; Accepted 9 March 2010

Academic Editor: Fausto J. Pinto

Copyright © 2010 Cesar Cruz et al. This is an open access article distributed under the Creative Commons Attribution License, which permits unrestricted use, distribution, and reproduction in any medium, provided the original work is properly cited.

Anomalous right-sided left main coronary arteries and dual type IV left anterior descending arteries are rare coronary anomalies. In this case report, we present a 59 year old man with atypical chest pain and a combination of the above coronary anomalies as identified by selective coronary angiography and computed tomography angiography. To the best of our knowledge, the coincidence of these coronary anomalies has not been previously described.

## 1. Introduction

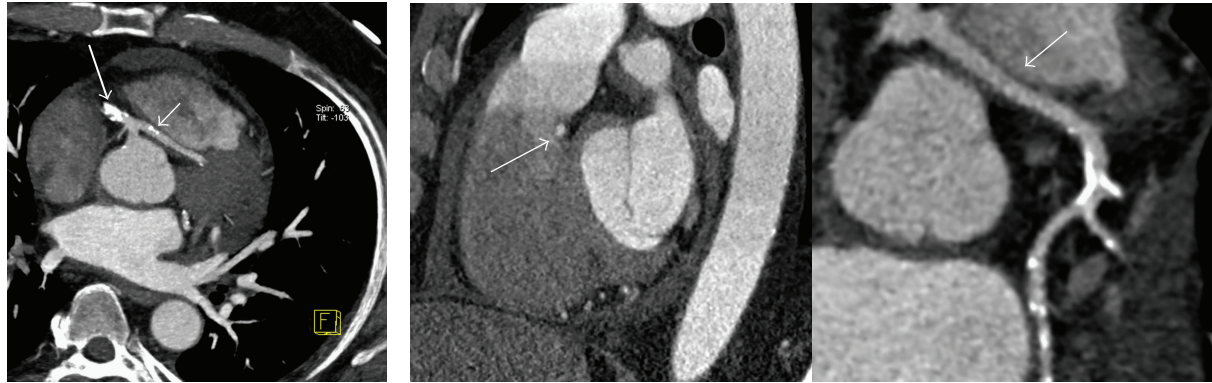
Anomalies of the coronary arteries occur in 0.2%–1.2% of the general population [1–3]. Anomalous left main coronary artery (LMCA) arising from the right sinus of Valsalva is found in 0.0024% to 0.03% of the population [2, 4]. Dual left anterior descending coronary artery (LADCA) is a rare congenital anomaly seen in about 1% of the population and is classified in four different types [5]. It is important to recognize both coronary anomalies due to different clinical implications.

In this case report, we present a patient with an anomalous LMCA arising from the right sinus of Valsalva that divides into a left circumflex coronary artery (LCXCA) and a long LADCA and an additional hypoplastic LADCA arising from the left sinus of Valsalva.

## 2. Case Report

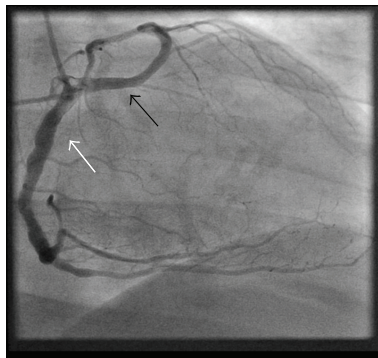
A 59-year-old man with a history of type 2 diabetes mellitus, hypertension, and dyslipidemia was referred to cardiology clinic for evaluation of atypical chest pain. The patient denied any family history of coronary artery disease and had a history of 60 pack years of smoking. Physical examination was normal as was the 12-lead electrocardiogram. He had a recent workup, including transthoracic echocardiography that showed a left ventricular ejection fraction of 60%, stage II diastolic dysfunction and mild biatrial enlargement,

and a radionuclear myocardial perfusion imaging stress test that showed no evidence of inducible ischemia or previous myocardial infarction. Patient underwent cardiac catheterization for definite evaluation of coronary artery disease. Selective right coronary angiography with a 6F right coronary Judkins 4 catheter revealed a common blood vessel from which the right coronary artery (RCA) and the LMCA were arising. The RCA followed its normal course around the atrioventricular groove and the LMCA traveled to the left side of the heart and divided at the level of the interventricular septum giving off a long LADCA and the LCXCA (Figure 1). Selective left coronary angiography with a 6F left Judkins 3.5 catheter revealed a second short hypoplastic LADCA that ended at the distal end of the proximal third of the interventricular sulcus without giving any branches of significant size (Figure 2). An aortogram was done to demonstrate the origins of the coronary blood vessels. Four coronary arteries were identified, one arising from the left coronary sinus and the other three originating from a main blood vessel from the right sinus of Valsalva. Left ventriculography showed normal chamber size and wall motion. There was significant calcification of the proximal segments of the RCA, LMCA, the longer LADCA, and the LCXCA without significant diameter stenoses. A coronary computed tomography angiography (CTA) was ordered to further delineate the course of the longer LADCA. Images were acquired with prospective gating on a 64-Multislice detector computed tomography scanner (Somatom Definition, Siemens, Forchheim, Germany) in the craniocaudal

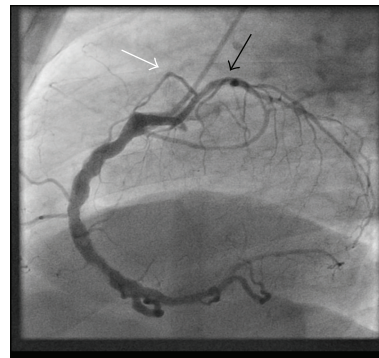


(a) Axial maximum intensity projection at the level of the origin of the LMCA (*small arrow*) from a common ostium with the right coronary artery (*large arrow*)

(b) Demonstration of the course of the LMCA below the pulmonary artery and through the septum by sagittal maximum intensity projection (*left*) and curved multiplanar reconstruction (*right*). Left main Coronary artery (*white arrow*)



(c) Right anterior oblique showing the LMCA (*black arrow*) arising with the right coronary artery (*white arrow*) from a common ostium in the right sinus of Valsalva



(d) Left lateral projection during selective coronary angiography demonstrating the LMCA dividing into a small caliber LADCA and the left circumflex artery in a 90-degree angle, with the LADCA traveling anteriorly (*white arrow*), and the left circumflex following its usual distribution posteriorly (*black arrow*)

FIGURE 1: Transseptal course of the right-sided left main coronary artery by CTA and selective coronary angiography.

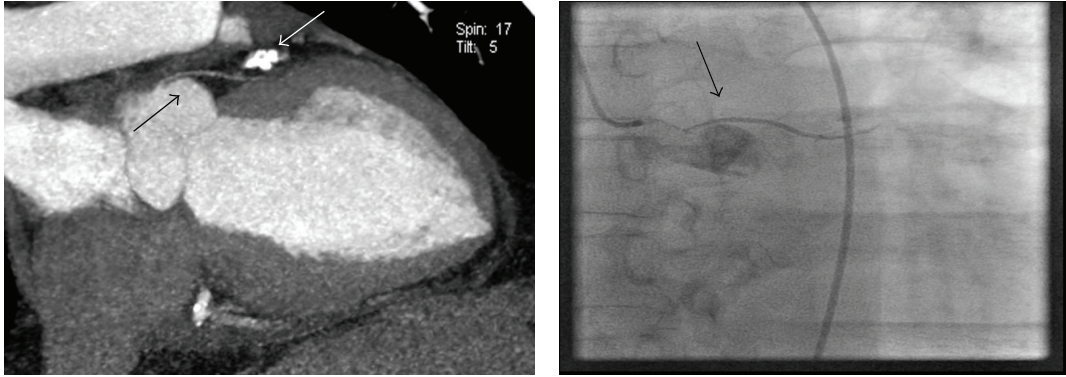
direction during suspended respiration at 0.75 mm slice thickness and reconstruction interval, 0.33 second gantry rotation speed, tube voltage 120 kVp, and a peak tube current of 390 mA. Cumulative dose-length product was 651 mGy  $\times$  cm. Iso-osmolar nonionic contrast material (Omnipaque, GE Healthcare, Princeton, NJ) was used. Premedication with nitroglycerin 0.6 mg SL was administered. No beta blocker was given since heart rate was  $<70$  per minute. CTA demonstrated the LMCA traveling to the left side of the heart behind the right ventricular outflow tract and through the interventricular septum (Figures 1 and 2). No angiographically significant stenoses or high-degree calcifications were noted.

### 3. Discussion

Coronary anomalies are frequently asymptomatic and usually discovered as incidental findings during diagnostic

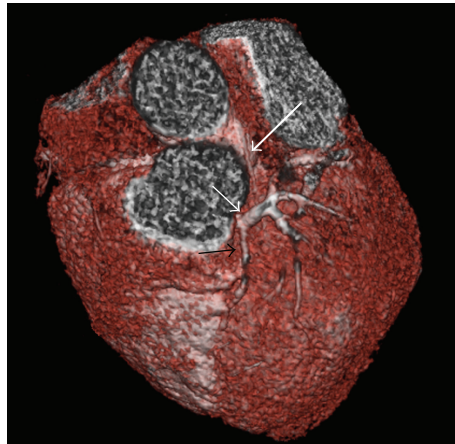
cardiac catheterization [6]. Its recognition may have significant clinical implications.

Spindola-Franco et al. classified dual LAD coronary arteries into four types. Types I to III consist of a LADCA that divides into a shorter and a longer LADCA. These arteries are further differentiated by the course that the longer LADCA takes in relation to the interventricular septum in order to reach the apex. Type IV consists of a shorter LADCA originating in the left sinus of Valsalva and a longer LADCA arising from the right coronary artery [5]. In a recent large series involving 70,850 unselected patients, a Type IV LAD was noted only in 3 out of 171 (1.8%) of patients with major congenital coronary anomalies [7]. Our case patient is most consistent with a dual LADCA Type IV, as a longer LADCA arises from the anomalous right-sided LMCA, and a shorter LADCA emerges from the left coronary artery sinus and travels along the anterior proximal third of the interventricular septal wall.



(a) Demonstration of the course of the short LADCA on the anterior interventricular septum by curved multiplanar reconstruction (*black arrow*). Note that it terminates in the proximal third of the interventricular septum and does not give any branches. The heavily calcified LCX artery is seen coursing on the AV groove (*white arrow*)

(b) Anteroposterior projection of the hypoplastic LADCA arising from the left sinus of Valsalva (*arrow*)



(c) Three-dimensional reconstruction showing the short LADCA on the proximal third of the anterior interventricular sulcus (IVS) (*large white arrow*) and the LMCA emerging from the septum and dividing into the long LADCA which travels along the second and distal third of the IVS (*black arrow*) and left circumflex artery coursing in the atrioventricular groove (*short white arrow*)

FIGURE 2: Short LADCA (hypoplastic) arising from the left sinus of Valsalva by CTA and selective coronary angiography.

Routine coronary angiography may fail to demonstrate the longer LADCA, particularly if it arises from a separate ostium, and could lead to erroneous interpretation of a 100% mid-LADCA occlusion. In such cases, aortography in the left anterior oblique projection may help to visualize the origin of this anomalous blood vessel. In our case, the short hypoplastic LADCA supplies a very small myocardial territory and other than representing a very uncommon coronary anomaly likely confers minimal clinical relevance.

Anomalous LMCA arising from the right sinus of Valsalva is a rare coronary anomaly found in 0.0024% to 0.03% of the population [2, 4]. Depending on the anatomic relationship of the anomalous coronary artery to the aorta and the pulmonary trunk, the anomaly can be classified

into four common courses: the posterior or retroaortic, the interarterial or preaortic, the septal or subpulmonary, and the pre-pulmonic or anterior course [8, 9]. The interarterial course has been associated with sudden cardiac death, particularly during exercise in athletes [10–13]. Surgical correction is indicated if there is evidence of myocardial ischemia or a history of syncope [14]. The prepulmonic, subpulmonary, and retroaortic courses are generally asymptomatic.

CTA can be used to characterize with great accuracy the course of the anomalous coronary artery, especially when differentiating between the subpulmonary or interarterial course [9]. These variations are important to be recognized prior to certain cardiac surgeries as failure to do so may result in unintentional transection of the aberrant blood

vessel during the procedure. Accidental vascular compression of an anomalous LCXCA with prosthetic valvular rings has been reported during mitral and aortic valve replacements [15–17]. Informing the cardiothoracic surgeon along with defining the aberrant course may be lifesaving as special surgical considerations may be needed when performing such valvular procedures.

In summary, we report a combination of two rare congenital coronary anomalies, a dual LADCA Type IV, and an anomalous right-sided LMCA with a subpulmonary course. This anomalous coronary anatomy is unlikely to be associated with sudden cardiac death or ischemia. Interventional cardiologists and cardiothoracic surgeons should be aware of these coronary variations to assure correct angiography interpretations and avoidance of complications. To the best of our knowledge, the combined presence of both coronary anomalies has not been previously described.

## References

- [1] R. W. Alexander and G. C. Griffith, “Anomalies of the coronary arteries and their clinical significance,” *Circulation*, vol. 14, no. 5, pp. 800–805, 1956.
- [2] C. E. Wilkins, B. Betancourt, V. S. Mathur, et al., “Coronary artery anomalies. A review of more than 10,000 patients from the Clayton Cardiovascular Laboratories,” *Texas Heart Institute Journal*, vol. 15, no. 3, pp. 166–173, 1988.
- [3] E. D. Fernandes, H. Kadivar, G. L. Hallman, G. J. Reul, D. A. Ott, and D. A. Cooley, “Congenital malformations of the coronary arteries: the Texas Heart Institute experience,” *Annals of Thoracic Surgery*, vol. 54, no. 4, pp. 732–740, 1992.
- [4] W. Desmet, J. Vanhaecke, M. Vrolix, et al., “Isolated single coronary artery: a review of 50 000 consecutive coronary angiographies,” *European Heart Journal*, vol. 13, no. 12, pp. 1637–1640, 1992.
- [5] H. Spindola Franco, R. Grose, and N. Solomon, “Dual left anterior descending coronary artery: angiographic description of important variants and surgical implications,” *American Heart Journal*, vol. 105, no. 3, pp. 445–455, 1983.
- [6] O. Yamanaka and R. E. Hobbs, “Coronary artery anomalies in 126,595 patients undergoing coronary arteriography,” *Catheterization and Cardiovascular Diagnosis*, vol. 21, no. 1, pp. 28–40, 1990.
- [7] C. Tuncer, T. Batyraliev, R. Yilmaz, M. Gokce, B. Eryonucu, and S. Koroglu, “Origin and distribution anomalies of the left anterior descending artery in 70,850 adult patients: multicenter data collection,” *Catheterization and Cardiovascular Interventions*, vol. 68, no. 4, pp. 574–585, 2006.
- [8] W. C. Roberts and J. Shirani, “The four subtypes of anomalous origin of the left main coronary artery from the right aortic sinus (or from the right coronary artery),” *American Journal of Cardiology*, vol. 70, no. 1, pp. 119–121, 1992.
- [9] D. Ropers, G. Gehling, K. Pohle, et al., “Images in cardiovascular medicine. Anomalous course of the left main or left anterior descending coronary artery originating from the right sinus of Valsalva: identification of four common variations by electron beam tomography,” *Circulation*, vol. 105, no. 6, pp. e42–e43, 2002.
- [10] M. D. Cheitlin, C. M. De Castro, and H. A. McAllister, “Sudden death as a complication of anomalous left coronary origin from the anterior sinus of Valsalva. A not so minor congenital anomaly,” *Circulation*, vol. 50, no. 4, pp. 780–787, 1974.
- [11] A. J. Taylor, K. M. Rogan, and R. Virmani, “Sudden cardiac death associated with isolated congenital coronary artery anomalies,” *Journal of the American College of Cardiology*, vol. 20, no. 3, pp. 640–647, 1992.
- [12] A. J. Taylor, J. P. Byers, M. D. Cheitlin, and R. Virmani, “Anomalous right or left coronary artery from the contralateral coronary sinus: “high-risk” abnormalities in the initial coronary artery course and heterogeneous clinical outcomes,” *American Heart Journal*, vol. 133, no. 4, pp. 428–435, 1997.
- [13] C. Basso, B. J. Maron, D. Corrado, and G. Thiene, “Clinical profile of congenital coronary artery anomalies with origin from the wrong aortic sinus leading to sudden death in young competitive athletes,” *Journal of the American College of Cardiology*, vol. 35, no. 6, pp. 1493–1501, 2000.
- [14] J. Jagers and A. J. Lodge, “Surgical therapy for anomalous aortic origin of the coronary arteries,” *Seminars in Thoracic and Cardiovascular Surgery: Pediatric Cardiac Surgery Annual*, vol. 8, no. 1, pp. 122–127, 2005.
- [15] P. Mikaeloff, R. Loire, M. Amiel, et al., “Anomaly of the origin of the circumflex artery. Effects on the risk of mitral and mitro-aortic valve replacement,” *Archives des Maladies du Cœur et des Vaisseaux*, vol. 72, pp. 895–898, 1979.
- [16] J. P. Veinot, V. C. Acharya, and P. Bedard, “Compression of anomalous circumflex coronary artery by a prosthetic valve ring,” *Annals of Thoracic Surgery*, vol. 66, no. 6, pp. 2093–2094, 1998.
- [17] E. J. de Marchena, C. D. Russo, P. M. Wozniak, and K. M. Kessler, “Compression of an anomalous left circumflex coronary artery by a bioprosthetic valve ring,” *Journal of Cardiovascular Surgery*, vol. 31, no. 1, pp. 52–54, 1990.