

CORRECTION

Correction: Functional magnetic resonance: biomarkers of response in breast cancer

Elizabeth AM O'Flynn* and Nandita M deSouza

See related review by O'Flynn and deSouza, <http://breast-cancer-research.com/content/13/1/204>

Upon publication of our article [1], we noticed that the wrong image had been uploaded for Figure 6a. The figure as it should appear can be found below.

Competing interests

The authors declare that they have no competing interests.

Published: 30 June 2011

References

1. O'Flynn EA, Desouza NM: **Functional magnetic resonance: biomarkers of response in breast cancer.** *Breast Cancer Res* 2011, **13**:204.

doi:10.1186/bcr2910

Cite this article as: O'Flynn EAM, deSouza NM: Correction: Functional magnetic resonance: biomarkers of response in breast cancer. *Breast Cancer Research* 2011, **13**:405.

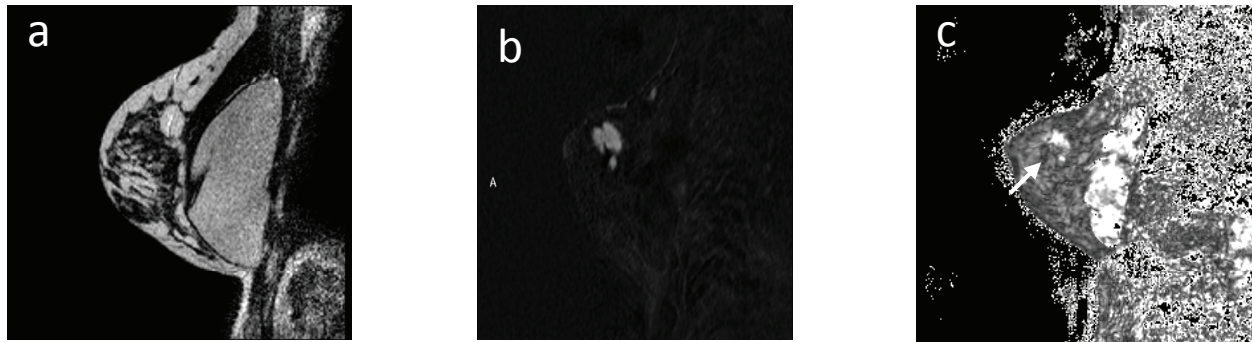


Figure 6. T₂*W images of a breast tumour. (a-c) Sagittal T₂W (a), dynamic contrast-enhanced (DCE) subtracted image at time point 2.44 minutes (b), and T₂*W image (c) in a patient with a palpable breast lump in the upper outer quadrant. The tumour seen in (a) and highlighted in (b) shows heterogeneity of T₂* with faster signal decay in the inferior part of the tumour, indicating a greater deoxyhaemoglobin content here.

*Correspondence: Elizabeth.OFlynn@icr.ac.uk
Clinical Magnetic Resonance Group, Institute of Cancer Research, Royal Marsden
NHS Foundation Trust, Sutton, Surrey, SM2 5PT, United Kingdom