

# Efficacy and safety of apatinib plus docetaxel as the second or above line treatment in advanced nonsquamous NSCLC

## A multi center prospective study

Qian Jiang, MM<sup>a</sup>, Ning-Ling Zhang, MB<sup>a</sup>, Dai-Yuan Ma, MD<sup>a,\*</sup>, Bang-Xian Tan, MM<sup>a</sup>, Xin Hu, MB<sup>b</sup>, Xiang-Dong Fang, MB<sup>c</sup>

### Abstract

**Background:** Apatinib is an oral small-molecule tyrosine kinase inhibitor targeting vascular endothelial growth factor receptor 2 (VEGFR-2). Some clinical trials have demonstrated that apatinib is efficacious against advanced nonsquamous NSCLC.

**Objective:** This study aimed to probe efficacy and safety of apatinib plus docetaxel, as the second or above line treatment, in advanced nonsquamous NSCLC.

**Design:** Multicenter, prospective, single arm study.

**Setting:** Three teaching hospitals centers in the Sichuan.

**Participants:** Fourteen patients with stage IVA/B nonsquamous NSCLC had previously received at least 1 platinum-based chemotherapy regimen.

**Intervention:** Patients who were enrolled between November 2016 and January 2018 were given docetaxel (75 mg/m<sup>2</sup>, i.v., d1) plus oral apatinib (250 mg/d), 4 weeks as one cycle, until disease progression or intolerance to adverse events (AE).

**Main outcome measures:** The primary endpoint was progression-free survival (PFS). The secondary endpoints comprised objective response rate (ORR), disease control rate (DCR), overall survival (OS), and AE incidence rate.

**Results:** All patients carried adenocarcinoma by pathological type. The median follow-up duration was 9.76 months. Out of 14 cases, 12 were evaluable, showing ORR of 33.33%, DCR of 66.67%, DCR of 50% in cases with brain metastasis, median PFS of 2.92 months (95% CI: 1.38–4.48), and 6-month OS of 80%. Primary AEs encompassed: leukopenia in 7 cases (58.33%), hand-foot skin reaction in 5 cases (41.67%), and diarrhea in 4 cases (33.33%). Among them, grade 3 AEs were: leukopenia in 4 cases (33.33%), and hand-foot skin reaction in 1 case (8.33%). No grade 4/5 AEs were reported. Univariate and multivariate analysis were conducted respectively for PFS and OS. These factors encompassed: gender, age, gene mutations, clinical stage, ECOG scores, quantity of metastatic foci, brain metastasis, and hand-foot skin reaction. Results demonstrated zero risk factors for PFS or OS.

**Conclusion:** Apatinib plus docetaxel, as the second or above line treatment, is effective and safe against advanced nonsquamous NSCLC, with good tolerance profile.

**Trial registration:** NCT03416231.

**Abbreviations:** AE = adverse events, ALT = blood alanine aminotransferase, ANC = neutrophil, AST = aspartate aminotransferase, BBB = blood brain barrier, CR = complete response, Cr = serum creatinine, DCR = disease control rate, HB = hemoglobin, LVEF = left ventricular ejection fraction, MDR = multidrug resistance, NSCLC = non-small cell lung cancer, ORR = objective response rate, PD = progressive disease, PLT = platelet, PR = partial response, SD = stable disease, TBIL = total bilirubin, VEGFR-2 = vascular endothelial growth factor receptor 2.

**Keywords:** apatinib, docetaxel, nonsquamous NSCLC, second or above line treatment

Editor: Eric Bush.

QJ and N-LZ were equally contributed to this work.

The authors have no conflicts of interests to disclose.

<sup>a</sup> Department of Oncology, Affiliated Hospital of North Sichuan Medical College, <sup>b</sup> Department of Oncology, Central Hospital of Nanchong, Nanchong, <sup>c</sup> Department of Oncology, Central Hospital of Dazhou, Dazhou, PR China.

\* Correspondence: Dai-Yuan Ma, Department of Oncology, Affiliated Hospital of North Sichuan Medical College, No. 63 Wenhua Road, Nanchong, Sichuan 637000, PR China (e-mail: mdyx@163.com).

Copyright © 2019 the Author(s). Published by Wolters Kluwer Health, Inc.

This is an open access article distributed under the terms of the Creative Commons Attribution-Non Commercial-No Derivatives License 4.0 (CCBY-NC-ND), where it is permissible to download and share the work provided it is properly cited. The work cannot be changed in any way or used commercially without permission from the journal.

Medicine (2019) 98:26(e16065)

Received: 17 October 2018 / Received in final form: 30 April 2019 / Accepted: 23 May 2019

<http://dx.doi.org/10.1097/MD.00000000000016065>

## 1. Introduction

Lung cancer is the main cause of cancer related death worldwide, severely endangering human health.<sup>[1]</sup> Non-small cell lung cancer (NSCLC) accounts for about 80% of lung cancer occurring in all patients,<sup>[2]</sup> which is mostly at the advanced stage upon diagnosis, with the median survival of less than 1 year.<sup>[3]</sup> Studies revealed the beneficial effect of chemotherapy and targeted therapy in a portion of NSCLC patients who experienced refractory first/second line treatment,<sup>[4–6]</sup> but there lacks a standard third-line therapy regimen.

According to published reports over the last 20 years, the epidermal growth factor receptor (EGFR) has played an important role in regulating survival and cell proliferation in different types of cancer.<sup>[7]</sup> As in NSCLC EGFR is often deregulated by mutations, gene amplification or overexpression,<sup>[8]</sup> its inhibition effect has drawn a lot of attraction from researchers as an attractive therapeutic target. EGFR-TKIs such as gefitinib, icotinib and erlotinib have made great progress in treating NSCLC in clinic. A summary from 6 papers has demonstrated that the effect of erlotinib in the treatment of advanced NSCLC patients is superior to docetaxel in the terms of PFS, OS, and toxicity.<sup>[9]</sup> Hirsch et al have indicated that a subset of long-term NSCLC survivors who were receiving gefitinib had an excellent long-term safety profile.<sup>[10]</sup> Moreover, combining icotinib and chemotherapy led to improved PFS and OS in patients with untreated NSCLC harboring sensitive EGFR mutations, especially in those who harbored the EGFR exon 19 deletion.<sup>[11]</sup> Apatinib, an oral small-molecule tyrosine kinase inhibitor, binds with high affinity to VEGF receptor-2, preventing VEGF binding and activation.<sup>[12,13]</sup> Even though apatinib has not been internationally approved yet for lung cancer treatment, some clinical studies have already displayed efficacy in advanced nonsquamous NSCLC.<sup>[14]</sup> The results of the clinical trial demonstrated that the use of apatinib alone or combined with chemotherapy exhibits a high response rate and favorable tolerability profile in patients with advanced or metastatic squamous cell lung carcinoma.<sup>[15]</sup> Thus, combining apatinib with docetaxel may be a promising therapeutic schedule in the treatment of advanced NSCLC.

In this study, we enrolled 14 cases of advanced nonsquamous NSCLC, who had received at least 1 refractory platinum-based regimen before. The safety and efficacy of apatinib in combination with docetaxel in these patients were evaluated in this research.

## 2. Patients and methods

### 2.1. Patient selection

Patients with advanced nonsquamous NSCLC were enrolled into this study, who were hospitalized into our department between November 2016 and January 2018. Those patients previously received at least 1 platinum-based regimen and the treatment failed.

Inclusion criteria were:

- (1) 18 to 78 years old;
- (2) pathologically diagnosed stage IV (AJCC, eighth edition) nonsquamous NSCLC was;
- (3) receipt of at least 1 prior platinum-based chemotherapy;
- (4) performance status (ECOG-PS) score of 0 to 3;
- (5) laboratory tests: hemoglobin (HB)  $\geq 90$  g/L, neutrophil (ANC)  $\geq 1.5 \times 10^9$ /L, platelet (PLT)  $\geq 80 \times 10^9$ /L, total

bilirubin (TBIL)  $< 1.5$  ULN (upper limit of normal value), blood alanine aminotransferase (ALT)/aspartate aminotransferase (AST)  $< 2.5$  ULN ( $< 5$  ULN for patients with liver metastasis), serum creatinine (Cr)  $\leq 1.25$  ULN or endogenous creatinine clearance rate  $> 45$  mL/min.

Patients were excluded from current study, if they:

- (1) currently had uncontrollable hypertension (even upon the optimal medications, systolic pressure was  $\geq 140$  mmHg or diastolic pressure  $\geq 90$  mmHg);
- (2) had myocardial infarction or uncontrolled arrhythmia;
- (3) had grade III/IV (NYHA) heart failure or left ventricular ejection fraction (LVEF)  $< 50\%$  under color doppler echocardiography;
- (4) had coagulation dysfunction (INR  $> 1.5$  or prothrombin time (PT)  $> \text{ULN} + 4$  seconds or APTT  $> 1.5$  ULN), or had bleeding tendency, or received medications of thrombolysis or anticoagulation;
- (5) had active bleeding, gastrointestinal ulcer, intestinal perforation, intestinal obstruction, or within 30 days following major surgery.

All study subjects voluntarily participated in this trial, signed the informed consent, and complied with follow-up process. This work was approved by the Ethics Committee of Affiliated Hospital of North Sichuan Medical College. Clinical trial number: NCT03416231.

### 2.2. Treatment protocol

Docetaxel ( $75 \text{ mg/m}^2$ , i.v., d1) plus oral apatinib ( $250 \text{ mg/d}$ ) were administered to patients, 4 weeks as one cycle, until disease progression or occurrence of intolerable adverse events (AEs).

### 2.3. Patients evaluation

This was a multi-center, prospective, noncomparative study to determine whether apatinib administered in combination with docetaxel played a vital in patients with advanced NSCLC after first- or second-line chemotherapy failure. Efficacy assessment was conducted every 2 cycles. According to Response Evaluation Criteria in Solid Tumors (RECIST) Version 1.1, it was defined as complete response (CR), partial response (PR), stable disease (SD), or progressive disease (PD). Objective response rate (ORR) referred to the proportion of CR+PR cases in evaluable patients. Disease control rate (DCR) referred to the proportion of CR+PR+SD in evaluable patients. AEs were monitored and recorded during trial, and classified into grade 1 to 5 according to Common Terminology Criteria for Adverse Events (CTCAE) Version 4.0.

### 2.4. Follow-up visit

Every patient was regularly followed-up by scheduled protocol in our institution. All patients were informed the AEs, physical examination, and laboratory tests including hepatorenal function, blood routine, and urine routine every 2 weeks by a thorough inquiry. Since starting therapy, follow-up by phone call or clinic consultation was conducted at least once per month to collect information on survival status, AEs, and subsequent treatment after disease progression. It was lasted until death or patient dropping-out or the end of the study. The detailed

information of survival status from each follow-up was documented in the follow-up form. Progression free survival (PFS) referred to the time interval between therapy start and first onset of disease progression or death caused by any reason (whichever occurred first). Overall survival (OS) referred to the time interval between therapy start and death caused by any reason. The cut-off date for follow-up study was December 28, 2017, and the median follow-up duration was 9.76 months.

## 2.5. Statistical analysis

Kaplan–Meier method was adopted for survival analysis, and statistical software SAS9.2 was used for programming and computing. Two-tailed test was applied, with  $P < .05$  designated as statistical significance, and 95% confidence interval (CI) was applied. A Cox proportional hazards model was adopted to analyze risk factors for PFS and OS. Chi-square test was used to detect DCR and ORR. Descriptive statistics was adopted for analysis of safety assessment, and AEs taking place during trial were described in the table.

## 3. Results

### 3.1. General information of patients

Fourteen cases of advanced nonsquamous NSCLC were enrolled into this study who were hospitalized into our department between November 2016 and January 2018. For 2 patients failed to make a return visit, only 12 patients were evaluable. These patients included 4 males and 8 females, at the age range of 36 to 76 years (median age of 50 years). The pathological type in all cases was adenocarcinoma, 11 cases harboring wild-type *EGFR* while 1 case with mutated *EGFR* (exon 20 insertion mutation). 4 cases were at stage IVA while 8 cases at stage IVB. ECOG analysis displayed score 1 in 9 cases while score 2 in 2 cases and score 3 in 1 case. 5 cases had no more than 2 metastatic foci while 7 cases with more than 2 metastatic foci, in whom 2 cases harbored brain metastasis while 10 cases without. Eight patients have pleural effusion. Treatment histories were: 2 cases with brain metastasis previously received head radiotherapy, and 3 cases previously received lung radiotherapy, and 2 cases previously received analgesic radiotherapy for bone metastasis. As shown in Table 1, regimen of apatinib plus docetaxel was second line treatment in 3 cases while third line treatment in 5 cases and fourth line treatment in 4 cases.

### 3.2. Treatment effectiveness

In all enrolled cases, 12 were evaluable. Efficacy in 12 cases were: CR in 0 case, PR in 4 cases, SD in 4 cases, PD in 4 cases; ORR of 33.33%, DCR of 66.67%, DCR of 50% in cases with brain metastasis; median PFS of 2.92 months (95% CI: 1.38–4.48) (Fig. 1); 6-month OS of 80% (Fig. 2).

**3.2.1. Safety assessment.** As shown in Table 2, AEs encompassed: leukopenia in 7 cases (58.33%), hand-foot skin reaction in 5 cases (41.67%), diarrhea in 4 cases (33.33%), vomiting in 4 cases (33.33%), proteinuria in 3 cases (25%), and hypertension in 2 cases (16.67%). Among them, grade 3 AEs were: leukopenia in 4 cases (33.33%), hand-foot skin reaction in 1 case (8.33%). No grade 4/5 AEs occurred. After symptomatic management, all patients showed tolerance, without drug reduction or withdrawal due to intolerance (Table 3).

**Table 1**

#### Patients information.

Age	
Median age (range)	50 (36–76)
Gender	
Male	4 (33.3%)
Female	8 (66.7%)
ECOG	
1	9 (75.0%)
2	2 (16.7%)
3	1 (8.3%)
Clinical stages	
IVA	4 (33.3%)
IVB	8 (66.7%)
Pathologic types	
adenocarcinoma	12 (100.0%)
Mutation of EGFR	
Yes	1 (8.3%)
No	11 (91.7%)
Metastasis	
≤2	5 (41.7%)
>2	7 (58.3%)
Smoking	
Yes	5 (41.7%)
No	7 (58.3%)
Pleural effusion	
Yes	8 (66.67%)
No	4 (33.33%)
Brain metastasis	
Yes	2 (16.7%)
No	1 (83.3%)
Treatment line	
Second-line treatment	3 (25.0%)
Third-line treatment	5 (41.7%)
Fourth-line treatment	4 (33.3%)

**3.2.2. Risk factor analysis.** Univariate and multivariate analysis were conducted for PFS. These factors encompassed: gender, age, gene mutations, clinical stage, ECOG scores, quantity of metastatic foci, brain metastasis, and hand-foot skin reaction. Results demonstrated zero risk factors for PFS (Table 4). However, hand-foot skin reaction was positive related to the DCR of the enrolled patients (Table 5).

## 4. Discussion

At present, platinum-based dual drug regimen is the standard chemotherapy for NSCLC, and targeted therapy can improve survival in patients who harbor mutations of sensitive genes, such as epidermal growth factor receptor (*EGFR*).<sup>[16,17]</sup> However, there lacks determined therapy regimen for advanced NSCLC patients who have experienced refractory first/second line chemotherapy, peculiarly those carrying no mutations of sensitive genes. Therefore, researchers launch clinical studies targeting those patients, including our study reported here.

In a multicenter randomized and controlled trial reported by Shepherd and colleagues,<sup>[18]</sup> 204 patients with stage III/IV NSCLC, who had previously received at least 1 regimen of platinum-based chemotherapy, were randomized to single docetaxel 100 mg/m<sup>2</sup> group (49 cases), single docetaxel 75 mg/m<sup>2</sup> group (55 cases), and optimal support treatment group (100 cases). Results demonstrated: single docetaxel was superior over

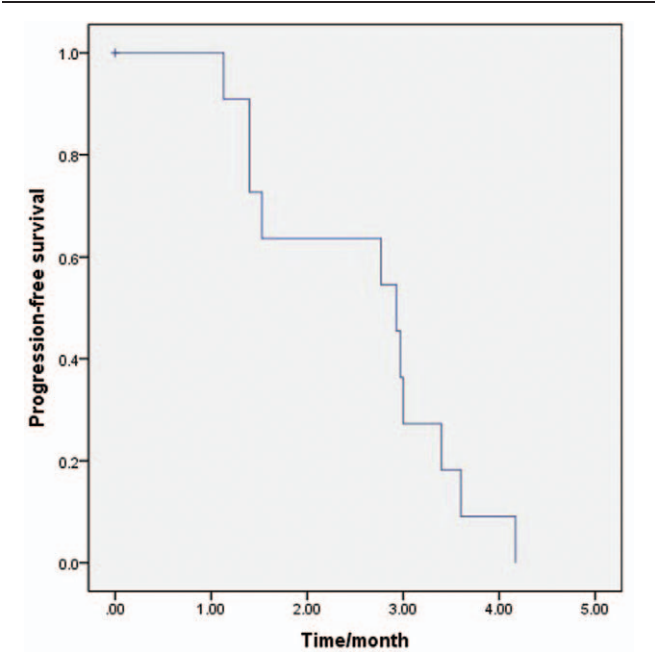


Figure 1. Kaplan–Meier estimates the progression-free survival.

the optimal support treatment in time to progression (TTP) and in median OS, respectively 10.6 weeks vs 6.7 weeks ( $P<.001$ ) and 7.0 months vs 4.6 months ( $P=.047$  by long-rank test). Notably, docetaxel 75 mg/m<sup>2</sup> was markedly superior to the optimal support treatment, reflected by median OS of 7.5 months vs 4.6 months ( $P=.010$  by long-rank test) and 1-year OS of 37% vs 11% ( $P=.003$  by Chi-square test). The primary AEs in docetaxel 75 mg/m<sup>2</sup> group included grade 3/4 leukopenia (37 cases, 67.27%) and diarrhea (20 cases, 36.36%). For these reasons, the dose (75 mg/m<sup>2</sup>) of docetaxel were selected in our study.

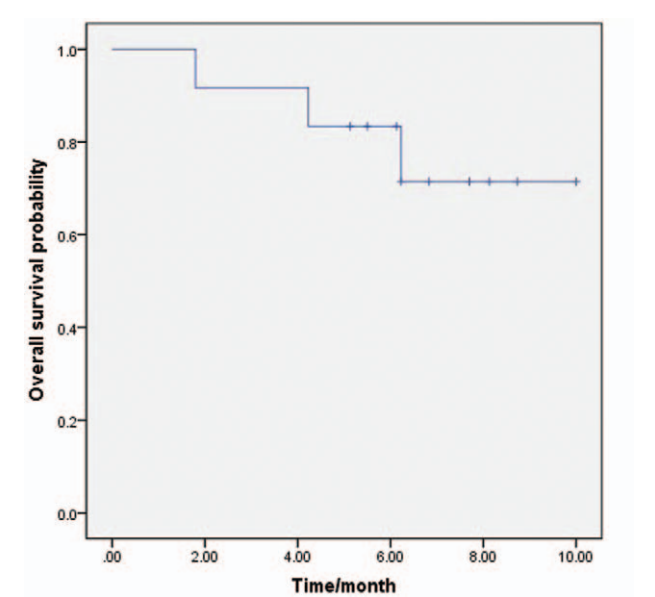


Figure 2. Kaplan–Meier estimates the overall survival.

Table 2			
Adverse event.			
Adverse event	Total percentage	Level (1–2)	Level (3)
Leukopenia	58.33%	3 (25%)	4 (33.33%)
Hand-foot skin reaction	41.67%	4 (33.33%)	1 (8.33%)
Diarrhea	33.33%	4 (33.33%)	
Emesis	33.33%	4 (33.33%)	
Proteinuria	25%	3 (25%)	
Hypertension	16.67%	2 (16.67%)	

Song et al<sup>[19]</sup> launched a study on apatinib third/fourth line treatment for advanced NSCLC. 42 patients were enrolled into this study, who received oral apatinib mesylate tablets, 28 days as a cycle, and the median follow-up duration was 12.5 months (3.0–23 months). Results demonstrated: ORR of 9.5%, DCR of 61.9%; median PFS of 4.2 months (95%CI: 1.0–9.5), median OS of 6.0 months (95%CI: 3.9–8.0). No grade 4 or above AEs were observed during trial. The primary grade 3/4 AEs included: hand-foot skin reaction (6 cases, 14.29%), hypertension (4 cases, 9.52%), proteinuria (3 cases, 7.14%), liver damage (3 cases, 7.14%), fatigue (2 cases, 4.76%), nausea and vomiting (2 cases, 4.76%).

Compared with above 2 trials, our study presented higher ORR (33.33%) and DCR (66.67%). Even though median OS was not available yet, 6-month OS was 80%, implying a trend of longer OS in apatinib plus docetaxel regimen. We speculate it might relate to the antitumor performance of both drugs. Angiogenesis is the key element for malignant tumor growth, and sustained angiogenesis closely associates with tumor initiation/development/metastasis.<sup>[20,21]</sup> According to reference, over 50% of lung cancer had VEGF overexpression, which was correlated

Table 3		
Clinical characteristics of the study population (n = 12).		
Variables	Numbers	Percentage (%)
Gender		
Male	4	33.3
Female	8	66.7
PS		
0–1	9	75.0
≥2	3	25.0
Age, years		
≤50	7	58.3
>50	5	41.7
EGFR mutation		
Yes	1	8.33
No	11	91.7
Line of apatinib therapy		
≤third line	7	58.3
>third line	5	41.7
Number of metastases		
≤2	5	41.7
>2	7	58.3
Evaluation at 2 cycles		
Yes	8	66.7
No	4	33.3
Brain metastases		
Yes	2	16.7
No	10	83.3

**Table 4****Univariate analysis of PFS.**

	PFS	95%CI	P value
Gender			.99
Male	2.93	0.5–5.4	
Female	2.77	0.8–4.8	
PS			.35
0–1	2.93	2.7–3.2	
≥2	1.4	1.0–1.8	
Age, years			.77
≤50	1.53	0.2–3.2	
>50	2.97	2.9–3.1	
EGFR mutation			.33
Yes	1.53	NA	
No	2.93	2.6–3.2	
Line of apatinib therapy			.45
≤third line	2.93	0.1–6.9	
>third line	2.77	1.3–4.2	
Number of metastases			.45
≤2	1.4	0.1–3.0	
>2	2.97	2.9–3.1	
Evaluation at 2 cycles			.13
Yes	3	2.9–3.1	
No	1.4	NA	
Pleural effusion			.037
Yes	3.36	1.8–3.3	
No	2.850	1.4–5.1	
Brain metastases			.71
Yes	1.53	NA	
No	2.93	2.46–3.4	

with poor outcome.<sup>[22,23]</sup> Apatinib could highly selectively compete for the ATP-binding site of intracellular VEGFR-2 and block its downstream signal transduction, thereby playing an antitumor part via robust inhibition of tumor angiogenesis.<sup>[24,25]</sup> In addition, apatinib can reverse multidrug resistance (MDR) of tumor cells mediated by multidrug transporter protein ABCB1 (p-glycoprotein) via suppressing its activity in pumping out chemotherapy drugs, hence improving chemotherapy efficacy.<sup>[26,27]</sup> This promotive effect of apatinib on chemotherapy efficacy was also revealed by drug kinetics in a NSCLC mouse model. Interestingly, a study from Wang et al<sup>[28]</sup> displayed disparity to the therapeutic time window shown in other anti-angiogenesis agents: the efficacy of synchronous apatinib with chemotherapy drugs was superior over the one in sequential administration. Data of our study as well favors the treatment modality of apatinib plus chemotherapy. Nonetheless, the specific antitumor mechanism underpinning combinatory therapy remains to be elucidated, and further exploration is needed to delineate the dose and frequency of combinatory drugs.

Median PFS in our study was 2.92 months, shorter than the counterpart from above trial of single apatinib medication. It is worth noting that 2 trials showed divergence in enrolled patients' conditions and in medication methods. In our study, all patients were at stage IV and harbored multiple metastasis, involving important organs of the brain, lung, and liver; disease progressed even after multi line treatment; most patients carried wild-type *EGFR*, which imposed limitation on treatment options. Many researches have indicated that apatinib or other anti-angiogenic drugs combined with *EGFR*-TKI are effective in the treatment of NSCLC with sensitive gene mutations.<sup>[29,30]</sup> In this study, 11/12 (91.7%) patients have no *EGFR* mutation and did not receive

**Table 5****Chi-square test of ORR, DCR.**

	ORR	χ <sup>2</sup>	P value	DCR	χ <sup>2</sup>	P value
Gender		0.75	.386		0.188	.665
Male	50%			75%		
Female	25%			62.50%		
PS		2	.157		0	1
0–1	44.44%			66.67%		
≥2	0%			66.67%		
Age, years		0.171	.679		0.686	.408
≤50	28.57%			57.14%		
>50	40%			80.00%		
EGFR mutation		0.545	0.46		2.182	0.14
Yes	0%			0.00%		
No	36.36%			72.73%		
Pleural effusion		0.75	0.386		3	0.083
Yes	25%			50.00%		
No	50%			100.00%		
Line of apatinib therapy		0.188	0.665		0.75	0.386
≤Third line	37.50%			75.00%		
>Third line	25%			50.00%		
Number of metastases		0.171	0.679		0.171	0.679
≤2	40.00%			60.00%		
>2	28.57%			71.43%		
Brain metastases		0.3	0.584		0.3	0.584
Yes	50%			50.00%		
No	30%			70.00%		
Smoking		0.171	.679		0.686	.408
Yes	40%			80.00%		
No	29%			57.14%		
Staging		0.75	0.368		0.188	.665
IVA	0.5			75.00%		
IVB	0.25			62.50%		
Hand-foot skin reaction		2.743	0.098		4.286	0.038
Yes	60%			100%		
No	14%			42.86%		
Leukopenia		3	0.083		0.75	0.386
≥grade 3	100%			50.00%		
<grade 3	50%			25.00%		

*EGFR*-TKI therapy. However, in the research of Zhengbo Song, patients harboring *EGFR* mutation take a proportion of 16.7%. Besides that, the pathological types of the patients were all adenocarcinoma in our study, which was different from patients consisted of 30/42 (71.4%) adenocarcinoma in Zhengbo Song study. Furthermore, the dose of apatinib (250 mg) in this research is lighter than Zhengbo Song research (500 mg). In these regards, survival duration was estimated to be short.

Overall drug tolerance in our study is good. Primary AE encompassed: leukopenia in 7 cases (58.33%), hand-foot skin reaction in 5 cases (41.67%), diarrhea in 4 cases (33.33%), vomiting in 4 cases (33.33%), proteinuria in 3 cases (25%), and hypertension in 2 cases (16.67%). Among them, grade 3 AEs were: leukopenia in 4 cases (33.33%), hand-foot skin reaction in 1 case (8.33%). No grade 4/5 AEs were reported. In a randomized, double-blind, controlled phase III trial,<sup>[31]</sup> 176 patients with advanced gastric cancer and gastroesophageal junction cancer were treated with apatinib 850 mg qd monotherapy. Grade 3 to 4 AEs mainly included: leukopenia in 3 cases



**Table 6****Clinical characteristics and grade 3 or above hand-foot skin reaction.**

	Percentage	$\chi^2$	P value
Gender		2.182	.140
Male	25.00%		
Female	0.00%		
PS		0.364	.546
0–1	11.11%		
≥2	0.00%		
Age		1.527	.217
≤50	0.00%		
>50	20.00%		
EGFR mutation		0.099	.753
Yes	0.00%		
No	9.09%		
Line of apatinib therapy	0.545	0.460	
≤Third line	12.50%		
>Third line	0.00%		
Number of metastases	1.527	0.217	
≤2	20.00%		
>2	0.00%		
Brain metastases	0.218	0.640	
Yes	0.00%		
No	10.00%		
Pleural effusion	0.545	0.460	
Yes	12.50%		
No	0.00%		
Smoking		1.527	.217
Yes	20.00%		
No	0.00%		
Staging		2.182	.140
IVA	25.00%		
IVB	0.00%		

(1.7%), hand and foot skin reaction in 15 cases (8.5%), diarrhea in 2 cases (1.1%), proteinuria in 4 cases (2.3%), and hypertension in 8 cases (4.5%). Compared with the above results, except for the increase of leukopenia, the occurrence of other grade 3 to 4 AEs in this study was reduced. The reason may be that in this study, lower apatinib dosage reduced the occurrence of AEs, but chemotherapy increased the number of hematological AEs. Liu et al<sup>[32]</sup> have found that in patients with advanced gastric cancer treated with apatinib alone, AEs such as hypertension, hand and foot skin reaction and proteinuria were good predictors of efficacy. In this study, the efficacy of patients with severe AEs was not better than those who have no severe AEs (Table 5). It may be because docetaxel was combined with low dosage of apatinib in our experiment. This research indicated that serious AEs (foot-hand skin reaction and leukopenia) was not related to patients' age, PS score and number of treatment lines (Tables 6 and 7). This scenario is similar to results of above-mentioned trials: combinatory drugs presented no increase in AE severity or categories. Grade 3/4 AE incidence was low, and all patients showed tolerance after symptomatic management. Therefore, it is rational to encourage further exploration on the feasibility of increased apatinib dose for boosting the therapeutic effectiveness of combinatory therapy.

Univariate and multivariate analysis were conducted respectively for PFS and OS. These factors encompassed: gender, age, gene mutations, clinical stage, ECOG scores, quantity of metastatic foci, brain metastatic, and hand-foot skin reaction.

**Table 7****Clinical characteristics and grade 3 or above leukopenia.**

	Percentage	$\chi^2$	P value
Gender		0.750	.386
Male	50.00%		
Female	25.00%		
PS		0.000	1.000
0–1	33.33%		
≥2	33.33%		
Age		0.171	.679
≤50	28.57%		
>50	40.00%		
EGFR mutation		0.545	.460
Yes	0.00%		
No	36.36%		
Line of apatinib therapy	0.188	0.665	
≤Third line	37.50%		
>Third line	25.00%		
Number of metastases	2.743	0.098	
≤2	60.00%		
>2	14.29%		
Brain metastases	0.300	0.584	
Yes	50.00%		
No	30.00%		
Pleural effusion	0.188	0.665	
Yes	37.50%		
No	25.00%		
Smoking		2.743	.098
Yes	60.00%		
No	14.29%		
Staging		0.188	.665
IVA	25.00%		
IVB	37.50%		

Results displayed zero risk factors for PFS or OS. Noticeably, conditions of 2 cases with brain metastasis were: cerebral lesion size reduced in one case (PR); in the other case, the original cerebral lesion stabilized while new lesion emerged (PD). It is consistent with the change trend observed in single apatinib medication for NSCLC by Xu et al<sup>[33]</sup>: in 7 cases of brain metastasis, 1 case had a reduction in cerebral lesion while 3 cases with stable cerebral lesions (head radiotherapy effect could not be excluded). In another clinical trial without adoption of radiotherapy, apatinib plus irinotecan demonstrated effectiveness in malignant glioma relapsing after chemotherapy.<sup>[34]</sup> Our study as well suggests apatinib could control cerebral lesions, that probably attributes to this small-molecule tyrosine kinase inhibitor penetrating through the blood brain barrier (BBB) and suppressing tumor. Given those 2 patients of our study had previously received head radiotherapy, and radiotherapy is known to inhibit tumor and alter BBB permeability,<sup>[35]</sup> further study is still required to illustrate the inhibitory effect of apatinib on brain metastasis.

In summary, our study preliminarily demonstrated the therapeutic effectiveness of apatinib plus docetaxel, as the second or above line treatment, in advanced nonsquamous NSCLC, and displayed good tolerance of patients. It could be an alternative multi line treatment option for patients harboring wild-type *EGFR* or brain metastasis. Based on these results, prospective randomized and controlled trials are expected to further validate the effectiveness and safety of combinatory drugs, and to

gradually explore the optimal modes of combinatory medications.

## Acknowledgments

The authors thank everyone at our institution who helped in this study.

## Author contributions

**Conceptualization:** Dai-Yuan Ma.

**Data curation:** Qian Jiang.

**Formal analysis:** Ning-Ling Zhang.

**Investigation:** Bang-Xian Tan.

**Methodology:** Xin Hu.

**Project administration:** Xiang-Dong Fang.

**Software:** Qian Jiang.

**Supervision:** Dai-Yuan, Ma.

**Writing – original draft:** Qian Jiang.

**Writing – review & editing:** Qian Jiang.

## References

- [1] Chen W. Cancer statistics: updated cancer burden in China. *Chin J Cancer Res* 2015;27:1.
- [2] Ke EE, Zhou Q, Wu YL. Emerging paradigms in targeted treatments for Asian patients with NSCLC. *Expert Opin Pharmacother* 2015;16:1167–76.
- [3] Soda M, Choi YL, Enomoto M, et al. Identification of the transforming EML4-ALK fusion gene in non-small-cell lung cancer. *Nature* 2007;448:561–6.
- [4] Song Z, Yu Y, Chen Z, et al. Third-line therapy for advanced non-small-cell lung cancer patients: feasible drugs for feasible patients. *Med Oncol* 2011;28(Suppl 1):S605–612.
- [5] Girard N, Jacoulet P, Gaiet M, et al. Third-line chemotherapy in advanced non-small cell lung cancer: identifying the candidates for routine practice. *J Thorac Oncol* 2009;4:1544–9.
- [6] Song Z, Zhang Y. Retreatment with pemetrexed chemotherapy in advanced non-small cell lung cancer patient. *J Thorac Dis* 2014;6:856–60.
- [7] Grandis JR, Sok JC. Signaling through the epidermal growth factor receptor during the development of malignancy. *Pharmacol Ther* 2004;102:37–46.
- [8] Hirsch FR, Varella-Garcia M, Bunn PA Jr, et al. Molecular predictors of outcome with gefitinib in a phase III placebo-controlled study in advanced non-small-cell lung cancer. *J Clin Oncol* 2006;24:5034–42.
- [9] Xu W, Jin C, Dai X, et al. A meta-analysis of erlotinib versus docetaxel for advanced nonsmall-cell lung cancer with poor prognosis. *Indian J Cancer* 2015;52(Suppl 1):e12–16.
- [10] Hirsch FR, Sequist LV, Gore I, et al. Long-term safety and survival with gefitinib in select patients with advanced non-small cell lung cancer: results from the US IRESSA Clinical Access Program (ICAP). *Cancer* 2018;124:2407–14.
- [11] Wang L, Li Y, Li L, et al. The effect of icotinib combined with chemotherapy in untreated non-small-cell lung cancer that harbored EGFR-sensitive mutations in a real-life setting: a retrospective analysis. *Onco Targets Ther* 2018;11:2345–53.
- [12] Xie L, Guo W, Wang Y, et al. Apatinib for advanced sarcoma: results from multiple institutions' off-label use in China. *BMC Cancer* 2018;18:396.
- [13] Yang C, Feng W, Wu D. Apatinib for advanced nonsmall-cell lung cancer: a retrospective case series analysis. *J Cancer Res Ther* 2018;14:159–62.
- [14] Wu D, Liang L, Nie L, et al. Efficacy, safety and predictive indicators of apatinib after multilines treatment in advanced nonsquamous nonsmall cell lung cancer: apatinib treatment in nonsquamous NSCLC. *Asia Pac J Clin Oncol* 2018;14:446–52.
- [15] Li X, Le L, Han L, et al. Short-term efficacy and safety of apatinib in advanced squamous cell carcinoma of the lung. *Indian J Cancer* 2017;54:547–9.
- [16] Zhou C, Wu YL, Chen G, et al. Erlotinib versus chemotherapy as first-line treatment for patients with advanced EGFR mutation-positive non-small-cell lung cancer (OPTIMAL, CTONG-0802): a multicentre, open-label, randomised, phase 3 study. *Lancet Oncol* 2011;12:735–42.
- [17] Inoue A, Kobayashi K, Usui K, et al. First-line gefitinib for patients with advanced non-small-cell lung cancer harboring epidermal growth factor receptor mutations without indication for chemotherapy. *J Clin Oncol* 2009;27:1394–400.
- [18] Shepherd FA, Dancey J, Ramlau R, et al. Prospective randomized trial of docetaxel versus best supportive care in patients with non-small-cell lung cancer previously treated with platinum-based chemotherapy. *J Clin Oncol* 2000;18:2095–103.
- [19] Song Z, Yu X, Lou G, et al. Salvage treatment with apatinib for advanced non-small-cell lung cancer. *Onco Targets Ther* 2017;10:1821–5.
- [20] Kim KJ, Li B, Winer J, et al. Inhibition of vascular endothelial growth factor-induced angiogenesis suppresses tumour growth in vivo. *Nature* 1993;362:841–4.
- [21] Sammarco G, Gadaleta CD, Zuccala V, et al. Tumor-associated macrophages and mast cells positive to tryptase are correlated with angiogenesis in surgically-treated gastric cancer patients. *Int J Mol Sci* 2018;19.
- [22] Bremnes RM, Camps C, Sirera R. Angiogenesis in non-small cell lung cancer: the prognostic impact of neoangiogenesis and the cytokines VEGF and bFGF in tumours and blood. *Lung Cancer* 2006;51:143–58.
- [23] Deng Y, Yang Y, Yao B, et al. Paracrine signaling by VEGF-C promotes non-small cell lung cancer cell metastasis via recruitment of tumor-associated macrophages. *Exp Cell Res* 2018;364:208–16.
- [24] Tian S, Quan H, Xie C, et al. YN968D1 is a novel and selective inhibitor of vascular endothelial growth factor receptor-2 tyrosine kinase with potent activity in vitro and in vivo. *Cancer Sci* 2011;102:1374–80.
- [25] Zhang Y, Chen Y, Zhang D, et al. Discovery of novel potent VEGFR-2 inhibitors exerting significant antiproliferative activity against cancer cell lines. *J Med Chem* 2018;61:140–57.
- [26] Tong XZ, Wang F, Liang S, et al. Apatinib (YN968D1) enhances the efficacy of conventional chemotherapeutic drugs in side population cells and ABCB1-overexpressing leukemia cells. *Biochem Pharmacol* 2012;83:586–97.
- [27] Mi YJ, Liang YJ, Huang HB, et al. Apatinib (YN968D1) reverses multidrug resistance by inhibiting the efflux function of multiple ATP-binding cassette transporters. *Cancer Res* 2010;70:7981–91.
- [28] Wang Y, Fan J, Fu S, et al. Experiment of different administration sequences of apatinib and paclitaxel on lung cancer. *Cancer Res Prev Treat* 2016;560–5.
- [29] Seto T, Kato T, Nishio M, et al. Erlotinib alone or with bevacizumab as first-line therapy in patients with advanced non-squamous non-small-cell lung cancer harbouring EGFR mutations (JO25567): an open-label, randomised, multicentre, phase 2 study. *Lancet Oncol* 2014;15:1236–44.
- [30] Li F, Zhu T, Cao B, et al. Apatinib enhances antitumour activity of EGFR-TKIs in non-small cell lung cancer with EGFR-TKI resistance. *Eur J Cancer* 2017;84:184–92.
- [31] Li J, Qin S, Xu J, et al. Randomized, double-blind, placebo-controlled phase iii trial of apatinib in patients with chemotherapy-refractory advanced or metastatic adenocarcinoma of the stomach or gastroesophageal junction. *J Clin Oncol* 2016;34:1448–54.
- [32] Liu X, Qin S, Wang Z, et al. Early presence of anti-angiogenesis-related adverse events as a potential biomarker of antitumor efficacy in metastatic gastric cancer patients treated with apatinib: a cohort study. *J Hematol Oncol* 2017;10:153.
- [33] Xu J, Liu X, Yang S, et al. Clinical response to apatinib monotherapy in advanced non-small cell lung cancer. *Asia Pac J Clin Oncol* 2018;14:264–9.
- [34] Wang L, Liang L, Yang T, et al. A pilot clinical study of apatinib plus irinotecan in patients with recurrent high-grade glioma: Clinical Trial/Experimental Study. *Medicine (Baltimore)* 2017;96:e9053.
- [35] Jin X, Liang B, Chen Z, et al. The dynamic changes of capillary permeability and upregulation of VEGF in rats following radiation-induced brain injury. *Microcirculation* 2014;21:171–7.