

## ORIGINAL RESEARCH

# Efficacy of calcipotriol plus betamethasone dipropionate foam on psoriatic skin lesions beyond human eyes: An observational study

Campanati Anna<sup>1</sup> | Marani Andrea<sup>1</sup> | Giannoni Melania<sup>1</sup> | Orciani Monia<sup>2</sup> |  
Fabiani Francesco<sup>3</sup> | Napolitano Rachele<sup>3</sup>  | Arnesano Marco<sup>4</sup> |  
Tomasini Enrico Primo<sup>3</sup> | Offidani Annamaria<sup>1</sup>

<sup>1</sup>Department of Clinical and Molecular Sciences - Dermatological Clinic, Polytechnic Marche University, Ancona, Italy

<sup>2</sup>Department of Clinical and Molecular Sciences - Histology Section, Polytechnic Marche University, Ancona, Italy

<sup>3</sup>Department of Industrial Engineering and Mathematical Sciences, Polytechnic Marche University, Ancona, Italy

<sup>4</sup>Dr. Arnesano Marco Università Telematica eCAMPUS, Novedrate (CO), Italy

## Correspondence

Marani Andrea, Dermatology Unit, United Hospital of Ancona, Ancona, Italy.  
Email: andreamarani.med@yahoo.com

## Abstract

**Background and Aims:** Calcipotriol plus betamethasone dipropionate foam has been developed as a new topical therapeutic option for psoriasis, whose effect has been documented mainly on clinical basis.

**Methods:** We decided to evaluate its efficacy on 11 patients, not only at the clinical level (by using Psoriasis Area Severity Index [PASI], Dermatology Life Quality Index [DLQI], and Psoriasis Global Assessment [PGA] clinimetric indexes) but especially from a subclinical viewpoint (by using videocapillaroscopy and thermography).

**Results:** After 4 weeks of treatment with calcipotriol plus betamethasone dipropionate foam, there was a marked reduction in all three clinimetric indexes PASI, PGA, and DLQI (DLQI mean value decreased from  $13.45 \pm 3.59$  to  $6.82 \pm 3.31$  ( $p = 0.001$ ), PASI from  $7.909 \pm 2.857$  to  $4.582 \pm 2.422$  ( $p = 0.001$ ), PGA from  $1.8 \pm 0.6$  to  $0.7 \pm 0.4$  ( $p = 0.002$ ). From thermographic survey, a significant reduction of mean value of  $\Delta T$  (temperature difference [°C] between center of the lesions and their periphery [healthy skin]), from  $0.28 \pm 0.99$  to  $-0.42 \pm 0.39$  ( $p = 0.058$ ), was observed. An exceptional reduction of capillaries of psoriatic plaques was detected through videocapillaroscopy (capillary density decreased from  $27.91 \pm 6.70$  capillaries/mm<sup>2</sup> to  $4.54 \pm 2.77$  capillaries/mm<sup>2</sup> ( $p = 0.001$ ), with an 83.73% reduction).

**Conclusion:** Our results demonstrate both clinical and subclinical efficacy of calcipotriol plus betamethasone dipropionate foam on psoriatic skin lesions. The subclinical improvement detected, not only demonstrates that the therapeutic effect of foam is truly due to a decrease in inflammation, but, being earlier and more effectively detectable than clinical benefit, suggests future applications of thermography and videocapillaroscopy in evaluating the in vivo effect of therapies for psoriasis, and, in general, the course of the disease “beyond human eyes.”

Campanati Anna and Marani Andrea contributed equally to this manuscript.

This is an open access article under the terms of the Creative Commons Attribution-NonCommercial-NoDerivs License, which permits use and distribution in any medium, provided the original work is properly cited, the use is non-commercial and no modifications or adaptations are made.

© 2022 The Authors. *Health Science Reports* published by Wiley Periodicals LLC.

## KEYWORDS

psoriasis, calcipotriol/betamethasone foam, videocapillaroscopy, thermography

## 1 | INTRODUCTION

Psoriasis vulgaris is a chronic, inflammatory, immune-mediated, erythematous-squamous dermatosis, affecting 2%–4% of Western population,<sup>1,2</sup> with a significant negative impact on health-related quality of life (HRQoL), comparable with that induced by other chronic conditions, such as diabetes.<sup>3</sup> Although in the last 15 years the introduction of biologics has deeply changed the therapeutic management of patients suffering from moderate to severe disease, topical treatments still represent the milestone in the treatment of patients with mild to moderate psoriasis.<sup>4,5</sup> Considering clinical parameters Psoriasis Global Assessment (PGA), Psoriasis Area Severity Index (PASI), Dermatology Life Quality Index (DLQI), or the so-called “rules of tens,” nearly 80% of psoriasis cases are mild, so they can be effectively managed by topical therapy alone. Current guidelines, indeed, recommend the topical use of vitamin D analogs and corticosteroids, either as separate products used in combination or as a fixed combination, as first-line treatment.<sup>6,7</sup>

An aerosol foam formulation of fixed-combination of calcipotriol plus betamethasone dipropionate (Cal/BD foam) has been developed as a new topical therapeutic option for psoriasis, indicated for patients at least 18 years of age.<sup>8,9</sup> It proposes the innovation of the vehicle, the foam, which compared with cream, or ointment is aimed at increasing the adherence to topical therapy, which still remains the major challenge in the management of the psoriatic patient, with topical treatment based on a combination of steroid and vitamin D analogue.<sup>10</sup>

The purpose of this open-label, non-randomized clinical trial was to evaluate the efficacy of this treatment beyond the clinically evaluable effect. The scientific community is nowadays aware that psoriasis is a disease that develops “beyond the skin,” because of its multisystem involvement and the range of co-morbidities it is associated with, and because of its complex immunoinflammatory genesis, involving several cells and molecules.<sup>11,12</sup> Thus, “beyond the skin,” that is “beyond the eyes” of clinicians, it has been thought to evaluate the anti-inflammatory and pro-keratinizing effect of Cal/BD foam, by detecting changes in skin microcirculation. For this purpose, skin lesions were evaluated both before and after treatment by using videocapillaroscopy, able to evaluate morphologic changes in dermal microvessels, and thermography, able to provide an indirect evaluation of surface temperature of human skin and assess the hyperkeratinization, respectively at dermal and epidermal levels, through identification of epithelium's temperature gradients.

## 2 | MATERIALS AND METHODS

### 2.1 | Study population

We evaluated the efficacy of Cal/BD foam application on 11 patients (6 males, 5 females, with ages between 23 and 66 years and median

age  $45.9 \pm 10.9$ ) affected by mild-to-moderate psoriasis. Calcipotriol and betamethasone concentrations were  $50 \mu\text{g/g}$  and  $0.5 \text{ mg/g}$ , respectively. Patients recruited generally had PASI value less than 10, although some patients with DLQI values even greater than 10 were recruited. The patients all had psoriasis for at least 5 years.

After a wash-out period of 4 weeks for topical and 12 weeks for systemic therapies, Cal/BD foam was applied on psoriatic lesions for 4 weeks ( $T_0$ – $T_4$ ). None of these patients had previously used calcipotriol plus betamethasone dipropionate foam ad therapy. Patients were recommended to apply once daily an amount of 0.5 g of Cal/BD foam (corresponding to 2 s of delivery) for each palm-sized area of skin affected by psoriasis, and to apply the Cal/BD foam once daily. Informed consent was obtained from all patients before starting the study. Patients were recruited during a period from November to March to avoid the antipsoriatic effect of sun exposure.

### 2.2 | Efficacy evaluation

Patients were evaluated both before ( $T_0$ ) and after ( $T_4$ ) 4 weeks of treatment.

*Clinimetric indexes:* PASI, PGA, and DLQI values were obtained at  $T_0$  and  $T_4$ .

*Instrumental analyses:* Psoriatic plaques were analyzed by videocapillaroscopy and thermography, at  $T_0$  and  $T_4$ .

- Videocapillaroscopy is a noninvasive, in vivo imaging technique involving the direct visualization of skin capillaries through an optic contact probe microscope attached to a computerized video microscope (Fotofinder Dermoscope at magnification 60X, 100X, and 200X). In all enrolled patients, we selected a target lesion on the extensor surface of upper limb and IVCP examination was performed both at  $T_0$  and  $T_4$ , to quantify the density of newly formed blood vessels, so-called “bushy capillaries,” derived from the elongation and convolution of the capillary loops of the dermal papillae. Blood vessel counting was carried out by the same external observer at 60X magnification and compared between  $T_0$  and  $T_4$ .
- Thermography is a noncontact technique capable of capturing, by means of a thermographic sensor (namely *infrared camera*), the radiant energy emitted by a body at a given temperature other than absolute zero. The recorded thermal energy is converted in *thermographs*, also called *thermal images*. Each image is a map of false colors representing the various levels of infrared emission, from the higher value (red color), which indicates the maximum temperature, to the lower value (blue color) which is the minimum one (Figure 1). For this purpose, the “InfraTec” infrared camera (model: Variocam HD head 900) was adopted to obtain a quantitative map of the skin temperature. In this way, the

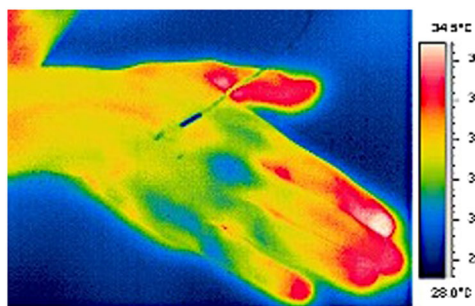
temperature variation caused by skin plaques was observed and analyzed by calculating the temperature difference  $\Delta T$  ( $^{\circ}\text{C}$ ), between the center of the lesions and their periphery (healthy skin), before and after 4-weeks of treatment. The color map obtained from the skin temperature of each patient was also compared with the visible images of the same investigated area acquired by using a common digital camera, to verify any differences through the infrared and visible spectral regions. A thermo-hygrometer was also adopted to monitor the relative humidity and the room temperature during the acquisition, using these values for calibrating the thermal camera parameters. Patients were examined in an outpatient clinic with an ambient temperature of  $21^{\circ}$  for a duration of 30 min per visit.

### 2.3 | Safety evaluation

Any adverse effects of topical therapy were carefully monitored and registered.

## 3 | RESULTS

The antipsoriatic effect of the drug was highlighted by clinical parameters evaluation. After 4 weeks of treatment with Cal/BD foam, all clinimetric indexes showed a significant decrease: DLQI



**FIGURE 1** Thermogram (infrared image): Image of a hand taken in mid-infrared (“thermal”) light (false color) with a related celsius temperature scale.

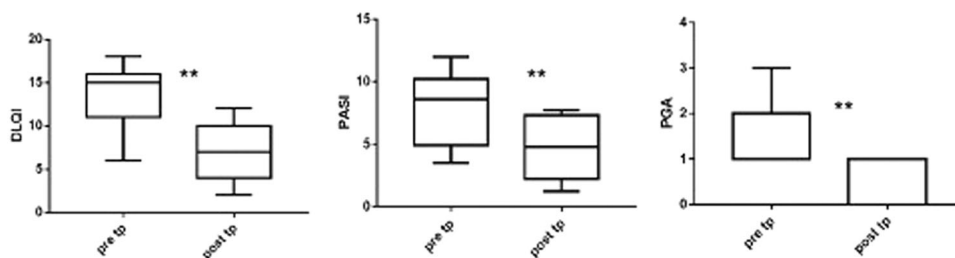
mean value decreased from  $13.45 \pm 3.59$  ( $T_0$ ) to  $6.82 \pm 3.31$  ( $T_4$ ) ( $p = 0.001$ ), PASI mean value reduced from  $7.909 \pm 2.857$  ( $T_0$ ) to  $4.582 \pm 2.422$  ( $T_4$ ) ( $p = 0.001$ ), PGA mean value diminished from  $1.8 \pm 0.6$  ( $T_0$ ) to  $0.7 \pm 0.4$  ( $T_4$ ) ( $p = 0.002$ ). Both skin lesions, objectively assessable by clinician by PASI and PGA indexes, and QoL (Quality of Life), subjectively perceived by patient and estimated by DLQI index, showed improvement after therapy (Figure 2).

Videocapillaroscopy showed an excellent reduction of typical “bushy capillaries” after administration of Cal/BD foam. Capillary density decreased from  $27.91 \pm 6.70$  capillaries/ $\text{mm}^2$  ( $T_0$ ) to  $4.54 \pm 2.77$  capillaries/ $\text{mm}^2$  ( $T_4$ ) ( $p = 0.001$ ), with an 83.73% reduction (Figure 3).

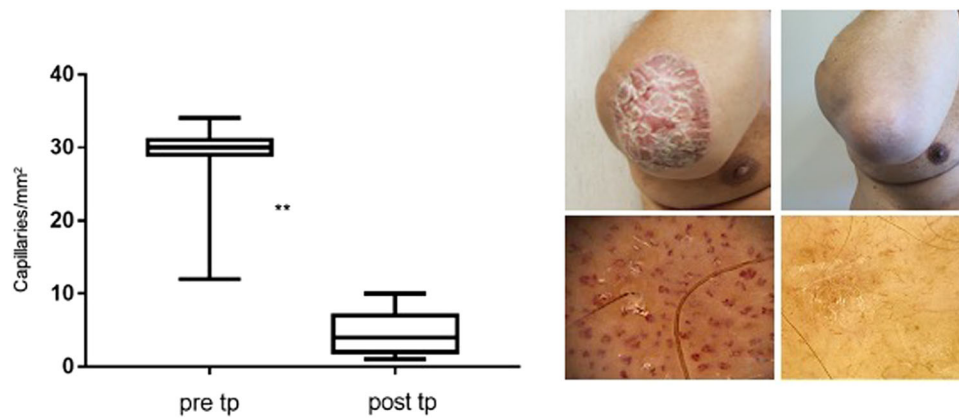
Similar results merged from the thermographic analysis. First, through a correlation between clinical parameters and  $\Delta T$  values, the threshold for “active patients” at a  $\Delta T$  mean value of 0.13 and the threshold for “patients in regression” of  $-0.19$  were established. Most importantly, a significant reduction of mean value of  $\Delta T$ , decreasing from  $0.28 \pm 0.99$  to  $-0.42 \pm 0.39$  ( $p = 0.048$ ), was observed. Moreover, we noticed that  $\Delta$ body temperatures values were always  $>0$  at  $T_0$ , and  $\Delta$ body temperatures were always  $<0$  at  $T_4$ , but this was not for supra-articular lesions, which were already  $<0$  in most cases at  $T_0$ , and tend to remain  $<0$  at  $T_4$ , while approaching the value of 0. Changes in videocapillaroscopy and thermography are shown in Figure 4.

## 4 | DISCUSSION

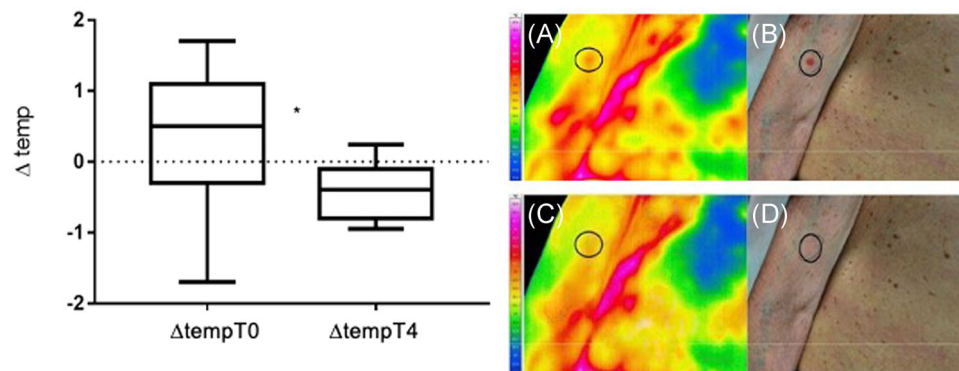
Psoriasis vulgaris is a common immune-mediated inflammatory disorder. Several histological and immunohistochemical studies have led to the general awareness that the two major pathogenic drivers of psoriatic plaques are alteration of cutaneous microcirculation and dysregulated differentiation of the epidermal cells. In psoriasis plaques, the capillary loops in the dermal papillae are elongated, tortuous, and dilated, to be defined “bushy.”<sup>13</sup> They represent angiogenesis occurring at the level of the dermis, an early and reversible phenomenon, indicative of increased inflammation.<sup>14,15</sup> The pathophysiology of angiogenesis in psoriasis is extremely complex and not fully elucidated yet. Several cell types are involved,



**FIGURE 2** Clinimetric indexes changes after 4 weeks of therapy with Cal/BD foam. Cal/BD, calcipotriol plus betamethasone dipropionate; DLQI, dermatology Life Quality Index; PASI, Psoriasis Area Severity Index; PGA, Physician Global Assessment; post tp, posttherapy; pre tp, pre-therapy; \*\* $p < 0.001$



**FIGURE 3** Clinical and videocapillaroscopic changes after 4 weeks of therapy with Cal/BD foam. Cal/BD, calcipotriol plus betamethasone dipropionate; post tp, posttherapy; pre tp, pre-therapy. \*\* $p < 0.01$



**FIGURE 4** Clinical and thermographic changes before (A and B) after 4 weeks of therapy with Cal/BD foam (C and D).  $\Delta\text{tempT0}$ : Temperature difference  $\Delta T$  ( $^{\circ}\text{C}$ ), between the center of the lesions and their periphery (healthy skin), before treatment;  $\Delta\text{tempT4}$ : Temperature difference  $\Delta T$  ( $^{\circ}\text{C}$ ), between the center of the lesions and their periphery (healthy skin), after 4 weeks of treatment with Cal/BD foam. Cal/BD, calcipotriol plus betamethasone dipropionate. \* $p < 0.05$

such as keratinocytes, mast cells, monocytes, and neutrophils, as well as several chemokines, including vascular endothelial growth factor (VEGF), tumor necrosis factor, angiopoietins, hypoxia-inducible factors, and interleukin-8. VEGF-1 probably plays a central role in the process of vessel budding, being overexpressed, as its receptors, at the level of the microcirculation of the psoriatic plaque, and angiopoietins 1-2, also overexpressed and probably more involved in the stabilization of newly formed vessels.<sup>16,17</sup> These vascular changes appear before the process of hyper-parakeratosis becomes clinically and histologically evident.<sup>18,19</sup>

Our study compared the clinical efficacy of the Cal/BD foam with its “capillaroscopic and thermographic effect.” Completed 4 weeks of treatment, both PASI and PGA significantly decreased with a reduction of about 43% and 50% mean levels, respectively, however, videocapillaroscopy showed a greater significant decrease, in the same time range, of the capillary density of 83.73%.

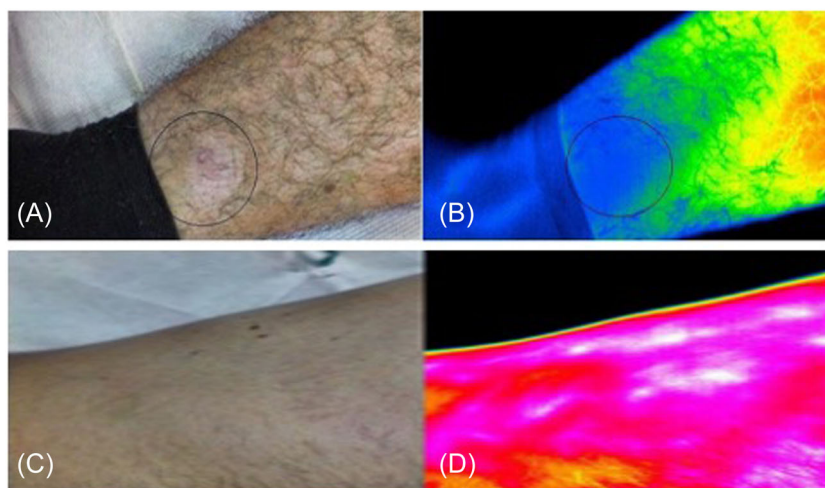
Our study demonstrated, first, that the drug effect is related to a real reduction of the inflammatory process which supports angiogenesis. Moreover, our data provide evidence that restoration of

physiological microcirculation is faster than a return of the skin to normal clinical status: this supports the idea that the pathological vascular bed of the psoriatic plaque plays a key role in perpetrating clinical lesions.<sup>19</sup>

Skin affected by psoriasis undergoes temperature changes. These are due to pathophysiological features of the disease, such as loss of the granular layer of the epidermis, parakeratosis, dermal inflammatory infiltrate, as well as the alterations in microcirculation mentioned above.<sup>20,21</sup> In particular, as also shown by previous studies, active plaques tend to have higher temperatures than regressing ones.<sup>20</sup>

Thermography is a diagnostic investigation increasingly employed in medicine, and especially in dermatology, where it has gained application in various diseases such as allergic patch and prick skin tests, morphea, basal cell carcinoma, and melanocytic naevi, melanoma, Raynaud's phenomenon, and many other pathological conditions.<sup>22,23</sup> In our study, we combined it to videocapillaroscopy to better assess the subclinical benefit of therapy on psoriatic plaques.

**FIGURE 5** Correlation between thermographic and clinical aspects of psoriatic skin lesions at T4 (A and B) and T0, (C and D).



We detected an excellent decrease in  $\Delta T$ , that is, the difference of temperature ( $^{\circ}\text{C}$ ) between center of the lesions and their “healthy” periphery, at T4 with a reduction in the order of 200% of the initial value, even in this case we observed a proportionally greater improvement in subclinical parameters than in clinical ones. This is a clear demonstration not only of the anti-inflammatory but also of the keratinization regularizing effect of the drug. Furthermore, by correlating clinical parameters with  $\Delta T$  values, a threshold for “active patients” at a  $\Delta T$  mean value of 0.13 and threshold for “patients in regression” of  $-0.19$  were established. Figure 5 provides a correlation between the clinical and thermographic appearance of some psoriatic lesions. Figure 5A shows at T4, a psoriatic plaque probably in remission, while remission is certain considering thermographic analysis as shown in Figure 5B.

Figure 5C shows, at T0, clinically healthy skin, whereas “active lesions” appeared considering thermography (Figure 5C): it was probably unaffected skin which later transferred into psoriatic lesions. Thus, a patient might be clinically healed but still be “subclinically” ill; conversely, a patient with apparently active clinical lesions might be already in remission.

We noticed that  $\Delta$ body temperatures values were always  $>0$  at  $T_0$ , and  $\Delta$ body temperatures were always  $<0$  at  $T_4$ , but this was not for supra-articular lesions, which were already  $<0$  in most cases at  $T_0$ , and tend to remain  $<0$  at  $T_4$ . We attributed the origin of this phenomenon to the fact that the plaques that develop in supra-articular sites are more keratotic, and thus give rise to greater thermal insulation. This may be a limitation of using thermographic analysis in these areas.

Videocapillaroscopy and thermography can see what escapes human eyes. The concepts of “active patient” and “regressing patient,” or “effective therapy,” and “ineffective therapy,” can change when considered from the perspectives of videocapillaroscopy and thermography. These considerations are in accordance with recent studies showing that unaffected skin in course of psoriasis is only apparently healthy, as it would instead be affected on a molecular level.<sup>24,25</sup> This also recalls the concept of “residual psoriasis,” that is, clinical residue of psoriasis that may remain active while the patient is

on biological drug therapy, and still needs further explanation in etiology, pathogenesis, monitoring, and therapy, and, then, eyes more powerful than human ones, which could catch it.<sup>26</sup>

Psoriasis is a such complex and multifaceted pathology that it should be considered under its subclinical and microscopic profile when evaluating its course or the efficacy of a therapy. If we combine this with the fact that videocapillaroscopy and thermography are quantitative techniques and therefore more objective in assessment, we can imagine their potential in the management of psoriasis.<sup>27</sup>

## 5 | CONCLUSIONS

Our clinical, capillaroscopic, thermographic data supported the hypothesis that 4-week application of Cal/BD foam is effective on psoriatic skin lesions.

The efficacy of the Cal/BD foam has been demonstrated at both clinical and subclinical levels; the improvement observed at the subclinical level reveals that the Cal/BD foam is capable of both inducing a decrease in inflammation and regularization of epithelial keratinization.

In addition, our investigation looks into a complex and unexplored world, that of the management of psoriasis from a subclinical viewpoint, both in terms of diagnosis and therapy, a world in which videocapillaroscopy and thermography appear to us as eyes that could see better than ours, “human eyes.”

### AUTHOR CONTRIBUTIONS

**Marani Andrea:** Data curation; formal analysis; writing—original draft. **Orciani Monia:** Conceptualization; resources. **Fabiani Francesco:** Data curation; funding acquisition; investigation. **Napolitano Rachele:** Methodology; project administration; visualization. **Arnesano Marco:** Resources; software. **Tomasini Enrico Primo:** Methodology; project administration.

### ACKNOWLEDGMENT

The manuscript was not funded.



## CONFLICTS OF INTEREST

The authors declare no conflicts of interest.

## DISCLOSURE

All authors have read and approved the final version of the manuscript and had full access to all of the data in this study and takes complete responsibility for the integrity of the data and the accuracy of the data analysis. The authors confirm that the data supporting the findings of this study are available within the article. Prof. Anna Campanati affirms that this manuscript is an honest, accurate, and transparent account of the study being reported; that no important aspects of the study have been omitted; and that any discrepancies from the study as planned (and, if relevant, registered) have been explained.

## TRANSPARENCY STATEMENT

The manuscript is an honest, accurate, and transparent account of the study being reported; that no important aspects of the study have been omitted; and any discrepancies from the study as planned (and, if relevant, registered) have been explained.

## ORCID

Napolitano Rachele  <http://orcid.org/0000-0002-6015-1682>

## REFERENCES

- Papp KA, Gniadecki R, Beecker J, et al. Psoriasis prevalence and severity by expert elicitation. *Dermatol Ther.* 2021;11(3):1053-1064.
- Luchetti MM, Benfaremo D, Campanati A, et al. Clinical outcomes and feasibility of the multidisciplinary management of patients with psoriatic arthritis: two-year clinical experience of a dermo-rheumatologic clinic. *Clin Rheumatol.* 2018;37(10):2741-2749.
- Gisondi P, Talamonti M, Chiricozzi A, et al. Treat-to-target approach for the management of patients with moderate-to-severe plaque psoriasis: consensus recommendations. *Dermatol Ther.* 2021;11(1):235-252.
- Bardazzi F, Magnano M, Campanati A, et al. Biologic therapies in HIV-infected patients with psoriasis: an Italian experience. *Acta Derm Venereol.* 2017;97(8):989-990.
- Campanati A, Ganzetti G, Giuliodori K, Molinelli E, Offidani A. Biologic therapy in psoriasis: safety profile. *Curr Drug Saf.* 2016;11(1):4-11.
- Menter A, Korman NJ, Elmets CA, et al. Guidelines of care for the management of psoriasis and psoriatic arthritis. Section 3. Guidelines of care for the management and treatment of psoriasis with topical therapies. *J Am Acad Dermatol.* 2009;60: 643-659.
- Samarasekera E, Sawyer L, Parnham J, Smith CH. Assessment and management of psoriasis: summary of NICE guidance. *BMJ.* 2012;345:e6712.
- Summary of product characteristics: Enstilar, Leo Pharma May, 2017. Accessed July 11, 2018. <https://www.medicines.org.uk/emc/files/pil.2139.pdf>
- Megna M, Cinelli E, Camela E, Fabbrocini G. Calcipotriol/betamethasone dipropionate formulations for psoriasis: an overview of the options and efficacy data. *Expert Rev Clin Immunol.* 2020;16(6): 599-620. doi:10.1080/1744666X.2020.1776116
- Kuehl B, Shear NH. The evolution of topical formulations in psoriasis. *Skin Therapy Lett.* 2018;23(4):5-9.
- Campanati A, Neri P, Giuliodori K. Psoriasis beyond the skin surface: a pilot study on the ocular involvement. *Int Ophthalmol.* 2015;35(3): 331-340.
- Ganzetti G, Campanati A, Santarelli A, et al. Involvement of the oral cavity in psoriasis: results of a clinical study. *Br J Dermatol.* 2015;172(1):282-285. doi:10.1111/bjd.13201
- Campanati A, Moroncini G, Ganzetti G, et al. Adalimumab modulates angiogenesis in psoriatic skin. *Eur J Inflam.* 2013;11:489-498.
- Hern S, Stanton AWB, Mellor RH, Harland CC, Levick JR, Mortimer PS. In vivo quantification of the structural abnormalities in psoriatic microvessels before and after pulsed dye laser treatment. *Br J Dermatol.* 2005;152:505-511.
- Rosina P, Zamperetti MR, Giovannini A, Girolomoni G. Videocopy-rospectroscopy in the differential diagnosis between psoriasis and seborrheic dermatitis of the scalp. *Dermatology.* 2007;214: 21-24.
- Detmar M, Brown LF, Schön MP, et al. Increased micro-vascular density and enhanced leukocyte rolling and adhesion in the skin of VEGF transgenic mice. *J Invest Dermatol.* 1998;111:1-6.
- Kuroda K, Sapadin A, Shoji T, Fleischnajer R, Lebwohl M. Altered expression of angiopoietins and Tie2 endothelium receptor in psoriasis. *J Invest Dermatol.* 2001;116:713-720.
- Stinco G, Lautieri S, Valent F, Patrone P. Cutaneous vasculature alterations in psoriatic patients treated with cyclosporine. *Acta Derm Venereol.* 2007;87:152-154.
- Rosina P, Giovannini A, Gisondi P, Girolomoni G. Microcirculatory modifications of psoriatic lesions during. *Skin Res and Technol.* 2009;15:135-138.
- Zalewska A, Gralewicz G, Owczarek G. Thermography in psoriasis vulgaris evaluation. *Proceedings of the IEEE Engineering in Medicine and Biology 27th Annual Conference Shanghai, China, September 1-4, 2005.*
- Zalewska A, Wiecek B, Sysa-Jedrzejowska A, Gralewicz G, Owczarek G. Qualitative thermographic analysis of psoriatic skin lesions. *Conf Proc IEEE Eng Med Biol Soc.* 2004;2004:1192-1195.
- Jung A, Zuber J, Ring F, eds. *A Casebook of Infrared Imaging in Clinical Medicine.* Medpress; 2003.
- Mikulska D, Maleszka R, Rozewicka M. Application of thermographic imaging as a diagnostic technique in dermatology. *(Polish) Dermatol Klin.* 2002;4:57-60.
- Bozó R, Danis J, Flink BL, Vidács DL, Kemény L, Bata-Csörgő Z. Stress-related regulation is abnormal in the psoriatic uninvolved skin. *Life (Basel).* 11(7), 2021:599.
- Campanati A, Orciani M, Sorgentoni G, et al. Indirect co-cultures of healthy mesenchymal stem cells restore the physiological phenotypic profile of psoriatic mesenchymal stem cells. *Clin Exp Immunol.* 2018;193(2):234-240.
- Malagoli P. Secukinumab for the treatment of residual psoriasis: a case series. *J Dermatolog Treat.* 29(sup1). 2018;12-13.
- Castillo-Martinez C, Valdes-Rodriguez. El R, Kolosovas-Machuca S., Moncada B, Gonzalez F J. Use of digital infrared imaging in the assessment of childhood psoriasis. *Skin Res Technol.* 2012: 1-3.

**How to cite this article:** Anna C, Andrea M, Melania G, et al. Efficacy of calcipotriol plus betamethasone dipropionate foam on psoriatic skin lesions beyond human eyes: An observational study. *Health Sci. Rep.* 2022;5:e597. doi:10.1002/hsr2.597