



Posterior capsule rupture with FLACS due to erroneous interpretation of a high OCT intensity area in anterior vitreous

Hiroshi Horiguchi^{*}, Mei Kurosawa, Takuya Shiba

Department of Ophthalmology, The Jikei University, School of Medicine, Tokyo, Japan

ARTICLE INFO

Keywords:

Femtosecond laser-assisted cataract surgery
FLACS
Complication
OCT
Posterior capsule rupture
Dropped nucleus

ABSTRACT

Purpose: We describe a case of posterior capsule rupture during femtosecond laser-assisted cataract surgery (FLACS) due to direct exposure of the posterior capsule to the laser beam.

Observations: A 47-year-old man underwent FLACS for anterior capsule opacity. The CATALYS® system automatically detected the posterior capsule from the optical coherence tomography (OCT) images, after which the operator manually adjusted the line of posterior capsule. Femtosecond laser irradiation was presumed to be completed successfully. However, upon insertion of a phaco-tip, the diced nucleus of the lens dropped into the vitreous chamber. Reviewing intraoperative OCT images of the treatment summary to check the area irradiated by laser, an arc-shaped high-intensity area was observed behind the posterior capsule. This high-intensity was misinterpreted as the posterior capsule, which led to error in application of laser beam during procedure.

Conclusions and importance: Comparison of data acquired using different imaging modalities could enable correct identification of the posterior capsule.

1. Introduction

Femtosecond laser-assisted cataract surgery (FLACS) is beneficial to both cataract surgeons and patients. For example, femtosecond laser capsulotomy allows for performance of more precise capsulotomy¹ and lens fragmentation reduces the effective phacoemulsification time.² The positive aspects of this new technology could reduce the risk of severe complications during cataract surgery.

However, there is a possibility of relatively unknown complications that inevitably accompany new techniques. One severe complication during cataract surgery is posterior capsule rupture (PCR). Roberts et al. reported that capsular block syndrome (CBS) associated with FLACS caused PCR.³ Gas bubbles produced by exposure to the femtosecond laser caused CBS. Most commonly, PCR in FLACS occurred aspiration of the nucleus of the lens or the cortex. Less commonly, it may be associated with CBS. PCR and/or vitreous loss occurred in approximately 2% of patients undergoing conventional phacoemulsification surgery.⁴ Moreover, there was no significant difference in PCR between the conventional phacoemulsification group and FLACS group.⁵

In this study, we describe a novel case of PCR caused by exposure to femtosecond laser. The PCR resulted because an arc-shaped structure visible in the high-intensity optical coherence tomography (OCT) in the

anterior vitreous behind the posterior capsule was mistakenly identified as the posterior capsule by both the software for automatic tissue detection of the FLACS system and a highly experienced cataract surgeon (~10,000 conventional surgeries and ~500 FLACS surgeries).

2. Case report

A 47-year old man with moderate myopia underwent FLACS with multifocal intraocular lens (mIOL) for the treatment of bilateral anterior capsular cataract. Preoperatively, best-corrected visual acuity (BCVA) of his right eye at distance was 0.7, based on decimal visual acuity (equivalent to 0.1547 on logMAR visual acuity) with a refractive error of $-4.00-1.00 \times 010$. The BCVA of his left eye at distance was also 0.7, with a refractive error $-3.50-2.50 \times 180$. Slit lamp and fundus examination with mydriasis showed no specific findings except anterior capsular cataract in both eyes. In the right eye, axial length was 25.70 mm, anterior chamber depth was 3.87 mm, and lens thickness was 3.63 mm, as measured by an optical biometer (IOLMaster®, Carl Zeiss Meditec AG, Jena, Germany). Anterior swept-source OCT measurement (CASIA2®, TOMEY, Japan) revealed lens thickness of 3.87 mm (Fig. 1a, b and c). In the left eye, optical biometer measurements revealed that the axial length was 25.59 mm, anterior chamber depth was 4.05 mm,

^{*} Corresponding author.

E-mail address: hhiro@jikei.ac.jp (H. Horiguchi).

and lens thickness was 3.20 mm. Originally, we planned to implant ZLB00 lens for the right eye and ZMB00 for the left eye using a mix-and-match strategy. The CATALYS® Precision Laser System (Johnson & Johnson, New Brunswick, United States) was used to perform this surgery.

FLACS was first performed on the right eye for an anterior capsule opacification. After the automatic lens detection procedure, the operator manually adjusted the position of the posterior capsule. Femtosecond laser exposure seemed to be performed successfully with no complications. The operator then opened a temporal corneal incision with a blunt spatula and confirmed whether the anterior capsulotomy was completed using an ophthalmic viscosurgical device and slit illumination as is typical. The operator noticed that the diced-nucleus abnormally moved slightly towards the vitreous chamber, but continued the surgical procedure. As soon as the operator inserted a phaco-tip (Signature®, Johnson & Johnson, New Brunswick, United States) into the anterior chamber, the lump of the diced-nucleus started to drop into the vitreous chamber. The operator immediately stopped irrigation, switched to viscoextraction and then performed anterior vitrectomy. Because the diced-nucleus was softened by exposure to the femtosecond laser, most nuclei were smoothly removed with viscoextraction and easily excised using a vitreous cutter. After carefully removing all the remnants of the nucleus within his visible range, the operator did not insert any IOLs with the preserved capsulorrhexis because of two reasons: the planned multifocal IOL (ZLB00) was a one-piece IOL not suitable for a sulcus fixation and an optic capture, and the distance at the near focal point of ZLB00 differs from that of any other available three-piece multifocal IOLs.

After the surgery, we reviewed the treatment summary of FLACS, which reported a lens thickness of 5.2 mm by the intraoperative OCT measurement. The OCT image showed that an arc-shaped high-intensity area existed behind the posterior capsule in the anterior vitreous (Fig. 2a and b), which led to error in determining the correct location of the

posterior capsule. The intensity of this area was higher than that of the posterior capsule.

On postoperative day 1, the patient's BCVA was "hand motion" due to the residual swollen nucleus in the anterior chamber that presumably remained behind the iris or the ciliary body. The residual nucleus was removed from the existing temporal corneal incision by viscoextraction. On postoperative day 8, BCVA of his right eye was 1.2, based on decimal visual acuity with a refractive error of $+6.25-0.50 \times 040$. On postoperative day 14, we inserted the ZMA00 + 10.00D lens with a sulcus fixation into his right aphakic eye. The operator chose a sulcus fixation rather than an IOL capture to avoid a myopic refractive error that could occur due to the release of the captured IOL from a capsulorrhexis.

We performed FLACS with a ZLB00 + 11.5D lens for his left eye on the next day. An automatic alignment for the posterior capsule failed again because an arc-shaped high OCT intensity area also existed in the left eye. The operator fixed the alignment carefully and completed the surgery without any complications. After 1-month, uncorrected visual acuity at a distance in his right eye was 1.2, and BCVA was 1.5.

3. Discussion

We report a case of PCR during FLACS due presence of a high OCT intensity zone behind the posterior capsule. To the best of our knowledge, this is the first study reporting direct evidence of PCR due to laser

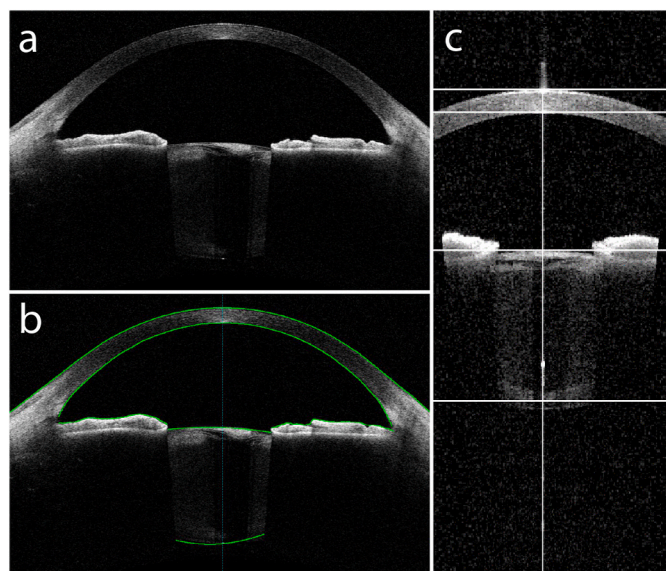


Fig. 1. Swept-source OCT images of the sagittal section of the right eye. a) b) Scanning with CASIA2®. a) Although anterior capsule opacification caused shadows in the lens, the posterior capsule was clearly distinguished as a border between the lens and vitreous chamber. b) Same view with automatically defined borders. The green solid line indicates the borders between tissues (cornea, iris, and lens) and chambers. Automatic segmentation was successfully performed. The lens thickness was 3.87 mm, as calculated from the image. c) Scanning with the IOLMaster®700 system. The lens thickness was 3.63 mm, as calculated by the third and fourth horizontal lines defining a crystalline lens. (For interpretation of the references to colour in this figure legend, the reader is referred to the Web version of this article.)

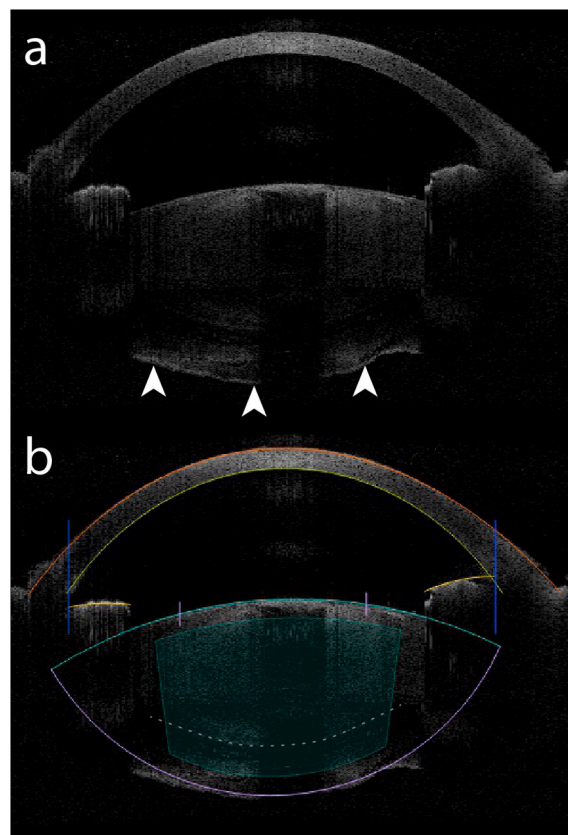


Fig. 2. Spectral domain OCT (CATALYS®) image of the sagittal section of the right eye. a) A high-intensity arc-like zone was observed behind the posterior capsule, in the anterior vitreous, which could be mistaken for the posterior capsule (white arrowhead). b) Same view with manually defined borders after automatic segmentation. The defined posterior capsule (purple) was well aligned to high-intensity zone. However, the purple line was located much deeper than the actual posterior capsule based on the CASIA2® images (gray dotted line). Consequently, the exposure area for the femtosecond laser (cyan) included the posterior capsule. (For interpretation of the references to colour in this figure legend, the reader is referred to the Web version of this article.)

exposure during cataract surgery. We believe that our case is rare; however, PCR could occur in any similar case if the causes and measures are not considered. Herein, we discuss the cause and measures to avoid this complication.

High OCT intensity area behind the posterior capsule: In our case, the high OCT intensity area behind the posterior capsule obviously played an important role in PCR due to laser exposure. The high-intensity area showed downward convexity that made it appear as a part of the lens, which presumably results from the anterior vitreous behind the lens. The high OCT area was observed only on the CATALYS® OCT subsystem, and not on the CASIA2® OCT and IOL master® 700. There were several possible reasons for observation of this phenomenon only on CATALYS® system. First, the patient was in a supine position only while undergoing the scan with the CATALYS® system. The vitreous could be easily moved by the head position. Second, the laser wavelength and the scanning method in the CATALYS® system differ from the others. The CATALYS® OCT subsystem employs an 820–930 nm spectral domain OCT. On the other hand, CASIA2® employs a 1310 nm swept-source OCT, while IOL master® 700 employs a 1055 nm swept-source OCT. Finally, the sensitivity of OCT scanning in CATALYS® system differs from that of other devices due to duration of the scan and use of mydriatics. The anterior ocular segment was scanned in approximately 7 seconds by the CATALYS® system. The scanning duration of CASIA2® and IOL master® 700 were 0.3 and 1.2 secs, respectively. Additionally, the pupil is dilated using mydriatics during FLACS, which allows more photons to pass through the iris plane. We assume that some or all of the reasons stated above explain why the CATALYS® OCT system and not the other systems depicted the high-intensity area in anterior vitreous behind the lens.

We have to consider not only the anterior vitreous but also the Berger space as a source of high OCT intensity behind the posterior capsule. In previous reports, the Berger space has been depicted as a very low OCT intensity area surrounded by the anterior face of the vitreous whose intensity was higher than that of the Berger space.^{6,7} Similar to a previous case,⁸ the idiopathic opacification of the Berger space could be a source of the high OCT intensity. However, it was unlikely that such unique findings were overlooked under mydriasis at our clinic. Hence, we concluded that the high OCT intensity area was the anterior vitreous, which was confused with the posterior capsule.

Prevention of the mis-irradiation: After quick identification of the anterior and posterior cornea and iris, edge of the pupil, and the anterior and posterior capsule using the CATALYS® system, the surgeon carefully checks the position of these lines on the OCT image by eye, and manually adjusts the position (if necessary). In our case, this routine safety step did not prevent the mis-irradiation of the femtosecond laser to the posterior capsule. Ideally, an artificial intelligence system could be developed to automatically confirm the real shape of the crystalline lens; however, currently this error must be avoided by other means. One such measure would be to check whether the estimate of lens thickness by the CATALYS® system is within the plausible range. However, this alone would not likely be sufficient given that lens thickness may vary widely, ranging from 3 to over 6 mm.⁹ Accordingly, in our center, we have now started to compare pre- and intra-operative lens thickness using other devices. Importantly, in this study, we observed a similar arc-shaped OCT area behind the lens in the other eye. Automatic segmentation failed again, but the operator adjusted the line defining the location of the posterior capsule, which indicates that examination of the fellow eye is useful for predicting the intraoperative OCT images and avoiding procedural errors. If surgeons have knowledge of the

possibility of failure of automatic segmentation, distinguishing between the posterior capsule and the convex shape of the anterior vitreous could be possible. The convex shape of the anterior vitreous does not form a perfect arc like the posterior capsule.

4. Conclusions

A surgeon should pay attention during FLACS, despite normal appearance of intraoperative OCT images and correct identification of tissues in the anterior chamber, in order to avoid occurrence of complications due to presence of a high OCT intensity area in the vitreous. Comparison with preoperative biometry measurements could prevent complications arising due to misalignment of tissues in the anterior chamber.

Patient consent

Written informed consent was obtained from the patient in this case. The Institutional Review Board of the Jikei University School of Medicine approved this clinical study (approval numbers: Jikei University 25–169 (7304)).

Declaration of competing interest

The Authors declare that there is no conflict of interest regarding this paper.

Acknowledgment

We thank Jonathan Winawer for useful comments and professional scientific English editing, and Tadashi Nakano for helpful advices regarding our early version of manuscript. This study was supported by Japan Society for the Promotion of Science (JSPS) KAKENHI (JP18K16939 to H.H.), and Charitable Trust Fund for Ophthalmic Research in Commemoration of Santen Pharmaceutical's Founder (H.H.). The Authors declare that there is no conflict of interest.

References

- Friedman NJ, Palanker DV, Schuele G, et al. Femtosecond laser capsulotomy. *J Cataract Refract Surg.* 2011;37:1189–1198.
- Conrad-Hengerer I, Hengerer FH, Schultz T, Dick HB. Effect of femtosecond laser fragmentation on effective phacoemulsification time in cataract surgery. *J Refract Surg.* 2012;28:879–883.
- Roberts TV, Sutton G, Lawless MA, Jindal-Bali S, Hodge C. Capsular block syndrome associated with femtosecond laser-assisted cataract surgery. *J Cataract Refract Surg.* 2011;37:2068–2070.
- Narendran N, Jaycock P, Johnston RL, et al. The Cataract National Dataset electronic multicentre audit of 55,567 operations: risk stratification for posterior capsule rupture and vitreous loss. *Eye.* 2009;23:31–37.
- Abell RG, Darian-Smith E, Kan JB, Allen PL, Ewe SY, Vote BJ. Femtosecond laser-assisted cataract surgery versus standard phacoemulsification cataract surgery: outcomes and safety in more than 4000 cases at a single center. *J Cataract Refract Surg.* 2015;41:47–52.
- Tassignon MJ, Ni Dhubhghaill S. Real-Time intraoperative optical coherence tomography imaging confirms older concepts about the berger space. *Ophthalmic Res.* 2016;56:222–226.
- Haeussler-Sinangin Y, Schultz T, Holtmann E, Dick HB. Primary posterior capsulotomy in femtosecond laser-assisted cataract surgery: in vivo spectral-domain optical coherence tomography study. *J Cataract Refract Surg.* 2016;42:1339–1344.
- Tanaka H, Ohara K, Shiwa T, Minami M. Idiopathic opacification of Berger's space. *J Cataract Refract Surg.* 2004;30:2232–2234.
- Jivrajka R, Shammam MC, Boenzi T, Swearingen M, Shammam HJ. Variability of axial length, anterior chamber depth, and lens thickness in the cataractous eye. *J Cataract Refract Surg.* 2008;34:289–294.