

Patellar Tendon Reconstruction Using Semitendinosus Autograft With Preserved Distal Insertion for Treatment of Patellar Tendon Rupture After Bone–Patellar Tendon–Bone ACL Reconstruction

A Case Report

John P. Haskoor,^{*†} MD and Brian D. Busconi,[†] MD

Investigation performed at the Department of Orthopedic Surgery, University of Massachusetts Medical Center, Worcester, Massachusetts, USA

Keywords: knee; complication; BTB; hamstring

Patellar tendon rupture after bone–patellar tendon–bone (BTB) anterior cruciate ligament (ACL) reconstruction is a rare but known complication. Other complications that are more common include anterior knee pain, pain with kneeling, and peri-incisional numbness. When the extensor mechanism fails after a BTB harvest, it is more commonly in the form of a patellar fracture. The rate of patellar tendon rupture has been reported to be about 0.25%, while patellar fractures are seen at a rate of 1.3%.^{1,7,18} Patellar tendon rupture can occur either in the early postoperative period, usually attributed to slip and fall–type injuries, or as a late manifestation by forced eccentric contraction in a flexed knee.^{4,6,8,9} A variety of reconstruction options have been reported in the literature.^{2,7,10} Much of the traditionally described patellar tendon repair techniques are difficult to

apply to a harvested tendon because of the defect within the patella and tendon as well as the different patterns of rupture encountered in harvested tendons. Combined with the risk of patellar fracture after BTB ACL reconstruction, the decision to make additional drill holes through the bone before the defect has filled is met with hesitation.¹¹

Hamstring tendon autografts have recently become more common as reinforcements for patellar tendon reconstruction in native tissue.^{5,16,18} The concept of preserving the distal attachment of the hamstring when reconstructing the extensor mechanism has also shown promising results. Takazawa et al¹⁷ reported a technique using a transosseous tunnel at the tibial tubercle to preserve the distal attachment of the hamstring tendons while augmenting the patellar tendon repair in a figure-of-8 fashion.

Other secondary procedures, such as meniscal root repair during the index ACL reconstruction, may further complicate surgical planning after patellar tendon rupture as well as rehabilitative protocols. To date, there has not been a case report of patellar tendon reconstruction after BTB ACL reconstruction and meniscal root repair. This is a case example of a rupture of the patellar tendon in the early postoperative period after BTB ACL reconstruction and meniscal root repair with use of a semitendinosus autograft with preserved distal attachment.

CASE REPORT

The patient was an 18-year-old male college freshman who injured his knee after a player tackled him during his high

*Address correspondence to John P. Haskoor, MD, Department of Orthopedic Surgery, 55 Lake Ave North, Worcester, MA 01655, USA (email: jphaskoor@gmail.com).

[†]Department of Orthopedic Surgery, University of Massachusetts Medical Center, Worcester, Massachusetts, USA.

One or more of the authors declared the following potential conflict of interest or source of funding: B.D.B. has received consulting fees from DePuy/Medical Device Business Systems, Extremity Medical, and Pacira Pharmaceuticals; nonconsulting fees from Arthrex and Kairos Surgical; and educational support from Arthrex and Kairos Surgical. AOSSM checks author disclosures against the Open Payments Database (OPD). AOSSM has not conducted an independent investigation on the OPD and disclaims any liability or responsibility relating thereto.

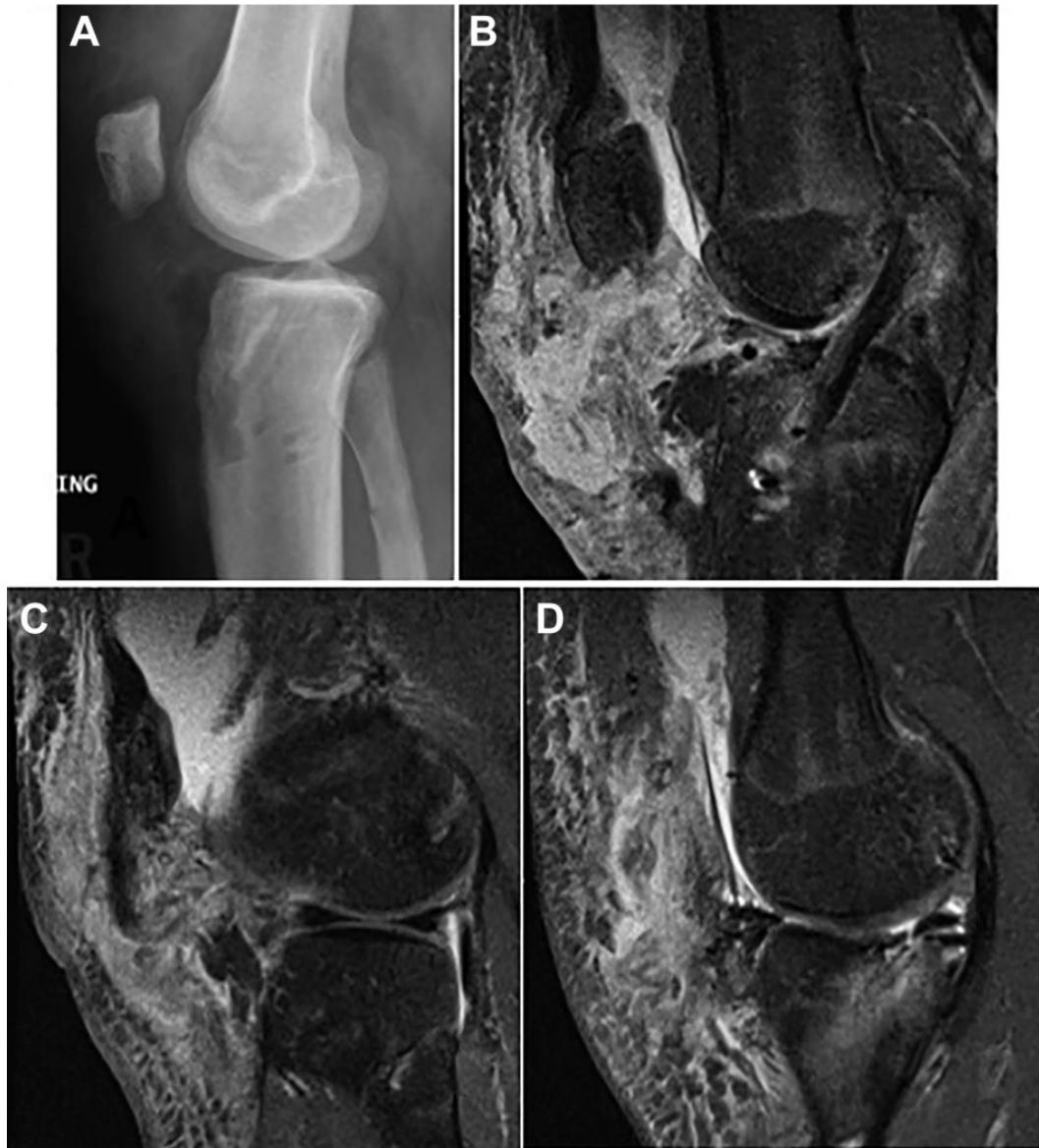

Figure 1. (A) Lateral radiograph showing the patella alta. Magnetic resonance imaging illustrates (B) rupture of the patellar tendon with an intact anterior cruciate ligament graft and a small medial stump attached to the tibia (C, D) as well as the lateral tendon still attached to the patella and an intact meniscal root repair.

school senior season. His examination was significant for a grade 2B Lachman classification and a positive medial McMurray test result. A magnetic resonance imaging (MRI) scan revealed complete tear of his ACL as well as a complex tear of the medial meniscus involving the meniscal root. Because of his desire to continue playing football competitively, he decided on a BTB autograft reconstruction with meniscal repair.

The patient was brought to the operating room, and the BTB autograft was harvested using an oscillating saw, with care taken to obtain a triangular bone block from the patella to minimize bone loss.¹⁴ During diagnostic knee arthroscopy, it was noted that there was complete rupture of the medial meniscal root as well as a displaced flap tear of the medial

meniscus. The flap tear was debrided, and the meniscal root repair was completed using a transtibial pull-out technique.³ A second medial incision was made for the ACL reconstruction to ensure that the tibial tunnel for the ACL would remain separate from the tibial harvest site and the anchor from the meniscal root repair. The graft was fixed to the tibia and femur with biocomposite interference screws. The patient had full flexion and extension, with no impingement. The paratenon was closed with interrupted Vicryl sutures. He was made 50% partial weightbearing with crutches in a hinged knee brace locked in extension, and he began continuous passive motion on postoperative day 1.

At 2 weeks postoperative, his wounds had healed and he began physical therapy focusing on range of motion; per

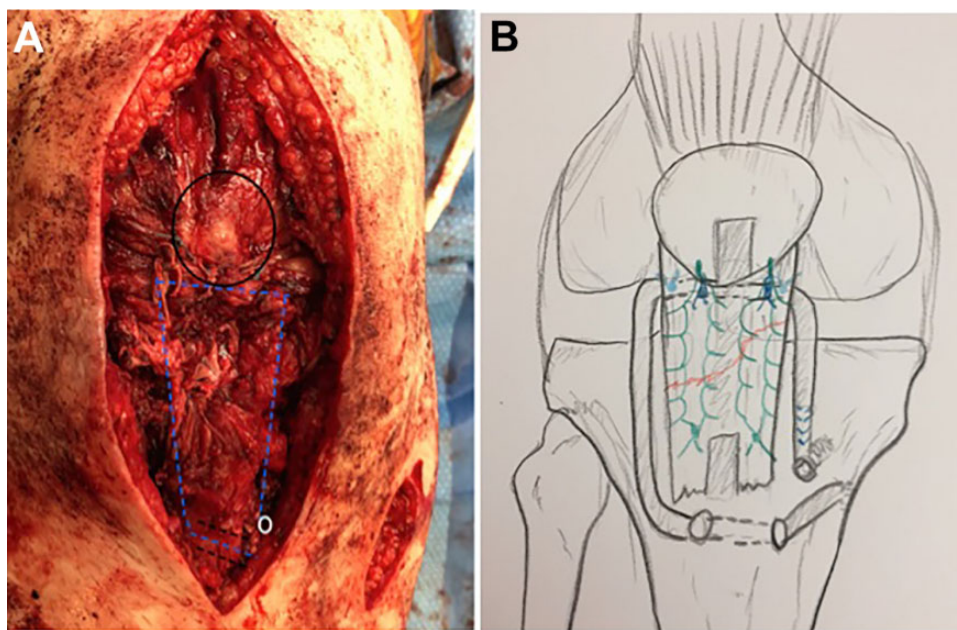


Figure 2. (A) Intraoperative photo and (B) illustration demonstrating the described operative technique.

protocol, he was to remain in a hinged brace with crutches for weightbearing. Around 6 weeks postoperatively, he slipped on ice without his brace or crutches and came in for evaluation because of increased pain and ecchymosis at the operative knee. On examination, he was unable to perform a straight leg raise. His wound remained intact but was ecchymotic. Radiographs of the knee showed patella alta. MRI showed an intact ACL reconstruction and meniscal root repair with complete tear of the mid- to distal portion of his patellar tendon (Figure 1). He was indicated for surgery to repair the ruptured patellar tendon.

The patient was taken to the operating room, where an examination under anesthesia showed an intact ACL (Lachman test) and full range of motion. These findings, combined with the lack of additional injury seen on MRI, led to the decision to forgo arthroscopic examination. A midline incision was made over the patella down to the tibial tubercle, incorporating the incision from the initial BTB graft harvest. The patellar tendon had ruptured in the distal substance, leaving a 23-mm stump attached to the tibia on the medial side. The lateral side had a substantial amount of tendon still attached to the patella. Once the scar tissue was cleared and the patellar tendon was clearly identified, a separate medial incision was made to harvest the semitendinosus tendon with an open-ended tendon stripper, preserving the distal attachment to the tibia. The harvested tendon was delivered into the central wound under soft tissue. Once the harvested tendon was stripped of muscle tissue, a 4.0-mm drill hole was placed through the tibial tubercle below the attachment of the patellar tendon. The harvested tendon was then brought through the drill hole from medial to lateral and was incorporated into the proximal tendon stump in a Pulvertaft weave fashion along the inferior border of the patella.¹³ Based on preinjury MRI, it

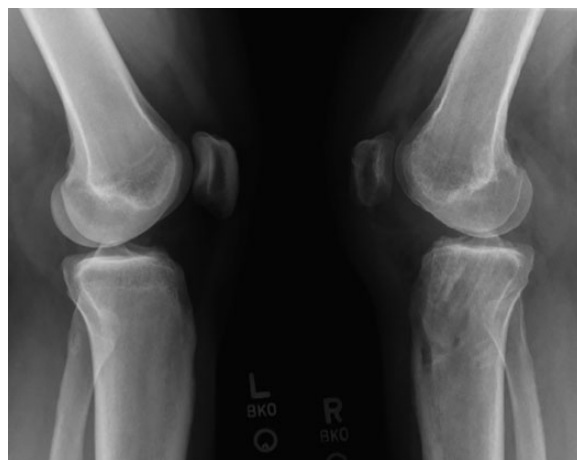

Figure 3. Three-month postoperative lateral radiographs of bilateral knees.

was determined that the patellar tendon length was 50 mm. Once the semitendinosus was weaved through the proximal tendon stump, it was placed in tension until the preinjury length of 50 mm was reestablished. The semitendinosus graft was then secured to the medial aspect of the tibia with a 4.75-mm biocomposite anchor (Figure 2). Two interrupted No. 2 FiberWire sutures were then placed to reinforce the Pulvertaft weave at the proximal tendon stump.

At this point, to further augment the repair and directly connect the proximal-to-distal stump, 2 double-loaded 2.3-mm all-suture anchors were placed in the inferior pole of the patella on the medial and lateral patellar bone adjacent to the prior BTB harvest site. A set of sutures from each anchor was used to directly repair the 2 stumps

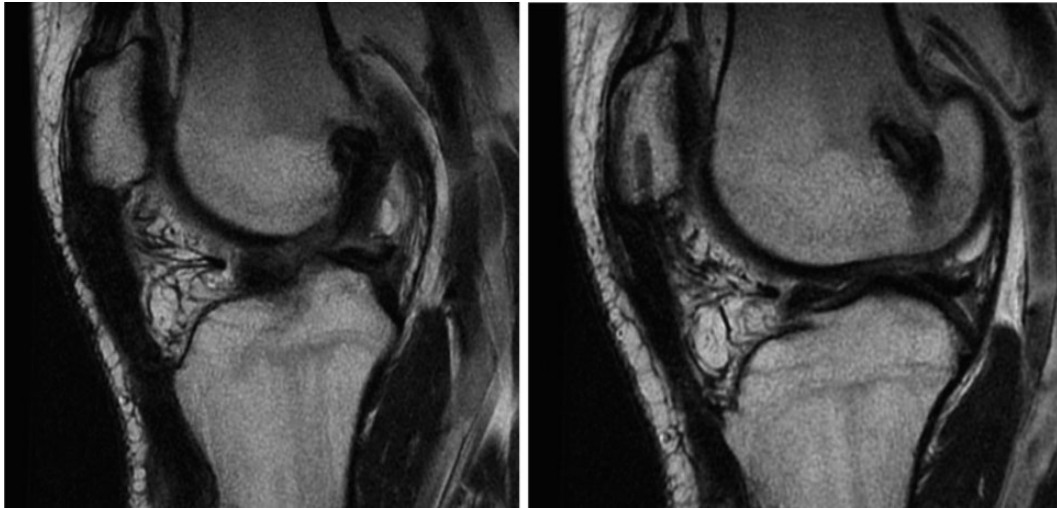


Figure 4. T2 magnetic resonance images 1 year postoperatively show a healed patellar tendon repair.

together in a running Krakow fashion, independent of the autograft. The remaining sutures were used to reinforce the weave at the inferior portion of the patella in a simple interrupted fashion. The knee was flexed from 0° to 40° intraoperatively, and the repair held together nicely.

The patient was placed in a brace locked in extension for 3 weeks until the wound had fully healed. At that point, he progressed to range of motion starting at 0° to 30°. At 6 weeks postoperatively, he advanced to 0° to 60°, then range of motion as tolerated at 10 weeks. At the 3-month follow-up, he was no longer using a brace and was able to actively flex to 110°. There was no extension lag. Radiographs at that time showed maintenance of patellar tendon length that was comparable to the uninjured side (Figure 3). At 1-year follow-up, he continued to progress with knee flexion of 135° with no extensor lag. MRI scans were taken to evaluate the integrity of the repair before allowing return to sport and showed healing of the patellar tendon–augment complex (Figure 4). He was allowed a gradual return to sport.

DISCUSSION

With patellar tendon rupture after BTB autograft ACL reconstruction, goals of operative intervention are to restore function of the extensor mechanism with little or no extensor lag, to allow early range of motion to prevent stiffness, and to avoid wound complications. Techniques with metal implants, such as Dall-Miles cables, have been used to reinforce the repair to allow range of motion more quickly.¹⁵ However, these techniques require a secondary procedure to remove the cables, and additional drill holes are made through the patella before the central defect has filled in. The use of hamstring autograft has been utilized previously in patellar tendon reconstructions, given the low morbidity of the harvest and preference of autograft over allograft tissue. Typically, this has been used in the setting of failed patellar tendon repairs, chronic patellar tendon

ruptures, or salvage techniques where quality of the residual patellar tendon tissue is of concern.^{12,18,19} Van der Bracht et al¹⁸ showed autograft hamstring to be a strong graft that allows early rehabilitation. The idea of using hamstring autograft when tissue augmentation is required was applied in this case, where a surgical void in the patellar tendon existed after BTB harvest.

The combination of hamstring autograft with all-suture anchors based in the inferior pole of the patella created a strong reconstructed patellar tendon that allowed early range of motion. This strength persisted, and by 3 months, the patient had regained almost full range of motion of the operative knee with no evidence of recurrent patella alta and was able to eventually return to sport. Additionally, this avoided the placement of large bony tunnels in the patella and the placement of hardware, which can make the patient susceptible to wound complications, necessitate removal of hardware, or increase the risk of patellar fracture.¹⁷ Finally, this fixation method highlights the large amount of tibial bone on the medial aspect of the tibia, through which anchors may be placed despite the existence of bone tunnels for ACL reconstruction and/or meniscal root repair.

The fact that this is a rare injury that can present with a variety of tear patterns makes reconstruction options difficult to study. Fortunately, advances such as all-suture anchors allow strong bony anchoring while taking up minimal space in the bone. This proves especially beneficial when anchoring in a patella with a preexisting bony defect. Furthermore, maintenance of the distal insertion of the semitendinosus autograft provides a strong biologic point of fixation, which can be helpful when reconstructing the patellar tendon.

CONCLUSION

Patellar tendon rupture after ACL reconstruction with BTB can be a devastating complication. Fortunately, it remains a rare complication. Because of the low incidence,

a gold standard technique for repair has not been established. This case represents a successful technique of patellar tendon reconstruction with semitendinosus autograft while maintaining the native attachment of the tendon on the anteromedial tibia. Additionally, MRI follow-up confirms the success of this repair technique.

REFERENCES

1. Benner RW, Shelbourne KD, Freeman H. Infections and patellar tendon ruptures after anterior cruciate ligament reconstruction: a comparison of ipsilateral and contralateral patellar tendon autografts. *Am J Sports Med.* 2011;39(3):519-525.
2. Benner RW, Shelbourne KD, Urch SE, Lazarus D. Tear patterns, surgical repair, and clinical outcomes of patellar tendon ruptures after anterior cruciate ligament reconstruction with a bone-patellar tendon-bone autograft. *Am J Sports Med.* 2012;40(8):1834-1841.
3. Blackman AJ, Stuart MJ, Levy BA, Mccarthy MA, Krych AJ. Arthroscopic meniscal root repair using a Ceterix NovoStitch suture passer. *Arthrosc Tech.* 2014;3(5):e643-e646.
4. Bonamo JJ, Krinick RM, Sporn AA. Rupture of the patellar ligament after use of its central third for anterior cruciate reconstruction. *J Bone Joint Surg.* 1984;66(8):1294-1297.
5. Espregueira-Mendes J, Andrade R, Michael MJSF, et al. Augmentation of patellar tendon repair with autologous semitendinosus graft-Porto technique. *Arthrosc Tech.* 2017;6(6):e2271-e2276.
6. Haasters F, Ockert B, Mutschler W, Kessler MA. Late patellar tendon rupture 10 years after anterior cruciate ligament reconstruction using a bone-patellar tendon-bone graft [in German]. *Unfallchirurg.* 2009;112(8):728-733.
7. Lee GH, McCulloch P, Cole BJ, Bush-Joseph CA, Bach BR. The incidence of acute patellar tendon harvest complications for anterior cruciate ligament reconstruction. *Arthroscopy.* 2008;24:162-166.
8. Marumoto JM, Richardson AB, Medoff RJ, Mayfield GW. Late patellar tendon ruptures after removal of the central third for anterior cruciate ligament reconstruction: a report of two cases. *Am J Sports Med.* 1996;24(5):698-701.
9. Mickelsen PL, Morgan SJ, Johnson WA, Ferrari JD. Patellar tendon rupture 3 years after anterior cruciate reconstruction with a central one third bone-patellar tendon-bone graft. *Arthroscopy.* 2001;17(6):648-652.
10. Milankov Ziva M, Semnic R, Miljkovic N, Harhaji V. Reconstruction of patellar tendon rupture after anterior cruciate ligament reconstruction: a case report. *Knee.* 2008;15:419-422.
11. Miller MD, Nichols T, Butler CA. Patella fracture and proximal patellar tendon rupture following arthroscopic anterior cruciate ligament reconstruction. *Arthroscopy.* 1999;15(6):640-643.
12. Nguene-nyemb AG, Hutten D, Ropars M. Chronic patellar tendon rupture reconstruction with a semitendinosus autograft. *Orthop Traumatol Surg Res.* 2011;97(4):447-450.
13. Pulvertaft RG. Tendon grafts for flexor tendon injuries in the fingers and thumb; a study of technique and results. *J Bone Joint Surg Br.* 1956;38B(1):175-194.
14. Schoderbek RJ, Treme GP, Miller MD. Bone-patella tendon-bone autograft anterior cruciate ligament reconstruction. *Clin Sports Med.* 2007;26(4):525-547.
15. Shelbourne KD, Darmelio MP, Klootwyk TE. Patellar tendon rupture repair with Dall-Miles cable. *Am J Knee Surg.* 2001;14:17-21.
16. Stephen I, Matthew M, Balazs G. Semitendinosus autograft augmentation for a patella tendon rupture after BTB ACL reconstruction. *Orthopedics and Rheumatology Open Access Journal.* 2017;6(5):555698.
17. Takazawa Y, Ikeda H, Ishijima M, et al. Reconstruction of a ruptured patellar tendon using ipsilateral semitendinosus and gracilis tendons with preserved distal insertions: two case reports. *BMC Res Notes.* 2013;6:361.
18. Van der Bracht H, Verdonk R, Stuyts B. Augmentation of a patellar tendon repair with an autologous semitendinosus graft. *Acta Orthop Belg.* 2009;75(3):417-419.
19. Van der Zwaal P, Van Arkel ERA. Recurrent patellar tendon rupture: reconstruction using ipsilateral gracilis and semitendinosus tendon autografts. *Injury.* 2007;38:320-323.