


BMJ Open ThOracic Ultrasound in Idiopathic Pulmonary Fibrosis Evolution (TOUPIE): research protocol of a multicentric prospective study

Sylvie Legué,^{1,2} Sylvain Marchand-Adam,^{1,3} Laurent Plantier,^{1,3} Betsega Assefa Bayeh,¹ Hugues Morel,^{2,4} Gilles Mangiapan,^{2,5} Thomas Flament ^{1,2}

To cite: Legué S, Marchand-Adam S, Plantier L, *et al.* ThOracic Ultrasound in Idiopathic Pulmonary Fibrosis Evolution (TOUPIE): research protocol of a multicentric prospective study. *BMJ Open* 2021;**11**:e039078. doi:10.1136/bmjopen-2020-039078

► Prepublication history for this paper is available online. To view these files, please visit the journal online (<http://dx.doi.org/10.1136/bmjopen-2020-039078>).

Received 04 April 2020
Revised 04 February 2021
Accepted 18 February 2021



© Author(s) (or their employer(s)) 2021. Re-use permitted under CC BY-NC. No commercial re-use. See rights and permissions. Published by BMJ.

¹Pulmonology Unit, CHRU Tours, Tours, Centre, France

²Chest Ultrasound Working Group (G-ECHO), Societe de Pneumologie de Langue Francaise, Paris, Île-de-France, France

³U1100, INSERM, Tours, France

⁴Pulmonology Unit, CHR Orleans, Orleans, Centre, France

⁵Pulmonology Unit, Centre Hospitalier Intercommunal de Créteil, Creteil, Île-de-France, France

Correspondence to

Sylvie Legué;
legue.sylvie@gmail.com

ABSTRACT

Introduction Idiopathic pulmonary fibrosis (IPF) is the most common and severe interstitial lung disease (ILD). It is a progressive disease that requires a regular follow-up: clinical examination, pulmonary function testing (PFT) and CT scan, which is performed yearly in France. These exams have two major disadvantages: patients with severe dyspnoea have difficulties to perform PFT and repeated CT scans expose to high dose of radiations. Considering these limits, it would be relevant to develop new tools to monitor the progression of IPF lesions. Three main signs have been described in ILD with lung ultrasound (LUS): the number of B lines, the irregularity and the thickening of the pleural line. Cross-sectional studies already correlated the intensity of these signs with the severity of fibrosis lesions on CT scan in patients with IPF, but no prospective study described the evolution of the three main LUS signs, nor the correlation between clinical evaluation, PFT and CT scan. Our hypothesis is that LUS is a relevant tool to highlight the evolution of pulmonary lesions in IPF. The main objective of our study is to show an increase in one or more of the three main LUS signs (total number of B lines, pleural line irregularity score and pleural line thickness) during the follow-up.

Methods ThOracic Ultrasound in Idiopathic Pulmonary Fibrosis Evolution is a French prospective, multicentric and non-interventive study. Every 3 months, patients with IPF will have a clinical examination, PFT and LUS. CT data will be collected if the CT scan is performed within 3 months before the inclusion; the second CT scan will be performed from 9 to 12 months after the inclusion. The presence, location and severity of LUS signs will be recorded for each patient, and their correlation with clinical, functional and CT scan evolution will be evaluated. 30 patients will be enrolled.

Ethics and dissemination The protocol was approved by the French Research Ethics Committee (Comité de Protection des Personnes SUD OUEST ET OUTRE MER II, reference RIPH3-RNI19-TOUPIE) on 11 April 2019. Results will be disseminated via peer-reviewed publication and presentation at international conferences.

Trial registration number NCT03944928; Pre-results.

INTRODUCTION

Idiopathic pulmonary fibrosis (IPF) is one of the most common interstitial lung diseases

Strengths and limitations of this study

- This is the first prospective study designed to describe the evolution of the three main echographic signs of interstitial lung disease during follow-up of patients with idiopathic pulmonary fibrosis.
- Its multicentric nature may decrease intrastitutional bias.
- Study endpoints are measured during usual follow-up visits of each patient and do not require additional visits to the benefit of feasibility.
- Lack of precise time matching of CT and lung ultrasound; this is an important limitation that precludes precise analysis of radiological–ultrasound correlations (but lung function tests done on the same day).
- The cohort is small, and the exploratory and positive findings would need to be confirmed in larger studies.

(ILD). IPF is an active pathology characterised by a rapid worsening of pulmonary fibrosis lesions that are irreversible.¹ To date, there are two main antifibrotic treatments (pirfenidone and nintedanib) that slow down the decline in respiratory function without allowing recovery or improving respiratory functional capacity.^{2,3} Due to a poor prognosis and a rapid evolution of the pathology, close monitoring of patients is essential in order to identify at an early stage the worsening of fibrosis lesions and respiratory function and then allow a therapeutic adjustment as fast as possible. Thus, patients with IPF require regular follow-up through clinical examination, pulmonary function testing (PFT) and CT scan.

The PFT are done before each medical consultation. Measuring the forced vital capacity (FVC) and the diffusion capacity of carbon monoxide (DLCO) helps assess the functional impact of interstitial involvement.

The decline in FVC and DLCO reflect a worsening of the disease.^{2,3} These conditions require the patient's cooperation and cannot be achieved in patients with severe respiratory failure with an FVC of less than 1 L. The high-resolution thoracic CT scan in millimetre sections is important for the initial diagnosis of IPF lesions. Doing an annual CT scan without injection and low dose is proposed by French recommendations to screen lung cancer in this population at risk.⁴ There are many disadvantages to the repetition of CT scans in patients with IPF: the repeated irradiation, the accessibility and sometimes the difficulties related to the supine position for patients with severe dyspnoea. Considering these limits, it is relevant to suggest other monitoring tools allowing the detection of the progression of IPF lesions. Lung ultrasound (LUS) has long been considered poorly applicable to examine the lung due to the presence of air, which attenuates the ultrasound beam. However, the description of artefacts and their analysis has enabled the establishment of an ultrasound semiology of the lung, which has been gradually enriched in recent years.⁵ The elementary findings detectable are artefacts generated from the thickened interlobular septa at lung surface level. LUS was applied in the evaluation of ILD in connective tissue disorders.⁶⁻⁹ Three main ultrasound signs are described in interstitial lesions: the B lines score, defined by the total number of B lines, the pleural line irregularity and the pleural line thickness.^{7,8,10} Each of these three signs has shown a strong correlation between the intensity of the LUS score and, on one hand, the severity of fibrosis lesions on CT scan and, on the other hand, the severity of the PFT.^{7,10-12} Two studies have evaluated LUS in IPF. Vassalou *et al*¹³ have showed significant correlation between B lines and the Warrick's score in 26 patients with IPF. A recent study has showed a positive and significant correlation between the total number of B lines and the pleural thickness with a CT scan fibrotic score in 31 patients with IPF.¹⁴ These studies have evaluated the intensity of an ultrasound sign at one moment in the patient's management. However, no studies have prospectively described the evolution of

ultrasound signs in the same patient with IPF or their correlation to clinical, functional and CT scan evolution.

Thus, to our knowledge, this is the first study to describe the evolution of the three main LUS signs during follow-up of patients with IPF.

We hypothesise that LUS could be a relevant tool to highlight the evolution of pulmonary lesions in IPF by the combined analysis of three ultrasound signs: the B line score, the pleural line irregularity score and the pleural line thickness.

Objectives

The main objective of the TOUPIE study is to show with LUS an increase in one or more of the ultrasound signs during the follow-up of a patient with IPF.

The secondary objectives are: (1) to evaluate the reproducibility of the measurements of the ultrasound signs, (2) to evaluate the association between the severity of each ultrasound sign and the severity of the clinical, functional and CT scores and (3) to evaluate the association between the measurement of each ultrasound sign made during a standard protocol exploring 14 thoracic areas and a simplified protocol exploring six thoracic areas.

METHODS AND ANALYSIS

Study design

TOUPIE study (figure 1) is a non-interventional, multi-centre, prospective trial evaluating patients followed for IPF. The study is planned for a 3-year duration with a recruitment period of 24 months (beginning 11 June 2019) and a 12-month follow-up period for each patient. LUS and PFTs are to be performed every 3 months for 12 months, and CT scan is performed yearly in our centre. The study protocol is reported according to the Strengthening the Reporting of Observational Studies in Epidemiology guidelines.

Study setting

Patients will be selected for recruitment by trained lung specialists in the rare pulmonary disease competence

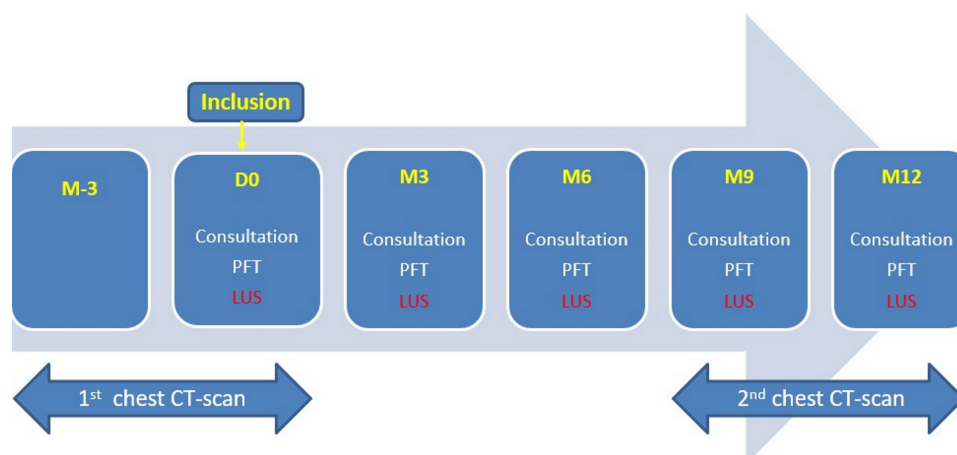


Figure 1 TOUPIE study design. TOUPIE, ThOracic Ultrasound in Idiopathic Pulmonary Fibrosis Evolution.

centre of the university hospital of Tours and the hospital of Orléans, which are collaborating to improve clinical care, education and research in the field of rare pulmonary diseases.

Patient recruitment

Inclusion criteria

- ▶ Older than 18 years old.
- ▶ Diagnosis of IPF validated in a multidisciplinary consultation meeting according to French recommendations.
- ▶ Ability for subject to comply with the requirements of the study.

Non-inclusion/exclusion criteria

- ▶ other forms of ILD, included combined forms of IPF (eg, combined pulmonary fibrosis and emphysema).
- ▶ Exacerbation of IPF in the previous 4 weeks.
- ▶ Diagnosis of chronic left heart failure with left ventricular ejection fraction (LVEF) <50%.
- ▶ Pulmonary infectious disease in the previous 3 weeks.
- ▶ Diagnosis of lung or pleural cancer.
- ▶ Pregnant or breastfeeding women.
- ▶ Opposition to the data collection.

Temporary exclusion criteria (cancelling a visit)

- ▶ Fibrosis exacerbation occurring in the previous 4 weeks.
- ▶ Recent low respiratory infection occurring in the previous 3 weeks.
- ▶ Patients showing clinical signs of left or right heart failure requiring diuretics treatment.

Interventions

Pulmonary function test

The evolution of functional parameters will be done through the use of FVC and DLCO. As commonly used in the literature,^{2 15} the threshold of the variation of FVC and DLCO (10% for FVC, 15% for DLCO) will be used to define disease progression. Furthermore, the composite physiological index (CPI) will be calculated. It is a predictive mortality score used in IPF.¹⁶ This algorithm includes the values of FVC, DLCO and forced expiratory volume in 1 s (FEV₁). The CPI is calculated as follows: $CPI = 91.0 - (0.65 \times DLCO \text{ percentage of theoretical value } [\% \text{ theoretical}]) - (0.53 \times FVC \% \text{ theoretical}) + (0.34 \times FEV_1 \% \text{ theoretical})$. Since the CPI combines both FVC and DLCO, we hypothesise that the CPI may provide a single metric to study correlations between LUS signs and lung function. Moreover, the CPI has never been used to define disease progression in previous studies that is why it will be calculated as an exploratory analysis. It will be calculated at each follow-up visit, after realisation of the PFT.

Chest CT scan technique and analysis

At our centre, patients with IPF undergo yearly CT scans. To allow correlation analysis between LUS signs and CT signs, patients will be included within 3 months of the last CT scan. The CT examination is carried out according

to the usual protocol. Images are acquired while maintaining apnoea from the apex of the lung to the bases. The patient is placed in supine position. The CT sections obtained are millimetre spaced 7–10 mm apart. Chest CT scans are usually performed without injecting iodinated contrast media.

CT anomalies will be analysed by an experienced radiologist to establish the Warrick score. He will be blinded with clinical, functional and ultrasound data. The Warrick score is most frequently used to assess the extent and severity of interstitial involvement in pulmonary fibrotic pathologies, mostly in ILD.^{9 17 18} First, different abnormalities are described (ground-glass opacities, irregular pleural margin, septal or subpleural lines, honeycombing and subpleural cyst) to calculate the severity score. Second, the extent is determined based on the total number of bronchopulmonary segments involved for each abnormality. The greater the number of segments involved, the higher the extent score. These scores are combined to obtain a global score.¹⁹

The Warrick score will be calculated for each patient.

LUS examination

Three main LUS signs are described in IPF: the total number of B lines previously called ‘comet tail’, the irregularity of the pleural line and the thickening of the pleural line (table 1).

B lines are described as vertical hyperechoic reverberation artefacts from the pleural line, extending to the bottom of the screen without attenuation and moving with breathing (figure 2). The irregularity of the pleural line is defined as a loss of the linear contour of the hyperechoic pleural line (figure 3). The pleural line is considered thickened and abnormal when it exceeds 3 mm (figure 4).

A convex probe (1–5 MHz) will be used. The patient will be placed in right lateral decubitus then left. LUS will be timed, recorded and anonymised. It will be practised by experienced sonographers and according to a validated protocol, allowing the exploration of 14 thoracic areas (figure 5). As per common practice in ultrasound studies, two rereadings of LUS images will be done. One rereading will be done by the same operator to measure intrareader variability. A second rereading will be performed by an independent reader to measure inter-reader variability. Habitually in ultrasound studies, a delay of a few hours to 3 months is proposed between rereadings.²⁰ Our choice of delay is 15 days to measure the intrareader variability in order to limit this bias. LUS and CT scan operators are different people. The CT scan reader is blinded of the PFT and LUS information.

The presence, location and severity of ultrasound signs will be recorded for each patient during successive reassessments, and the correlation to clinical, functional and CT scan evolution will be studied.

Outcomes

The primary endpoint is:

Table 1 Summary of the diagnostic criteria for the three main ultrasound signs

LUS signs	
Diagnostic criteria	B lines
Positive diagnostic criteria	Vertical hyperechoic line, and appearing below the pleural line, and extending to the bottom of the screen without attenuation, and moving with breathing.
Negative diagnostic criteria	Vertical hyperechoic line interrupted before the bottom of the screen (=Z line).
Irregularity of the pleural line	Horizontal hyperechoic line, and appearing below the chest wall, and having lost its regular linear contour.
Thickening of the pleural line	Horizontal hyperechoic line, and appearing below the chest wall, and it exceeds 3 mm in its smallest thickness.
Typical images	Horizontal hyperechoic line appearing in the chest wall, or horizontal hyperechoic line appearing in the lung area on the US screen, or horizontal hyperechoic line with regular linear contour.
Presentation of results	Sum of the number of B lines in all thoracic areas.
	For each thoracic area, the thickness of the pleural line is given in millimetres.

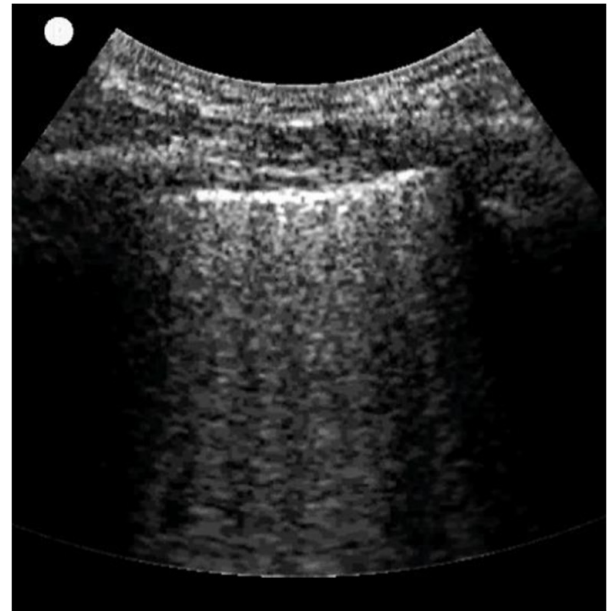
LUS, lung ultrasound.

**Figure 2** Iconography from the TOUPIE study illustrating the presence of B lines in patients with IPF: B lines between 8 and 10/field. IPF, idiopathic pulmonary fibrosis; TOUPIE, ThOracic Ultrasound in Idiopathic Pulmonary Fibrosis Evolution.

1. Change of the total number of B lines from inclusion to 12 months.
2. Change of pleural line percentage irregularity (number of thoracic areas with irregularity/ total number of thoracic areas) from inclusion to 12 months.
3. Change of pleural line thickness in millimetres from inclusion to 12 months.

The secondary endpoints are:

- ▶ The measurement of intrareader and inter-reader variability of the three ultrasound signs.
- ▶ The study of the correlation between:
 - The total number B lines and:
 - FCV and DLCO.
 - The CPI.
 - The Warrick's CT scan score.



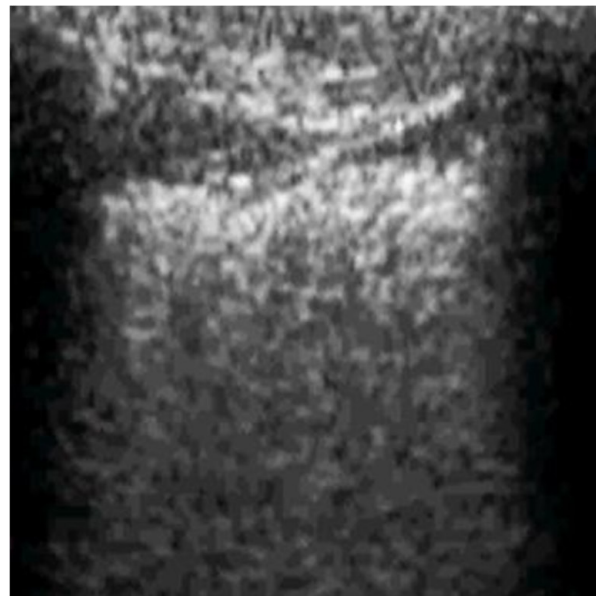
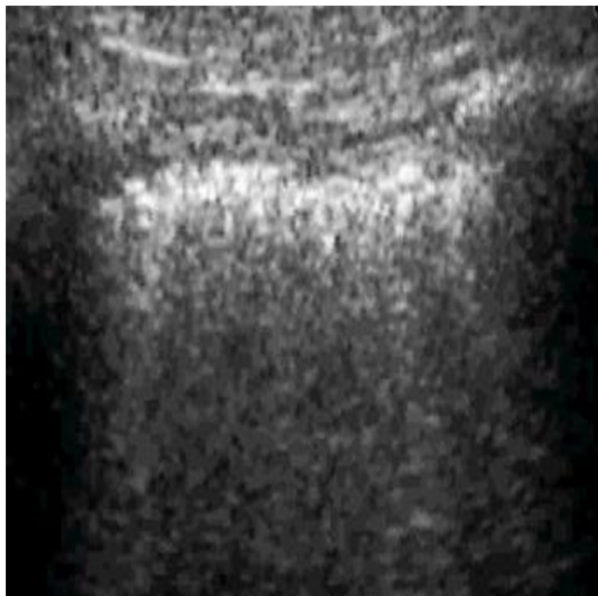


Figure 3 Iconography from the TOUPIE study illustrating the pleural line anomalies in patients with IPF: blurred, irregular, discontinuous pleural line. IPF, idiopathic pulmonary fibrosis; TOUPIE, ThOracic Ultrasound in Idiopathic Pulmonary Fibrosis Evolution.



Figure 4 Iconography from the TOUPIE study illustrating the thickening of the pleural line in patients with IPF: pleural line >5 mm. IPF, idiopathic pulmonary fibrosis; TOUPIE, ThOracic Ultrasound in Idiopathic Pulmonary Fibrosis Evolution.

- The irregularity pleural score and:
 - FCV and DLCO.
 - The CPI.
 - The Warrick's CT scan score.
- The measurement of pleural thickness and:
 - FCV and DLCO.
 - The CPI.
 - The Warrick's CT scan score.
- ▶ The study of the correlation between the total number B lines, the pleural irregularity score and the pleural thickness measured on 14 thoracic areas and on 6 thoracic areas.

Study procedures

Patients will be included in the study after informed signed consent. The duration of the study for each

patient will be of 12 months. Patients will be included during a follow-up visit. In accordance with usual practices, patients will be reassessed every 3 months. Within the protocol, each visit will include the same day, as part

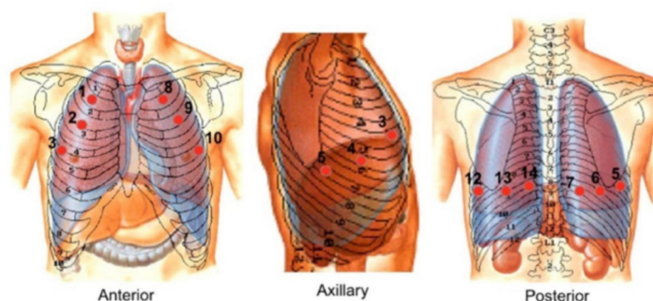


Figure 5 Thoracic areas scanned.

of routine care: performing PFT with calculation of the CPI score, a clinical examination, then afterwards, carrying out a LUS examination as part of the research according to the protocol described previously. Usually, all patients followed for IPF perform an annual CT scan as established by French recommendations.⁴ Inclusion in the protocol does not require an additional chest CT scan, because this is a non-interventional study. CT data were collected if the CT scan was performed within 3 months before inclusion; the second scan is performed between 9 and 12 months after inclusion. The second scan will compare the evolution of the CT lesions with LUS signs evolution.

Sample size calculation

As this is an exploratory study, there is not enough data allowing a formal calculation of the number of subjects needed on statistical hypotheses. We anticipate the inclusion of 30 patients with IPF. A sample size of 30 patients may not be strong enough to show differences in the study outcomes. Moreover, most studies about LUS in IPF have similar cohort sizes.¹⁴ Since this is the first prospective study of this nature, the data may be still helpful for the medical community.

Statistical analysis

The data set will be analysed, and the analysis will include all patients who have performed at least two ultrasound examinations with the corresponding PFT and two CT scans. Missing values will not be replaced by estimated values but will be considered missing in the statistical analysis. The results will be considered statistically significant if $p < 0.05$.

The individual evolution profiles of the three selected ultrasound signs will be displayed using a spaghetti plot. The average changes over time of the three ultrasound signs selected will be modelled using a mixed linear model taking into account:

- ▶ The correlation of repeated measurements at different follow-up times for the same subject (longitudinal data), that is, intrasubject variability.
- ▶ The subject effect by the random intercept and the random slope over time, that is, the intersubject variability (profiles at inclusion and variable evolutions).

The parameters of interest will be the coefficients estimated over the follow-up time (12 months), for the three ultrasound signs measured repeatedly.

The study of the correlation between FCV, DLCO and the CPI functional score, the Warrick CT score and the LUS results will be calculated using the Spearman correlation coefficient (rho coefficient) accompanied by its 95% CI. To assess the intrareader and inter-reader reproducibilities, we will estimate coefficients of intra-class correlations with their CI at 95%. We will also use graphical representations of Bland and Altman.

Data management and quality control

Data from source documents will be captured into the protocol-specific electronic case report form by the site study personnel. A data review will be done prior to locking the database. An audit may be performed at any time by people appointed by the sponsor who are independent of those responsible for the study.

Adverse events reporting

The promoter qualifies this first-line research as non-interventional. Indeed, external ultrasound is one of the collection techniques authorised within the collection techniques using non-invasive extracorporeal sensors. In addition, chest ultrasound scans are now used regularly in consultation with patients with IPF, in particular to look for an aetiology during clinical deterioration or acute respiratory failure (pneumonia, heart failure, pneumothorax and so on).

Ethics, approval and dissemination

The protocol was approved by an independent French ethics committee (Comité de Protection des Personnes SUD OUEST ET OUTRE MER II, reference RIPH3-RNI19-TOUPIE) on 11 April 2019. The study protocol is registered on ClinicalTrials.gov. An independent Data and Safety Monitoring Board with at least three members with expertise in lung diseases, biostatistics and clinical pharmacology, independent from the sponsor, will meet regularly and whenever necessary to review safety data and make recommendations about the continuation, amendments or termination of the clinical trial. Any written or oral communication of the research results must be approved by the research coordinating investigator and, where appropriate, in collaboration with the associated scientists. The publication of the main results must cite the promoter.

The recommendations 'Recommendations for the Conduct, Reporting, Editing, and Publication of Scholarly Work in Medical Journals' (updated December 2015) from the International Committee of Medical Journal Editors will be followed.

Participant confidentiality and data protection

In accordance with French laws and regulations, research staff with direct access to source data will take all necessary precautions to ensure the confidentiality of information. All information regarding participants forwarded to the sponsor will be made anonymous. All data transferred between sites will be encrypted, and no individual will be identifiable from the stored data. Identifiable patient information will be stored in a locked cabinet, accessible only by research members at the site of the data collection. All original records will be archived at trial sites for 15 years. The clean database file will be anonymised and kept for 15 years.

Patients and public involvement

Patients and/or public were not involved in the study design, recruitment or conduct of the study.

DISCUSSION

To our knowledge, this is the first study describing the evolution of several ultrasound signs over time in the same patient with IPF. This will allow the acquisition of new knowledge in the field of chest ultrasound.

If a correlation between the ultrasound signs and the functional and CT scan scores is confirmed, the early detection of the ultrasound signs of worsening of the interstitial changes will constitute an additional argument for an earlier evaluation by CT scan or even the initiation of a treatment to limit the spread of irreversible fibrosis lesions. Conversely, in case of stability of the ultrasound signs, CT scans to control fibrosis lesions could be spaced to limit the irradiation of patients.

The second analysis of the ultrasound signs on six thoracic areas may lead to the implementation of a simplified protocol, which is faster to perform.

If the LUS signs are significantly correlated with functional or CT scan scores, a composite LUS score could be created. This will be assessed in further studies.

The information collected during this study will reflect interstitial involvement in the basal state. In future studies, IPF LUS patterns at the stable state may be compared with LUS patterns during IPF exacerbations or other causes of acute respiratory failure such as pneumonia or heart failure.

Concerning the diagnosis of IPF, the protocol was written in 2017, before the most recent ATS/ERS/JRS/ALAT guidelines were published.¹ Thus, the 2017 French society, which are very similar to the 2013 revised ATS/ERS guidelines for diagnosis of IPF,^{4 21} appeared as the best method to define IPF. Actually, to best translate study results to current international practice, we will report whether each patient fulfils the current 2018 ATS/ERS/JRS/ALAT criteria for a diagnosis of 'IPF', 'Likely IPF', 'Indeterminate' or 'other diagnosis'. In case a number of patients do not fulfil these criteria, which we deem unlikely, data analysis will be repeated restricted to patients who do and reported. In addition, key criteria for 2013 ATS/ERS¹¹, 2017 French society and 2018 ATS/ERS/JRS/ALAT guidelines were summarised in online supplemental table 1.

We choose to evaluate at the same time the evolution of the three most studied ultrasound signs in ILDs and for which a correlation has been demonstrated with the clinical parameters or CT data.^{7 8 10 12} The number of B lines is the first ultrasound sign described in interstitial syndrome and the most studied. Numerous studies have shown a correlation between the number of B lines and CT scores, especially in IPF.¹³ This sign presents a good sensitivity and a very good negative predictive value, which makes it particularly interesting for the screening of IPF.²² However, it is not very specific. That is why other LUS signs need to be evaluated. Pleural thickness has been studied in patients with IPF, and a positive correlation was shown between pleural thickness and CT score.⁷ Finally, the pleural irregularity was studied in several studies with heterogeneous populations with ILD, including IPF.^{10 23–25}

Others LUS signs were described like subpleural cysts or Am-lines but not especially in IPF.^{23 26}

The study has several limitations. First, the lack of precise time matching of CT and LUS; this is an important limitation that precludes precise analysis of radiological–ultrasound correlations (but lung function done on same day). CT scan is done within 0–3 months before the LUS time point. There is therefore a time lag between the images of the CT scan and the LUS images. Our study is observational and no interventional study. It was not possible to add a CT scan on the same day as the LUS. However, we do not want to compare the images of CT scan and LUS but the evolution of these images during the follow-up. Patients with IPF at our centre undergo yearly CT scan. This will allow to compare 12-month changes in CT scan with 12-month changes in LUS. Second, the small sample size is another limitation of our study. It may be difficult to enrol this population for several reasons: IPF is a rare disease, the median survival time is of 2–5 years after diagnosis and patients can die during this 1-year follow-up study. As this is an exploratory study, there is not enough data allowing a formal calculation of the number of subjects needed on statistical hypotheses. Since this is the first prospective study of this nature, the data may be still helpful for the medical community. The exploratory and positive findings would need to be confirmed in larger studies.

Thus, chest ultrasound could constitute an additional monitoring tool for IPF, which is a rapidly progressive disease, usable by the pulmonologist at the patient's bedside or during a consultation, easily available, non-irradiating, achievable in a short time and immediately informative, for a trained sonographer.

Acknowledgements The authors would like to thank Katia Desplobain and Elodie Mureau, from the Centre of Clinical Investigations (CIC de Tours) and Gaelle Fajole from ERIC (Equipe de Renforcement de l'Investigation Clinique) for their help in piloting patients' inclusion in the study.

Contributors TF is the principal investigator of the ThOraic Ultrasound in Idiopathic Pulmonary Fibrosis Evolution (TOUPIE) study. TF and SL conceived the research and wrote the first draft of the protocol. SM-A, LP, HM, GM and BAB made significant revisions to the manuscript. All authors read and approved the final version of the manuscript.

Funding The authors have not declared a specific grant for this research from any funding agency in the public, commercial or not-for-profit sectors.

Competing interests None declared.

Patient consent for publication Not required.

Provenance and peer review Not commissioned; externally peer reviewed.

Supplemental material This content has been supplied by the author(s). It has not been vetted by BMJ Publishing Group Limited (BMJ) and may not have been peer-reviewed. Any opinions or recommendations discussed are solely those of the author(s) and are not endorsed by BMJ. BMJ disclaims all liability and responsibility arising from any reliance placed on the content. Where the content includes any translated material, BMJ does not warrant the accuracy and reliability of the translations (including but not limited to local regulations, clinical guidelines, terminology, drug names and drug dosages), and is not responsible for any error and/or omissions arising from translation and adaptation or otherwise.

Open access This is an open access article distributed in accordance with the Creative Commons Attribution Non Commercial (CC BY-NC 4.0) license, which permits others to distribute, remix, adapt, build upon this work non-commercially, and license their derivative works on different terms, provided the original work is

properly cited, appropriate credit is given, any changes made indicated, and the use is non-commercial. See: <http://creativecommons.org/licenses/by-nc/4.0/>.

ORCID iD

Thomas Flament <http://orcid.org/0000-0003-0258-7856>

REFERENCES

- Raghu G, Remy-Jardin M, Myers JL, et al. Diagnosis of idiopathic pulmonary fibrosis. An official ATS/ERS/JRS/ALAT clinical practice guideline. *Am J Respir Crit Care Med* 2018;198:e44–68.
- King TE, Bradford WZ, Castro-Bernardini S, et al. A phase 3 trial of pirfenidone in patients with idiopathic pulmonary fibrosis. *N Engl J Med* 2014;370:2083–92.
- Richeldi L, du Bois RM, Raghu G, et al. Efficacy and safety of nintedanib in idiopathic pulmonary fibrosis. *N Engl J Med* 2014;370:2071–82.
- Cottin V, Crestani B, Cadranet J. [French practical guidelines for the diagnosis and management of idiopathic pulmonary fibrosis. 2017 update. Full-length update]. *Rev Mal Respir* (Published Online First: 21 September 2017).
- Volpicelli G, Elbarbary M, Blaivas M, et al. International evidence-based recommendations for point-of-care lung ultrasound. *Intensive Care Med* 2012;38:577–91.
- Gargani L, Doveri M, D'Errico L, et al. Ultrasound lung comets in systemic sclerosis: a chest sonography hallmark of pulmonary interstitial fibrosis. *Rheumatology* 2009;48:1382–7.
- Sperandeo M, De Cata A, Molinaro F, et al. Ultrasound signs of pulmonary fibrosis in systemic sclerosis as timely indicators for chest computed tomography. *Scand J Rheumatol* 2015;44:389–98.
- Tardella M, Di Carlo M, Carotti M, et al. Ultrasound B-lines in the evaluation of interstitial lung disease in patients with systemic sclerosis: cut-off point definition for the presence of significant pulmonary fibrosis. *Medicine* 2018;97:e0566.
- Gutierrez M, Salaffi F, Carotti M, et al. Utility of a simplified ultrasound assessment to assess interstitial pulmonary fibrosis in connective tissue disorders--preliminary results. *Arthritis Res Ther* 2011;13:R134.
- Pinal-Fernandez I, Pallisa-Nuñez E, Selva-O'Callaghan A, et al. Pleural irregularity, a new ultrasound sign for the study of interstitial lung disease in systemic sclerosis and antisynthetase syndrome. *Clin Exp Rheumatol* 2015;33:S136–41.
- Wang Y, Gargani L, Barskova T, et al. Usefulness of lung ultrasound B-lines in connective tissue disease-associated interstitial lung disease: a literature review. *Arthritis Res Ther* 2017;19:206.
- Gutierrez M, Tardella M, Rodriguez L, et al. Ultrasound as a potential tool for the assessment of interstitial lung disease in rheumatic patients. where are we now? *Radiol Med* 2019;124:989–99.
- Vassalou EE, Raissaki M, Magkanas E. Lung ultrasonography in patients with idiopathic pulmonary fibrosis: evaluation of a simplified protocol with High-Resolution computed tomographic correlation. *J Ultrasound Med* (Published Online First: 6 September 2017).
- Manolescu D, Oancea C, Timar B, et al. Ultrasound mapping of lung changes in idiopathic pulmonary fibrosis. *Clin Respir J* 2020;14:54–63.
- Flaherty KR, Fell CD, Huggins JT, et al. Safety of nintedanib added to pirfenidone treatment for idiopathic pulmonary fibrosis. *Eur Respir J* 2018;52:1800230.
- Lee SH, Park JS, Kim SY, et al. Comparison of Cpl and gap models in patients with idiopathic pulmonary fibrosis: a nationwide cohort study. *Sci Rep* 2018;8:4784.
- Gigante A, Rossi Fanelli F, Lucci S, et al. Lung ultrasound in systemic sclerosis: correlation with high-resolution computed tomography, pulmonary function tests and clinical variables of disease. *Intern Emerg Med* 2016;11:213–7.
- Vassalou EE, Raissaki M, Magkanas E, et al. Modified lung ultrasonographic technique for evaluation of idiopathic pulmonary fibrosis: lateral decubitus position. *J Ultrasound Med* 2017;36:2525–32.
- Diot E, Boissinot E, Asquier E, et al. Relationship between abnormalities on high-resolution CT and pulmonary function in systemic sclerosis. *Chest* 1998;114:1623–9.
- Pinedo M, Villacorta E, Tapia C, et al. Inter- and intra-observer variability in the echocardiographic evaluation of right ventricular function. *Rev Esp Cardiol* 2010;63:802–9.
- Travis WD, Costabel U, Hansell DM, et al. An official American thoracic Society/European respiratory Society statement: update of the International multidisciplinary classification of the idiopathic interstitial pneumonias. *Am J Respir Crit Care Med* 2013;188:733–48.
- Barskova T, Gargani L, Guiducci S, et al. Lung ultrasound for the screening of interstitial lung disease in very early systemic sclerosis. *Ann Rheum Dis* 2013;72:390–5.
- Buda N, Piskunowicz M, Porzezińska M, et al. Lung Ultrasonography in the Evaluation of Interstitial Lung Disease in Systemic Connective Tissue Diseases: Criteria and Severity of Pulmonary Fibrosis - Analysis of 52 Patients. *Ultraschall Med* 2016;37:379–85.
- Asano M, Watanabe H, Sato K, et al. Validity of ultrasound lung Comets for assessment of the severity of interstitial pneumonia. *J Ultrasound Med* 2018;37:1523–31.
- Moazedi-Fuerst FC, Kielhauser SM, Scheidl S, et al. Ultrasound screening for interstitial lung disease in rheumatoid arthritis. *Clin Exp Rheumatol* 2014;32:199–203.
- Cogliati C, Antivalle M, Torzillo D, et al. Standard and pocket-size lung ultrasound devices can detect interstitial lung disease in rheumatoid arthritis patients. *Rheumatology* 2014;53:1497–503.