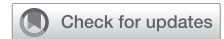

## Painless Urethral Bleeding During Penile Erection in an Adult Man With Klippel-Trenaunay Syndrome: A Case Report



Hongen Lei, MD, PhD, Xing Guan, MD, Hu Han, MD, Xiaosong Qian, MD, Xiaoguang Zhou, MD, Xiaodong Zhang, MD, PhD, and Long Tian, MD, PhD

### ABSTRACT

**Introduction:** Klippel-Trenaunay syndrome (KTS) is a rare congenital vascular disorder characterized by a triad of cutaneous port wine capillary malformations, varicose veins, and hemihypertrophy of bone and soft tissues.

**Aims:** To report on a rare case of KTS in an adult man manifested by painless urethral bleeding during penile erection briefly review the clinical presentation and management of the genitourinary forms of this syndrome.

**Methods:** On presentation, the clinical features of this patient, including medical history, signs and symptoms, and imaging examinations, were recorded. After diagnosis and initial treatment, a literature review of the urethral features of KTS was performed and is discussed in this report.

**Results:** A 35-year-old man with KTS presented with painless urethral bleeding during penile erection that was associated with posterior urethral vascular malformations. The coagulation method was used to treat the malformation, and no urethral bleeding or gross hematuria occurred during a postoperative follow-up period of 6 months.

**Conclusion:** This case demonstrates that coagulation therapy and careful follow-up can be adequate treatment approaches for urethral features of KTS. However, the long-term efficacy of coagulation for this disorder should be investigated further. **Lei H, Guan X, Han H, et al. Painless Urethral Bleeding During Penile Erection in an Adult Man With Klippel-Trenaunay Syndrome: A Case Report. Sex Med 2018;6:180–183.**

Copyright © 2018, The Authors. Published by Elsevier Inc. on behalf of the International Society for Sexual Medicine. This is an open access article under the CC BY-NC-ND license (<http://creativecommons.org/licenses/by-nc-nd/4.0/>).

**Key Words:** Urethral Bleeding; Klippel-Trenaunay Syndrome; Vascular Malformation; Posterior Urethra; Genitourinary Manifestation

### INTRODUCTION

Klippel-Trenaunay syndrome (KTS) is a rare congenital vascular disorder characterized by a triad of cutaneous port wine capillary malformations, varicose veins, and hemihypertrophy of bone and soft tissues.<sup>1</sup> Its incidence is approximately 1 in 30,000 live births, and 75% of patients will have symptoms before 10 years of age.<sup>2</sup> The etiology of this syndrome is not fully understood, and abnormality of the mesodermal tissues is suggested to affect angiogenesis during embryologic development.

Patients can be diagnosed with KTS with only 1 or 2 features, with 63% of patients reported to have all 3 features and 37% reported to have 2 of the 3 features.<sup>3</sup> The gastrointestinal tract and

genitourinary system are commonly affected in this syndrome. Genitourinary manifestations of KTS can affect the bladder, penis, scrotum, vagina, or vulva and occur as intrapelvic and retroperitoneal vascular malformations.<sup>4</sup> In general, 23% to 30% of patients with KTS will have genitourinary vascular anomalies, and 3% to 6% of patients with KTS will have urinary tract hemangioma.<sup>2,5</sup>

We report on a rare case of KTS in an adult man manifested by painless urethral bleeding during penile erection. A brief review of the clinical presentation and management of the genitourinary forms of this syndrome is included.

### CASE REPORT

A 35-year-old man was admitted to our andrology department because of painless urethral bleeding during penile erection. The symptom of transient dark-red urethral bleeding with no pain during a nocturnal penile tumescence had recurred 3 times since the patient was 26 years old. Further, no gross hematuria or abnormal urination had developed subsequently. The patient underwent hemorrhoid surgery 9 years previously and had no other remarkable medical history.

Received October 25, 2017. Accepted December 30, 2017.

Department of Urology, Beijing Chao-Yang Hospital, Capital Medical University, Beijing, China

Copyright © 2018, The Authors. Published by Elsevier Inc. on behalf of the International Society for Sexual Medicine. This is an open access article under the CC BY-NC-ND license (<http://creativecommons.org/licenses/by-nc-nd/4.0/>).

<https://doi.org/10.1016/j.jsxm.2017.12.001>

Physical examination found typical hemihypertrophy of the right hand and left lower extremity (especially of the 2nd and 3rd fingers and toes), port wine stains on the left thigh and buttock, and varicose malformations on the left lower limb. In addition, the left side of the glans penis was hypertrophic, and the left side of the scrotum was covered with varicose veins. The rest of the clinical examination was unremarkable, and no obvious abnormality was found in blood coagulation function or in other routine laboratory tests. Magnetic resonance imaging showed multiple tortuous blood vessels extensively distributed under the skin of the left buttock and left side of the scrotum. No obvious vascular malformations were seen in the retroperitoneal area or pelvic area at computed tomography.

Elastic compression stockings were used to treat the varices in the left lower extremity. Cystoscopy demonstrated reddish-blue vascular malformations occupying 2/3 of the posterior bladder wall and dome, whereas the anterior bladder wall, trigone, and bladder neck were not involved (Figure 1A, B). Explorative urethroscope examination was performed, and vascular malformations of approximately  $2 \times 2 \text{ cm}^2$  were noted in the posterior urethra 2 cm from the remote end of the verumontanum (Figure 1C). The coagulation method was used to treat the vascular malformations in the posterior urethral area. Under a plasma-kinetic transurethral resectoscope, the varicose veins overlying the urethral mucosal surfaces were electrocoagulated until coagulative necrosis was produced (Figure 1D), whereas malformations in the bladder wall were not touched. No urethral

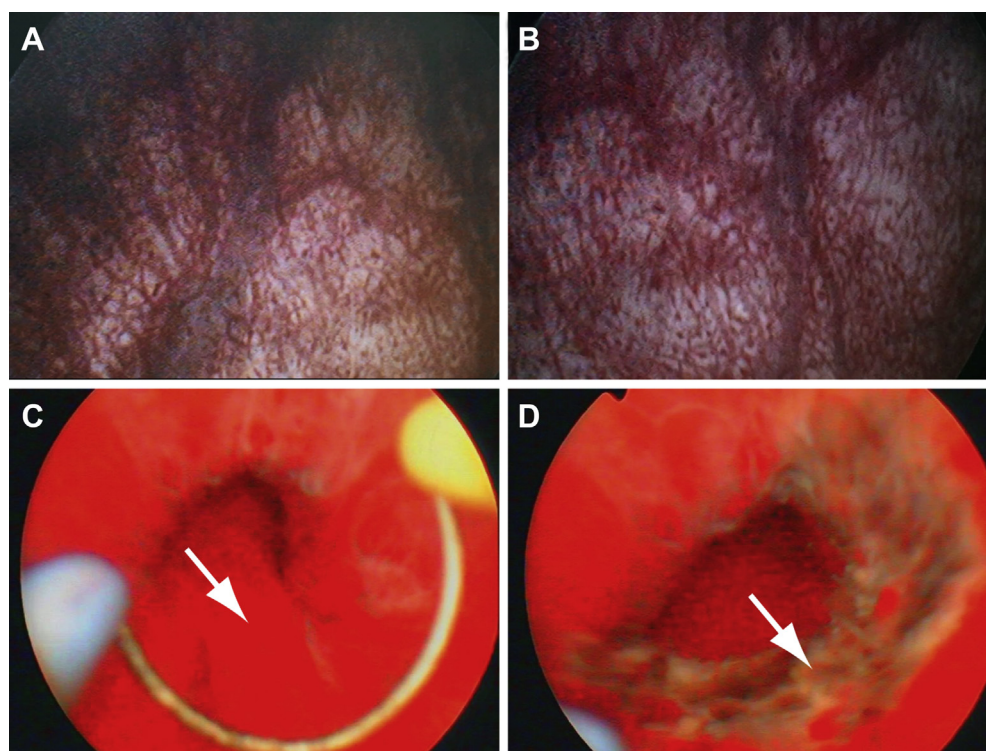
bleeding or gross hematuria occurred during the postoperative follow-up period of 6 months.

This report was approved by the medical ethics committee of the Beijing Chao-Yang Hospital of the Capital Medical University (Beijing, China). Written informed consent was obtained from the patient for the publication of this report and any accompanying images.

## DISCUSSION

Several hypotheses have been reported to explain the pathogenesis of KTS,<sup>6</sup> including congenital spinal cord anomaly, disturbed vasculogenesis, deep vein abnormalities, generalized mesodermal defects, para-dominant inheritance, and a dominant lethal gene surviving by mosaicism. None of these hypotheses can explain KTS completely, because KTS is, in general, a sporadically occurring disorder; moreover, although it has an inclination toward familial aggregation, no causative gene has been found.<sup>7,8</sup>

Manifestations of enlarged arteries and veins, capillary or venous malformations, and limb enlargement are defined as Parkes-Weber syndrome, whereas port wine capillary malformations, vascular malformations, and hemihypertrophy of bone and soft tissues are the 3 typical features of KTS.<sup>9</sup> Parkes-Weber syndrome and KTS are similar, but slow flow venous malformations are predominant in KTS, whereas fast flow arteriovenous fistulas are always found in Parkes-Weber syndrome.<sup>9</sup>



**Figure 1.** Vascular malformations in the bladder wall and posterior urethra. Panels A and B show reddish-blue vascular malformations in the posterior bladder wall and dome, respectively. Panels C and D show vascular malformations (arrows) in the posterior urethra before and after coagulation, respectively.

In some cases considered inverse KTS, venous malformation can affect limb growth in the form of deficiency rather than abundance.<sup>10</sup> Patients with suspected KTS can be evaluated with various diagnostic imaging methods.<sup>11</sup> Doppler ultrasound, computed tomography, and magnetic resonance imaging are effective for visualizing the extent of lesions, infiltration of deeper tissues, and response to treatment. The measurement of long bones can be performed by scanograms or plain film radiographs, and scintigraphy can be used to assess blood flow and bone vascularity.<sup>11</sup> In the present case, the patient, who had clinical manifestations of hemihypertrophy of the limbs, port wine stains, and varicose malformations, was diagnosed as having KTS after consultation with a vascular surgeon.

Individualized therapy should be provided to manage patients with KTS.<sup>12</sup> Conservative treatment should be performed in most patients, with elastic compression stockings frequently used for varices and edema of the extremities and hormonal therapy for women with KTS who have menorrhagia.<sup>2</sup> It is reported that 52% of patients who have urologic manifestations eventually require interventional therapy.<sup>2</sup> Endoscopic cauterization can be used for the management of bladder or urethral vascular malformations, and neodymium:YAG laser has good effects on vesical venous malformations.<sup>13</sup> In addition, arteriographic control, tranexamic acid, and interferon-alpha could be useful to treat hemorrhage and other coagulopathic complications.<sup>13</sup> Patients with KTS have a 50% risk for spontaneous venous thrombosis; regular aspirin, warfarin, and low-molecular-weight heparin therapy could be used, except during acute bleeding or surgical interventions.<sup>2</sup> When vascular malformations affect intrapelvic or retroperitoneal areas or the hematuria is life-threatening, surgical treatments should be adopted, such as partial cystectomy, subtotal cystectomy, or enterocystoplasty using an ileocecal segment.<sup>4</sup> It is suggested that endoscopic resection can cause serious bleeding, and it should not be attempted for treating gross hematuria.<sup>13</sup>

In the present case, painless urethral bleeding during nocturnal penile tumescence was believed to be related to vascular malformations in the posterior urethral wall. Vascular wall tension increases rapidly, and the abnormal venous wall can be ruptured more easily, causing painless urethral bleeding with penile erection. Vascular malformations and hemangiomas have distinctive cellular kinetics and clinical behavior, and the clinical conditions of vascular malformations are common in KTS, whereas hemangiomas occur only rarely in malformation syndromes.<sup>9,14</sup> The tortuous veins in the posterior urethral wall should not recur or regrow after the initial treatment in this patient with KTS, because it has been reported that the growth of the lesion is commensurate with the growth of the child and not with rapid postnatal growth.<sup>9</sup> However, to avoid possible postoperative bleeding or gross hematuria in this patient, electroresection or endoscopic resection should not be used, and no urethral tissue or histopathologic results were obtained before the coagulation

method was performed for the treatment of posterior urethral vascular malformations under urethroscopic guidance.

Patients with port wine stains have been reported to be 3 times more likely to have a visceral genitourinary vascular malformation than patients without abdominal, pelvic, or perineal port wine stains<sup>2</sup>; however, no vascular malformations were found in the retroperitoneal area or pelvic area in this patient. In addition, 2/3 of the posterior bladder wall and dome were found to have reddish-blue vascular malformations, whereas no abnormality was found in areas of the anterior bladder wall, trigone, or bladder neck. The distribution of venous malformations in the urinary bladder was in accordance with a previous report.<sup>1</sup> Painless severe gross hematuria often can be found in patients with this kind of KTS; however, no massive hematuria occurred, and the method of conservative therapy and careful follow-up for cystic vascular malformation was used in this case. However, there are some limitations about the span of follow-up time in this case, and a postoperative follow-up of 6 months might be insufficient because the frequency of symptoms is very low, although no urethral bleeding or gross hematuria occurred in this patient. The long-term efficacy of therapeutic methods for KTS genitourinary features should be investigated further.

## CONCLUSIONS

KTS is a rare syndrome that can cause painless urethral bleeding during penile erection in men because of vascular malformations in the posterior urethral wall. Coagulation was a safe and effective method to treat the urethral bleeding under urethroscopic guidance in this case, and no urethral bleeding or gross hematuria occurred during the 6-month postoperative follow-up period. This demonstrated that coagulation therapy and careful follow-up can be adequate treatment approaches for urethral features of KTS; however, the long-term efficacy should be investigated further.

**Corresponding Author:** Long Tian, MD, PhD, Department of Urology, Beijing Chao-Yang Hospital, Capital Medical University, No 8 Gongren Tiyuchang Nanlu, Chaoyang District, Beijing 100020, China. Tel: +86-10-8523-1247; Fax: +86-10-8523-1247; E-mail: [longtian@ccmu.edu.cn](mailto:longtian@ccmu.edu.cn)

*Conflicts of Interest:* The authors report no conflict of interest.

*Funding:* None.

## STATEMENT OF AUTHORSHIP

### Category 1

#### (a) Conception and Design

Hongen Lei; Long Tian

#### (b) Acquisition of Data

Hongen Lei; Xing Guan; Hu Han; Xiaosong Qian

#### (c) Analysis and Interpretation of Data

Hongen Lei; Hu Han; Xiaoguang Zhou; Xiaodong Zhang; Long Tian

**Category 2****(a) Drafting the Article**

Hongen Lei; Hu Han; Xiaosong Qian; Long Tian

**(b) Revising It for Intellectual Content**

Xiaodong Zhang; Long Tian

**Category 3****(a) Final Approval of the Completed Article**

Hongen Lei; Xing Guan; Hu Han; Xiaosong Qian; Xiaoguang Zhou; Xiaodong Zhang; Long Tian

**REFERENCES**

1. Furness PD III, Barqawi AZ, Bisignani G, et al. Klippel-Trenaunay syndrome: 2 case reports and a review of genitourinary manifestations. *J Urol* 2001;166:1418-1420.
2. Husmann DA, Rathburn SR, Driscoll DJ. Klippel-Trenaunay syndrome: incidence and treatment of genitourinary sequelae. *J Urol* 2007;177:1244-1249.
3. Kocaman O, Alponat A, Aygun C, et al. Lower gastrointestinal bleeding, hematuria and splenic hemangiomas in Klippel-Trenaunay syndrome: a case report and literature review. *Turk J Gastroenterol* 2009;20:62-66.
4. Rubenwolf P, Roosen A, Gerharz EW, et al. Life-threatening gross hematuria due to genitourinary manifestation of Klippel-Trenaunay syndrome. *Int Urol Nephrol* 2006;38:137-140.
5. Tepeler A, Yesilolva Y, Kilinc A, et al. A mild and rare form of Klippel-Trenaunay syndrome presenting with urethral bleeding due to penile hemangioma. *Urology* 2011;77:463-465.
6. Oduber CE, van der Horst CM, Hennekam RC. Klippel-Trenaunay syndrome: diagnostic criteria and hypothesis on etiology. *Ann Plast Surg* 2008;60:217-223.
7. Hofer T, Frank J, Itin PH. Klippel-Trenaunay syndrome in a monozygotic male twin: supportive evidence for the concept of paradominant inheritance. *Eur J Dermatol* 2005;15:341-343.
8. Pereira de Godoy JM, Fett-Conte AC. Dominant inheritance and intra-familial variations in the association of Sturge-Weber and Klippel-Trenaunay-Weber syndromes. *Indian J Hum Genet* 2010;16:26-27.
9. Cohen MM Jr. Klippel-Trenaunay syndrome. *Am J Med Genet* 2000;93:171-175.
10. Danarti R, Konig A, Bittar M, et al. Inverse Klippel-Trenaunay syndrome: review of cases showing deficient growth. *Dermatology* 2007;214:130-132.
11. Kihiczak GG, Meine JG, Schwartz RA, et al. Klippel-Trenaunay syndrome: a multisystem disorder possibly resulting from a pathogenic gene for vascular and tissue overgrowth. *Int J Dermatol* 2006;45:883-890.
12. Wang SK, Drucker NA, Gupta AK, et al. Diagnosis and management of the venous malformations of Klippel-Trenaunay syndrome. *J Vasc Surg Venous Lymphat Disord* 2017; 5:587-595.
13. Ahmed I, Aslam M, Bin Mahfooz A, et al. Genitourinary manifestations of Klippel-Trenaunay syndrome: report of two cases managed with systemic alpha-interferon. *Scand J Urol Nephrol* 2005;39:523-526.
14. Han H, Zhou XG, Fan DD, et al. An unusual etiology for hematospermia and treatments that were successful. *Urology* 2015;86:740-743.