

## What's Bugging You: A Closer Look at the Crab Louse

Sir,

We read with interest the review article titled "Entodermoscopy update: A contemporary review on dermoscopy of cutaneous infections and infestations."<sup>[1]</sup> We hereby describe the dermoscopic findings in a patient with pediculosis pubis, as well as a special emphasis of crab louse morphology and its differentiation from head and body louse.

A 25-year-old man presented to dermatology outpatient department complaining of severe pruritus in his pubic region for the past 3 months. Examination of the pubic area revealed several erythematous excoriated papules, adherent brownish concretions along the pubic hair, and several interspersed lice. When visualized through dermatoscope, slowly motile adult louse could be seen clearly, tenuously hanging on to the pubic hair [Figure 1 and Supplementary Video 1]. A diagnosis of pediculosis pubis was ascertained, and the patient was prescribed short-contact permethrin 1% cream. He was suggested to shave his pubic hair, screened for other sexually transmitted diseases, and counseled regarding safe sexual practices and partner management for pediculosis pubis. At follow-up visit after a week, the patient was symptom free.

Human pubic louse (*Pthirus pubis*) is an ectoparasite that infests the coarse terminal hair of pubic region, scalp, axilla, thighs, chest, eyebrows, and eyelashes. The infestation, known as pediculosis pubis, presents with severe pruritus of the affected sites. Mode of transmission is usually sexual. Diagnosis relies on visualization of the

minute lice and/or nits on hair shafts and can be aided by dermatoscopy, which aids in quick diagnosis and species identification. *Pthirus pubis* is characterized by light color, small size (1.2 × 8 mm) and slow motility, contrasting with the brown color, larger size (24 mm) and quick motility of *Pediculus humanus* (human head and body lice).<sup>[2]</sup> In addition, posterior pair of legs in *Pthirus pubis* are much thicker than the front pair, giving it an appearance similar to the pincers of a crab [Figure 1]. Scabies mite is characterized by a triangular structure corresponding to the fore portion of mite found at the end of the burrow, likened to a jetliner with contrail.<sup>[2]</sup> Using a dermatoscope can aid in arriving at the correct diagnosis in a non-invasive manner, eliminating the need for a microscope or other sophisticated devices. Dermatoscopy can also aid in assessing the adequacy of treatment at follow-up visit.

### Declaration of patient consent

The authors certify that they have obtained all appropriate patient consent forms. In the form, the patient has given his consent for his images and other clinical information to be reported in the journal. The patient understands that his names and initials will not be published and due efforts will be made to conceal his identity, but anonymity cannot be guaranteed.

### Financial support and sponsorship

Nil.

### Conflicts of interest

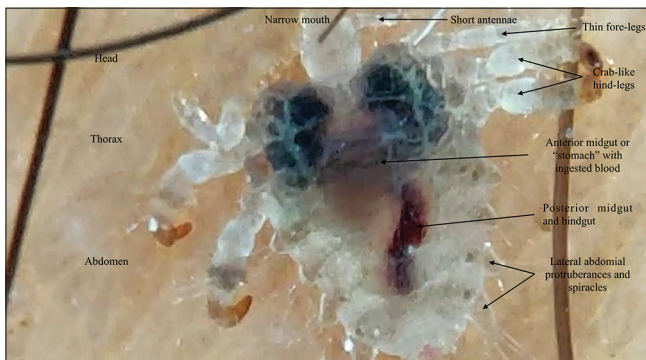There are no conflicts of interest.

**Hitaishi Mehta, Sheetanshu Kumar,  
Anuradha Bishnoi**

Department of Dermatology, Venereology and Leprology, Postgraduate Institute of Medical Education and Research, Chandigarh, India

#### Address for correspondence:

Dr. Anuradha Bishnoi,  
Department of Dermatology, Venereology and Leprology,  
Postgraduate Institute of Medical Education and Research, Sector 12,  
Chandigarh - 160 012, India.  
E-mail: dranhal4@gmail.com



**Figure 1: Adult crab louse on pubic hair. Respiratory spiracles and digestive system with ingested blood are clearly visible through the translucent exoskeleton (Dermlite II, hybrid M, 10×, polarized)**

### References


1. Sonthalia S, Agrawal M, Bhatia J, Zeeshan M, Elsamanoudy S, Tiwary P, et al. Entodermoscopy update: A contemporary review on dermoscopy of cutaneous infections and infestations. Indian

Dermatol Online J 2021;12:220-36.

2. Tschandl P, Argenziano G, Bakos R, Gourhant J-Y, Hofmann-Wellenhof R, Kittler H, *et al.* Dermoscopy and entomology (entomodermoscopy). J Dtsch Dermatol Ges 2009;7:589-96.

This is an open access journal, and articles are distributed under the terms of the Creative Commons Attribution-NonCommercial-ShareAlike 4.0 License, which allows others to remix, tweak, and build upon the work non-commercially, as long as appropriate credit is given and the new creations are licensed under the identical terms.

Video Available on: [www.idoj.in](http://www.idoj.in)

Access this article online	
<b>Website:</b> <a href="http://www.idoj.in">www.idoj.in</a>	<b>Quick Response Code</b> 
<b>DOI:</b> 10.4103/idoj.IDOJ_161_21	

**How to cite this article:** Mehta H, Kumar S, Bishnoi A. What's bugging you: A closer look at the crab louse. Indian Dermatol Online J 2022;13:143-4.

**Received:** 08-Mar-2021. **Revised:** 10-Mar-2021.

**Accepted:** 12-Mar-2021. **Published:** 24-Jan-2022.

© 2022 Indian Dermatology Online Journal | Published by Wolters Kluwer - Medknow