

# Unilateral pulmonary edema during laparoscopic resection of adrenal tumor

Smita Prakash, Pavan Nayar, Pooja Virmani, Shipra Bansal, Mridula Pawar

Department of Anesthesia and Intensive Care, Vardhman Mahavir Medical College and Safdarjang Hospital, New Delhi, India

## Abstract

Despite technological, therapeutic and diagnostic advancements, surgical intervention in pheochromocytoma may result in a life-threatening situation. We report a patient who developed unilateral pulmonary edema during laparoscopic resection of adrenal tumor.

**Key words:** Anesthesia complication, laparoscopic adrenalectomy, unilateral pulmonary edema, surgery

## Introduction

Unilateral pulmonary edema is usually reported with reexpansion of collapsed lung, unilateral pulmonary embolism, severe mitral valve regurgitation, cerebral autonomic dysfunction and unilateral sympathectomy. We report occurrence of unilateral pulmonary edema during laparoscopic adrenalectomy.

## Case Report

A 22-year-old male, 64 kg, with thyroid nodule and left suprarenal mass (multiple endocrine neoplasia, type 2a, suspected pheochromocytoma of the familial variety) was scheduled for laparoscopic adrenalectomy. He was asymptomatic and normotensive. Hemogram, blood sugar, liver, kidney and thyroid functions, lipid profile, electrocardiogram (ECG) and echocardiogram were normal. Urine catecholamine + vanillylmandelic acid, urine adrenaline and noradrenaline 24-h levels were normal. Serum calcitonin level was raised

(58.10 pg/ml). Contrast-enhanced computed tomography abdomen showed a 4.0 cm × 2.5 cm × 2.0 cm rounded heterogeneously enhancing left adrenal mass. Whole body meta-iodobenzylguanidin (MIBG) scan revealed a MIBG concentrating tumor of left suprarenal gland. There was a strong family history (maternal) of medullary carcinoma thyroid and pheochromocytoma.

The patient was premedicated with tab. alprazolam 0.5 mg given night prior to surgery. In the operating room, standard monitoring (ECG, noninvasive blood pressure, SpO<sub>2</sub>, EtCO<sub>2</sub>, temperature) was instituted and intravenous (IV) midazolam 1.5 mg and fentanyl 100 µg was administered. Anesthesia was induced with propofol 120 mg and morphine 4.5 mg. Tracheal intubation was facilitated with vecuronium 7 mg. There was no hypertensive response to intubation. Anesthesia was maintained with isoflurane (0.2-0.6%) and nitrous oxide in oxygen (33%) with mechanical ventilation via circle system (initial tidal volume setting 500 ml, respiratory rate 12/min). Peak airway pressure (Paw) was 16 cmH<sub>2</sub>O.

An epidural catheter was sited at L1-L2 interspace. Left radial artery was cannulated. The right internal jugular vein double-lumen catheter was sited. Baseline central venous pressure (CVP) was 10 mmHg. The patient was positioned in right lateral decubitus position with raised kidney bridge. Carboperitoneum was created with intra-abdominal pressure < 12 mmHg; Paw was 20 cmH<sub>2</sub>O. Bupivacaine (0.25%) 6 ml with morphine 3 mg was administered epidurally. The patient was hemodynamically stable until dissection started around the adrenal gland when a surge in BP 180/96/133 mmHg, heart rate (HR) 109/min occurred. This was managed by sodium nitroprusside (SNP, 2 µg/kg/min) and phentolamine infusion

Address for correspondence: Dr. Smita Prakash,  
C 17 HUDCO Place,  
New Delhi - 110 049, India.  
E-mail: drsunilprakash@gmail.com

### Access this article online

#### Quick Response Code:

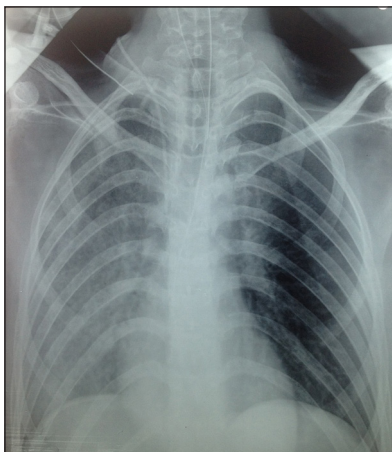


Website:  
[www.joacp.org](http://www.joacp.org)

DOI:  
10.4103/0970-9185.161681

( $\approx 0.1$ - $0.2$  mg/min), isoflurane 1.5% and fentanyl 100  $\mu$ g. During adrenal gland manipulation, bigemini and stable ventricular tachycardia developed followed by supraventricular tachycardia. These were treated with IV lignocaine (100 mg) and esmolol (30 mg), respectively. Twenty minutes later, a decrease in  $\text{SpO}_2$  (86%) occurred.  $\text{N}_2\text{O}$  was stopped ( $\text{FiO}_2$  1.0). HR was 121/min, BP 133/85/102 mmHg (maintained by SNP, phentolamine and morphine 3 mg), CVP 14 mmHg,  $\text{EtCO}_2$  32 mmHg and Paw 23  $\text{cmH}_2\text{O}$ .  $\text{SpO}_2$  increased to 92%. Preloading with  $\approx 1$  l Ringer's lactate was done prior to vein clipping. Following vein clipping, BP decreased to 91/46/67 mmHg, HR 106/min, CVP 15  $\text{cmH}_2\text{O}$ . SNP was discontinued, and norepinephrine infusion (4  $\mu$ g/min) commenced. Ten minutes after vein clipping, Paw increased (26  $\text{cmH}_2\text{O}$ ), and air entry was markedly decreased in right dependent lung. Left endobronchial intubation was excluded by laryngoscopy. BP decreased to 66/35 mmHg, HR was 104/min, CVP 19 mmHg and  $\text{SpO}_2$  84-91% with  $\text{FiO}_2$  1.0. Norepinephrine infusion was stepped up (8  $\mu$ g/min). Copious pale yellow, nonfrothy, clear fluid appeared in the closed circuit signifying pulmonary edema [Figure 1]; Frusemide IV in 10 mg increments (total 40 mg) was administered and positive end-expiratory pressure (PEEP) 4-6  $\text{cmH}_2\text{O}$  applied. Fluid analysis revealed pH 8 and protein 2 g/dl. Following left adrenalectomy, pneumoperitoneum was relieved. At the end of surgery, HR was 93/min, BP 106/69/86 mmHg with norepinephrine (8  $\mu$ g/min),  $\text{SpO}_2$  98%,  $\text{FiO}_2$  1.0, Paw 20  $\text{cmH}_2\text{O}$ , PEEP 5  $\text{cmH}_2\text{O}$ , CVP 12 mmHg. Air entry was markedly decreased in the right lung in the supine position.

Duration of anesthesia and surgery was 5.5 h and 4.5 h, respectively; pneumoperitoneum lasted 4 h. Blood loss was  $\approx 400$  ml. Urinary output was 1200 ml. Patient received 2.5 L of Ringer's lactate solution and 500 ml gelofusine. The patient was shifted to the intensive care unit (ICU) for further management.



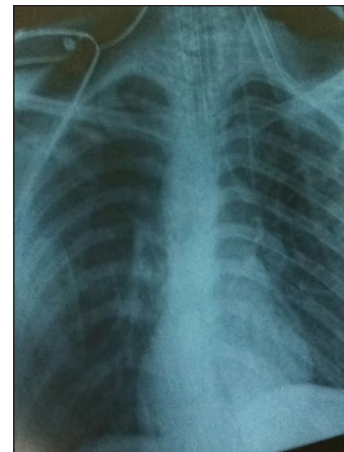**Figure 1:** Postoperative X-ray chest AP view. Near total haziness in right lung field

In the ICU, the patient was stable with HR between 90 and 115/min, BP 98/50 mmHg to 115/65 mmHg on norepinephrine (6-8  $\mu$ g/min). The lungs were ventilated with synchronized intermittent mandatory ventilation (SIMV) mode, PEEP 8  $\text{cmH}_2\text{O}$  and pressure support (PS) 12  $\text{cmH}_2\text{O}$ ,  $\text{FiO}_2$  0.6-0.45. Air entry continued to be decreased in the right lung. Chest X-ray revealed haziness of right lung field consistent with unilateral pulmonary edema [Figure 1]. Arterial blood gas (ABG) analysis revealed  $\text{PaO}_2$  125 mmHg,  $\text{PaCO}_2$  51 mmHg, pH 7.384. Troponin *t*-test was negative. Postoperative echocardiogram was normal.

On postoperative day 1, the patient remained hemodynamically stable, and noradrenaline was reduced. SIMV support with PEEP was continued. After 24 h bilateral air entry was present. Chest X-ray showed marked aeration [Figure 2]. ABG was normal. On postoperative day 2, norepinephrine infusion was tapered. Patient remained hemodynamically stable. Patient was put on CPAP 8  $\text{cmH}_2\text{O}$ , and PS 8  $\text{cmH}_2\text{O}$  followed by T-piece trial and extubation. The patient maintained well on ventimask ( $\text{FiO}_2$  0.4); Norepinephrine was discontinued on postoperative day 4. The patient was transferred to the ward on postoperative day 5 and discharged home on postoperative day 8.

## Discussion

Acute pulmonary edema, a known but uncommon feature of pheochromocytoma, can be of cardiogenic (catecholamine-induced cardiomyopathy or myocarditis)<sup>[1]</sup> or noncardiogenic origin. Noncardiogenic edema can be caused by direct effects of catecholamines on pulmonary vascular bed that results in a transient increase in pulmonary capillary hydrostatic pressure or direct damage to alveoli and capillaries leading to increased pulmonary capillary permeability.<sup>[1,2]</sup> Several episodes of pulmonary edema in the absence of hypertension and left ventricular dysfunction in pheochromocytoma have been



**Figure 2:** Chest X-ray on postoperative day 1 showing complete resolution of pulmonary edema

reported.<sup>[2]</sup> An adrenergic crisis (severe hypertension, mydriasis and pulmonary edema) occurred despite preoperative alpha and beta adrenergic blockade following insufflation of the peritoneum for laparoscopic surgery for pheochromocytoma resulting in abandonment of the procedure.<sup>[3]</sup>

Unilateral dependent pulmonary edema has been reported during laparoscopic donor nephrectomy, nephrectomy for renal cell carcinoma and urological surgery.<sup>[4]</sup> Several factors contribute toward the development of unilateral pulmonary edema. During lateral decubitus position with controlled ventilation in an anesthetized patient, the dependent lung is relatively hyperperfused and hypoventilated compared with the nondependent lung. Dependent lung hypoventilation results from upward displacement of the dependent hemi-diaphragm by abdominal organs, mediastinal sagging, patient positioning maneuvers (flexion of the operating table or elevation of the kidney rest) and pneumoperitoneum. Increased perfusion of the dependent lung results in increased pulmonary capillary pressures with fluid transudation according to Starling's equation. Unilateral impairment of lymphatic drainage has also been implicated. Operations in which the patient is in the lateral decubitus position for  $\geq 5$  h with high fluid requirement is an independent risk factor for unilateral dependent pulmonary edema.<sup>[5]</sup> Pulmonary edema fluid is classically described as pink and frothy because of the presence of red blood cells and mixing with air in the alveoli. We were surprised by the clear pale-yellow, nonfrothy fluid and the copious amount flowing out of the tracheal tube. Protein content was 2 g/dL, suggestive of a transudate. Absence of red blood cells in the transudate and the copious amount precluded presence of air in the affected alveoli resulting in a nonpink, nonfrothy fluid.

It has been suggested that patients with subclinical pheochromocytoma (minimal or no symptoms; mild hypertension or normal BP) should undergo the same preoperative preparation with alpha-adrenergic blocking agents as patients with classic symptomatic pheochromocytoma because they may still manifest perioperative hemodynamic derangements even with minimal hormonal secretion.<sup>[6]</sup>

Our patient was asymptomatic, normotensive and biochemically normal. Surgery was planned without preoperative preparation with alpha- and beta-blockers in consultation with endocrinologist and cardiologist. Resting HR recorded at each preoperative visit was 58-68/min. Intraoperative increase in arterial pressure in patients undergoing pheochromocytoma

removal can occur when moving the patient on the table, during induction of general anesthesia and tracheal intubation, when abdominal pressure changes due to the initiation of mechanical ventilation, at skin incision, during the creation of pneumoperitoneum and when the tumor is directly manipulated.<sup>[7]</sup> Our patient did not exhibit a hypertensive response at any of these times except during tumor manipulation. Complications during the pheochromocytoma surgery were independently associated with preoperative systolic blood pressure, urinary metanephrine excretion and with the number of operations (repeat vs. first operation). Our patient had none of these features. The combination of prolonged lateral decubitus position, pneumoperitoneum, raised kidney bridge, ventilation-perfusion mismatch, Starling's forces, impaired lymphatic drainage in right lateral position, catecholamine-induced alveolar-capillary injury possibly contributed to unilateral pulmonary edema in our patient undergoing laparoscopic pheochromocytoma removal. It is important that anesthesiologists be aware of the possibility of unilateral pulmonary edema in any prolonged laparoscopic surgical procedures performed in lateral decubitus position.

## References

1. Pineda Pompa LR, Barrera-Ramírez CF, Martínez-Valdez J, Rodríguez PD, Guzmán CE. Pheochromocytoma-induced acute pulmonary edema and reversible catecholamine cardiomyopathy mimicking acute myocardial infarction. *Rev Port Cardiol* 2004;23:561-8.
2. de Leeuw PW, Waltman FL, Birkenhäger WH. Noncardiogenic pulmonary edema as the sole manifestation of pheochromocytoma. *Hypertension* 1986;8:810-2.
3. Tauzin-Fin P, Hilbert G, Krol-Houdek M, Gosse P, Maurette P. Mydriasis and acute pulmonary oedema complicating laparoscopic removal of pheochromocytoma. *Anaesth Intensive Care* 1999;27:646-9.
4. Modi M, Shah V, Modi P. Unilateral dependant pulmonary edema during laparoscopic donor nephrectomy: Report of three cases. *Indian J Anaesth* 2009;53:475-7.
5. Leeming BW. Gravitational edema of the lungs observed during assisted respiration. *Chest* 1973;64:719-22.
6. Shen WT, Grogan R, Vriens M, Clark OH, Duh QY. One hundred two patients with pheochromocytoma treated at a single institution since the introduction of laparoscopic adrenalectomy. *Arch Surg* 2010;145:893-7.
7. Lentschener C, Gaujoux S, Tesniere A, Dousset B. Point of controversy: Perioperative care of patients undergoing pheochromocytoma removal-time for a reappraisal? *Eur J Endocrinol* 2011;165:365-73.

**How to cite this article:** Prakash S, Nayar P, Virmani P, Bansal S, Pawar M. Unilateral pulmonary edema during laparoscopic resection of adrenal tumor. *J Anaesthesiol Clin Pharmacol* 2015;31:401-3.

**Source of Support:** Nil, **Conflicts of Interest:** None declared.