

# Outcomes of evisceration or enucleation by resident trainees in patients with recalcitrant endophthalmitis or panophthalmitis

Wannaporn Tianthong, MD<sup>a</sup>, Orapan Aryasit, MD<sup>a,\*</sup> 

## Abstract

To evaluate the surgical outcomes and complications of evisceration or enucleation with primary implantation, performed by ophthalmology resident trainees, in regards to patients with recalcitrant endophthalmitis or panophthalmitis. We also compared the surgical outcomes and complications between resident trainees and experienced staff. In this retrospective analysis, the clinical records of all patients diagnosed with endophthalmitis or panophthalmitis who underwent enucleation or evisceration with primary implantation over a 13-year period were reviewed. The factors predicting implant exposure or extrusion in regards to patients who underwent eye removal by trainees were identified using multivariate analysis. The percentages of successful prosthesis fittings and complications were also reported. Sixty-six patient records, median age of 46.8 years, who underwent eye removal by resident trainees were reviewed. Thirty-six (55%) out of 66 patients were diagnosed with panophthalmitis. Four patients (6%) had implant exposure, and 4 patients (6%) had implant extrusion. Multivariate analysis demonstrated that *Pseudomonas aeruginosa* infection ( $P = .02$ , adjusted odd ratio [aOR] = 33.75) and not receiving intravitreal antimicrobial drugs before the eye removal procedure ( $P = .02$ , aOR = 30.11) were associated with implant exposure or extrusion. Patients with panophthalmitis who underwent evisceration had a higher rate of implant exposure or extrusion than those who underwent enucleation ( $P = .03$ , aOR 38.38). At the last visit, 65 patients had a successful prosthesis fitting. Furthermore, there were similar rates of complications and successful prosthesis fittings between experienced staff and resident trainees. This study suggests that evisceration or enucleation with primary implant placement in patients with recalcitrant endophthalmitis or panophthalmitis can be performed by resident trainees with acceptable surgical outcomes and a low rate of serious complications.

**Abbreviations:** aOR = adjusted odds ratio, CI = confident interval, HM = hand motion, SD = standard deviation.

**Keywords:** endophthalmitis, enucleation, evisceration, implant exposure, implant extrusion, panophthalmitis

## 1. Introduction

Endophthalmitis is defined as ocular inflammation that is attributable to an infection of the intraocular cavity. The causes of endophthalmitis consist of endogenous and exogenous causes, such as direct trauma, intraocular surgery, and adjacent infection.<sup>[1]</sup> If infection is uncontrolled, inflammation can progress to involve the sclera, and this is called panophthalmitis.<sup>[2]</sup>

The management of fulminant endophthalmitis or panophthalmitis, which is refractory to other medical treatments, is evisceration or enucleation, in order to eradicate the infection. However, surgical choices, timing, and types of implant placement remain controversial.<sup>[3–5]</sup> Over the past decade, evisceration or enucleation with primary implants has been frequently performed with acceptable outcomes, including a

low rate of implant extrusion or exposure and postoperative infections.<sup>[6–9]</sup>

In recent studies, the implant exposure or extrusion rate, after evisceration, of primary implants in patients with endophthalmitis was 3% to 9%.<sup>[6,9]</sup> However, the international literature appears to not sufficiently feature treatment outcomes in regards to evisceration or enucleation in connection to primary implant placement operations conducted by resident trainees on patients with endophthalmitis or panophthalmitis.

In Songklanagarind Hospital, a residency-training tertiary hospital in southern Thailand, there are many patients with intractable endophthalmitis and panophthalmitis requiring eye removal surgery. These operations include eviscerations and enucleations in regards to eyes featuring large areas of necrotic or melting scleral tissue. In addition, primary implant placement

This research was supported by a grant from the Faculty of Medicine, Prince of Songkla University.

For this type of study, formal consent was waived.

The authors have no conflicts of interest to disclose.

The datasets generated during and/or analyzed during the current study are available from the corresponding author on reasonable request.

Ethics approval was provided by the Ethics Committee, Faculty of Medicine, Prince of Songkla University. (REC number 62-007-2-4).

<sup>a</sup> Department of Ophthalmology, Faculty of Medicine, Prince of Songkla University, Hat Yai, Songkhla, Thailand.

\*Correspondence: Orapan Aryasit, Department of Ophthalmology, Faculty of Medicine, Prince of Songkla University, Hat Yai, Songkhla 90110, Thailand (e-mail: all\_or\_none22781@hotmail.com).

Copyright © 2022 the Author(s). Published by Wolters Kluwer Health, Inc. This is an open-access article distributed under the terms of the Creative Commons Attribution-Non Commercial License 4.0 (CCBY-NC), where it is permissible to download, share, remix, transform, and buildup the work provided it is properly cited. The work cannot be used commercially without permission from the journal.

How to cite this article: Tianthong W, Aryasit O. Outcomes of evisceration or enucleation by resident trainees in patients with recalcitrant endophthalmitis or panophthalmitis. *Medicine* 2022;101:30(e29932).

Received: 29 September 2021 / Received in final form: 23 May 2022 / Accepted: 15 June 2022

<http://dx.doi.org/10.1097/MD.00000000000029932>

is the preferred option. Most operations are done by resident trainees as part of their training curriculum.

The purpose of this study was to evaluate the rate of implant exposure or extrusion and the predictive factors related to implant exposure or extrusion in connection to eviscerations or enucleations with primary implants, performed by resident trainees on patients with recalcitrant endophthalmitis or panophthalmitis. We also compared the surgical outcomes between resident trainees and experienced staff.

## 2. Methods

### 2.1. Study population

The medical records of all patients with endophthalmitis or panophthalmitis who underwent enucleation or evisceration with primary implants by resident trainees at Songklanagarind Hospital between January 1, 2006, and December 31, 2018, were enrolled. Patients who had a follow-up period of <6 months, had no prosthesis fittings, and no primary implant placements were excluded (Fig. 1). The surgical outcomes in connection to operations performed by experienced members of staff, within the same time period, were also collected for the purpose of comparison. This study was approved by the Ethics Committee of the Faculty of Medicine, Prince of Songkla University (REC number 62-007-2-4), and it adhered to the tenets of the Declaration of Helsinki. Formal consent was waived due to the retrospective nature of the study.

All decisions to perform enucleation or evisceration were made by the ophthalmology consultant. All operations were performed, with patients under general anesthesia, by residents under the supervision of at least 1 supervising senior resident and/or ophthalmology consultant. Prior to the operations, all residents underwent “wet lab” training by performing evisceration surgeries on pigs' eyeballs. Evisceration was the operation of choice for the removal of infectious eyes without the presence of scleral melting or necrosis. If nonviable sclera was present, then the operation was shifted to enucleation.

### 2.2. Data collection

Patient characteristics, causes, and causative organisms of endophthalmitis or panophthalmitis, as well as surgical procedures and techniques, were documented. In addition, post-operative outcomes, including postoperative complications, prosthesis fitting results, and adjunctive surgical procedures, were also collected.

### 2.3. Main outcome measures

Primary outcomes were measured by calculating the rate of major complications and whether there was implant exposure or extrusion, due to their detrimental effect on the fitting of the prosthesis and the subsequent requirement for major surgery and medical resource to ensure rectification. The predictive factors related to implant exposure or extrusion were analyzed using multivariate analysis. The secondary outcome measure was the percentage of patients who achieved eye prosthesis fitting.

### 2.4. Statistical analysis

In regards to the sample size calculation, we aimed to detect an implant retention rate of 97%.<sup>[9]</sup> With a 5% error rate, a 2-sided alpha of 0.05, and an expected 20% dropout rate, 54 patients with endophthalmitis or panophthalmitis, who underwent evisceration or enucleation, were required. Data were collected in R program version 4.1.0 (The R Group, Vienna, Austria) with Epicalc software. Analysis was performed using STATA version 14 (StataCorp LP, College Station, TX). Descriptive statistics, including means ± standard deviation, medians, percentages, and frequencies, were demonstrated in regards to the variable of interest. Categorical variables were compared by Pearson chi-square test and Fisher exact test. Continuous variables were compared by the Mann–Whitney test. Factors associated with surgical outcome were identified using multivariate analysis,

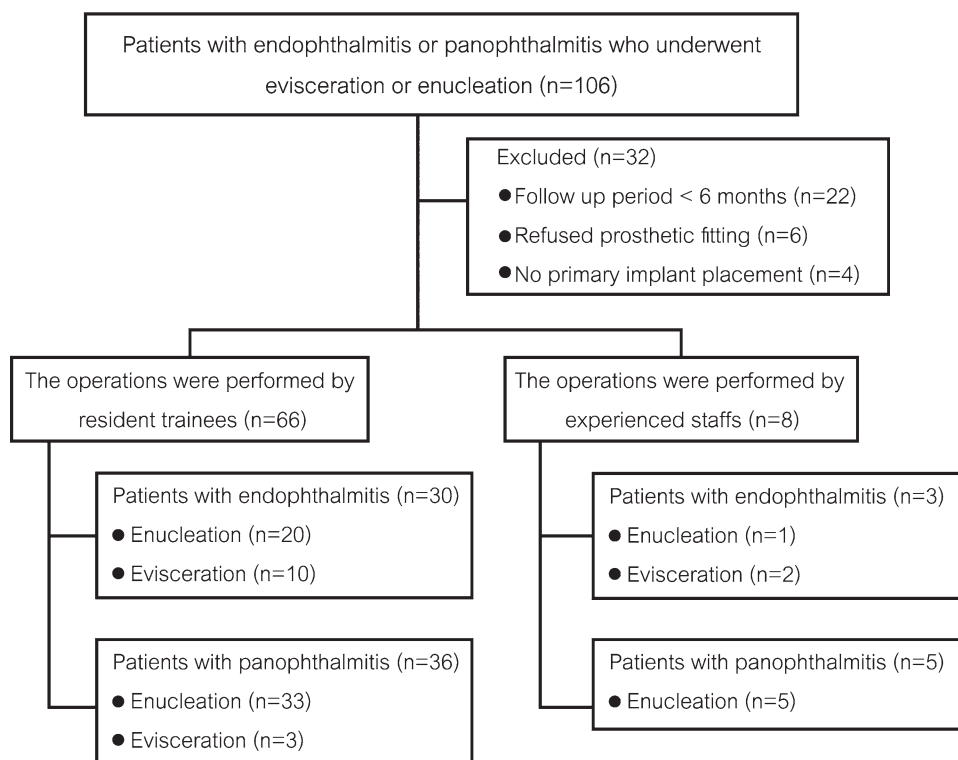


Figure 1. Flow diagram of patient enrollment.

which used the logistic regression model based on stepwise regression models. A *P* value of  $<.05$  was considered statistically significant.

### 3. Results

#### 3.1. Patient characteristics

In regards to operations that were performed by resident trainees, 66 patients were included, with a median age of 46.8 years (mean: 44.3, range; 4–84 years) and 43 of those were male. The follow-up period ranged from 7 to 139 months (mean: 56 months). Thirty-six (55%) out of 66 patients were diagnosed with panophthalmitis. Traumatic causes were found in 36 patients (55%): 22 patients from penetrating globe injuries, 13 patients from intraocular foreign bodies, and 1 patient from rupture globe injury. Thirteen patients (20%) had previous perforated corneal ulcers, 10 patients (15%) experienced endogenous infection, and 7 patients (11%) developed postoperative endophthalmitis or panophthalmitis (6 from cataract surgery and 1 from trabeculectomy with mitomycin C). Only 8 patients (7 patients had a traumatic cause and 1 patient had previous perforated corneal ulcers) were operated by experienced staff members. Furthermore, 5 (63%) out of 8 patients were diagnosed with panophthalmitis.

#### 3.2. Surgical procedures and microorganisms

Resident trainees performed enucleation to 53 patients (80%) and evisceration to the remaining patients. The vitreous and/or aqueous humor was collected and sent for culture and sensitivity in 48 patients. The results were positive for any organisms in 39 patients (81%); 14 patients had mixed organisms, 9 of which had traumatic causes. The most common pathogen was *Bacillus species*, followed by *Staphylococcus epidermidis*, *Pseudomonas aeruginosa*,  $\beta$ -*streptococcus group B*, and *Enterobacter cloacae*, which were positive in 14, 7, 6, 3, and 3 patients, respectively. Fungal infection was found in 4 patients. Antimicrobial drugs were used via a variety of routes: topical, intravitreal, and systemic. The average number of intravitreal injections was 1.6 (range: 1–4). The mean duration of oral and intravenous administration was 8.9 days (range: 1–42 days). Experienced staff members performed enucleation in 6 (75%) out of 8 patients. A mixture of microorganisms was found in 4 patients. The most common pathogens were *P aeruginosa* and *Escherichia coli*.

In operations by trainees, 64 implants (97%) were of the nonporous type, including acrylic, glass, and silicone spheres in 59, 4, and 1 patient, respectively. Only 2 patients received a porous type (1 bovine hydroxyapatite and 1 porous polyethylene implant). Most implants were 20 mm in size and they were placed in 44 patients (67%), while 14-mm, 16-mm, and 18-mm implants were placed in 1, 6, and 15 patients, respectively. Small-sized implants were used in cases where there was inadequate soft tissue coverage. The mean operative time of enucleation was 215 minutes (range: 130–335 minutes) and that of evisceration was 194 minutes (range: 155–239 minutes).

#### 3.3. Complications

The complications of evisceration or enucleation with primary implant placement in patients with recalcitrant endophthalmitis or panophthalmitis illustrates in Table 1. In regards to the 66 operations, done by resident trainees, implant exposure was discovered in 4 patients at days 19, 23, 39, and 72 after surgery. All of them required surgical interventions to remove implants and augment orbital volume using dermis-fat grafts. Implant extrusion was noted in 4 patients at 9 months, 11 months, 5 years, and 10 years postoperatively; 2 patients received dermis-fat grafts, while the other 2 patients achieved successful prosthesis

fitting after prosthesis modification. From all patients who had implant exposure or extrusion, 5 patients were diagnosed with panophthalmitis. Wound dehiscence developed in 3 patients at 14, 32, and 45 days postoperatively, and surgical wound repair had to be performed. Infected socket occurred in 3 out of 66 patients, resulting in implant exposure or extrusion. In addition, other less severe complications consisted of socket discharge in 14 patients, which improved following medical treatment and lower lid laxity in 5 patients who underwent the lateral tarsal strip procedure. In regards to the 8 patients who underwent enucleation or evisceration by experienced staff members, there was a major complication in connection to 1 patient who was diagnosed with panophthalmitis and developed implant exposure at 19 days after enucleation. None had an implant extrusion.

Univariate analysis revealed that the predictors of implant exposure or extrusion in the operations that were performed by resident trainees are illustrated in Table 2. Multivariate analysis is shown in Table 3. The factors related to implant exposure or extrusion were *P aeruginosa* infection ( $P = .02$ , aOR = 33.75) and not receiving intravitreal antimicrobial drugs before the eye removal procedure ( $P = .02$ , aOR = 30.11).

#### 3.4. Surgical outcomes

At the last follow-up, in regards to operations done by resident trainees, 65 out of 66 patients (98%) had successful prosthesis fittings. Only 1 patient who developed early postoperative endophthalmitis from *Pseudomonas aeruginosa* after complicated cataract surgery could not retain the eye prosthesis because of a contracted socket after adjunctive surgery for implant exposure and requested a conformer instead. All patients who underwent enucleation or evisceration by experienced members of staff had the prosthesis successfully fitted. No statistically significant difference was found between the rates of successful prosthesis fitting in operations performed by trainees or experienced members of staff ( $P = 1.00$ ).

### 4. Discussion

This study revealed that surgical outcomes of evisceration or enucleation with primary implant placement by resident trainees in patients with fulminant endophthalmitis or panophthalmitis were satisfactory, with a low rate of implant exposure or extrusion and residual infection and a high rate of successful prosthesis fitting. In patients with panophthalmitis, evisceration was significantly associated with a higher frequency of implant exposure or extrusion than enucleation. The predictive factors affecting implant exposure or extrusion were *Pseudomonas aeruginosa* infection and not receiving intravitreal antimicrobial drugs before the eye removal procedure. However, younger age was not a factor that was associated with implant exposures or extrusions.

**Table 1**

**Complications of evisceration or enucleation with primary implant placement in patients with recalcitrant endophthalmitis or panophthalmitis.**

Complications	Trainees	Staff	<i>P</i> value
Severe complications, n (%)			
Implant exposure or extrusion	8 (12)	1 (13)	1.00
Wound dehiscence	3 (5)	1 (13)	.37
Minor complications, n (%)			
Infected socket	14 (21)	2 (25)	1.00
Lower lid laxity	5 (8)	1 (13)	.51
Late orbital cellulitis	2 (3)	0 (0)	1.00
Ptosis	0 (0)	1 (13)	.11

**Table 2****Univariate analysis for factors related to implant exposure or extrusion.**

Variables	Implant exposure or extrusion		P value	Odd ratio (95% CI)	P value
	No (N = 58), n (%)	Yes (N = 8), n (%)			
Age (yr)					
Mean (SD)	44.7 (21.2)	41.6 (19.2)	.42		
Median (min–max)	48.1 (3.9–84.1)	34.9 (22.8–83.8)			
Age (yr)					
>46.8	30 (51.7)	2 (25.0)	.26	1	
≤46.8	28 (48.3)	6 (75.0)		3.21 (0.60–17.27)	.17
Gender					
Male	38 (65.5)	5 (62.5)	1.00	1	
Female	20 (34.5)	3 (37.5)		1.14 (0.25–5.27)	.87
Diagnosis of affected eye					
Endophthalmitis	27 (46.6)	3 (37.5)	.72	1	
Panophthalmitis	31 (53.4)	5 (62.5)		1.45 (0.32–6.65)	.63
Cause of endophthalmitis or panophthalmitis					
Trauma	32 (55.2)	4 (50.0)	.97	1	
Endogenous	9 (15.5)	1 (12.5)		0.89 (0.09–8.98)	.92
Postoperation	6 (10.3)	1 (12.5)		1.33 (0.13–14.10)	.81
Others	11 (18.9)	2 (25.0)		1.45 (0.23–9.07)	.69
Cause of endophthalmitis or panophthalmitis					
Trauma	32 (55.2)	4 (50.0)	1.00	1	
Nontrauma	26 (44.8)	4 (50.0)		1.23 (0.28–5.40)	.78
Preoperative visual acuity					
Better than HM	1 (1.8)	0 (0.0)		1	
HM or worse	56 (98.2)	8 (100.0)		1 (omitted)	–
Types of operation					
Enucleation	49 (84.5)	4 (50.0)	.04*	1	
Evisceration	9 (15.5)	4 (50.0)		5.44 (1.15–25.85)	.03*
Diagnosis of affected eye and eye removal procedure					
Panophthalmitis and enucleation	30 (51.7)	3 (37.5)		1	
Endophthalmitis and enucleation	19 (32.7)	1 (12.5)	.01*	0.53 (0.06–5.44)	.59
Endophthalmitis and evisceration	8 (13.8)	2 (25.0)		2.5 (0.36–17.60)	.36
Panophthalmitis and evisceration	1 (1.7)	2 (25.0)		20.0 (1.37–291.07)	.03*
<i>Bacillus</i> species					
No	45 (77.6)	7 (87.5)	1.00	1	
Yes	13 (22.4)	1 (12.5)		0.49 (0.06–4.39)	.53
<i>Pseudomonas aeruginosa</i>					
No	55 (94.8)	6 (75.0)	.11	1	
Yes	3 (5.2)	2 (25.0)		6.11 (0.85–44.16)	.07
Underlying diseases					
No	35 (60.3)	4 (50.0)	.71	1	
Yes	23 (39.7)	4 (50.0)		1.52 (0.35–6.70)	.58
White blood cell count (cells/ $\mu$ L)					
≤9500	11 (19.0)	1 (12.5)	1.00	1	
>9500	47 (81.0)	7 (87.5)		1.64 (0.18–14.72)	.70
Intravitreal antimicrobial drugs					
Yes	40 (69.0)	2 (25.0)	.02*	1	
No	18 (31.0)	6 (75.0)		6.67 (1.22–36.28)	.03*
Intravenous antimicrobial drugs					
No	2 (3.5)	1 (12.5)	.33	1	
Yes	56 (96.5)	7 (87.5)		0.25 (0.02–3.13)	.28
Prior ocular surgery					
No	14 (24.1)	4 (50.0)	.20	1	
Yes	44 (75.9)	4 (50.0)		0.32 (0.07–1.44)	.14
Type of orbital implant					
Nonporous	56 (96.6)	8 (100.0)	1.00	1	
Porous	2 (3.4)	0 (0.0)		1 (omitted)	–
Implant size (mm)					
14–18	21 (36.2)	1 (12.5)	.25	1	
20	37 (63.8)	7 (87.5)		3.97 (0.46–35.54)	.21

CI = confident interval, HM hand motion, SD = standard deviation.

\*Statistically significant.

The advantages of evisceration are less operative time in addition to less disruption of orbital tissues<sup>[10]</sup> but it may increase the risk of sympathetic ophthalmia.<sup>[11,12]</sup> Evisceration is also thought to have higher extrusion rates due to the residual nidus in the sclera. Wills Eye Hospital found that the implant extrusion rate in eviscerated sockets was 22%, compared with 6% after enucleation.<sup>[13]</sup> Primary

orbital implantation at the time of evisceration or enucleation, in cases of endophthalmitis, was previously believed to have a higher risk of implant extrusion. In 1988, Shore et al<sup>[14]</sup> performed delayed wound closure in 3 patients who had successful outcomes, but 1 patient underwent primary closure, which developed wound dehiscence and implant extrusion at 6 weeks postoperatively. However,



**Table 3**  
**Multivariate analysis for factors related to implant exposure or extrusion.**

Variables	Adjusted odd ratio (95% CI)	P value
Age (yr)		
≥46.8	1	
<46.8	7.65 (0.64–90.88)	.11
<i>Pseudomonas aeruginosa</i>		
No	1	
Yes	33.75 (1.72–663.73)	.02*
Diagnosis of affected eye and eye removal procedure		
Panophthalmitis and enucleation	1	
Panophthalmitis and evisceration	38.38 (1.39–1059.24)	.03*
Intravitreal antimicrobial drugs		
Yes	1	
No	30.11 (1.64–552.25)	.02*

CI = confident interval.

\*Statistically significant.

there are many advantages of primary implant placement, including decreasing both the risks and expenses of 2 separate surgeries and early initiation of rehabilitation.<sup>[4]</sup> Primary orbital implantation has been performed recently in cases of endophthalmitis or panophthalmitis, with satisfactory outcomes and an acceptable rate of complications.<sup>[6–9]</sup> A retrospective nonrandomized comparative interventional case series was conducted by Tripathy and Rath<sup>[15]</sup> in 2015 to compare the outcome of evisceration with primary orbital implants in blind eyes, with and without fulminant infection, and there was no statistically significant difference in major complications between the 2 groups.

In 2017, Fu et al<sup>[5]</sup> conducted a survey among American Society of Ophthalmic Plastic and Reconstructive Surgery surgeons to assess practice patterns in the treatment of endophthalmitis and found that 72% preferred evisceration, while 28% preferred enucleation. If infection extended to orbital tissues, 59% preferred enucleation versus 27% who preferred evisceration. Primary implant placement was performed by 65% in enucleation and 58% in evisceration.

In 2007, Tawfik et al<sup>[9]</sup> studied the outcomes of evisceration with primary implant placement in 52 endophthalmitis patients and 15 panophthalmitis patients; implant extrusion occurred in 2 patients (3%), and successful prosthesis fitting was achieved by 62 patients (92%). In our study, 66 operations were done by resident trainees, and implant extrusion was found in 2 patients with endophthalmitis and 2 patients with panophthalmitis. The extrusion rate was 6%, slightly more than that in a previous study.<sup>[9]</sup> This might be due to the higher proportion of panophthalmitis patients, which consisted of 55% with panophthalmitis in our study versus 22% with panophthalmitis in a previous study.<sup>[9]</sup> Our study found that both experienced staff and resident trainees had similar rates in regards to implant exposure or extrusion and fitting prostheses successfully.

In this study, the mean operative times of enucleation and evisceration were 215 and 194 minutes, respectively. It is worth noting that the operations, in this study, were performed by less experienced surgeons. Nevertheless, all operations were done under the supervision of a minimum of 1 senior resident and/or ophthalmology consultant.

In Thailand, both enucleation and evisceration are operations that are normally carried out by general ophthalmologists due to a limited number of oculoplastic specialists and poor accessibility to tertiary care. Hence, these operations are required components of the training of residents in the Thai system. This study demonstrates that the rate of implant exposure or extrusion and prosthesis fitting of operations performed by resident

trainees are not statistically different from experienced members of staff. Accordingly, resident trainees can perform evisceration or enucleation operations on patients with endophthalmitis or panophthalmitis with acceptable surgical outcomes.

From this study, the rate of implant exposure or extrusion in patients with panophthalmitis was 67% in the evisceration group compared with 9% in the enucleation group. Hence, enucleation is recommended in cases of panophthalmitis. Diagnosis as endophthalmitis or panophthalmitis was not associated with surgical outcomes in our study, which might be due to a tendency to perform enucleation in patients with panophthalmitis.

The potential of porous implants in reducing implant extrusion due to vascular ingrowth has been previously discussed. However, concerns regarding organism seeding in vascularized implants and further extrusion were also raised without definitive consensus.<sup>[4]</sup> Two of our patients received primary porous implants with bovine hydroxyapatite and the other with porous polyethylene. Each surgery was successful without subsequent complications and prosthesis fitting was achieved. This was in accordance with Park et al,<sup>[16]</sup> who in 2010 assessed the results of evisceration with primary porous implant placement in 29 eyes with endophthalmitis; only 2 eyes developed implant exposure or infection.

In the cases of ocular infection by virulent organisms, such as *Bacillus species* and *Pseudomonas aeruginosa*, scleral abscess, scleral melting, and perforation frequently develop, and these have a poor response to topical and systemic antibiotics.<sup>[17,18]</sup> Previous studies suggested enucleation in these cases because the integrity of the sclera might not be strong enough to support an orbital implant, especially in diabetes mellitus and immunocompromised hosts.<sup>[6,7,19]</sup> Accordingly, this study demonstrated that implant exposure or extrusion is more commonly developed in eyes infected by *Pseudomonas aeruginosa* than in eyes infected by other organisms. Therefore, if the preoperative diagnosis was *Pseudomonas aeruginosa* infection, then a secondary implant placement may need to be considered.

Various routes of antibiotic administration are used in endophthalmitis, and intravitreal injection is the main treatment because drugs are directly delivered into the infected part of the eye.<sup>[1,20]</sup> In contrast with systemic medication, penetration into the ocular posterior segment is limited by the blood–retinal barrier.<sup>[21,22]</sup> This study also showed the benefit of intravitreal antibiotics as lower rates of implant exposure or extrusion after enucleation or evisceration by trainees in cases of endophthalmitis or panophthalmitis. It is feasible that intravitreal injection can control some part of organism growth and reduce scleral invasion or orbital tissue infection.

Bee et al<sup>[23]</sup> reported that preoperative white blood cell counts of >9500 cells/microliter were associated with a higher risk of implant exposure, whereas in our study, implant exposure or extrusion was not significantly different in patients with either high or normal white blood cell counts.

The strengths of this study consisted of the following. First, long-term surgical outcomes were able to be assessed due to the long follow-up period (mean: almost 5 years), which was long enough to demonstrate late postoperative complications and the retention of implants. Second, this was the first study to demonstrate the results of evisceration or enucleation performed by resident trainees in patients with fulminant endophthalmitis or panophthalmitis. However, there were some limitations in this study, including the lack of evaluation of patient satisfaction after prosthesis fitting, selection bias from a high loss of follow-up rate, and incomplete data due to this being a retrospective study. Moreover, there were only 8 patients who were operated on by staff, making it difficult to appropriately compare serious complications and surgical outcomes between the 2 groups.

The information in our study can potentially encourage surgeons to perform enucleation in patients with panophthalmitis to prevent implant exposure or extrusion. Additionally, resident trainees had the competency to perform eye removal procedures in regards to severe eye infections. However, the comparison of

surgical results and complications of the eye removal procedure in this disease between ophthalmology consultants and resident trainees must be evaluated prospectively. It is suggested that an assessment of surgical outcomes in terms of cosmesis and satisfaction of prostheses is conducted accordingly.

## 5. Conclusions

Evisceration or enucleation operations involving primary implant placements, on endophthalmitis or panophthalmitis patients, can be safely performed by resident trainees. In addition, there is a low rate of implant exposures or extrusions associated with these operations. Patients not receiving an intravitreal injection before eye removal, and having a *Pseudomonas aeruginosa* infection may be risk factors in relation to postoperative implant exposures or extrusions. Furthermore, in regards to patients with panophthalmitis, enucleations were found to be less related to implant exposures or extrusions versus eviscerations. Our data also indicated that there were favorable surgical outcomes, at similar rates, between experienced staff and resident trainees.

## Acknowledgments

We would like to thank Ms. Parichat Damthongsuk and Ms. Nannapat Pruphetkaew for their valuable assistance regarding the statistics used in this project. Finally, we would like to thank SNAS website ([www.authorservices.springernature.com](http://www.authorservices.springernature.com)) for English language editing.

## Author contributions

Study concept and design: W.T. and O.A.; acquisition of data: W.T. and O.A.; analysis and interpretation of data: W.T. and O.A.; drafting the manuscript: W.T. and O.A.; revising the manuscript critically for important intellectual content: W.T. and O.A.; study supervision: O.A. All authors had full access to all of the data in this study and take responsibility for the integrity of the data and the accuracy of the data analysis. All authors read and approved the final manuscript.

## References

- [1] Sheu SJ. Endophthalmitis. *Korean J Ophthalmol.* 2017;31:283–9.
- [2] Pappuru RR, Dave VP, Pathengay A, et al. Endophthalmitis progressing to panophthalmitis: clinical features, demographic profile, and factors predicting outcome. *Semin Ophthalmol.* 2018;33:671–4.
- [3] O'Donnell BA, Kersten R, McNab A, et al. Enucleation versus evisceration. *Clin Exp Ophthalmol.* 2005;33:5–9.
- [4] Hui JI. Outcomes of orbital implants after evisceration and enucleation in patients with endophthalmitis. *Curr Opin Ophthalmol.* 2010;21:375–9.
- [5] Fu R, Childs J, Nunery W, et al. Surgical preferences in the management of recalcitrant endophthalmitis. *Orbit.* 2018;37:315–20.
- [6] Dresner SC, Karesh JW. Primary implant placement with evisceration in patients with endophthalmitis. *Ophthalmology.* 2000;107:1661–4.
- [7] Abel AD, Meyer DR. Enucleation with primary implant insertion for treatment of recalcitrant endophthalmitis and panophthalmitis. *Ophthalmic Plast Reconstr Surg.* 2005;21:220–6.
- [8] Ozgur OR, Akcay L, Dogan OK. Primary implant placement with evisceration in patients with endophthalmitis. *Am J Ophthalmol.* 2007;143:902–4.
- [9] Tawfik HA, Budin H. Evisceration with primary implant placement in patients with endophthalmitis. *Ophthalmology.* 2007;114:1100–3.
- [10] Hughes WL. Evisceration. *Arch Ophthalmol.* 1960;63:36–40.
- [11] Green WR, Maumenee AE, Sanders TE, et al. Sympathetic uveitis following evisceration. *Trans Am Acad Ophthalmol Otolaryngol.* 1972;76:625–44.
- [12] Levine MR, Pou CR, Lash RH. The 1998 Wendell Hughes Lecture. Evisceration: is sympathetic ophthalmia a concern in the new millennium? *Ophthalmic Plast Reconstr Surg.* 1999;15:4–8.
- [13] Zolli CL. Implant extrusion in eviscerations. *Ann Ophthalmol.* 1988;20:127–35.
- [14] Shore JW, Dieckert JP, Levine MR. Delayed primary wound closure. Use to prevent implant extrusion following evisceration for endophthalmitis. *Arch Ophthalmol.* 1988;106:1303–8.
- [15] Tripathy D, Rath S. Evisceration with primary orbital implant in fulminant endophthalmitis/panophthalmitis. *Orbit.* 2015;34:279–83.
- [16] Park YG, Paik JS, Yang SW. The results of evisceration with primary porous implant placement in patients with endophthalmitis. *Korean J Ophthalmol.* 2010;24:279–83.
- [17] Reynolds MG, Alfonso E. Treatment of infectious scleritis and kerato-scleritis. *Am J Ophthalmol.* 1991;112:543–7.
- [18] Raber IM, Laibson PR, Kurz GH, et al. *Pseudomonas* corneoscleral ulcers. *Am J Ophthalmol.* 1981;92:353–62.
- [19] Burnstine MA. Primary implant placement with evisceration. *Ophthalmology.* 2000;107:1664–5.
- [20] Lemley CA, Han DP. Endophthalmitis: a review of current evaluation and management. *Retina.* 2007;27:662–80.
- [21] Brockhaus L, Goldblum D, Eggenschwiler L, et al. Revisiting systemic treatment of bacterial endophthalmitis: a review of intravitreal penetration of systemic antibiotics. *Clin Microbiol Infect.* 2019;25:1364–9.
- [22] Grzybowski A, Turczynowska M, Schwartz SG, et al. The role of systemic antimicrobials in the treatment of endophthalmitis: a review and an international perspective. *Ophthalmol Ther.* 2020;9:485–98.
- [23] Bee YS, Lin MC, Sheu SJ, et al. Elevated white blood cell count may predict risk of orbital implant exposure. *Can J Ophthalmol.* 2014;49:45–9.