

## References

- 1 Genovese G, Moltrasio C, Berti E, Marzano AV. Skin manifestations associated with COVID-19: current knowledge and future perspectives. *Dermatology* 2021; **237**: 1–12.
- 2 Marzano AV, Genovese G, Moltrasio C *et al*. The clinical spectrum of COVID-19-associated cutaneous manifestations: an Italian multicenter study of 200 adult patients. *J Am Acad Dermatol* 2021; **84**: 1356–1363.
- 3 Miot HA, Ianhez M, Muller RP. Self-reported cutaneous manifestations in 1429 Brazilian COVID-19-infected patients. *J Eur Acad Dermatol Venereol* 2021; **35**: e172–e173.
- 4 Patsatsi A, Kyriakou A. Impact of the COVID-19 pandemic on the course and management of chronic inflammatory immune-mediated skin diseases: What's the evidence? *Clin Dermatol* 2021; **39**: 52–55.
- 5 Weidinger S, Beck LA, Bieber T, Kabashima K, Irvine AD. Atopic dermatitis. *Nat Rev Dis Primers* 2018; **4**: 1.
- 6 Donlan AN, Sutherland TE, Marie C *et al*. IL-13 is a driver of COVID-19 severity. *JCI Insight* 2021; **6**: e150107. <https://doi.org/10.1172/jci.insight.150107>
- 7 Kartal SP, Celik G, Yilmaz O *et al*. The impact of COVID-19 pandemic on psoriasis patients, and their immunosuppressive treatment: a cross-sectional multicenter study from Turkey. *J Dermatolog Treat* 2021; **32**: 1–8. <http://doi.org/10.1080/09546634.2021.1927947>
- 8 Wang J, Jiang M, Chen X, Montaner LJ. Cytokine storm and leukocyte changes in mild versus severe SARS-CoV-2 infection: Review of 3939 COVID-19 patients in China and emerging pathogenesis and therapy concepts. *J Leukoc Biol* 2020; **108**: 17–41.
- 9 Gregório P, da Cunha RS, Biagini G *et al*. Chloroquine may induce endothelial injury through lysosomal dysfunction and oxidative stress. *Toxicol Appl Pharmacol* 2021; **414**: 115412.
- 10 Shen WX, Luo RC, Wang JQ, Chen ZS. Features of cytokine storm identified by distinguishing clinical manifestations in COVID-19. *Front Public Health* 2021; **9**: 671788.

DOI: 10.1111/jdv.17635

## Changes in the incidence of contagious infectious skin diseases after the COVID-19 outbreak

COVID-19, which first emerged at the end of 2019 and spread worldwide in 2020, has caused many deaths and remains prevalent. To reduce the infection and spread of COVID-19, various methods of personal hygiene are currently being emphasized. In this study, we evaluated changes in the incidence of contagious infectious skin diseases treated in dermatology clinics to determine whether they were associated with improvements in personal hygiene after the COVID-19 outbreak.

We retrospectively reviewed the medical records of patients who visited our hospitals each year in 2018, 2019 and 2020. We counted the number of patients diagnosed with contagious infectious skin diseases such as impetigo, molluscum contagiosum (MC), scabies and varicella. Because there was no lockdown in South Korea and teleconsultations were encouraged for patients with fever or other COVID-19 symptoms, the study was

conducted with the assumption that COVID-19 did not affect the total number of hospitalized patients. If a patient returned within 3 months with the same symptoms, it was counted as a revisit, while if a patient revisited after more than 3 months had passed, he or she was counted as a new patient.

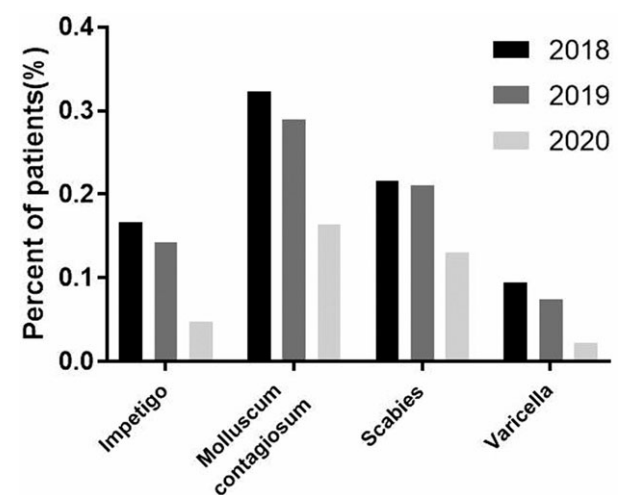
The statistical analysis was performed using GraphPad Prism (version 7.04, GraphPad Software, San Diego CA, USA). We used student's t-test to determine whether there were any significant differences in the incidence rates of impetigo, MC, scabies and varicella between 2018–2019 and 2019–2020. A *P*-value <0.01 was considered statistically significant.

The number and percentage of patients diagnosed with impetigo, MC, scabies and varicella and the total numbers of our dermatology outpatient clinic in 2018, 2019 and 2020 were summarized in the table (Table 1). From 2018 to 2020, patients diagnosed with impetigo, MC, scabies and varicella showed a decreasing trend (Fig. 1). Since the total number of patients who visited the clinic differed each year, the number of patients in each disease group was divided by the total number of patients

**Table 1** The number and percentage of patients for each disease and the total numbers of dermatology outpatient clinic in each year of 2018, 2019 and 2020

	2018	2019	2020
Impetigo	219 (0.1664)	184 (0.1423)	57 (0.0476)
Molluscum contagiosum	425 (0.3228)	375 (0.2899)	197 (0.1646)
Scabies	285 (0.2165)	273 (0.2111)	156 (0.1303)
Varicella	124 (0.0942)	96 (0.0742)	27 (0.0226)
Total dermatology outpatient clinic	131 647	129 341	119 705

Values are presented as number (%).



**Figure 1** Percentage of patients diagnosed with impetigo, molluscum contagiosum, scabies and varicella in 2018, 2019 and 2020.

per year, and then, a *t*-test was performed. There was no significant difference in the incidence rates of impetigo, MC, scabies and varicella between 2018 and 2019 ( $P = 0.019$ ), but there was a significant decrease in the incidence of contagious infectious diseases between 2019 and 2020 ( $P = 0.005$ ).

COVID-19 continues to have negative social and economic impacts worldwide. One positive change that has emerged, however, is an increased interest in hand hygiene and wearing a mask. This improvement in hand hygiene significantly reduced the incidence of impetigo, MC, scabies and varicella, which are transmitted through person-to-person contact, compared to the incidence of these infectious diseases before the outbreak of COVID-19. In the case of varicella, which is spread through both airborne and direct contact routes, the increase in mask wearing also seems to have contributed to a decrease in the incidence of this virus' spread. Hand washing with soap is effective at reducing microbial contamination.<sup>1</sup> Mask wear has increased during the COVID-19 pandemic, and Hsu *et al.*<sup>2</sup> reported a reduction of influenza infections in Taiwan, and Sakamoto *et al.*<sup>3</sup> noted lower seasonal influenza activity during the COVID-19 period in Japan, which were similar to our results regarding varicella. As most of the infectious diseases seen in dermatology clinics are transmitted through contact, hand hygiene seems to have a large impact on skin infections.

Until now, many papers have reported a reduction in respiratory diseases in the COVID-19 era from increased mask use, but few papers have described a reduction in contagious infectious skin diseases related to hand hygiene and mask wearing. This study demonstrated a significant decrease in contagious infectious skin diseases with improved hand hygiene and mask use after the COVID-19 outbreak. Therefore, thorough personal hygiene may help prevent the spread of diseases and should be promoted even after the end of the COVID-19 era.

### Funding sources

None.

### Acknowledgements

None.

### Conflicts of interest

All authors declared that they have no conflicts of interest.

### Data availability statement

Data are openly available in a public repository that issues data sets with DOIs.

E.J. Chun,  J.K. Kim,  S.Y. Yang,  S.S. Kim,   
C.W. Kim 

Department of Dermatology, Kangdong Sacred Heart Hospital, Hallym University College of Medicine, Seoul, Korea

\*Correspondence: C.W. Kim. E-mail: sky\_stella74@naver.com

### References

- 1 Freeman MC, Stocks ME, Cumming O *et al.* Hygiene and health: systematic review of handwashing practices worldwide and update of health effects. *Trop Med Int Health* 2014; **19**: 906–916.
- 2 Hsu YL, Lin HC, Wei HM, Lai HC, Hwang KP. One benefit of COVID-19 measures in Taiwan: The reduction of influenza infections and severe complications. *Influenza Other Respir Viruses* 2020; **14**: 757–758.
- 3 Sakamoto H, Ishikane M, Ueda P. Seasonal influenza activity during the SARS-CoV-2 outbreak in Japan. *JAMA* 2020; **323**: 1969–1971.

DOI: 10.1111/jdv.17640

## Erythema annulare centrifugum triggered by SARS-CoV-2 infection

Erythema annulare centrifugum (EAC) is a reactive phenomenon of the skin that has been reported to occur in association with numerous conditions, including infections.<sup>1</sup> It commonly presents with annular, erythematous plaques with a fine desquamation in the inner portion of the advancing edge.<sup>2</sup> In the last year, a wide spectrum of cutaneous manifestations has been associated with SARS-CoV-2 infection, including acral areas of erythema with vesicles or pustules, other vesicular eruptions, urticarial lesions, maculopapular eruptions and livedo or necrosis.<sup>3,4</sup>

A 37-year-old otherwise healthy woman presented with a 1-week history of itching skin lesions on the arms and back. She referred history of fever, headache and malaise 2 weeks before the onset of these lesions. A nasopharyngeal reverse transcription-polymerase chain reaction (RT-PCR) was positive for SARS-CoV-2 at that time. Physical examination revealed multiple erythematous papules and annular plaques with central clearing and a delicate scale on the inner margin on the upper arms and back (Fig. 1). Potassium hydroxide test was negative. Histopathology showed a prominent perivascular lymphocytic infiltrate on papillary dermis and occasionally on reticular dermis, with endothelial tumefaction, hematic extravasation and sparse interstitial eosinophils (Fig. 2). Clinicopathologic findings were compatible with EAC. A routine laboratory work-up had no alterations. Treatment with clobetasol propionate 0.05% cream was applied once daily for 2 weeks with completely resolution of the lesions.

EAC is a gyrate erythema characterized by erythematous papules that expand centrifugally with central clearing resulting in annular plaques.<sup>2</sup> Typically, a fine scale is present in the inner portion of the advancing edge, known as trailing scale.<sup>2</sup> Pruritus is variable, and the most frequent localizations are the trunk and lower extremities.<sup>1</sup> EAC is thought to be a delayed-type hypersensitivity response to a wide variety of antigens. Possible triggers may include viral, bacterial or fungal infections, medications,