

Female Urology

Sacral Neuromodulation for Bladder Atony – A Case Report

Joseph Sujka^{a,*}, Tyler Zeoli^b, Joseph M. Ciccone^c^a St. George's University School of Medicine, Grenada^b College of the Holy Cross, Worcester, MA^c Harvard Medical School, Boston, MA

ARTICLE INFO

Article history:

Received 3 December 2013

Received in revised form

5 December 2013

Accepted 6 December 2013

Keywords:

Sacral neuromodulation

Fowler's syndrome

Urinary retention

Bladder atony

ABSTRACT

In most cases, sacral neuromodulation is used as a treatment for urge incontinence and symptoms of urgency and frequency. It is most used in those who are refractory to traditional management. It is much less common to be used for bladder atony. In this report, we present a case of a 24-year-old woman with a history of urinary retention and bladder atony who failed medical management and subsequently had an InterStim sacral neuromodulator implanted. After implantation, she was able to discontinue intermittent catheterization and had a decrease in her postvoid residual from 848 to 72 mL.

© 2014 The Authors. Published by Elsevier Inc. Open access under [CC BY-NC-ND license](http://creativecommons.org/licenses/by-nc-nd/4.0/).

Introduction

Sacral neuromodulation (ie, InterStim) has been shown to be an effective treatment for a variety of bladder control issues. It was first introduced by Tanagho and Schmidt in 1981 and approved by the Food and Drug Administration for the treatment of urge incontinence in 1991. In 1999, it was approved for the treatment of urinary retention and urinary frequency.¹ This technique involves the surgical implantation of a device in the abdomen or buttock region, which is then attached to an electrode to stimulate sacral nerves.² InterStim uses electrical impulses to modulate afferent sacral signals through inhibition. These impulses modulate the nerves and muscles used to control the bladder.³ This reversible treatment option has been shown to be successful in existing research.

Specifically, current research has shown that sacral neuromodulation can be used to successfully treat urinary urge incontinence, urgency frequency, urinary retention, and even fecal incontinence.² Recent research focuses primarily on sacral neuromodulation in conjunction with non-neurogenic urinary tract dysfunction.¹ However, a study by Wallace et al³ demonstrated the

effectiveness of sacral neuromodulation on patients with underlying neurologic disease, ranging from multiple sclerosis and Parkinson disease to spina bifida and spinal cord disease. This research seems to indicate that InterStim therapy can be successful in cases of nonobstructive bladder control issues in patients with neurogenic or non-neurogenic causes.

Case presentation

EM is a 24-year-old woman who presented with a history urinary retention brought on by stress since early premenstrual childhood. She reported multiple episodes in which she would become spontaneously unable to urinate and have painless retention. This necessitated multiple trips to the emergency room, in which a catheter was temporarily placed for urinary retention. She had no pertinent past urologic history except for these episodes. She had no known neurologic issues and no history of constipation.

After a recent episode of stress urinary retention, the patient presented to the office for outpatient urologic evaluation. A maximum postvoid residual (PVR) was found to be 848 mL. A trial of Flomax was given but discontinued because of orthostatic side effects. At this time, the patient underwent urodynamics (UDS). She was found to have no sensation of filling at 464 mL with no measurable detrusor voiding pressure (Fig. 1). Findings were most consistent with an atonic, high capacity bladder. Her surface patch electromyography recording was normal, and she was unable to void after UDS.

* Corresponding author. Tel.: +1-321-439-7808.

E-mail address: josephsujka@gmail.com (J. Sujka).

At this time, she was begun on intermittent catheterization four times daily. She reported no difficulty self-catheterizing but had several catheter-associated urinary tract infections and was treated appropriately with standard oral antibiotics. After 3 months of intermittent catheterization and no significant reduction in her PVR,

she underwent a magnetic resonance imaging of the spine to rule out an occult neurologic process. Imaging studies showed no evidence of cystic ovaries or occult neurologic processes. She was considered for reduction cystoplasty surgery, but in an effort to avoid major surgery, she instead underwent a sacral neuromodulation test procedure.

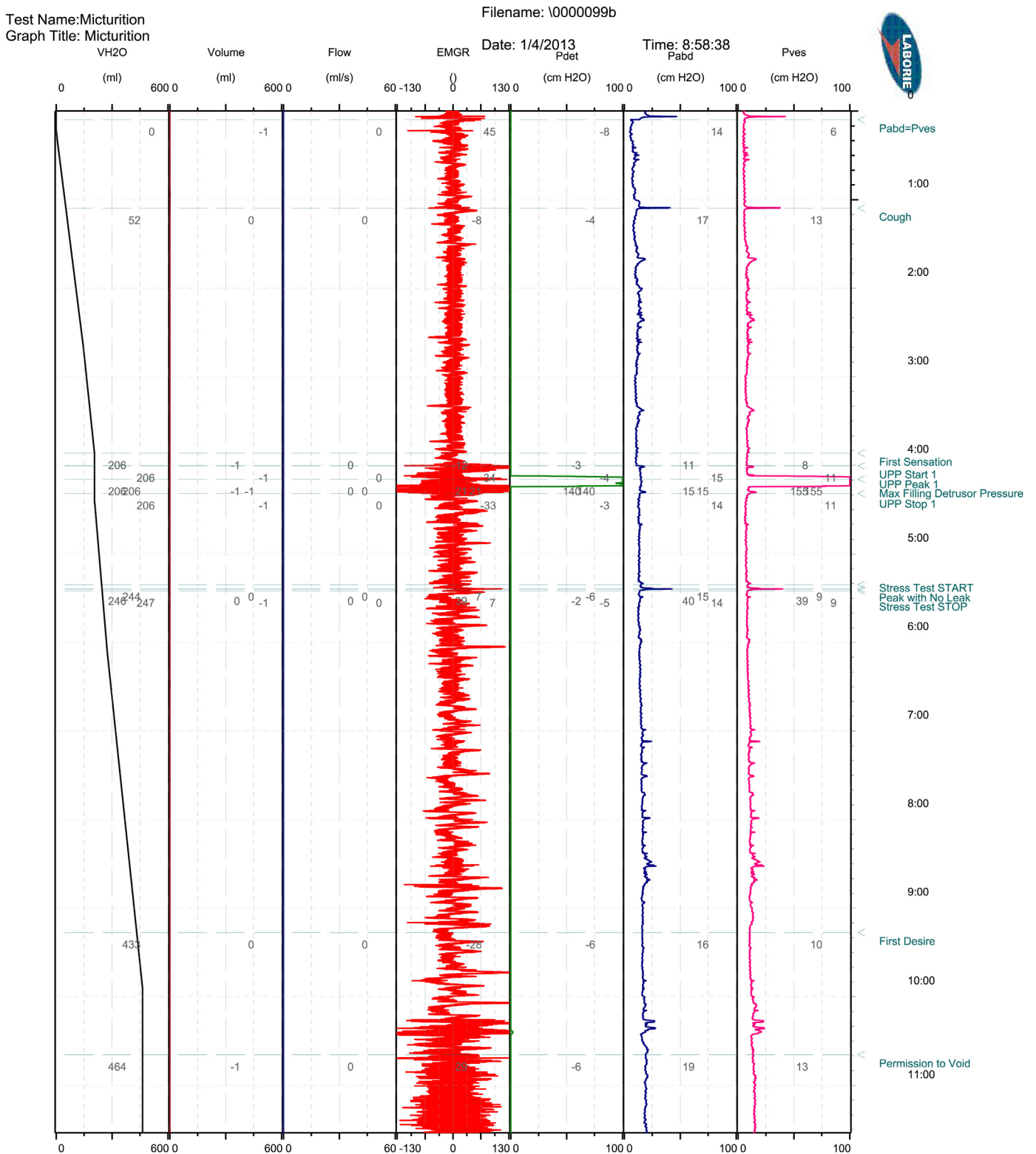


Figure 1. Urodynamics Study of our Patient.

The test procedure was performed under fluoroscopic guidance using the Medtronic unit. With reduction in the frequency of catheterization to twice daily, her residual volume was reduced to 100 mL on follow-up just 2 weeks later. She subsequently underwent generator placement and has been able to wean off of catheterization entirely with a most recent PVR of 72 mL.

Discussion

Typically, sacral neuromodulation has been used for the treatment of urge incontinence and symptoms of urgency and frequency. Its use for the treatment of urinary retention and bladder atony is less well established. Jonas et al¹ studied 177 patients with chronic urinary retention refractory to standard therapy. These patients were qualified for surgical implantation of InterStim through a 3–7-day percutaneous test. Those with a 50% or greater improvement in baseline voiding symptoms were then enrolled into a control group (n = 31) or an implantation group (n = 37). Of those patients treated with implants, 69% eliminated the need for intermittent catheterization, and an additional 14% had a >50% reduction of catheterization volume. A decrease in PVR was found in 83% of the implanted group as compared with 9% of the control group at 6 months. These findings were found to be statistically significant and were maintained even after a trial deactivation of the implant. This indicates that although the implant did not treat the underlying pathology, it did modulate the underlying dysfunctional system and allowed for more normal voiding.

A smaller study by Denzinger et al⁴ examined reduction of intermittent catheterization with sacral neuromodulation. Twenty patients were enrolled to receive InterStim, and it was found that 18 of 20 (90%) had a decrease in their PVR and the number of catheterizations per day. The results did not reach statistical significance, but the author hypothesized this was because of the small size of the study.

Chaabane et al⁵ further examined sacral neuromodulation for treating neurogenic bladder. Over a 10-year interval, 62 patients were evaluated for placement of a sacral device; of these, only 37 were implanted. Of the original 62 patients, 28 were noted to have urinary retention; however, it is not indicated how many of the 37 implants were placed in this population. The remaining population had detrusor overactivity (n = 34) or detrusor-sphincter dyssynergia (n = 9). In the implanted population, 75% had a 50% or greater improvement of their UDS testing.

One possibility is that our patient had Fowler's syndrome. This syndrome is characterized by painless urinary retention in young women and is thought to be because of failure of urethral sphincter relaxation.⁶ Typically, patients are approximately between the ages of 20–35 years at first presentation and have a triggering event, such

as an operation or childbirth. This leads to infrequent voiding and intermittent stream, which then progress to urinary retention. The definitive test for diagnosis is electromyography sampling of the urethral sphincter using a concentric needle electrode. Although it is not possible to retrospectively rule out this syndrome, our patient had characteristics that were different from patients with typical Fowler's syndrome. She had complete bladder atony, whereas patients with Fowler's syndrome usually have some measurable detrusor voiding pressure. As well, our patient had experienced these episodes since very early childhood and only had stress as a precipitating event. A smaller point is that she had no cysts in her ovaries which can be seen in >50% of patients with Fowler's syndrome. If the patient did have Fowler's syndrome, she was treated appropriately, as sacral neuromodulation is the treatment of choice for this syndrome.

In our case, the patient clearly benefited from her implant and further supports the use for sacral neuromodulation for the management of refractory urinary retention and bladder atony, not just urge incontinence and symptoms of urgency and frequency.

Conclusion

The use of sacral neuromodulation for urinary retention is not new, but its efficacy and utility for complete bladder atony have yet to be fully established. To our knowledge, sacral neuromodulation has not been reliably shown to be efficacious in cases of severe bladder atony. This case reiterates that sacral neuromodulation might be a valuable tool in this setting, and in light of our findings, bears further investigation by the urologic community as to the continued expansion of its indications. Clearly, in this case, it was a valuable and spared our patient from both ongoing self-catheterization and major surgery.

References

1. Jonas U, Fowler CJ, Chancellor MB, et al. Efficacy of sacral nerve stimulation for urinary retention: results 18 months after implantation. *J Urol*. 2001;165:15–19.
2. Medical Advisory Secretariat. Sacral nerve stimulation for urinary urge incontinence, urgency-frequency, urinary retention, and fecal incontinence: an evidence-based analysis. *Ont Health Technol Assess Ser*. 2005;5:1–64.
3. Wallace P, Lane F, Noblett K. Sacral nerve neuromodulation in patients with underlying neurologic disease. *Am J Obstet Gynecol*. 2007;197:96.e1–96.e5.
4. Denzinger S, Nowrotek A, Weingart P, et al. Does sacral neuromodulation lead to relevant reduction in the need for intermittent catheterization? a single-center experience on patients with chronic urinary retention. *Neuromodulation*. 2012;15:586–591.
5. Chaabane W, Guillotreau J, Castel-Lacanal E, et al. Sacral neuromodulation for treating neurogenic bladder dysfunction: clinical and urodynamic study. *Neurourology Urodyn*. 2011;30:547–550.
6. Swinn M, Fowler C. Isolated urinary retention in young women, or Fowler's syndrome. *Clin Auton Res*. 2001;11:309–311.