

Case report

BRCA1 reversion mutation acquired after treatment identified by liquid biopsy



Paul Mayor^{a,**}, Laurie M. Gay^b, Shashikant Lele^a, Julia A. Elvin^{b,*}

^a Roswell Park Cancer Institute, Buffalo, NY, USA

^b Foundation Medicine, Inc., Cambridge, MA, USA

ARTICLE INFO

Keywords:

Ovarian serous carcinoma

BRCA1

Olaparib

Comprehensive genomic profiling

1. Introduction

Patients with breast or ovarian cancers harboring *BRCA1/2* mutations have clinically benefitted from treatment with inhibitors of poly (ADP-ribose) polymerase (PARPi) or platinum compounds, but acquired resistance to these therapies can limit clinical benefit. A variety of genomic alterations can lead to loss of *BRCA1/2* activity, including nonsense or frameshift alterations and large scale genomic deletions or rearrangements. Previous studies have identified secondary mutations in both *BRCA1/2* that restore, at least partially, homologous repair capabilities and allow tumors to escape inhibition by PARPi or platinum-based therapies (Wang et al., 2016a; Wang et al., 2016b; Drost et al., 2016; Bouwman and Jonkers, 2014). Detecting these reversion alterations in *BRCA1/2* after disease progression following treatment with PARPi or platinum compounds can provide valuable information to be considered when modifying treatment plans. We report here the acquisition of a reversion mutation in *BRCA1* following treatment of ovarian serous carcinoma with both platinum therapy and the PARPi olaparib. This mutation was detected from circulating tumor DNA using a blood-based next-generation sequencing assay that did not require a tissue biopsy for analysis.

2. Methods

Comprehensive genomic profiling (FoundationOne®, Foundation Medicine, Inc., Cambridge, MA) of a pre-treatment sample obtained during surgical resection was performed as described previously (Frampton et al., 2013). The sequenced sample was from the omentum,

and was one of several observed tumor sites including the falciform ligament, peritoneum, pelvic wall, bilateral ovary and fallopian tube surfaces, serosal aspect colon and rectum, small bowel and hemidiaphragm. In brief, DNA was extracted from 40 μm of formalin-fixed, paraffin-embedded sections, and CGP was performed on a hybrid capture-based library of 315 genes, plus 28 select introns frequently rearranged in cancer (Supplemental Fig. 1). Sequence data were analyzed for clinically relevant classes of genomic alterations, including base pair substitutions, insertions/deletions, copy number alterations, and rearrangements.

At time of progression following treatment with olaparib (400 mg BID), a circulating tumor DNA (ctDNA) genomic profiling assay (FoundationACT™, Foundation Medicine, Inc., Cambridge, MA) was performed to assess potential resistance mechanisms and inform future therapeutic strategy for the patient. The assay is validated in accordance with the Clinical Laboratory Improvement Amendment (CLIA) and was conducted as follows. Two 10 mL aliquots of peripheral whole blood were collected in cell-free DNA blood collection tubes. A double-spin protocol was used to isolate plasma, and 50 ng to 100 ng of ctDNA was extracted to create an adapted sequencing library before hybrid capture and sample-multiplexed sequencing on an Illumina HiSeq 2500 sequencer (Illumina, San Diego, CA). The assay evaluates 62 genes (Supplemental Fig. 1) to ×5000 unique coverage and can identify alterations at low allele frequencies (0.1% for substitutions, 1% for indels and rearrangements, and 20% for copy number amplifications). These 62 genes are a subset of those interrogated with the tissue-based assay. Mutant allele frequency (MAF) for the tissue-based assay represents the percentage of DNA obtained from the mutation-containing tumor on

* Corresponding author at: Foundation Medicine, Inc., 150 Second Street, Cambridge, MA 02141, USA.

** Corresponding author.

E-mail addresses: paul.mayor@roswellpark.org (P. Mayor), jelvin@foundationmedicine.com (J.A. Elvin).

<http://dx.doi.org/10.1016/j.gore.2017.06.010>

Received 27 February 2017; Received in revised form 14 June 2017; Accepted 17 June 2017

Available online 21 June 2017

2352-5789/ © 2017 The Authors. Published by Elsevier Inc. This is an open access article under the CC BY-NC-ND license (<http://creativecommons.org/licenses/by-nc-nd/4.0/>).

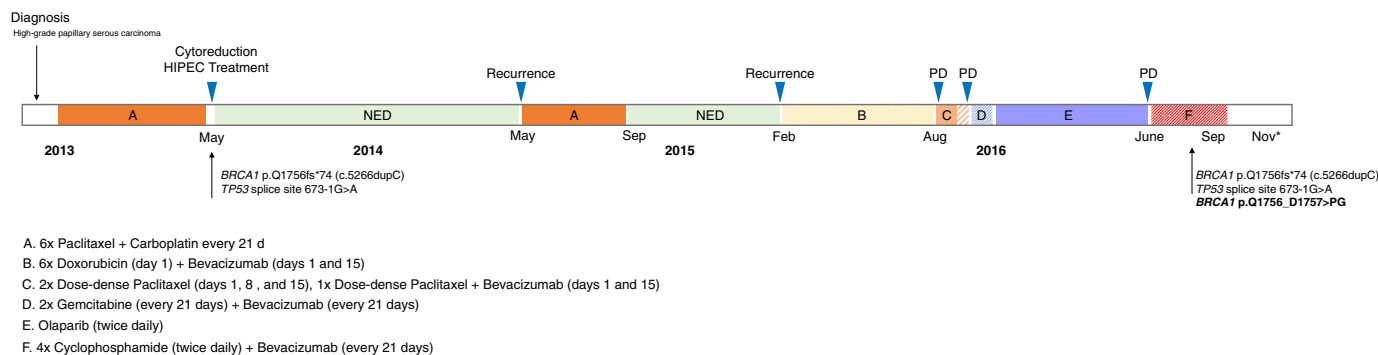


Fig. 1. Timeline of disease course from diagnosis onward. The patient received germline genetic testing in December 2015, which revealed the BRCA1 alteration c.5266dupC. Comprehensive genomic profiling was subsequently performed on the tumor resection sample obtained in May 2013 and on a liquid biopsy sample obtained in August 2016. The results of both CGP analyses revealed the germline BRCA1 alteration, as expected. In addition, the ctDNA sequenced post-treatment (Aug 2016) revealed the acquisition of a BRCA1 mutation that is expected to restore some level of BRCA1 protein functionality.

which a biopsy was performed. In the blood, MAF represents the percentage of ctDNA in the bloodstream that is harboring the mutation on a given day and time. For this reason, MAF for the tissue assay and ctDNA assays cannot be directly compared.

The listed price for each assay is \$5800, although actual cost will vary depending on circumstances. Approval for this study, including a waiver of informed consent and a HIPAA waiver of authorization, was obtained from the Western Institutional Review Board (IRB# 20152817).

3. Results

The patient is a 58-year-old Caucasian female who was initially seen at our institution in December of 2012 after being diagnosed with peritoneal carcinomatosis based on computed tomography (CT) of her abdomen and pelvis (Fig. 1). A paracentesis was performed and the fluid sample was found to be positive for adenocarcinoma of uncertain origin. Given her uncertain primary disease site, she was initially managed by colorectal surgery and was taken to the operating room for a diagnostic laparoscopy with biopsy. This revealed a large volume of straw colored ascites, omental caking and large volume tumor implants along the anterior abdominal wall, both hemi-diaphragms, the sigmoid colon, and the peritoneal surfaces in the pelvis and upper abdomen. Pathology from her omentum and pleural effusions revealed high grade papillary serous carcinoma, likely of ovarian origin. Given her advanced stage disease, high tumor burden, and likely need for extensive resection to achieve an optimal tumor debulking status, she was initially treated with the neoadjuvant chemotherapy regimen of carboplatin AUC 6 plus paclitaxel 175 mg/m² every 21 days for 6 cycles, followed by interval cytoreduction and heated intraperitoneal chemotherapy (HIPEC) treatment with mitomycin C for 90 min. She completed this surgery in May of 2013. Both prior to and after her diagnosis of ovarian cancer, the patient did not have any other cancer diagnoses made.

She was without evidence of disease until May of 2014 when she underwent a surveillance CT scan of her chest, abdomen and pelvis which revealed a recurrence. Given her platinum sensitivity, she was started on carboplatin AUC 6 plus paclitaxel 175 mg/m² every 21 days and completed 6 cycles in September of 2014. She was without disease until February of 2015. She was started on doxorubicin 40 mg/m² (day 1) plus bevacizumab 10 mg/kg (days 1 and 15), completing 6 cycles in August 2015. She was noted to have disease progression at that time and was referred to the Gynecologic Oncology service for clinical trial consideration.

After review of her treatment course and current disease state by the gynecologic oncology service, she was referred to the Clinical Genetics service for germline genetic testing and started on dose dense paclitaxel 80 mg/m² (Days 1, 8, and 15). After 2 cycles, the patient was noted to

have re-accumulation of large volume ascites requiring frequent paracentesis; therefore, bevacizumab 10 mg/kg (days 1 and 15) was added to her chemotherapy regimen. She completed a third cycle of dose dense paclitaxel with bevacizumab and CT imaging revealed progression of disease in December 2015. Her chemotherapy regimen was switched to gemcitabine 800 mg/m² plus bevacizumab 15 mg/m² every 21 days, and she completed two cycles. At this time, the patient met with the clinical genetics service and underwent germline genetic testing with the *OvaNext* panel through Ambry Genetics. This panel tests for deletion/duplication analysis of the following 23 genes: ATM, BARD1, BRCA1, BRCA2, BRIP1, CDH1, CHEK2, MLH1, MRE11A, MSH2, MSH6, MUTYH, NBN, NF1, PALB2, PMS2, PTEN, RAD50, RAD51C, RAD51D, SMARCA4, STK11, and TP53, as well as deletion/duplication analysis of the EPCAM gene. Her testing revealed a BRCA1 gene mutation (c.5266dupC, p. Q1756fs*74) and the remainder of her germline results were negative. In January 2016, she had increased abdominal pain and CT revealed disease progression (Fig. 2). Given her BRCA1 mutation, she started on olaparib 400 mg PO twice daily and completed approximately 6 months of therapy in June of 2016. While on olaparib the patient had a partial response to this therapy with reduction in size of her intraperitoneal tumor burden as evidenced on CT imaging done in May of 2016 (Fig. 2). She also had a plateau in her CA125 during her final three months of olaparib treatment: April, May and June (Fig. 3). Her olaparib was discontinued after 6 months of therapy due to intraperitoneal disease progression noted clinically by re-accumulation of ascites and CT imaging performed in June of 2016 showing progression. In May 2016, molecular genetic testing was completed on her omental tumor sample obtained in May of 2013 (FoundationOne). This testing revealed the previously identified germline BRCA1 mutation (p.Q1756fs*74, c.5266dupC) as well as an inactivating TP53 mutation (splice site 673-1G > A). This BRCA1 alteration would prematurely truncate the protein and disrupt the BRCT domains of BRCA1, if expressed. Alternatively, protein levels could be reduced through nonsense mediated decay. The BRCT domains of BRCA1 are responsible for interactions with a variety of additional proteins and protein complexes.

In June of 2016, due to disease progression, she was started on cyclophosphamide 50 mg PO twice daily and bevacizumab 15 mg/kg once every 3 weeks. She remained on this therapy until the end of September. In late August of 2016, sequencing of the patient's ctDNA detected 3 mutations: the previously identified TP53 splice site alteration and BRCA1 p.Q1756fs*74, as well as BRCA1 p.Q1756_D1757 > PG (c.5263_5272 > TCCCCAGGAC). The effect of the second BRCA1 alteration, p.Q1756_D1757 > PG, appears to serve as a reversion alteration that restores the translational reading frame of the expressed BRCA1 protein (Fig. 4). This alteration would occur within a loop region of the BRCT domain, just past an alpha helical domain (see A), and would maintain a similar distance between folded elements of the

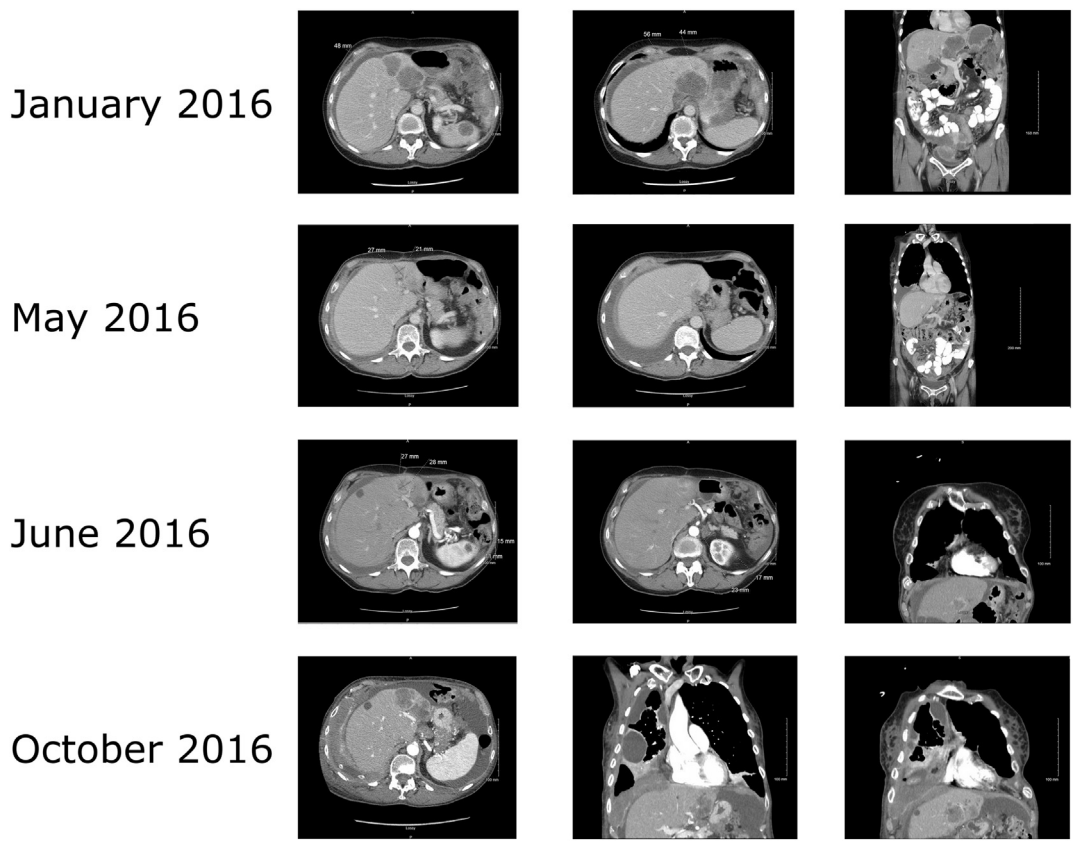


Fig. 2. CT scans showing disease progression between January 2016 and October 2016. 1 A–C, January 2016. A. Significant interval progression of diffuse metastatic disease in the abdomen and pelvis including hepatic metastases (as indicated by the white arrows), splenic metastasis, diffuse omental and peritoneal carcinomatosis (including extensive serosal involvement of the stomach and bowel), diffuse pelvic tumor compressing the rectum and urinary bladder, metastatic lymphadenopathy, and several abdominal wall metastases. 2 D–F, May 2016. Extensive peritoneal carcinomatosis throughout the abdomen and pelvis and liver metastases which appears markedly improved since 1/6/2016 (as indicated by the white arrows). 3 G–I, June 2016 G. No pulmonary embolus. H. Hepatic metastases. There is interval growth and prominent enhancement of the left hepatic mass (as indicated by the white arrow). Other included hepatic metastases are not significantly hyperenhancing and remain similar in size and relatively low in density. 4 J–L, October 2016, Interval increase of extensive peritoneal and omental carcinomatosis in the visualized portions of the abdomen and pelvis with interval increase of large pelvic masses. Interval increase of hepatic masses/metastasis (as indicated by the white arrows). Interval increase of ascites in the visualized abdomen and pelvis.

protein. Such a change in a loop region may be tolerated and the effect of this alteration could be to restore the capacity for DNA repair. The germline alteration, p.Q1756fs*74, was observed at nearly 50% allele frequency, as expected. The reversion alteration was observed at a minor allele frequency of 3.2%.

The patient unfortunately continued to develop recurrent ascites and pleural effusions requiring peritoneal drain placement and bilateral chest tube catheters for symptomatic management. She elected to proceed with comfort measures in October of 2016 and expired in November of 2016.

4. Discussion

Previous studies have reported a variety of mechanisms by which

BRCA1 activity can be restored, at least partially, through additional mutation or alternative splicing. This reversion can underlie resistance to therapies targeting cells deficient in DNA damage repair (Wang et al., 2016a; Wang et al., 2016b; Drost et al., 2016; Bouwman and Jonkers, 2014). In this study, we report the detection of a BRCA1 reversion mutation in ctDNA, assayed with a liquid biopsy-based, next-generation sequencing assay. The alteration was acquired after several rounds of platinum therapy and treatment with the PARPi olaparib, although it is not possible in this case to determine exactly when during treatment the second BRCA1 alteration arose (Fig. 1). The isolation of ctDNA from blood and comprehensive sequencing of BRCA1 provides a method for interrogating the mutational status of tumors that progress on therapy without the need for an invasive biopsy. In addition to detecting the small insertion and deletion present in this sample, a comprehensive

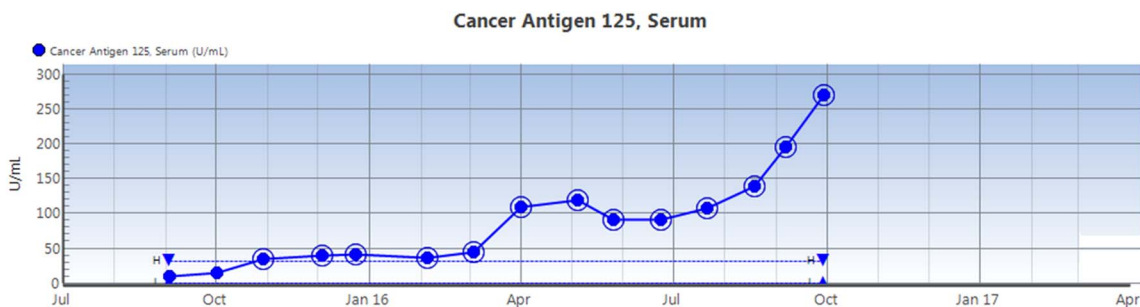


Fig. 3. Serum CA125 trend from September 2015 to October 2016, showing a plateau from April to June of 2016 and subsequent rapid increase.

A. wild-type *BRCA1*

c. 5239 CAA GGT CCA AAG CGA GCA AGA GAA TCC CAG GAC AGA AAG *gtaaagct...*
 p. 1748 Q G P K R A R E S Q D R K (intron)



B. Q1756fs*74 (c.5266dupC)

c. 5239 CAA GGT CCA AAG CGA GCA AGA GAA TCC CCA GGA CAG AAA Ggt aaa gct...
 p. 1748 Q G P K R A R E S P G Q K G K ... +69

C. Q1756_D1757>PG (c.5263_5272>TCCCCAGGAC)

c. 5239 CAA GGT CCA AAG CGA GCA AGA GAA TCC CCA GGA C_GA AAG *gtaaagct...*
 p. 1748 Q G P K R A R E S P G R K (intron)

Fig. 4. Sequences observed in the circulating tumor DNA (ctDNA) obtained by liquid biopsy post-treatment reveal two alterations in *BRCA1*. A. The sequence of wild-type *BRCA1* from c.5239 to c.5277, the end of exon 19 (NM_007294). B. The alteration c.5266dupC introduces a frameshift beginning at Q1756. This would prematurely truncate the protein and disrupt the BRCT domains of *BRCA1*. The BRCT domains of *BRCA1* are responsible for interactions with a variety of additional proteins and protein complexes. C. The reversion alteration observed would alter the encoded protein sequence within the BRCT domains from 1755 Ser-Gln-Asp-Arg 1785 to 1755 Ser-Pro-Gly-Arg 1785. This alteration would occur within a loop region of the BRCT domain, just past an alpha helical domain (see A), and would maintain a similar distance between folded elements of the protein. Such a change in a loop region may be tolerated and the effect of this alteration could be to restore the capacity for DNA repair.

sequencing assay can detect a variety of previously known and unknown genomic alterations, including missense mutations, larger deletions, or rearrangements that could impact response to treatment.

The detection of *BRCA* reversion mutation in circulating tumor DNA has been reported (Christie et al., 2017). In Christie et al., sequencing was performed with custom primers developed specifically for each patient sample based on the primary *BRCA* mutation. The methodology in this study does not require a priori knowledge of either the primary *BRCA* mutation or the expected reversion alteration and does not utilize custom primers. The unbiased, comprehensive detection of *BRCA* alterations through a universally applicable bait set, as described here, facilitates rapid, robust analysis in the clinical setting.

Treatment after detection of the second *BRCA1* alteration in this sample was additional chemotherapy, followed by palliative care as the disease continued to progress. Novel strategies for treating tumors with acquired resistance to PARPi are in early stages of investigation, such as inhibition of CDK12 (Johnson et al., 2016) or combinations of therapies such as PARPi, vorinostat, and 6-thioguanine (Yalon et al., 2016).

Supplementary data to this article can be found online at <http://dx.doi.org/10.1016/j.gore.2017.06.010>.

Acknowledgments

This work was supported by Roswell Park Cancer Institute National Cancer Institute (NCI) grant 5T32CA108456.

References

Wang, Y., Bernhardt, A.J., Cruz, C., Kraiss, J.J., Nacson, J., Nicolas, E., Peri, S., van der Gulden, H., van der Heijden, I., O'Brien, S.W., Zhang, Y., Harrell, M.I., Johnson, S.F., Reis, F.J.C.D., Pharoah, P.D.P., Karlan, B., Gourley, C., Lambrechts, D., Chenevix-Trench, G., Olsson, H., Benitez, J.J., Greene, M.H., Gore, M., Nussbaum, R., Sadetzki, S., Gayther, S.A., Kjaer, S.K., kConFab Investigators, D'Andrea, A.D., Shapiro, G.I., Wiest, D.L., Connolly, D.C., Daly, M.B., Swisher, E.M., Bouwman, P., Jonkers, J., Balmaña, J., Serra, V., Johnson, N., 2016a. The *BRCA1*-Δ11q alternative splice

isoform bypasses germline mutations and promotes therapeutic resistance to PARP inhibition and cisplatin. *Cancer Res.* 76, 2778–2790. <http://dx.doi.org/10.1158/0008-5472.CAN-16-0186>.

- Wang, Y., Kraiss, J.J., Bernhardt, A.J., Nicolas, E., Cai, K.Q., Harrell, M.I., Kim, H.H., George, E., Swisher, E.M., Simpkins, F., Johnson, N., 2016b. RING domain-deficient *BRCA1* promotes PARP inhibitor and platinum resistance. *J. Clin. Invest.* 126, 3145–3157. <http://dx.doi.org/10.1172/JCI87033>.
- Drost, R., Dhillon, K.K., van der Gulden, H., van der Heijden, I., Brandsma, I., Cruz, C., Chondronasiou, D., Castroviejo-Bermejo, M., Boon, U., Schut, E., van der Burg, E., Wientjens, E., Pieterse, M., Klijn, C., Klarenbeek, S., Loayza-Puch, F., Elkon, R., van Deemter, L., Rottenberg, S., van de Ven, M., Dekkers, D.H.W., Demmers, J.A.A., van Gent, D.C., Agami, R., Balmaña, J., Serra, V., Taniguchi, T., Bouwman, P., Jonkers, J., 2016. *BRCA1*185delAG tumors may acquire therapy resistance through expression of RING-less *BRCA1*. *J. Clin. Invest.* 126, 2903–2918. <http://dx.doi.org/10.1172/JCI70196>.
- Bouwman, P., Jonkers, J., 2014. Molecular pathways: how can *BRCA*-mutated tumors become resistant to PARP inhibitors? *Clin. Cancer Res.* 20, 540–547. <http://dx.doi.org/10.1158/1078-0432.CCR-13-0225>.
- Frampton, G.M., Fichtenholtz, A., Otto, G.A., Wang, K., Downing, S.R., He, J., Schnell-Levin, M., White, J., Sanford, E.M., An, P., Sun, J., Juhn, F., Brennan, K., Iwanik, K., Maillet, A., Buell, J., White, E., Zhao, M., Balasubramanian, S., Terzic, S., Richards, T., Banning, V., Garcia, L., Mahoney, K., Zwirko, Z., Donahue, A., Beltran, H., Mosquera, J.M., Rubin, M.A., Dogan, S., Hedvat, C.V., Berger, M.F., Pusztai, L., Lechner, M., Boshoff, C., Jarosz, M., Vietz, C., Parker, A., Miller, V.A., Ross, J.S., Curran, J., Cronin, M.T., Stephens, P.J., Lipsun, D., Yelensky, R., 2013. Development and validation of a clinical cancer genomic profiling test based on massively parallel DNA sequencing. *Nat. Biotechnol.* 31, 1023–1031. <http://dx.doi.org/10.1038/nbt.2696>.
- Christie, E.L., Fereday, S., Doig, K., Pattnaik, S., Dawson, S.-J., Bowtell, D.D.L., 2017. Reversion of *BRCA1/2* germline mutations detected in circulating tumor DNA from patients with high-grade serous ovarian cancer. *J. Clin. Oncol.* 35, 1274–1280. <http://dx.doi.org/10.1200/JCO.2016.70.4627>.
- Johnson, S.F., Cruz, C., Greifengberg, A.K., Dust, S., Stover, D.G., Chi, D., Primack, B., Cao, S., Bernhardt, A.J., Coulson, R., Lazaro, J.-B., Kochupurakkal, B., Sun, H., Unitt, C., Moreau, L.A., Sarosiek, K.A., Scaltriti, M., Juric, D., Baselga, J., Richardson, A.L., Rodig, S.J., D'Andrea, A.D., Balmaña, J., Johnson, N., Geyer, M., Serra, V., Lim, E., Shapiro, G.I., 2016. CDK12 inhibition reverses de novo and acquired PARP inhibitor resistance in *BRCA* wild-type and mutated models of triple-negative breast cancer. *Cell Rep.* 17, 2367–2381. <http://dx.doi.org/10.1016/j.celrep.2016.10.077>.
- Yalon, M., Tuval-Kochen, L., Castel, D., Moshe, I., Mazal, I., Cohen, O., Avivi, C., Rosenblatt, K., Aviel-Ronen, S., Schiby, G., Yahalom, J., Amarglio, N., Pfeffer, R., Lawrence, Y., Toren, A., Rechavi, G., Paglin, S., 2016. Overcoming resistance of cancer cells to PARP-1 inhibitors with three different drug combinations. *PLoS One* 11, e0155711. <http://dx.doi.org/10.1371/journal.pone.0155711>.