

Middle term results of tantalum acetabular cups in total hip arthroplasty following pelvic irradiation



Massimiliano De Paolis, Riccardo Zucchini*, Carlo Romagnoli, Matteo Romantini, Federica Mariotti, Davide Maria Donati

IRCCS Istituto Ortopedico Rizzoli, Bologna, Italy

ARTICLE INFO

Article history:

Received 9 April 2018

Received in revised form

4 January 2019

Accepted 3 March 2019

Available online 4 April 2019

Keywords:

Hip

Arthroplasty

Uncemented cup

Tantalum

Radiotherapy

Tumor

ABSTRACT

Objectives: The aim of this study was to evaluate the middle term cup survival, assess the functional implementation and the radiographic evolution of tantalum acetabular cups implanted on patients with a history of pelvic radiotherapy.

Methods: From 2005 to 2013, we performed 12 THA replacements (4 males 8 females; mean age: 46.6 years (range 25–75)) on irradiated bone with Trabecular metal acetabular cups, 8 primary implants and 4 revision implants. The mean radiation dose delivered was 5500 cGy (range 3000 cGy–13,600 cGy). The mean follow-up was 68 months, ranging from 38 to 136. Postoperative follow-up time was assessed at 1, 3, 6 and 12 months, then annually. Double projection radiographs were requested at each control. Radiographic signs of loosening were investigated by X-rays looking for radiolucent lines. We used the Harris hip score for the clinical and functional evaluation.

Results: To now none of the 12 patients in the series needed any revision surgery for aseptic loosening. In the revision group one patient have been revised for septic loosening, two patients have been treated by conservative procedure for hip dislocation. Post-operative Harris hip score improved from an average of 46 points to 85.3 points. At last follow-up we found only in one case radiographic signs of progressive lucent line, without clinical sign of failure.

Conclusion: In a clinical setting, tantalum cup seems to provide a good stability due to the integration of the trabecular metal to the underline cancellous bone. The reported results, in agreement with literature data, propose the use of tantalum cups in irradiated bone.

Level of evidence: Level IV, therapeutic study.

© 2019 Turkish Association of Orthopaedics and Traumatology. Publishing services by Elsevier B.V. This is an open access article under the CC BY-NC-ND license (<http://creativecommons.org/licenses/by-nc-nd/4.0/>).

Introduction

Radiotherapy in the pelvic area is commonly used to treat gastrointestinal and genitourinary carcinomas, bone metastasis, hematopoietic diseases and primary sarcomas.

Radiations can lead different side effects as bone atrophy and secondary complications as osteonecrosis,¹ degenerative arthritis² (Fig. 1), pathologic stress fractures^{3,4} and (less relevant to this study) radio induced sarcomas.

* Corresponding author.

E-mail addresses: massimiliano.depaolis@ior.it (M. De Paolis), riccardo.zucchini@studio.unibo.it (R. Zucchini), c.romagnoli@yahoo.it (C. Romagnoli), mtt.rmn2@gmail.com (M. Romantini), f.mariotti88@gmail.com (F. Mariotti), davidemaria.donati@ior.it (D.M. Donati).

Peer review under responsibility of Turkish Association of Orthopaedics and Traumatology.

It is recently reported a threshold dose of approximately 3000 cGy^{5,6} able to procure irreversible damage to bone tissue. Due to post-radiation bone damage, THAs is often required. However, a high rate of cup loosening is reported in the literature for both cemented and uncemented standard acetabular cups (44 and 52%).^{7–9}

Porous tantalum acetabular implants have potential benefits for acetabular component fixation. Thanks to its high coefficient of friction against the cancellous bone (0.88), the superior percentage of porosity (80%), and high ingrowth rates in vivo, tantalum cups are considered to lead to a great osteointegration with the surrounding bone.^{10–12}

Recently, the use of tantalum implants on bone that was included in the irradiation field, has been reported with good results.^{13,14} However, not much data is available on midterm results of these implants, nor is it clear whether these cups do well on directly irradiated bone.

<https://doi.org/10.1016/j.aott.2019.03.007>

1017-995X/© 2019 Turkish Association of Orthopaedics and Traumatology. Publishing services by Elsevier B.V. This is an open access article under the CC BY-NC-ND license (<http://creativecommons.org/licenses/by-nc-nd/4.0/>).

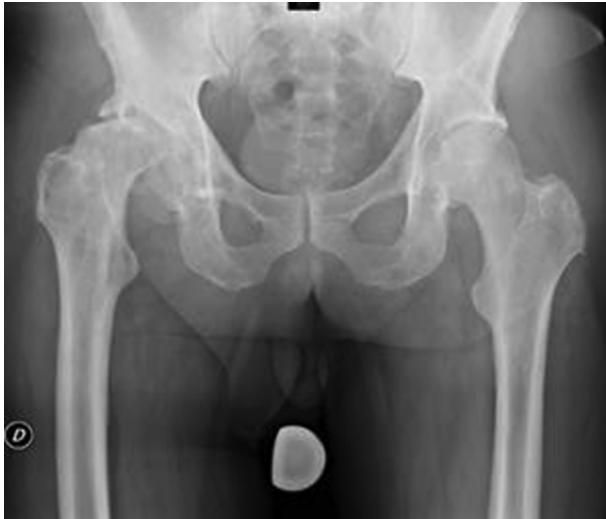

Fig. 1. Pelvic preoperative X-ray film shows evidence of postradiation arthritis. Note the sclerotic bone in the superior acetabular zone.

With this study, we sought to determine the midterm survival rate of tantalum acetabular cups implanted directly on irradiated bone in patient with history of musculoskeletal tumor. Furthermore, we evaluated the functional outcome and radiographic follow-up.

Patients and methods

Using our database from 2005 to 2013, we retrospectively reviewed 14 consecutive oncological patients with a history of therapeutic pelvic irradiation with irradiation field including acetabulum, who underwent THAs with tantalum acetabular components.

We only considered patients with a minimum of a 36-month follow-up (range from 38 to 136 months, mean 68 months).

Two patients have been excluded because they died before the minimum follow up, however, both patients were referred to have a stable implant at the last radiographic control and were functional.

Thus, our final cohort (Table 2) included 12 patients (4 male, 8 female), 8 for the primary THA implant and 4 implanted after a previous failed THA.

The mean age at time of surgery was 46.6 years (range 25–75).

Our institutional review board approved this study, and we recalled all the patients to obtain informed consent.

Primary tumors group included: 2 benign tumors (one aneurismal acetabular cyst, and one giant cell tumor) and 8 malignant tumors (1 myxoid-liposarcoma, 1 multiple myeloma, 1 plasmacytoma, 2 non-Hodgkin lymphomas, 2 Ewing's sarcomas and 1 synovial sarcoma). While, the other two patients were treated for breast cancer metastasis.

Radiation therapy was performed in all patients, even on the aneurismal acetabular cyst (treated in the 1980) and the giant cell tumor (treated in the 2007). Currently we don't use radiotherapy on these benign lesion, but at the time it was more frequently utilized as adjuvants to the surgery. The exact treatment plans and the total acetabular radiation dose was achieved in 9 patients. For the other 3, we relied upon clinical data referring to standard radiation treatment doses according to the pathology treated (4000–7500 cGy).

All together, the mean dose radiation was 5500 cGy (range 3000 cGy–13,600 cGy).

The mean interval between pelvic irradiation and surgery was 6.7 years (1–32 years).

Indications for primary THA were in 5 cases femoral head necrosis, in 1 subchondral acetabular fracture, and in the last 2 cases hip arthritis.

Indications for revision THA were 2 recurrent dislocations, 1 aseptic and 1 septic cup loosening.

In all cases, during the reaming process, the irradiated bone appeared generally more sclerotic and less vascularized than normal bone. No further biopsy was performed to quantify necrosis at a cellular level.

All patients received tantalum acetabular components (Zimmer Corp, Warsaw, Indiana).

Primary THA group received 6 Revision Shell cups and 2 Continuum Cup, while, revision THA group received 2 Revision Shell and 2 Continuum Cups.

After proper acetabular reaming, the primary cup fixation was achieved with multiple screws fixed to the postero-superior face of the acetabulum through the ilium; a supplemental screw was fixed in the direction of the pubic ramus only in one case.

Because of the magnitude of acetabular bone loss, trabecular metal augments were used in 3 patients, fixed to the superior acetabular rim with 2 screws (Fig. 2).

We combined polyethylene liners with CrCo heads in 5 cases and ceramic heads in 7 cases.

A cemented femoral component was used on 6 patients and an uncemented in the other 6 hips.

All patients received standard perioperative antibiotics and thromboembolic prophylaxis with low molecular weight heparin. Moreover, standard postoperative rehabilitation including early mobilization, assisted weight bearing as well as walking with canes, was allowed. General precautions regarding hip ROM were advised at patient discharge.

Postoperative follow-up time was assessed at 1, 3, 6 and 12 months, then annually. Double projection radiographs were requested at each control.

Patients were evaluated functionally and radiographically.

Harris hip score was obtained in all patients before surgical procedure and at last follow-up control. We used one tailed student's t-test to assess the significance of the clinical improvement.

For the radiographic evaluation, we analyzed the acetabular radiolucencies lines using the three zones of the classification described by de Lee and Charnley.¹⁵

Table 1
Data from literature.

Study	Acetabular fixation	N° THA	Mean follow-up (months) (range)	Mean radiation dose (cGy)	Acetabular loosening (%)
Massin et al ⁷	Cemented	42	69 (6–240)	5500	52
	Cemented into acetabular ring	22	40 (6–132)		19
Jacobs et al ⁸	Noncemented	9	37 (17–78)	5551	44
Cho et al ⁹	Noncemented	18	58 (20–139)	5250	50
	Cemented into acetabular ring	4	34 (20–41)		50
Rose et al ¹³	Tantalum Revision Shell cup	12	31 (24–48)	5890	0
Joglekar et al ¹⁴	Tantalum Revision Shell cup	22	78 (56–116)	6300	0

Table 2

Data for 12 patients included in the series.

N°	Age/Gender	Type	Postradiation complications	Primary implant	Previous surgical treatment	FU	Post-op complications
1	41/F	BCM	Acetabular stress fracture	Yes	No	41	No
2	55/M	MM	Avascular necrosis	Yes	No	38	Femoral infection
3	34/F	GCT	Avascular necrosis	Yes	Ischial resection. Local recurrence and reintervention	79	No
4	25/M	ES	Avascular necrosis	Yes	Superior pubic ramus resection + acetabulum	67	No
5	45/F	ABC	Degenerative arthritis	Yes	No	83	No
6	49/F	BCM	Avascular necrosis	Yes	No	100	No
7	45/M	MLS	Avascular necrosis	Yes	No	136	No
8	60/F	NHL	Degenerative arthritis	Yes	Endoprosthesis	50	No
9	51/F	SCS	Cup loosening	No	Femoral megaprosthesis	52	No
10	26/F	ES	Cup loosening	No	Hemipelvectomy + prosthesis + revision 10 years later	38	Hip dislocation
11	52/M	SBP	Cup loosening	No	Artroprosthesis with femoral megaprosthesis	57	Hip dislocation
12	77/F	NHL	Cup loosening + Avascular necrosis	No	Artroprosthesis	76	Septic loosening

BCM = Breast Cancer Metastases; MM = Multiple Myeloma; GCT = Giant cell Tumor; ABC = Aneurysmal bone cyst; ES = Ewing's sarcoma; MLS = Myxoid Liposarcoma; SCS = Synovial cell sarcoma; NHL = Non-Hodgkin lymphoma; SBP = Solitary bone Plasmacytoma.

Finally, we compared complications between primary THA and revision THA using one tailed Fisher's exact test.

Statistical analysis was performed using the website: www.socscistatistics.com.

Results

At a mean follow-up of 68 months, only one patient needed revision surgery for septic loosening, as shown in Kaplan Meier curve (Fig. 3). This patient belonged to the revision group. He was first implanted 46 months before using a Contemporary cup and a Muller ring, which failed 44 months after. After our revision with the tantalum cup he performed well (Harris hip score 83) for 73 months, then he reported pain and was eventually revised by prosthetic retrieval, antibiotic cement spacer and then received a new implant 2 years later.

In the revision group two patients reported hip dislocation treated with conservative procedure.

Primary THA performed better (p value = 0.018) with no acetabular complication.

In one patient (primary THA group) acute infection of the femoral component was registered at 22 months of follow-up, reasonably due to hematogenous spread of bacteria from a mandibular osteonecrosis diagnosed two months before. The femoral infection was

treated with antibiotic therapy and healed with no consequences. No acetabular complication has been registered.

Post-operative Harris hip score improved from an average of 46 points (range 19–67) to 85.3 points (range 64–95).

The score shows considerable and statistically significant clinical improvement (p value = 0.0013). However, there's no significant difference between the primary THA (8 patients) and the revision THA (4 patients) (p value = 0.2888).

We observed no implant migration in any of the hips at final follow up. Only one case (Fig. 4) reported lucencies in zones 2 and 3, starting from 85 months follow-up and now after 126 months the cup is stable without any progressive lucent line or clinical sign of failure.

Discussion

The radiations effects on bone have been first reported by Ewing in 1926.¹⁶ He described a progressive obliterative endarteritis and periarteritis with swelling of endothelial cell, cytoplasm vacuolization and necrosis of vessel wall, which leads to the narrowing of vascular lumen, hypoxia and sclerotic conversion of bone marrow.^{17,18}

Instead, more recent studies focus on the bone cells and matrix changes. Goodman, Sengupta and Prathap,¹⁹ found hypocellularity in irradiated human bone sections, with unaltered blood vessels.

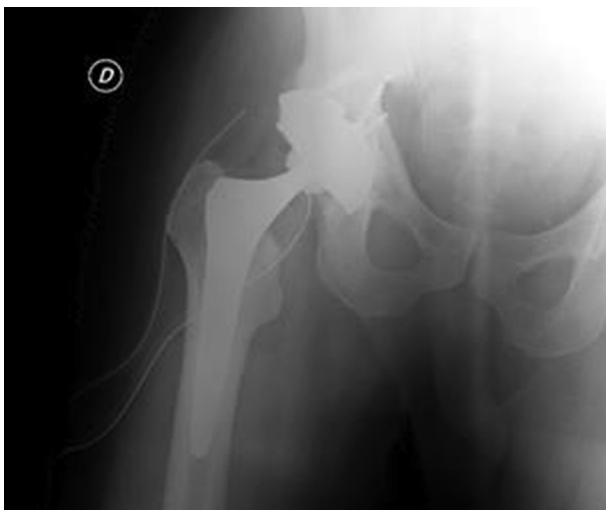

Fig. 2. Same case as in Fig. 1. Postoperative pelvic X-ray film: THA with Revision Shell cup, augment and 4 screws.

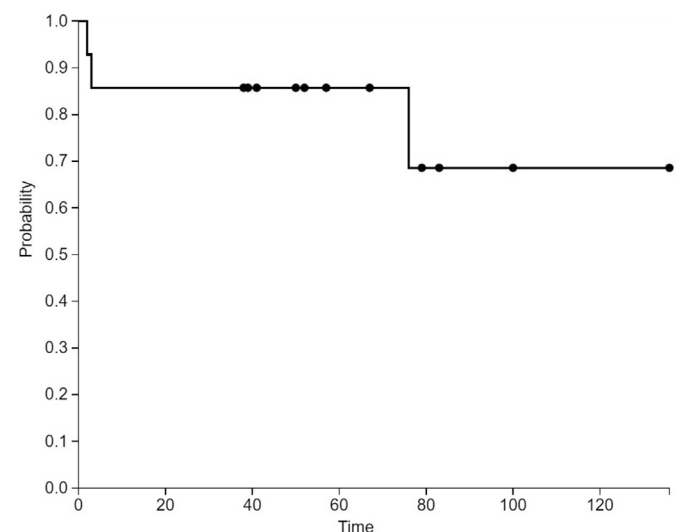


Fig. 3. Kaplan Meier survival analysis.

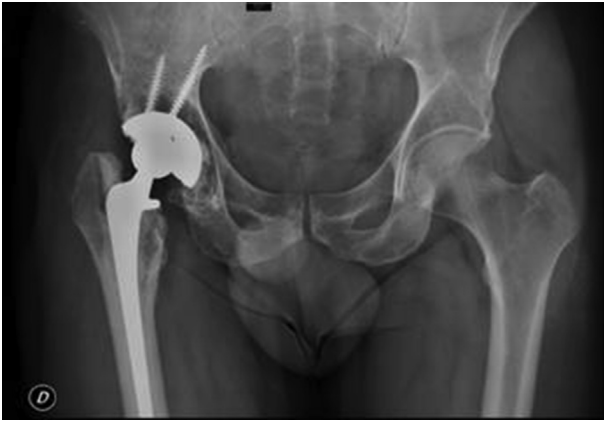

Fig. 4. Pelvic x-ray film performed 96 months postoperatively shows revision shell cup fixed with screws. Radiolucent lines are present in zone 2 and 3. Patient did not refer for any discomfort.

They also proved how osteoblasts are generally more sensitive to radiation than the osteoclasts.

The decreased number of osteoblasts decreases the collagen production and alkaline phosphatase activity and affect the matrix mineralization.

THA conventional surgery in a previous irradiated pelvis is a true challenge in terms of long term cup stability. Previous studies have shown how radiation therapy can affect both cemented and uncemented acetabular components, leading to aseptic loosening. These studies are summed up on [Table 1](#).

Massin and Duparc⁷ reported, at a mean of a 69 month follow-up, a failure rate between 44 and 52% using cemented acetabular component, and 19% after 40 months using roof ring components.

Jacobs et al.⁸ observed a 44% loosening rate in 9 uncemented acetabular Harris-Galante cups at a mean of a 25 month follow-up.

Cho et al.⁹ reported 7 failures out of 14 hips with cementless titanium fiber-metal cups, and 2 failures out of 4 cups with roof ring components.

This data shows the need of a better performing device in patients who underwent pelvis radiotherapy.

Recently, the use of tantalum implants on bone that was included in the irradiation field, has been reported with good results,^{13,14} thus we sought to determine its successful rate on patients with history of musculoskeletal tumor and radiotherapy.

Our study aimed to determine the survivalship of tantalum cup at medium term on patients with bone or soft tissue tumors history.

To this day only two other studies, both from Mayo Clinic, are promoting the use of more tantalum cup in radiotherapy treated acetabular bone.

Rose et al.¹³ report results with a mean follow-up of 31 months, while Joglekar et al.¹⁴ after a 78 month average. Both reported no cup loosening.

Rose included in the series 12 THA with tantalum acetabular cups on 11 patients. Primary tumors were 5 prostatic cancer, 4 gynecologic cancer, 2 colon rectal cancer, all treated with radiotherapy in a range dose between 4500 and 7500 cGy. They report 5 hips with postoperative unprogressive radiolucencies. No patient needed revision surgery; the mean Harris hip score improved from 46 points preoperatively to 88 points postoperatively.

Joglekar et al retrospectively reviewed 22 tantalum cups (Revision Shell) in 17 patients with a minimum of a 5 year follow-up, affected by gynecologic, prostatic, anal, colon-rectal and lymphoproliferative cancer. The mean radiation dose was 6300 cGy. They observed no implant migration or progressive radiolucencies, and

the Harris hip score increased from 36 points preoperatively to 80 points postoperatively.

The present series reports similar results compared to the two previous papers, and similar limitation: mainly the relatively short follow up (range from 38 to 136 months, mean 68) and the small sample size.

In contrast, our patients have been all affected by primary or secondary musculoskeletal tumors. Thus, they have been treated with radiotherapy and invasive surgery involving primarily the pelvic bone structures and the soft tissues around. We can reasonably assume a more consistent iatrogenic damage of the bone compared to the patients treated for genito-urinary tumors (Joglekar et al and Rose et al data). Unfortunately, this damage could not be objectively proved and quantified because of the heterogeneity of the group.

In fact, our data is poorly standardized: uncontrolled independent variables include patient age, pre-operative functional status, tumor type, grade and extension, chemotherapy and others. These variables have an inconstant and confounding effect limits the internal validity of this study, as it does in many studies of this type.

Compared to other prosthesis the successful result of tantalum cup in this series (implant survival rate 92%) can be considered remarkable. Until now primary acetabular implants haven't had any complications, while in the revision group a higher incidence of complications (2 hip dislocations and 1 infection) was observed (p value = 0.018). Indeed, after revision of a failed prosthesis on irradiated bone local condition are remarkably poor as well the soft tissue around, and higher complications' rate should be expected.

Concerning the mean functional results, 85.3 Harris hip score at the last follow-up is considered a good result to be correlated to the good performance of the tantalum cup.

The observation of a case with radiolucent line, beside stable 7 years after the first implant, leads to the need of a longer follow-up to draw more sound conclusions.

In conclusion the present data are comparable to others reporting tantalum cup performance in irradiated bone. While, in comparison to other type of cups they resulted far superior in terms of failure.

In a clinical setting compared with cemented and non-cemented cups, tantalum seems to provide a better initial fixation followed by secondary stability due to the integration of the trabecular metal to the underline spongy bone. The good performance of the material can provide a better functional result during time.

The reported results in agreement with literature data confirm the use of tantalum cups in irradiated bone.

References

- Deleeuw HW, Pottenger LA. Osteonecrosis of the acetabulum following radiation therapy. A report of two cases. *J Bone Joint Surg Am.* 1988;70(2):293–299.
- Phillips TW, Rao DR. Destructive arthropathy of the hip following pelvic irradiation: report of four cases. *Can J Surg.* 1989;32(5):353–357.
- Howland WJ, Loeffler RK, Starchman DE, Johnson RG. Postirradiation atrophic changes of bone and related complications. *Radiology.* 1975 Dec;117(3):677–685.
- Anna L, Fu MD, Kathryn M, Greven MD, Maruyama Y. Radiation osteitis and insufficiency fractures after pelvic irradiation for gynecologic malignancies. *Am J Clin Oncol (CCT).* 1994;17(3):248–254.
- Finston RA, Woodard HQ, Laughlin JS. Effects of external irradiation on mineral metabolism in the bones of adult dogs. *Clin Orthop Relat Res.* 1966;46:183–202.
- Woodard HQ, Coley BL. The correlation of tissue dose and clinical response in irradiation of bone tumors and of normal bone. *Am J Roentgenol Radium Ther.* 1947 Apr;57(4):464–471.
- Massin P, Duparc J. Total hip replacement in irradiated hips. A retrospective study of 71 cases. *J Bone Joint Surg Br.* 1995 Nov;77(6):847–852.
- Jacobs JJ, Kull LR, Frey GA, et al. Early failure of acetabular components inserted without cement after previous pelvic irradiation. *J Bone Joint Surg Am.* 1995 Dec;77(12):1829–1835.

9. Cho MR, Kwun KW, Lee DH, Kim SY, Kim JD. Latent period best predicts acetabular cup failure after total hip arthroplasties in radiated hips. *Clin Orthop Relat Res*. September 2005;438:165–170.
10. Levine BR, Sporer S, Poggie RA, Della Valle CJ, Jacobs JJ. Experimental and clinical performance of porous tantalum in orthopedic surgery. *Biomaterials*. 2006 Sep;27(27):4671–4681 [Epub 2006 Jun 5].
11. Zardiackas LD, Parsell DE, Dillon LD, Mitchell DW, Nunnery LA, Poggie R. Structure, metallurgy, and mechanical properties of a porous tantalum foam. *J Biomed Mater Res*. 2001;58(2):180–187.
12. Zhang Y, Ahn PB, Fitzpatrick DC, Heiner AD, Poggie RA, Brown TD. Interfacial frictional behavior: cancellous bone, cortical bone, and a novel porous tantalum biomaterial. *J Musculoskelet Res*. 1999;3(4):245–251.
13. Rose PS, Halasy M, Trousdale RT, et al. Preliminary results of tantalum acetabular components for THA after pelvic radiation. *Clin Orthop Relat Res*. 2006 Dec;453:195–198.
14. Joglekar SB, Rose PS, Lewallen DG, Sim FH. Tantalum acetabular cups provide secure fixation in THA after pelvic irradiation at minimum 5-year followup. *Clin Orthop Relat Res*. 2012 Nov;470(11):3041–3047.
15. DeLee JG, Charnley J. Radiological demarcation of cemented sockets in total hip replacement. *Clin Orthop Relat Res*. 1976 Nov-Dec;(121):20–32.
16. Ewing J. Radiation osteitis. *Acta Radiol*. 1927;6(1-6):399–412.
17. Ergün H, Howland WJ. Postradiation atrophy of mature bone. *CRC Crit Rev Diagn Imaging*. 1980 Jan;12(3):225–243.
18. Warren S. Histopathology of radiation lesions. *Physiol Rev*. 1944;24(225):399–412.
19. Sengupta S, Prathap K. Radiation Necrosis of the humerus. A report of three cases. *Acta Radiol*. Aug 1973;12:313–320.