

# Dysphagia as a Postoperative Complication of Anterior Cervical Discectomy and Fusion

Georgios Tsalimas<sup>1</sup>, Dimitrios Stergios Evangelopoulos<sup>2</sup>, Ioannis S. Benetos<sup>3</sup>, Spiros Pneumaticos<sup>4</sup>

Review began 06/24/2022

Review ended 07/12/2022

Published 07/15/2022

© Copyright 2022

Tsalimas et al. This is an open access article distributed under the terms of the Creative Commons Attribution License CC-BY 4.0., which permits unrestricted use, distribution, and reproduction in any medium, provided the original author and source are credited.

1. 5th Orthopaedic Department, KAT General Hospital of Athens, National and Kapodistrian University of Athens School of Medicine, Athens, GRC 2. 3rd Orthopaedic Department, KAT General Hospital of Athens, National and Kapodistrian University of Athens School of Medicine, Athens, GRC 3. Orthopaedics, KAT Trauma Hospital, University of Athens, Athens, GRC 4. Orthopaedics, KAT General Hospital Of Athens, National and Kapodistrian University of Athens School of Medicine, Athens, GRC

Corresponding author: Georgios Tsalimas, georgetsalimas@yahoo.com

---

## Abstract

Anterior cervical discectomy and fusion (ACDF), despite its possible complications, remains the gold standard for the surgical treatment of patients with radiculopathy and/or myelopathy caused by cervical intervertebral disc herniation or spondylosis. Despite its high rate of incidence, postoperative dysphagia following ACDF is still poorly understood; its pathogenesis remains relatively unknown, and its risk factors are still a subject of debate.

The aim of this study is to review the incidence, pathogenesis, diagnosis, and methods of prevention of dysphagia in ACDF patients. To this end, a literature review was conducted based on the PubMed internet database. Article titles were searched by using the following keywords: “dysphagia” and “anterior cervical discectomy and fusion” or “ACDF”. The search was limited to prospective clinical studies evaluating dysphagia after ACDF surgery. Studies published in non-English languages, retrospective studies, cadaveric studies, reviews, case reports, study protocols, and commentary studies were excluded.

Initially, 335 studies were identified after a primary search. After the application of the exclusion criteria, 73 studies remained for the final analysis. This literature review focused on identifying the rate of dysphagia and the various risk factors leading to this complication by comparing and evaluating the current literature with a wide spectrum of heterogeneity concerning patients, surgeons, and surgical techniques. A mean dysphagia rate of 19.4% (95% CI: 9.6%-29.1%) based on the findings of the included studies correlating dysphagia directly with ACDF procedures was calculated. Various established risk factors leading to dysphagia include the female sex, smoking, the surgical approach, rhBMP-2 use, and multilevel surgery, while zero-profile devices seem to reduce dysphagia risk. The diagnosis is based on clinical and radiological findings, especially prevertebral soft-tissue swelling. However, videofluoroscopic and endoscopic studies have been recently used for the evaluation of dysphagia. The role of local administration of steroids in the prevention of dysphagia has not yet been clarified. This review underscores the prevailing rudimentary understanding of the problem of dysphagia after ACDF procedures and highlights the need for more sensitive, factor-specific studies for understanding the impact of various risk factors on the incidence rate of dysphagia.

---

**Categories:** Neurosurgery, Orthopedics

**Keywords:** acdf complications, postoperative dysphagia, acdf, anterior cervical discectomy and fusion, dysphagia

## Introduction And Background

In spite of the potential complications associated with it, anterior cervical discectomy and fusion (ACDF) currently remains the gold standard in the surgical treatment of patients with radiculopathy and/or myelopathy caused by cervical intervertebral disc herniation or cervical spondylosis. ACDF maintains the disc height and the cervical alignment and the biomechanics of the cervical spine, besides promoting vertebral ossification and the faster return of the patients to daily activities. It is highly indicative when fixed cervical kyphosis >10 degrees is present, the compression arises from two or fewer disc segments, and anterior compression pathology is established and evident [ossification of posterior longitudinal ligament (OPLL), soft discs, disc osteophyte complexes]. Despite the fact that a large number of ACDFs are performed annually worldwide, various issues regarding the most appropriate intraoperative and postoperative management of these patients remain controversial and insufficiently defined. These include the method of fusion, the type of implants, the placement of plates and screws, the use of external vertebral orthotics, the application of postoperative physiotherapy, as well as the most appropriate duration of patients' absence from work. Since there are no official, evidence-based guidelines, spine surgeons are often forced to follow their own tactics, based on their training, specialization, and clinical experience [1-3].

The anterior cervical approach is a technically safe method, in which the structures in the anterior and anterolateral cervical spine are dissected effectively and usually without difficulty. With the patient in a

### How to cite this article

Tsalimas G, Evangelopoulos D, Benetos I S, et al. (July 15, 2022) Dysphagia as a Postoperative Complication of Anterior Cervical Discectomy and Fusion. Cureus 14(7): e26888. DOI 10.7759/cureus.26888

supine position, the skin incision can be horizontal or longitudinal, parallel to the course of the sternocleidomastoid muscle. With this approach, the surgeon has direct access to the vertebral bodies and the intervertebral discs, so that discectomy, removal of osteophytes, and, where required, corpectomy of the vertebrae are easy and feasible [1-3].

However, anterior spinal surgery carries a number of risks and potential complications. Implant failure and graft migration, which usually occur anteriorly, may result in partial kyphosis, dysphagia, airway obstruction, esophagus perforation, or pressure on the carotid artery leading to neurological symptoms. Also, in cases where an autologous bone graft is used, increased donor-site morbidity and the development of nonunion have been recorded [4-5]. Employing a poor surgical technique during the removal of osteophytes may lead to the injury of dura matter and cerebrospinal fluid leakage [6].

The process of swallowing is a vital but possibly underestimated function that involves emptying the nasopharynx and oropharynx and subsequently coordinating to close the nasopharynx and larynx to prevent aspiration [7]. The process of normal swallowing involves the fine collaboration of more than 25 pairs of muscles in the oral cavity, pharynx, larynx, and esophagus. There are three phases in the swallowing process: oral, pharyngeal, and esophageal. Dysphagia, which is defined as a dysfunction of normal swallowing, can occur during any or all of the three phases of swallowing [8-9].

There are three main types of dysphagia: acute, chronic, and progressive. Acute dysphagia mainly occurs after cervical head surgeries, neurosurgery, injuries, craniocerebral injuries, and vascular strokes. However, in genetic syndromes, such as cerebral palsy and developmental disorders, dysphagia is usually chronic. Progressive dysphagia is commonly found in neurological degenerative diseases. Symptoms of dysphagia include coughing or choking, foreign body sensation in the throat, food remainings in the mouth after swallowing, uncoordinated laryngeal movement, weight loss, and unexplained, recurrent nausea and/or vomiting. Dysphagia can increase the duration of hospitalization, affect recovery, and also endanger the quality of life of patients with spinal cord injury (SCI) in terms of oral nutrition and the ability to communicate. Hence, any difficulty in receiving, managing, promoting, and swallowing saliva, food, fluids, and substances of any composition, even medicines in general, entails a number of complex problems that characterize people with dysphagia [10-12].

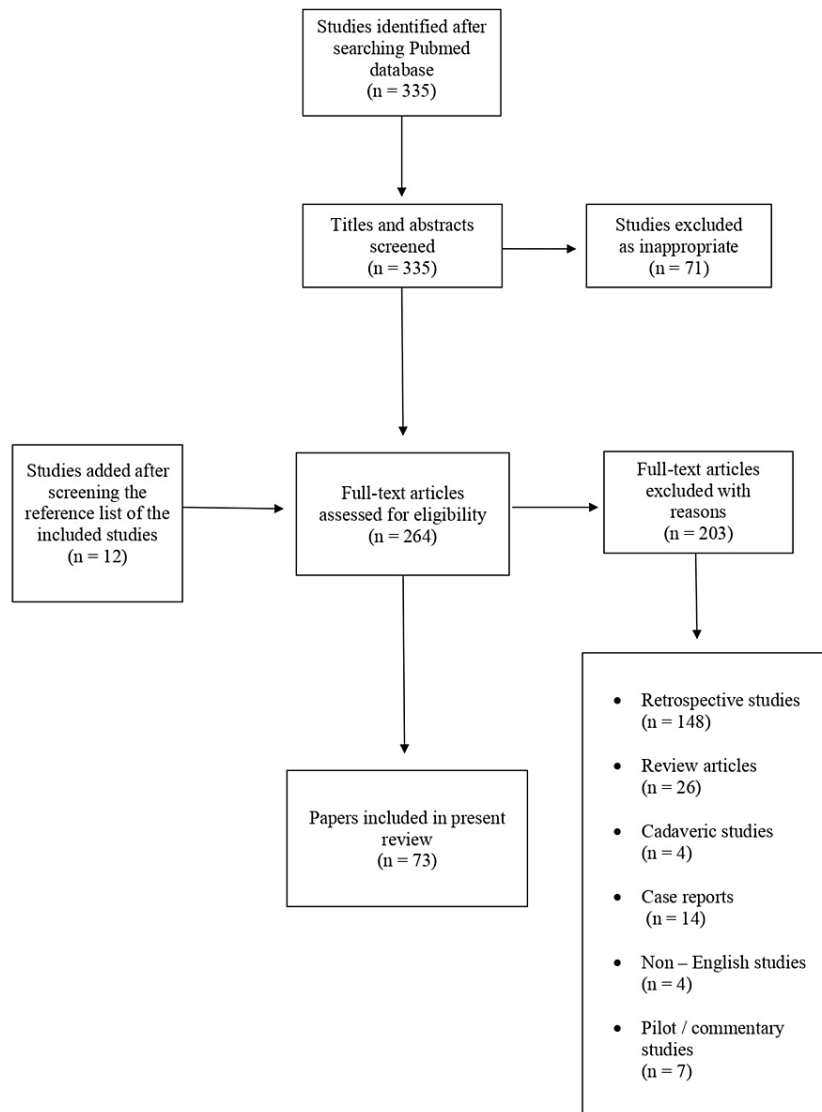
While dysphagia after the anterior spinal cervical approach is common, it is fortunately transient in most cases [13-14]. It may be caused by prevertebral soft tissue swelling, hematoma, bleeding, nerve injury, or inflammation associated with anterior cervical hardware irritation or esophageal retraction [14]. It occurs more frequently in patients who have undergone spinal fusion of more than one level and does not depend on anterior plate placement [6]. Older patients (aged >60 years) and those with pre-existing dysphagia (on the grounds of myelopathy) are at high risk for postoperative dysphagia [15]. Despite its high incidence, prolonged postoperative dysphagia is poorly understood; its pathogenesis remains relatively unknown, and its risk factors are still widely debated. The aim of this study is to review the incidence, pathogenesis, diagnosis, and modes of prevention of dysphagia in ACDF patients.

A literature review was conducted based on the PubMed internet database, following the PRISMA guidelines, with the use of the EndNote X3 software (Thompson Reuters) [16]. Article titles were searched with the use of the following keywords: “dysphagia” and “anterior cervical discectomy and fusion” or “ACDF”. The search was limited to prospective clinical studies evaluating dysphagia after ACDF surgery. Studies published in non-English languages, retrospective studies, cadaveric studies, reviews, case reports, study protocols, and commentary studies were excluded.

## Review

### Results

Initially, 335 studies were identified after a primary search on the PubMed electronic database. After the screening of titles and abstracts, 71 articles were excluded. Among the remaining 264 studies, 203 were rejected for creating a more homogenous patient cohort sample, as 148 were identified as retrospective studies, 26 were review articles, 14 were case report presentations, seven were pilot/commentary studies, four were cadaveric studies, and four papers were not in English. After a full-text analysis of the remaining studies, 12 additional studies that were found in the reference list of the already included studies were added, leaving 73 studies for the final analysis (Figure 1).



**FIGURE 1: Study selection flowchart**

*Incidence of Dysphagia and ACDF*

The incidence of postoperative dysphagia after ACDF has been reported in a plethora of studies, with varying results (Table 1) [1-95]. Dysphagia is considered to be a common complication in patients after ACDF, as in 50% of cases it was found video-radiographically after surgery. Although dysphagia may persist for months or years, the symptoms are typically transient. Thus, the timing of evaluation and follow-up influences the rate of diagnosis. Various studies have estimated the rate of dysphagia to range from 1 to 79% [17-21].

Authors, year	Study design	Patient details	Interventions (operated levels)	Follow-up time intervals	Graft type
Riley et al., 2005 [43]	Registry cohort study	N=454, mean age: 48.2 years, % male: 52.2	ACDF	3, 6, and 24 months	N/A
Bazaz et al., 2002 [19]	Prospective cohort	N=249, mean age: 52 years, no. of males: 52	ACDF or ACCF with or without plate or graft revision	6 months	Autograft
Haller et al., 2022 [21]	Prospective study	N=56, mean age: 60 years, no. of females: 33	ACDF	2, 12, and 24 months	N/A
Kepler et al.,	Prospective		ACDF one level: n=15, two levels:		Autograft or

2012 [79]	cohort	N=43	n=28	1.5 months	allograft
Bruneau et al., 2001 [22]	Prospective cohort	N=54	ACDF one level: n=40, two levels: n=14	24.6 months	Hydroxyapatite
Lied et al., 2013 [23]	Prospective single-center	N=96, mean age: 49 years, no. of females: 33	ACDF one level: n=60, two levels: n=36	6 months	N/A
Opsenak et al., 2019 [31]	Prospective single-center study	N=73	ACDF (zero-profile)	6 weeks; 3, 6, and 12 months	Allograft
Srikhande et al., 2019 [24]	Prospective study	N=100, mean age: 47.2 years, no. of females: 14	ACDF one level: n=95, two levels: n=5	24 months	Autograft
Frempong-Boadu et al., 2002 [20]	Prospective cohort	N=23, mean age: 59 years, % male: 95.6	ACDF (up to three levels)	1 week post-op, 12 months	Allograft
Mendoza-Lattes et al., 2008 [36]	Prospective cohort	N=17, mean age: 47.8 years, % male: 35.3	ACDF with either dynamic retraction or static retraction one level: n=7, two levels: n=10	1st day post-op, 6 weeks, 3 and 6 months	Allograft
Papavero et al., 2007 [35]	Prospective cohort	N=92, mean age: NR, % male: 57.6	ACDF using predominantly a left-sided Smith-Robinson approach	1st, 3rd, and 5th post-op day	N/A
Hou et al., 2014 [93]	Prospective cohort	N=196	ACDF one level: n=108, two levels: n=88	22.5 months	Autograft
Song and Lee, 2006 [94]	Prospective cohort	N=39, mean age: 46.3 years	ACDF one level	24 months	Autograft
Bolesta et al., 2000 [95]	Prospective cohort	N=15, mean age: 51 years, no. of males: 5, no. of females: 10	ACDF three levels: n=12, four levels: n=3	42 months	Autograft
O'Donohoe et al., 2020 [51]	Prospective cohort	N=25, mean age: 55.79 years, no. of females: 17	ACDF one level	2 years	Allograft
Lee et al., 2005 [52]	Prospective cohort	N=156	ACDF with 2 different plates: Atlantis and Zephir	1, 2, 6, 12, and 24 months	Allograft
Grasso et al., 2018 [58]	Prospective study	N=100	ACDF (zero-profile implants)	4 years	N/A
Zhang et al., 2016 [56]	Prospective cohort	N=50, mean age: 50.65 years, no. of males: 24, no. of females: 26	ACDF (zero-profile implants and anterior plate and cage)	2 years	N/A
De Leo-Vargas et al., 2019 [57]	Prospective study	N=53, mean age: 58.8 years	ACDF	6.7 months	N/A
Scholz et al., 2011 [62]	Prospective study	N=38, mean age: 53.7 years, no. of males: 24, no. of females: 14	ACDF (zero-profile implants)	6 months	N/A
El Baz et al., 2019 [63]	Prospective study	N=25, no. of males: 21, no. of females: 4	ACDF (zero-profile cage)	6 months (average follow-up time)	N/A
Gerszten et al., 2016 [64]	Prospective study	N=68, mean age: 56 years, no. of males: 51, no. of females: 17	ACDF (zero-profile fixation and stand-alone PEEK cages)	6 months	Allograft
Grasso et al., 2014 [65]	Prospective study	N=32, mean age: 59.8 years, no. of males: 18, no. of females: 14	ACDF (ROI-C cages)	6 weeks; 3, 6, 12, and 24 months	Allograft (cadaveric bony tissue)
Chen et al., 2015 [66]	Prospective study	N=69, mean age: 49.2 years, no. of males: 41, no. of females: 28	ACDF (Zero-P spacer, two-level fusion)	2-6 months	N/A

He et al., 2018 [67]	Prospective randomized trial	N=104, mean age: 57.4 years, no. of males: 55, no of females: 49	ACDF (zero-profile implants and traditional anterior cervical plate)	24 months	Autograft and allograft
Qizhi et al., 2016 [68]	Prospective cohort	N=17, mean age: 60.7 years, no. of males: 12, no. of females: 5	ACDF (zero-profile implants)	48, 59 months	N/A

**TABLE 1: Dysphagia incidence and ACDF: study characteristics**

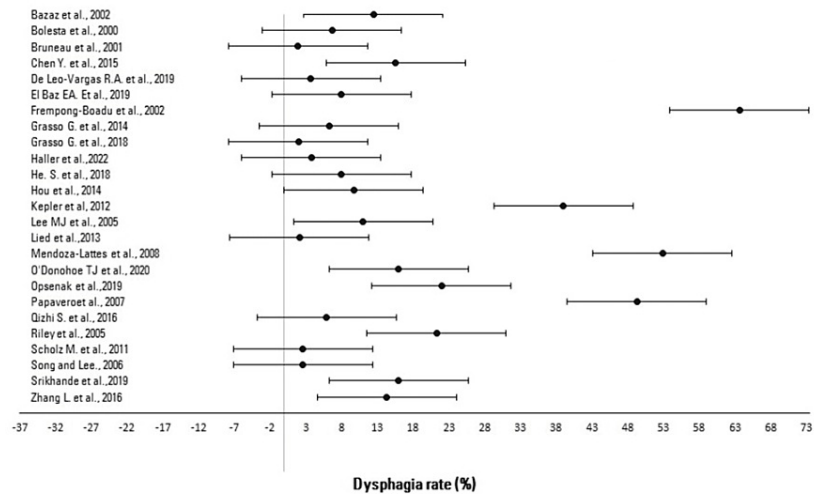
ACDF: anterior cervical discectomy and fusion; ACCF: anterior cervical corpectomy and fusion

#### *Dysphagia Rate and Evaluation*

A mean dysphagia rate of 19.4% (95% CI: 9.6%-29.1%) based on the included studies correlating dysphagia directly with ACDF procedures was calculated (Table 2). The upper and lower value intervals expressed as a percentage of each reported dysphagia rate of the included studies were calculated based on the 95% confidence interval, as presented in Table 2 and Figure 2. A crucial evaluation point is that across the combined interstudy population, studies reported dysphagia at different time intervals during the follow-up period, and hence the follow-up time holds no homogeneity, being a variable factor impacting the data analysis. Therefore, the dysphagia rates reported at the latest follow-up time in the studies included were chosen to be evaluated. Because of this limitation and the concomitant lack of studies with a consistent control follow-up interval time, further research is recommended to be performed on this topic. Moreover, the variation of the reported incidence may be attributed to the lack of standard criteria for its diagnosis, measurement, and the retrospective nature of many published studies. Retrospective studies would more often underreport postoperative complications [25]; moreover, the included studies used different dysphagia classification schemes, defining dysphagia differently or not at all, as discussed later.

Study	Dysphagia rate (95% CI)
Bazaz et al., 2002 [19]	12.5% (2.8%-22.2%)
Bolesta et al., 2000 [95]	6.7% (-3.0%-16.4%)
Bruneau et al., 2001 [22]	1.9% (-7.8%-11.6%)
Chen et al., 2015 [66]	15.6% (5.9%-25.3%)
De Leo-Vargas et al., 2019 [57]	3.7% (-6.0%-13.4%)
El Baz et al., 2019 [63]	8.0% (-1.7%-17.7%)
Frempong-Boadu et al., 2002 [20]	63.6% (53.9%-73.3%)
Grasso et al., 2014 [65]	6.25% (-3.5%-15.9%)
Grasso et al., 2018 [58]	2.0% (-7.7%-11.7%)
Haller et al., 2022 [21]	3.8% (-5.9%-13.5%)
He et al., 2018 [67]	8.0% (-1.7%-17.7%)
Hou et al., 2014 [93]	9.7% (-0.02%-19.4%)
Kepler et al., 2012 [79]	39.0% (29.3%-48.7%)
Lee et al., 2005 [52]	11.0% (1.3%-20.7%)
Lied et al., 2013 [23]	2.1% (-7.6%-11.8%)
Mendoza-Lattes et al., 2008 [36]	52.9% (43.2%-62.6%)
O'Donohoe et al., 2020 [51]	16.0% (6.3%-25.7%)
Opsenak et al., 2019 [31]	22.0% (12.3%-31.7%)
Papavero et al., 2007 [35]	49.3% (39.6%-59.0%)
Qizhi et al., 2016 [68]	5.9% (-3.8%-15.6%)
Riley et al., 2005 [43]	21.3% (11.6%-31.0%)
Scholz et al., 2011 [62]	2.6% (-7.1%-12.3%)
Song and Lee, 2006 [94]	2.6% (-7.1%-12.3%)
Srikhande et al., 2019 [24]	16.0% (6.3%-25.7%)
Zhang et al., 2016 [56]	14.3% (4.6%-24.0%)
Mean dysphagia rate	19.4% (9.6%-29.1%)

**TABLE 2: Dysphagia rates and 95% confidence intervals (CIs) as per the studies**



**FIGURE 2: Dysphagia rates and 95% confidence intervals (CIs) as per studies correlating dysphagia with ACDF, expressed in a forest plot for meta-analysis**

ACDF: anterior cervical discectomy and fusion

#### Risk Factors

Dysphagia as a complication after ACDF procedures has a multivariable characteristic. Many factors play a crucial role in leading to dysphagia and thereby affecting the dysphagia rates reported in the studies, some of which are patient sex, the surgical approach, the different ACDF devices utilized, the graft type, rhBMP-2 use, and the administration of steroids. By reviewing the current literature on the topic, an attempt was made to identify, compare, and evaluate those factors individually and the effect they might have in terms of leading to dysphagia.

Other causes, such as movement of structures, pharyngeal edema, or paralysis of the vocal cords, are also known to have an effect on postoperative dysphagia. Individuals who undergo surgery for cervical spine disease with anterior or posterior access tend to develop oropharyngeal dysphagia, which is often severe during the first month and progressively diminishes in intensity over time [26]. Multivariable analyses have identified smoking status, prior cervical surgery, preoperative C2-C7 angle, preoperative dysphagia, preoperative chronic obstructive pulmonary disease, multilevel surgery, and intraoperative steroid use as significant risk factors for dysphagia after ACDF [26-30]. However, the prospective study by Opsenak et al. failed to confirm these findings [31]. Prevertebral soft-tissue swelling of more than 5 mm and change of cervical alignment of more than 5 degrees are known predictors of postoperative dysphagia after ACDF [20,30,32]. Prevertebral soft-tissue swelling after ACDF resolves and returns to presurgery status within one to three months in the pharyngeal airway (C3) and within three to six months in the laryngeal airway (C6).

Female gender and obesity have been determined to have an influence on prevertebral soft tissue swelling after ACDF [26,33]. Operation time has been correlated with the severity of postoperative dysphagia [17]. Psychiatric disorders and preoperative opioid use are known predisposing factors of postoperative chronic dysphagia following ACDF [34]. No correlation between intraoperative esophagus retraction and postoperative dysphagia has been documented [36]. On the contrary, Mendoza-Lattes et al. have observed that during ACDF, patients were exposed to higher intraoperative esophageal pressure and decreased esophageal mucosal blood flow during surgical retraction. Dynamic retraction seemed to be associated with a lower prevalence of postoperative dysphagia [36].

#### Surgical Approach

The anterior approach of ACDF is highly associated with the development of dysphagia. Patients who underwent anterior or combined approach had a disproportionately high incidence of swallowing disorders. A randomized controlled trial compared the rate of postoperative dysphagia among patients who underwent two different approaches for ACDF. The authors concluded that, for the better prevention of dysphagia, an anterior approach lateral to the omohyoid muscle should be selected if the level of surgery involves C3-C4. For C6-C7 surgery, however, a left-sided anterior approach medial to the omohyoid muscle should be used [37]. Of note, 85% of patients with dysphagia after cervical spine surgery have been subjected to ACDF [38].

The placement of anterior cervical plates results in increased intraesophageal pressure when it is done in the vertebra C5-C6. This is true regardless of whether the placement of the plates occurs from the C3 to the C6 vertebra or individually to the C5-C6. In addition, cervical disc placement appears to require less esophageal friction and reduces esophageal pressure when compared to anterior plaque placement [59]. The reported rates of postoperative dysphagia are significantly higher in ACDF in comparison with posterior decompression and fusion [40-42]. Multiple cervical levels of ACDF represent a significantly higher postoperative risk for swallowing dysfunction, as compared with one-level ACDF [18,20,43]. Four-level ACDF has been associated with a 52% rate of transient dysphagia [43].

#### *ACDF Devices and Disc Replacement*

The comparison between ACDF and anterior disk replacement in terms of postoperative dysphagia has shown conflicting results. Anderson et al. reported that the incidence of postoperative dysphagia is higher in anterior disk replacement surgery in comparison to ACDF [44]. Other studies have found no significant difference in rates of postoperative dysphagia between ACDF and cervical disk arthroplasty [45]. Philips et al. found a statistically lower rate of prolonged dysphagia in patients subjected to cervical disk replacement [46]. Shi et al. found no significant difference in postoperative swallowing dysfunction when ACDF with zero-profile cages was compared to cervical disk arthroplasty (CDA) with Discover prosthesis [47]. Bryan(®) CDA has been found to have a significantly reduced rate of dysphagia compared to ACDF [48]. In a prospective randomized clinical study by McAfee et al., the incidence of postoperative dysphagia and the long-term resolution of the dysphagia were found to be greatly improved in the disk arthroplasty group in comparison to the instrumented ACDF control group [49].

The impact of implants used for ACDF has been extensively studied. Modular plates have been associated with a trend toward lower dysphagia in comparison to traditional plates [50]. The placement of larger plates may prolong retraction time but is not associated with higher rates of dysphagia, according to a prospective study by O' Donohoe et al. [51]. Smaller and smoother plates may reduce the incidence of postoperative dysphagia [52]. Plate thickness or preoperative osteophyte height does not seem to affect the risk of postoperative dysphagia after ACDF. Plates at C3 have a trend for an increased risk for postoperative dysphagia [53].

Zero-profile devices for ACDF have been widely associated with lower rates of postoperative dysphagia, compared to conventional implants [54-56]. The incidence of postoperative dysphagia in patients undergoing ACDF with zero-profile stand-alone cervical cages has been reported as 3.7% [57]. ACDF with the use of zero-profile intervertebral cages has shown a rate of transient postoperative dysphagia at 1.1%-7.9% [58-62]. Among 25 patients treated with ACDF with a zero-profile cage, three patients presented with mild transient dysphagia that resolved at two weeks and two patients had moderate dysphagia that resolved at five weeks [63]. In a prospective cohort study, the rate of dysphagia after ACDF with zero-profile devices that included titanium screw fixation was 12%, while the corresponding rate was 9% when PEEK cages were used [64]. When ROI-C cages were used for ACDF, the reported rate of transient postoperative dysphagia was 3.1% [65]. Two-level ACDF with the zero-profile spacer has a higher incidence of postoperative dysphagia compared with ACDF with plates and screws [66]. In multilevel ACDF, He et al. found a 0% rate of dysphagia when zero-profile constructs were used, in comparison to an 8% rate when traditional plate and screws were used [67]. Qizhi et al. reported a 5.9% rate of dysphagia after ACDF with zero-profile devices [68]. ACDF with intervertebral cages may have a higher rate of postoperative dysphagia in comparison to anterior instrumentation with plates and screws, according to Zavras et al. [69].

#### *Graft Type and rhBMP-2*

The use of grafts or growth factors may affect the development of dysphagia. Studies that performed ACDF with autograft fusion reported an overall dysphagia rate of 9.9%, whereas the use of allograft fusion resulted in a rate of 7.9%. The highest rate of dysphagia (20.2%) among studies using autograft fusion was reported by Bazaz et al. [19]. Among 72 ACDF patients with the use of bioabsorbable cervical spacer treated with low-dose rhBMP-2, only two patients suffered from excessive postoperative dysphagia [70]. The addition of rhBMP-2 to ACDF has been associated with increased postoperative dysphagia seven days after surgery [71-72]. Randomized controlled studies have shown that locally administered steroids on a collagen sponge significantly reduce the incidence and severity of postoperative dysphagia following ACDF using low-dose rhBMP-2 [73]. ACDF with intervertebral cages and the addition of BMP-7 has been reported to have a 1.6% rate of postoperative dysphagia [74]. ACDF with PEEK cages and the addition of rhBMP-2 placed on a type I collagen sponge and titanium plates was accompanied by up to 47% rate of swallowing problems two weeks after surgery. Swallowing scores dramatically improved six months after ACDF [75]. ACDF with titanium cages or anterior locking plating and tricortical iliac crest graft was associated with a 15% rate of dysphagia according to a prospective comparative study by Singh et al. [76].

#### *Diagnosing Dysphagia*

The Eating Assessment Tool (EAT-10) and the Bazaz Dysphagia score are two widely used clinical scoring systems for the measurement of dysphagia in clinical studies [77,78]. The Bazaz score classifies dysphagia



into none, mild, moderate, or severe based on its frequency and the kinds of foods that precipitate dysphagia [19]. In lateral cervical X-rays, there is a significant increase in anterior cervical soft-tissue swelling after ACDF. However, the width of prevertebral soft tissue is not associated with postoperative dysphagia [79]. According to Song et al., the measurement of prevertebral soft-tissue swelling with the use of consecutive cervical lateral radiographs after ACDF may contribute to the diagnosis of postoperative dysphagia [34].

As swallowing is a dynamic process, the videofluoroscopic swallow study (VFSS) is probably the most appropriate method of evaluating this normal function. Its aim is to detect and evaluate the physiology of all stages of swallowing, the reason why the examinee has a problem, and also to guide the therapist in choosing appropriate strategies by which the patient's nutrition will be safe and adequate for survival. The patient is asked to manage foods of any composition impregnated with barium, while at the same time the whole procedure is videotaped. VFSS studies have shown that patients after ACDF with their highest surgery level at C3 and C4 had more severe swallowing dysfunction and significantly increased soft-tissue thickness [80]. For patients with persisting dysphagia, VFSS has shown significant impairments in pharyngeal constriction, hyoid displacement, and pharyngoesophageal segment opening [40]. VFSS studies have reported that the incidences of dysphagia measured by the Bazaz Dysphagia score were 83.0% at one week and 59.6% at one month after ACDF [81].

Fiberoptic endoscopic evaluation of swallowing (FEES) is an examination performed by a doctor by using a flexible endoscope and a screen that is available to monitor the examination. This examination allows the control of anatomical structures (nasopharynx and larynx) involved in swallowing and phonation, the delay or absence of the pharyngeal or laryngeal reflex, the correct direction and timing of the bolus, the control of its early escape into the pharynx, the reduced sensation, the presence of residues in the lingual epiglottis or in the opioid pits, and the aspiration or the penetration [31]. The rate of dysphagia after ACDF as assessed by FEES has been reported to be 37% [82].

#### *Prevention*

Steroids have been administered intraoperatively with the aim to reduce dysphagia risk during ACDF; however, the results have been contradictory. Prospective randomized trials have not demonstrated any benefit of local or intravenous intraoperative administration of steroids in terms of patient-reported swallowing function or prevertebral soft-tissue swelling following ACDF [83-84]. Intraoperative administration of local anesthetics to the retropharyngeal space did not reduce dysphagia symptoms after ACDF [85]. Other prospective studies have observed that the local administration of steroids after multilevel ACDF can decrease postoperative soft-tissue swelling and the rate of postoperative dysphagia [86-87]. Retropharyngeal administration of steroids for the prevention of postoperative dysphagia is associated with a decreased rate of radiographic fusion or delayed fusion in ACDF surgery [88-89]. Jenkins et al. have observed that both local and intravenous intraoperative administration of steroids is associated with decreased dysphagia rates, when compared to the control group, after ACDF ( $p=0.014$ ) [90]. Similarly, Jeyamohan et al. found that perioperative administration of dexamethasone significantly improved swallowing function and airway edema, but did not affect long-term swallowing status [89]. Intraoperative placement of an esophageal temperature probe significantly improved postoperative dysphagia scores in patients undergoing two-level ACDF at two weeks and six months postoperatively [91]. The adjustment of endotracheal tube-cuff pressure in ACDF does not have a significant impact on the incidence of postoperative dysphagia [92].

## Conclusions

Dysphagia is an established multifactorial complication of ACDF with varying incidence rates. This literature review focused on identifying the rate of dysphagia and the various risk factors leading to this complication by comparing and evaluating the current literature with a wide spectrum of heterogeneity concerning patients, surgeons, and surgical techniques. A mean dysphagia rate of 19.4% (95% CI: 9.6%-29.1%) based on the findings of included studies correlating dysphagia directly with ACDF procedures was calculated. Various established risk factors leading to dysphagia include the female sex, smoking, the surgical approach, rhBMP-2 use, and multilevel surgery, while zero-profile devices seem to reduce dysphagia risk. The diagnosis is based on clinical and radiological findings, especially prevertebral soft-tissue swelling. However, videofluoroscopic and endoscopic studies have been recently used for the evaluation of dysphagia. The role of the local administration of steroids in the prevention of dysphagia has not yet been clarified. This review underscores the existing rudimentary understanding of the problem of dysphagia after ACDF procedures and highlights the need for more sensitive, factor-specific studies for gaining deeper insights into the impact of various risk factors on the rate of dysphagia.

## Additional Information

### Disclosures

**Conflicts of interest:** In compliance with the ICMJE uniform disclosure form, all authors declare the following: **Payment/services info:** All authors have declared that no financial support was received from

any organization for the submitted work. **Financial relationships:** All authors have declared that they have no financial relationships at present or within the previous three years with any organizations that might have an interest in the submitted work. **Other relationships:** All authors have declared that there are no other relationships or activities that could appear to have influenced the submitted work.

## References

- Schroeder GD, Kurd MF, Millhouse PW, Vaccaro AR, Hilibrand AS: Performing an anterior cervical discectomy and fusion. *Clin Spine Surg.* 2016, 29:186-90. [10.1097/BSD.0000000000000383](https://doi.org/10.1097/BSD.0000000000000383)
- Hauk L: Anterior cervical discectomy and fusion. *AORN J.* 2018, 108:P11-3. [10.1002/aorn.12317](https://doi.org/10.1002/aorn.12317)
- Kani KK, Chew FS: Anterior cervical discectomy and fusion: review and update for radiologists. *Skeletal Radiol.* 2018, 47:7-17. [10.1007/s00256-017-2798-z](https://doi.org/10.1007/s00256-017-2798-z)
- Ahn JS, Lee JK, Kim JH: Comparative study of clinical outcomes of anterior cervical discectomy and fusion using autobody graft or cage with bone substitute. *Asian Spine J.* 2011, 5:169-75. [10.4184/asj.2011.5.3.169](https://doi.org/10.4184/asj.2011.5.3.169)
- Guvan M, Cosar M, Alkan B, et al.: Comparison of anterior cervical discectomy fusion techniques: bladed and non bladed PEEK cages. *Turk Neurosurg.* 2016, 26:404-10. [10.5137/1019-5149.JTN.12797-14.1](https://doi.org/10.5137/1019-5149.JTN.12797-14.1)
- Fountas KN, Kapsalaki EZ, Nikolakakos LG, et al.: Anterior cervical discectomy and fusion associated complications. *Spine (Phila Pa 1976).* 2007, 32:2310-7. [10.1097/BRS.0b013e318154c57e](https://doi.org/10.1097/BRS.0b013e318154c57e)
- Matsuo K, Palmer JB: Anatomy and physiology of feeding and swallowing: normal and abnormal. *Phys Med Rehabil Clin N Am.* 2008, 19:691-707. [10.1016/j.pmr.2008.06.001](https://doi.org/10.1016/j.pmr.2008.06.001)
- Lancaster J: Dysphagia: its nature, assessment and management. *Br J Community Nurs.* 2015, 5:S28-32. [10.12968/bjcn.2015.20.Sup6a.S28](https://doi.org/10.12968/bjcn.2015.20.Sup6a.S28)
- McCarty EB, Chao TN: Dysphagia and swallowing disorders. *Med Clin North Am.* 2021, 105:939-54. [10.1016/j.mcna.2021.05.013](https://doi.org/10.1016/j.mcna.2021.05.013)
- Khan A, Carmona R, Traube M: Dysphagia in the elderly. *Clin Geriatr Med.* 2014, 30:43-53. [10.1016/j.cger.2015.10.009](https://doi.org/10.1016/j.cger.2015.10.009)
- Rommel N, Hamdy S: Oropharyngeal dysphagia: manifestations and diagnosis. *Nat Rev Gastroenterol Hepatol.* 2016, 13:49-59. [10.1038/nrgastro.2015.199](https://doi.org/10.1038/nrgastro.2015.199)
- Wilkinson JM, Codipilly DC, Wilfahrt RP: Dysphagia: evaluation and collaborative management. *Am Fam Physician.* 2021, 103:97-106.
- Alimi M, Njoku I, Hofstetter CP, et al.: Anterior cervical discectomy and fusion (ACDF): comparison between zero profile implants and anterior cervical plate and spacer. *Cureus.* 2016, 8:e573. [10.7759/cureus.573](https://doi.org/10.7759/cureus.573)
- Zhang L, Wang J, Feng X, et al.: Outcome evaluation of zero-profile device used for single-level anterior cervical discectomy and fusion with osteoporosis compared without osteoporosis: a minimum three-year follow-up study (Epub ahead of print). *World Neurosurg.* 2018, [10.1016/j.wneu.2018.10.024](https://doi.org/10.1016/j.wneu.2018.10.024)
- Lee SK, Lee GY, Wong GT: Prolonged and severe dysphagia following anterior cervical surgery. *J Clin Neurosci.* 2004, 11:424-7. [10.1016/j.jocn.2003.05.007](https://doi.org/10.1016/j.jocn.2003.05.007)
- Barnett I, Malik N, Kuijjer ML, Mucha PJ, Onnela JP: EndNote: feature-based classification of networks. *Netw Sci (Camb Univ Press).* 2019, 7:438-44. [10.1017/nws.2019.21](https://doi.org/10.1017/nws.2019.21)
- Rihn JA, Kane J, Albert TJ, Vaccaro AR, Hilibrand AS: What is the incidence and severity of dysphagia after anterior cervical surgery? *Clin Orthop Relat Res.* 2011, 469:658-65. [10.1007/s11999-010-1731-8](https://doi.org/10.1007/s11999-010-1731-8)
- Danto J, DiCapua J, Nardi D, Pekmezaris R, Moise G, Lesser M, Dimarzio P: Multiple cervical levels: increased risk of dysphagia and dysphonia during anterior cervical discectomy. *J Neurosurg Anesthesiol.* 2012, 24:350-5. [10.1097/ANA.0b013e3182622843](https://doi.org/10.1097/ANA.0b013e3182622843)
- Bazaz R, Lee MJ, Yoo JU: Incidence of dysphagia after anterior cervical spine surgery: a prospective study. *Spine (Phila Pa 1976).* 2002, 27:2453-8. [10.1097/00007632-200211150-00007](https://doi.org/10.1097/00007632-200211150-00007)
- Frempong-Boadu A, Houten JK, Osborn B, Opulencia J, Kells L, Guida DD, Le Roux PD: Swallowing and speech dysfunction in patients undergoing anterior cervical discectomy and fusion: a prospective, objective preoperative and postoperative assessment. *J Spinal Disord Tech.* 2002, 15:362-8. [10.1097/00024720-200210000-00004](https://doi.org/10.1097/00024720-200210000-00004)
- Haller L, Mehul Kharidia K, Bertelsen C, Wang J, O'Dell K: Post-operative dysphagia in anterior cervical discectomy and fusion. *Ann Otol Rhinol Laryngol.* 2022, 131:289-94. [10.1177/00034894211015582](https://doi.org/10.1177/00034894211015582)
- Bruneau M, Nisolle JF, Gilliard C, Gustin T: Anterior cervical interbody fusion with hydroxyapatite graft and plate system. *Neurosurg Focus.* 2001, 10:E8. [10.3171/foc.2001.10.4.9](https://doi.org/10.3171/foc.2001.10.4.9)
- Lied B, Rønning PA, Halvorsen CM, Ekseth K, Helseth E: Outpatient anterior cervical discectomy and fusion for cervical disk disease: a prospective consecutive series of 96 patients. *Acta Neurol Scand.* 2013, 127:31-7. [10.1111/j.1600-0404.2012.01674.x](https://doi.org/10.1111/j.1600-0404.2012.01674.x)
- Srikhande NN, Kumar VA, Sai Kiran NA, et al.: Clinical presentation and outcome after anterior cervical discectomy and fusion for degenerative cervical disc disease. *J Craniovertebr Junction Spine.* 2019, 10:28-32. [10.4103/jcvjs.JCVJS\\_87\\_18](https://doi.org/10.4103/jcvjs.JCVJS_87_18)
- Edwards CC 2nd, Karpitskaya Y, Cha C, Heller JG, Laurusen C, Yoon ST, Riew KD: Accurate identification of adverse outcomes after cervical spine surgery. *J Bone Joint Surg Am.* 2004, 86:251-6. [10.2106/00004623-200402000-00006](https://doi.org/10.2106/00004623-200402000-00006)
- Siska PA, Ponnappan RK, Hohl JB, Lee JY, Kang JD, Donaldson WF 3rd: Dysphagia after anterior cervical spine surgery: a prospective study using the swallowing-quality of life questionnaire and analysis of patient comorbidities. *Spine (Phila Pa 1976).* 2011, 36:1387-91. [10.1097/BRS.0b013e31822340f2](https://doi.org/10.1097/BRS.0b013e31822340f2)
- Nguyen S, Sherrod BA, Paziuk TM, Rihn JA, Patel AA, Brodke DS, Bisson EF: Predictors of dysphagia after anterior cervical discectomy and fusion: a prospective multicenter study. *Spine (Phila Pa 1976).* 2022, 47:859-64. [10.1097/BRS.0000000000004279](https://doi.org/10.1097/BRS.0000000000004279)
- Ohba T, Akaike H, Fujita K, et al.: Risk factors and assessment using an endoscopic scoring system for postoperative respiratory complications after anterior cervical decompression and fusion surgery. *Spine Surg Relat Res.* 2020, 5:10-5. [10.22605/ssrr.2020-0104](https://doi.org/10.22605/ssrr.2020-0104)
- Okano I, Salzmann SN, Ortiz Miller C, et al.: Risk factors for postoperative dysphagia and dysphonia following anterior cervical spine surgery: a comprehensive study utilizing the hospital for special surgery

- dysphagia and dysphonia inventory (HSS-DDI). *Spine J.* 2021, 21:1080-8. [10.1016/j.spinee.2021.02.011](https://doi.org/10.1016/j.spinee.2021.02.011)
30. Shi S, Li XF, Zhao QT, Yang LL, Liu ZD, Yuan W: Risk factors for dysphagia after single-level anterior cervical decompression with arthroplasty or fusion: a prospective study comparing 2 zero-profile implants. *World Neurosurg.* 2016, 95:148-55. [10.1016/j.wneu.2016.07.100](https://doi.org/10.1016/j.wneu.2016.07.100)
  31. Opsenak R, Kolarovszki B, Benco M, Richterová R, Snopko P, Varga K, Hanko M: Dysphagia after anterior cervical discectomy and interbody fusion - prospective study with 1-year follow-up. *Rozhl Chir.* 2019, 98:115-20.
  32. Song KJ, Choi BW, Kim HY, Jeon TS, Chang H: Efficacy of postoperative radiograph for evaluating the prevertebral soft tissue swelling after anterior cervical discectomy and fusion. *Clin Orthop Surg.* 2012, 4:77-82. [10.4055/cios.2012.4.1.77](https://doi.org/10.4055/cios.2012.4.1.77)
  33. Kim SW, Jang C, Yang MH, Lee S, Yoo JH, Kwak YH, Hwang JH: The natural course of prevertebral soft tissue swelling after anterior cervical spine surgery: how long will it last?. *Spine J.* 2017, 17:1297-309. [10.1016/j.spinee.2017.05.003](https://doi.org/10.1016/j.spinee.2017.05.003)
  34. Kang SS, Lee JS, Shin JK, Lee JM, Youn BH: The association between psychiatric factors and the development of chronic dysphagia after anterior cervical spine surgery. *Eur Spine J.* 2014, 23:1694-8. [10.1007/s00586-014-3281-3](https://doi.org/10.1007/s00586-014-3281-3)
  35. Papavero L, Heese O, Klotz-Regener V, Buchalla R, Schröder F, Westphal M: The impact of esophagus retraction on early dysphagia after anterior cervical surgery: does a correlation exist?. *Spine (Phila Pa 1976).* 2007, 32:1089-93. [10.1097/01.brs.0000261627.04944.cf](https://doi.org/10.1097/01.brs.0000261627.04944.cf)
  36. Mendoza-Lattes S, Clifford K, Bartelt R, Stewart J, Clark CR, Boezaart AP: Dysphagia following anterior cervical arthrodesis is associated with continuous, strong retraction of the esophagus. *J Bone Joint Surg Am.* 2008, 90:256-63. [10.2106/JBJS.G.00258](https://doi.org/10.2106/JBJS.G.00258)
  37. Fengbin Y, Xinwei W, Haisong Y, Yu C, Xiaowei L, Deyu C: Dysphagia after anterior cervical discectomy and fusion: a prospective study comparing two anterior surgical approaches. *Eur Spine J.* 2013, 22:1147-51. [10.1007/s00586-012-2620-5](https://doi.org/10.1007/s00586-012-2620-5)
  38. Miles A, Jamieson G, Shasha L, Davis K: Characterizing dysphagia after spinal surgery. *J Spinal Cord Med.* 2019, 44:735-41. [10.1080/10790268.2019.1665613](https://doi.org/10.1080/10790268.2019.1665613)
  39. Tortolani PJ, Cunningham BW, Vigna F, Hu N, Zorn CM, McAfee PC: A comparison of retraction pressure during anterior cervical plate surgery and cervical disc replacement: a cadaveric study. *J Spinal Disord Tech.* 2006, 19:312-7. [10.1097/01.bsd.0000210117.01897.ca](https://doi.org/10.1097/01.bsd.0000210117.01897.ca)
  40. El-Ghandour NM, Soliman MA, Ezzat AA, Mohsen A, Zein-Elabedin M: The safety and efficacy of anterior versus posterior decompression surgery in degenerative cervical myelopathy: a prospective randomized trial. *J Neurosurg Spine.* 2020, 1:1-9. [10.3171/2020.2.SPINE191272](https://doi.org/10.3171/2020.2.SPINE191272)
  41. Lee S, Cho DC, Chon H, Roh SW, Choi I, Park JH: Comparison between anterior cervical decompression with fusion and posterior cervical fusion with wide facetectomy for treatment of severe bony foraminal stenosis. *J Korean Neurosurg Soc.* 2021, 64:552-61. [10.3340/jkns.2020.0263](https://doi.org/10.3340/jkns.2020.0263)
  42. Charalampidis A, Hejrati N, Ramakonar H, Kalsi PS, Massicotte EM, Fehlings MG: Clinical outcomes and revision rates following four-level anterior cervical discectomy and fusion. *Sci Rep.* 2022, 12:5339. [10.1038/s41598-022-09389-1](https://doi.org/10.1038/s41598-022-09389-1)
  43. Riley LH 3rd, Skolasky RL, Albert TJ, Vaccaro AR, Heller JG: Dysphagia after anterior cervical decompression and fusion: prevalence and risk factors from a longitudinal cohort study. *Spine (Phila Pa 1976).* 2005, 30:2564-9. [10.1097/01.brs.0000186317.86379.02](https://doi.org/10.1097/01.brs.0000186317.86379.02)
  44. Anderson PA, Sasso RC, Riew KD: Comparison of adverse events between the Bryan artificial cervical disc and anterior cervical arthrodesis. *Spine (Phila Pa 1976).* 2008, 33:1305-12. [10.1097/BRS.0b013e31817329a1](https://doi.org/10.1097/BRS.0b013e31817329a1)
  45. Loidolt T, Kurra S, Riew KD, Levi AD, Florman J, Lavelle WF: Comparison of adverse events between cervical disc arthroplasty and anterior cervical discectomy and fusion: a 10-year follow-up. *Spine J.* 2021, 21:253-64. [10.1016/j.spinee.2020.10.013](https://doi.org/10.1016/j.spinee.2020.10.013)
  46. Phillips FM, Lee JY, Geisler FH, et al.: A prospective, randomized, controlled clinical investigation comparing PCM cervical disc arthroplasty with anterior cervical discectomy and fusion. 2-year results from the US FDA IDE clinical trial. *Spine (Phila Pa 1976).* 2013, 38:E907-18. [10.1097/BRS.0b013e318296232f](https://doi.org/10.1097/BRS.0b013e318296232f)
  47. Shi S, Zheng S, Li XF, Yang LL, Liu ZD, Yuan W: Comparison of 2 zero-profile implants in the treatment of single-level cervical spondylotic myelopathy: a preliminary clinical study of cervical disc arthroplasty versus fusion. *PLoS One.* 2016, 11:e0159761. [10.1371/journal.pone.0159761](https://doi.org/10.1371/journal.pone.0159761)
  48. Cheng L, Nie L, Li M, Huo Y, Pan X: Superiority of the Bryan® disc prosthesis for cervical myelopathy: a randomized study with 3-year followup. *Clin Orthop Relat Res.* 2011, 469:3408-14. [10.1007/s11999-011-2039-z](https://doi.org/10.1007/s11999-011-2039-z)
  49. McAfee PC, Cappuccino A, Cunningham BW, et al.: Lower incidence of dysphagia with cervical arthroplasty compared with ACDF in a prospective randomized clinical trial. *J Spinal Disord Tech.* 2010, 23:1-8. [10.1097/BSD.0b013e31819e2ab8](https://doi.org/10.1097/BSD.0b013e31819e2ab8)
  50. Hawasli AH, Cashin JL, Wright NM: Modular cervical plate system for adjacent segment disease. *J Neurosurg Sci.* 2020, 64:427-33. [10.23736/S0390-5616.18.04172-3](https://doi.org/10.23736/S0390-5616.18.04172-3)
  51. O'Donohoe TJ, Mililli L, Magee A, Thien C, Wang YY: Effect of the presence and type of plate augmentation on postoperative dysphagia among adult patients undergoing elective anterior cervical discectomy and fusion for spondylosis: a randomized trial. *Neurospine.* 2020, 17:174-83. [10.14245/ns.1938446.223](https://doi.org/10.14245/ns.1938446.223)
  52. Lee MJ, Bazaz R, Furey CG, Yoo J: Influence of anterior cervical plate design on dysphagia: a 2-year prospective longitudinal follow-up study. *J Spinal Disord Tech.* 2005, 18:406-9. [10.1097/01.bsd.0000177211.44960.71](https://doi.org/10.1097/01.bsd.0000177211.44960.71)
  53. Chin KR, Eiszner JR, Adams SB Jr: Role of plate thickness as a cause of dysphagia after anterior cervical fusion. *Spine (Phila Pa 1976).* 2007, 32:2585-90. [10.1097/BRS.0b013e318158dec8](https://doi.org/10.1097/BRS.0b013e318158dec8)
  54. Li Y, Hao D, He B, Wang X, Yan L: The efficiency of zero-profile implant in anterior cervical discectomy fusion: a prospective controlled long-term follow-up study. *J Spinal Disord Tech.* 2015, 28:398-403. [10.1097/BSD.0000000000000032](https://doi.org/10.1097/BSD.0000000000000032)
  55. Miao J, Shen Y, Kuang Y, Yang L, Wang X, Chen Y, Chen D: Early follow-up outcomes of a new zero-profile implant used in anterior cervical discectomy and fusion. *J Spinal Disord Tech.* 2013, 26:E193-7.

- [10.1097/BSD.0b013e31827a2812](https://doi.org/10.1097/BSD.0b013e31827a2812)
56. Zhang L, Wang J, Tao Y, Feng X, Yang J, Zhang S: Outcome evaluation of zero-profile implant compared with an anterior plate and cage used in anterior cervical discectomy and fusion: a two-year follow-up study. *Turk Neurosurg.* 2016, 26:416-22.
  57. De Leo-Vargas RA, Muñoz-Romero I, Mondragón-Soto MG, Martínez-Anda JJ: Locking stand-alone cage constructs for the treatment of cervical spine degenerative disease. *Asian Spine J.* 2019, 13:630-7. [10.31616/asj.2018.0234](https://doi.org/10.31616/asj.2018.0234)
  58. Grasso G, Landi A: Long-term clinical and radiological outcomes following anterior cervical discectomy and fusion by zero-profile anchored cage. *J Craniovertebr Junction Spine.* 2018, 9:87-92. [10.4103/jcvjs.JCVJS\\_36\\_18](https://doi.org/10.4103/jcvjs.JCVJS_36_18)
  59. Lane PD, Cox JL, Gaskins RB 3rd, Santoni BG, Billys JB, Castellvi AE: Early radiographic and clinical outcomes study evaluating an integrated screw and interbody spacer for one- and two-level ACDF. *Int J Spine Surg.* 2015, 9:39. [10.14444/2039](https://doi.org/10.14444/2039)
  60. Lonjon N, Favreul E, Huppert J, Lioret E, Delhaye M, Mraidri R: Clinical and radiological outcomes of a cervical cage with integrated fixation. *Medicine (Baltimore).* 2019, 98:e14097. [10.1097/MD.00000000000014097](https://doi.org/10.1097/MD.00000000000014097)
  61. Scholz M, Schelfaut S, Pingel A, Schleicher P, Kandziora F: A cervical "zero-profile" cage with integrated angle-stable fixation: 24-months results. *Acta Orthop Belg.* 2014, 80:558-66.
  62. Scholz M, Schnake KJ, Pingel A, Hoffmann R, Kandziora F: A new zero-profile implant for stand-alone anterior cervical interbody fusion. *Clin Orthop Relat Res.* 2011, 469:666-73. [10.1007/s11999-010-1597-9](https://doi.org/10.1007/s11999-010-1597-9)
  63. El Baz EA, Sultan AM, Barakat AS, Koptan W, ElMiligui Y, Shaker H: The use of anterior cervical interbody spacer with integrated fixation screws for management of cervical disc disease. *SICOT J.* 2019, 5:8. [10.1051/sicotj/2019002](https://doi.org/10.1051/sicotj/2019002)
  64. Gerszten PC, Paschel E, Mashaly H, Sabry H, Jalalod'din H, Saoud K: Outcomes evaluation of zero-profile devices compared to stand-alone PEEK cages for the treatment of three- and four-level cervical disc disease. *Cureus.* 2016, 8:e775. [10.7759/cureus.775](https://doi.org/10.7759/cureus.775)
  65. Grasso G, Giambardino F, Tomasello G, Iacopino G: Anterior cervical discectomy and fusion with ROI-C peek cage: cervical alignment and patient outcomes. *Eur Spine J.* 2014, 23:650-7. [10.1007/s00586-014-3553-y](https://doi.org/10.1007/s00586-014-3553-y)
  66. Chen Y, Chen H, Cao P, Yuan W: Anterior cervical interbody fusion with the Zero-P spacer: mid-term results of two-level fusion. *Eur Spine J.* 2015, 24:1666-72. [10.1007/s00586-015-3919-9](https://doi.org/10.1007/s00586-015-3919-9)
  67. He S, Feng H, Lan Z, et al.: A randomized trial comparing clinical outcomes between zero-profile and traditional multilevel anterior cervical discectomy and fusion surgery for cervical myelopathy. *Spine (Phila Pa 1976).* 2018, 43:E259-66. [10.1097/BRS.0000000000002323](https://doi.org/10.1097/BRS.0000000000002323)
  68. Qizhi S, Peijia L, Lei S, Junsheng C, Jianmin L: Anterior cervical discectomy and fusion for noncontiguous cervical spondylotic myelopathy. *Indian J Orthop.* 2016, 50:390-6. [10.4103/0019-5413.185603](https://doi.org/10.4103/0019-5413.185603)
  69. Zavras AG, Nolte MT, Sayari AJ, Singh K, Colman MW: Stand-alone cage versus anterior plating for 1-level and 2-level anterior cervical discectomy and fusion: a randomized controlled trial. *Clin Spine Surg.* 2022, 35:155-65. [10.1097/BSD.0000000000001332](https://doi.org/10.1097/BSD.0000000000001332)
  70. Khajavi K, Shen A: Safety and efficacy of bioabsorbable cervical spacers and low-dose rhBMP-2 in multi-level ACDF. *Int J Spine Surg.* 2014, 8:1-5. [10.14444/1009](https://doi.org/10.14444/1009)
  71. Bellamy JT, Dilbone E, Schell A, et al.: Prospective comparison of dysphagia following anterior cervical discectomy and fusion (ACDF) with and without rhBMP-2. *Spine J.* 2022, 22:256-64. [10.1016/j.spinee.2021.09.001](https://doi.org/10.1016/j.spinee.2021.09.001)
  72. Burkus JK, Dryer RF, Arnold PM, Foley KT: Clinical and radiographic outcomes in patients undergoing single-level anterior cervical arthrodesis: a prospective trial comparing allograft to a reduced dose of rhBMP-2. *Clin Spine Surg.* 2017, 30:E1321-32. [10.1097/BSD.0000000000000409](https://doi.org/10.1097/BSD.0000000000000409)
  73. Edwards CC 2nd, Dean C, Edwards CC, Phillips D, Blight A: Can dysphagia following anterior cervical fusions with rhBMP-2 be reduced with local Depo-Medrol application?: a prospective, randomized, placebo-controlled, double-blind trial. *Spine (Phila Pa 1976).* 2016, 41:555-62. [10.1097/BRS.0000000000001284](https://doi.org/10.1097/BRS.0000000000001284)
  74. Leach J, Bittar RG: BMP-7 (OP-1) safety in anterior cervical fusion surgery. *J Clin Neurosci.* 2009, 16:1417-20. [10.1016/j.jocn.2009.02.012](https://doi.org/10.1016/j.jocn.2009.02.012)
  75. Stachniak JB, Diebner JD, Brunk ES, Speed SM: Analysis of prevertebral soft-tissue swelling and dysphagia in multilevel anterior cervical discectomy and fusion with recombinant human bone morphogenetic protein-2 in patients at risk for pseudarthrosis. *J Neurosurg Spine.* 2011, 14:244-9. [10.3171/2010.9.SPINE09828](https://doi.org/10.3171/2010.9.SPINE09828)
  76. Singh P, Kumar A, Shekhawat V: Comparative analysis of interbody cages versus tricortical graft with anterior plate fixation for anterior cervical discectomy and fusion in degenerative cervical disc disease. *J Clin Diagn Res.* 2016, 10:RC05-8. [10.7860/JCDR/2016/16520.7340](https://doi.org/10.7860/JCDR/2016/16520.7340)
  77. Anderson KK, Arnold PM: Oropharyngeal dysphagia after anterior cervical spine surgery: a review. *Global Spine J.* 2013, 3:273-86. [10.1055/s-0033-1354253](https://doi.org/10.1055/s-0033-1354253)
  78. Rosenthal BD, McCarthy MH, Bhatt S, Savage JW, Singh K, Hsu WK, Patel AA: A comparison of patient-centered outcome measures to evaluate dysphagia and dysphonia after anterior cervical discectomy and fusion. *J Am Acad Orthop Surg.* 2019, 27:848-55. [10.5435/JAOS-D-17-00631](https://doi.org/10.5435/JAOS-D-17-00631)
  79. Kepler CK, Rihn JA, Bennett JD, Anderson DG, Vaccaro AR, Albert TJ, Hilibrand AS: Dysphagia and soft-tissue swelling after anterior cervical surgery: a radiographic analysis. *Spine J.* 2012, 12:639-44. [10.1016/j.spinee.2012.05.024](https://doi.org/10.1016/j.spinee.2012.05.024)
  80. Kang SH, Kim DK, Seo KM, Lee SY, Park SW, Kim YB: Swallowing function defined by videofluoroscopic swallowing studies after anterior cervical discectomy and fusion: a prospective study. *J Korean Med Sci.* 2016, 31:2020-5. [10.5346/jkms.2016.31.12.2020](https://doi.org/10.5346/jkms.2016.31.12.2020)
  81. Min Y, Kim WS, Kang SS, Choi JM, Yeom JS, Paik NJ: Incidence of dysphagia and serial videofluoroscopic swallow study findings after anterior cervical discectomy and fusion: a prospective study. *Clin Spine Surg.* 2016, 29:E177-81. [10.1097/BSD.0000000000000060](https://doi.org/10.1097/BSD.0000000000000060)
  82. Erwood MS, Walters BC, Connolly TM, et al.: Voice and swallowing outcomes following reoperative anterior cervical discectomy and fusion with a 2-team surgical approach. *J Neurosurg Spine.* 2018, 28:140-8. [10.3171/2017.5.SPINE161104](https://doi.org/10.3171/2017.5.SPINE161104)

85. Haws BE, Khechen B, Narain AS, et al.: Impact of local steroid application on dysphagia following an anterior cervical discectomy and fusion: results of a prospective, randomized single-blind trial. *J Neurosurg Spine*. 2018, 29:10-7. [10.3171/2017.11.SPINE17819](https://doi.org/10.3171/2017.11.SPINE17819)
84. Nam TW, Lee DH, Shin JK, Goh TS, Lee JS: Effect of intravenous dexamethasone on prevertebral soft tissue swelling after anterior cervical discectomy and fusion. *Acta Orthop Belg*. 2013, 79:211-5.
85. Villavicencio AT, Rajpal S, Nelson EL, Beasley K, Kantha V, Burneikiene S: Local retropharyngeal space anesthetic for dysphagia reduction after anterior cervical discectomy and fusion surgery: a single-center, prospective, randomized, double-blinded, placebo-controlled clinical trial. *World Neurosurg*. 2021, 146:e1377-83. [10.1016/j.wneu.2020.12.016](https://doi.org/10.1016/j.wneu.2020.12.016)
86. Kim HJ, Alluri R, Stein D, et al.: Effect of topical steroid on swallowing following ACDF: results of a prospective double-blind randomized control trial. *Spine (Phila Pa 1976)*. 2021, 46:413-20. [10.1097/BRS.0000000000003825](https://doi.org/10.1097/BRS.0000000000003825)
87. Song KJ, Lee SK, Ko JH, Yoo MJ, Kim DY, Lee KB: The clinical efficacy of short-term steroid treatment in multilevel anterior cervical arthrodesis. *Spine J*. 2014, 14:2954-8. [10.1016/j.spinee.2014.06.005](https://doi.org/10.1016/j.spinee.2014.06.005)
88. Gandhi SD, Wahlmeier ST, Louie P, Sauber R, Tooley TR, Baker KC, Park DK: Effect of local retropharyngeal steroids on fusion rate after anterior cervical discectomy and fusion. *Spine J*. 2020, 20:261-5. [10.1016/j.spinee.2019.08.018](https://doi.org/10.1016/j.spinee.2019.08.018)
89. Jeyamohan SB, Kenning TJ, Petronis KA, Feustel PJ, Drazin D, DiRisio DJ: Effect of steroid use in anterior cervical discectomy and fusion: a randomized controlled trial. *J Neurosurg Spine*. 2015, 23:137-43. [10.3171/2014.12.SPINE14477](https://doi.org/10.3171/2014.12.SPINE14477)
90. Jenkins TJ, Nair R, Bhatt S, Rosenthal BD, Savage JW, Hsu WK, Patel AA: The effect of local versus intravenous corticosteroids on the likelihood of dysphagia and dysphonia following anterior cervical discectomy and fusion: a single-blinded, prospective, randomized controlled trial. *J Bone Joint Surg Am*. 2018, 100:1461-72. [10.2106/JBJS.17.01540](https://doi.org/10.2106/JBJS.17.01540)
91. Samtani RG, Huttman D, Weinreb JH, Cyriac M, Yu W, O'Brien JR: The effect of esophageal temperature probes on postoperative dysphagia following primary anterior cervical discectomy and fusion: a randomized prospective study. *Int J Spine Surg*. 2021, 15:676-82. [10.14444/8089](https://doi.org/10.14444/8089)
92. Sejkorová A, Bolcha M, Beneš J, Kalhous J, Sameš M, Vachata P: Intraoperative measurement of endotracheal tube cuff pressure and its change during surgery in correlation with recurrent laryngeal nerve palsies, hoarseness, and dysphagia after anterior cervical discectomy and fusion: a prospective randomized controlled trial. *Global Spine J*. 2021, 29:21925682211046895. [10.1177/21925682211046895](https://doi.org/10.1177/21925682211046895)
93. Hou Y, Liu Y, Yuan W, Wang X, Chen H, Yang L, Zhang Y: Cervical kinematics and radiological changes after Discover artificial disc replacement versus fusion. *Spine J*. 2014, 14:867-77. [10.1016/j.spinee.2013.07.432](https://doi.org/10.1016/j.spinee.2013.07.432)
94. Song KJ, Lee KB: A preliminary study of the use of cage and plating for single-segment fusion in degenerative cervical spine disease. *J Clin Neurosci*. 2006, 13:181-7. [10.1016/j.jocn.2005.02.018](https://doi.org/10.1016/j.jocn.2005.02.018)
95. Bolesta MJ, Rehtine GR 2nd, Chrin AM: Three- and four-level anterior cervical discectomy and fusion with plate fixation: a prospective study. *Spine (Phila Pa 1976)*. 2000, 25:2040-4. [10.1097/00007632-200008150-00007](https://doi.org/10.1097/00007632-200008150-00007)