

Compressive optic neuropathy secondary to Ewing sarcoma in the paranasal sinus

A case report

Min Jee Lee, MD^a, Min Ho Kang, MD, PhD^a, Jong Hun Yeom, MD, PhD^b, Hoseok Yeom, MD^a, Mincheol Seong, MD, PhD^a, Heeyoon Cho, MD, PhD^a, Yong Un Shin, MD, PhD^{a,*}

Abstract

Rationale: Ewing sarcoma localized in the paranasal sinuses, compressing the optic nerve, is very rare, with no prior case reports

Patient concerns: A 68-year-old woman presented with decreased visual acuity in her left eye and paresthesia of the left face. Brain magnetic resonance imaging showed heterogeneously enhancing mass in the left paranasal sinuses with adjacent bone destruction, extending to the extraocular muscles and optic nerve of the left orbit. A biopsy of the nasal cavity confirmed Ewing sarcoma.

Diagnosis: Compressive optic neuropathy secondary to Ewing sarcoma in the paranasal sinuses.

Intervention: Neoadjuvant chemotherapy and radiotherapy were performed.

Outcomes: Resolution of the tumor and increased visual acuity and field of the left eye.

Lessons: Primary head and neck Ewing sarcoma can lead to compressive optic neuropathy, but the tumor responded well to the chemotherapy. Early diagnosis and immediate treatment by close cooperation between the ophthalmologist and oncologist can prevent from permanent visual loss.

Abbreviations: MRI = magnetic resonance imaging, OCT = optical coherence tomography, RNFL = retinal nerve fiber layer.

Keywords: compressive optic neuropathy, Ewing sarcoma, paranasal sinus

1. Introduction

Ewing sarcoma is an uncommon malignant neuroectodermal tumor consisting of small round cells, generally arising in the long bones or pelvis and soft tissue of the trunk and extremities. Primary head and neck Ewing sarcoma is uncommon, accounting for 1% to 4% of all reported cases.^[1] Ewing sarcoma localized in the paranasal sinuses, compressing the optic nerve, is very rare, with no prior case reports. Herein, we report a case of primary

Ewing sarcoma arising in the paranasal sinuses, leading to compressive optic neuropathy.

2. Case report

A 68-year-old woman presented with a 2-week history of subtle decreased visual acuity accompanied by headache, paresthesia, and paralysis of the left face. She complained that everything appeared gray through her left eye. Her medical history and review of systems were unremarkable. Ophthalmologic examinations were unremarkable with normal optic disc appearance (Fig. 1A) and normal peripapillary retinal nerve fiber layer (RNFL) thickness on optical coherence tomography (OCT) (Fig. 1B), except visual field abnormalities with generalized depression, sparing the central area in the left eye (Fig. 1C). To determine the cause of visual symptoms, brain magnetic resonance imaging (MRI) was performed and showed a 3.3-cm sized, heterogeneously enhancing mass, involving the left ethmoid, sphenoid, maxillary sinuses, and nasal cavity with adjacent bone destruction, extending to the extraocular muscles (superior oblique muscle, medial rectus muscle, and inferior rectus muscle), and optic nerve of the left orbit (Fig. 1D). A biopsy of the nasal cavity was performed and histologic study confirmed Ewing sarcoma consisting of malignant small round cells (Fig. 2).

Two days after the operation, her left visual acuity declined rapidly to 20/1000 with a relative afferent pupillary defect. The left eyeball movement was limited to a lateral gaze position. Immediately, neoadjuvant chemotherapy according to the VDC/IE protocol (vincristine 1.5 mg/d, doxorubicin 37 mg/d, and cyclophosphamide 1200 mg/d, alternating with ifosfamide 2.2 g/d and etoposide 120 mg/d) was initiated by the hematologist. A

Editor: N/A.

MJL and MHK contributed equally to this study as cofirst authors.

Informed consent was obtained from the patient for publication of this case report and its related images.

This work was supported by the research fund of Hanyang University (HY-201800000000614).

The authors have no conflicts of interest to disclose.

^aDepartment of Ophthalmology, ^bDepartment of Anesthesiology and Pain Medicine, Hanyang University College of Medicine, Seoul, Korea.

*Correspondence: Yong Un Shin, Department of Ophthalmology, Hanyang University College of Medicine, Hanyang University Guri Hospital, #153 Gyeongchun-ro, Guri, Gyeonggi-do 11923, Korea (e-mail: syu2000@hanmail.net).

Copyright © 2018 the Author(s). Published by Wolters Kluwer Health, Inc. This is an open access article distributed under the terms of the Creative Commons Attribution-Non Commercial-No Derivatives License 4.0 (CCBY-NC-ND), where it is permissible to download and share the work provided it is properly cited. The work cannot be changed in any way or used commercially without permission from the journal.

Medicine (2018) 97:44(e13027)

Received: 6 July 2018 / Accepted: 5 October 2018

<http://dx.doi.org/10.1097/MD.0000000000013027>

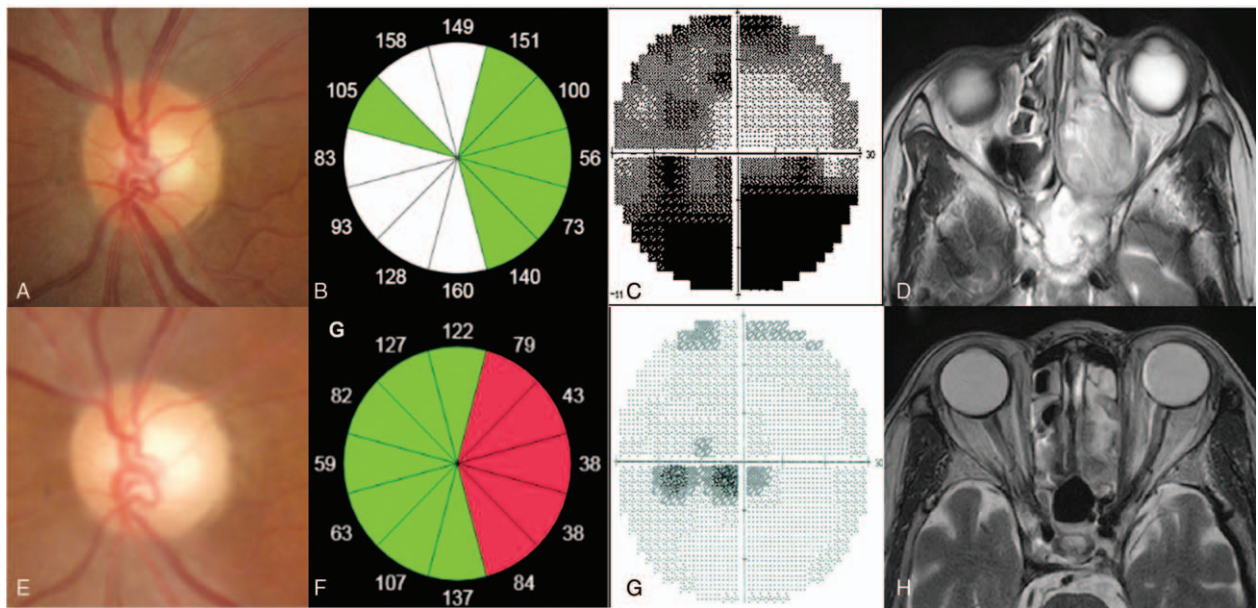


Figure 1. Changes in clinical findings of a patient with Ewing sarcoma involving paranasal sinus. (A–D) Initial examinations. (A) Disc photograph showing normal appearance. (B) Normal peripapillary retinal nerve fiber layer thickness on optical coherence tomography (OCT). (C) Visual field test showing generalized defect sparing center area. (D) Brain magnetic resonance imaging (MRI) (T2-weighted MRI) showing heterogeneously enhancing mass, involving the left ethmoid and sphenoid sinuses, and compressing the optic nerve. (E–H) Two years after completion of all 6 rounds of chemotherapy. (E) Disc photograph showing pale optic disc. Progression of peripapillary RNFL thinning using OCT. (F) Thinned peripapillary retinal nerve fiber layer thickness of temporal area on OCT. (G) Improved visual field showing mild cecentral scotoma. (H) Brain MRI showing near resolution of Ewing sarcoma. Colors (B and F) show percentiles of retinal nerve fiber layer thickness distribution; red 0–1%, yellow 1–5%, green 5–95%, white 95–100%.

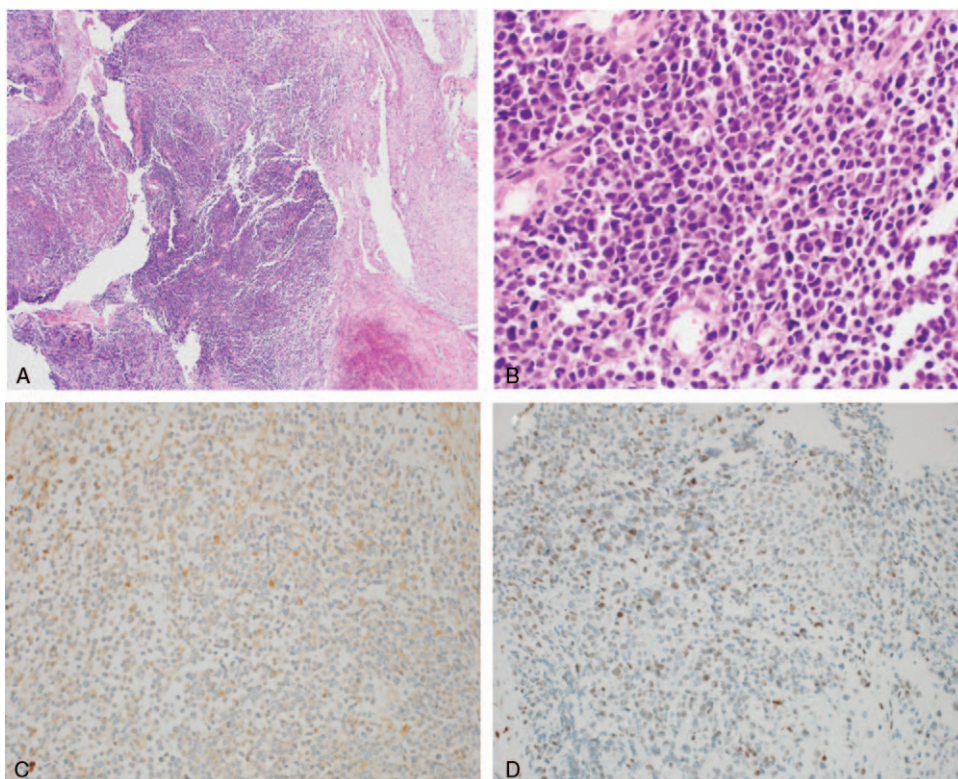


Figure 2. Histopathologic examination showing infiltration by a tumor composed of small round cells. Higher magnification showing a uniform sheet of small cells with round, bland nuclei, and small amount of clear cytoplasm. (A) ×40, (B) ×400, (C) CD99: positive, (D) FL-1: positive.

total of 5 cycles of this regimen were administered over 1 year. Between the 3rd and 4th cycles, curative radiotherapy at the primary site was administered at a total dose of 55 Gy (fractions of 2.2 Gy) for 8 weeks. The treatment was well tolerated and no incidents of major toxicity were recorded.

The tumor responded well to the chemotherapy. After the 2nd chemotherapy, visual acuity was 20/25 in the left eye with no afferent pupillary defect, and visual field was improved despite overall a little pale optic disc and progression of peripapillary RNFL thinning on OCT. Brain MRI showed decreased tumor size although the tumor persisted in the left ethmoid sinus.

After the completion of initial chemotherapy and radiotherapy, the patient's brain MRI showed near resolution of the Ewing sarcoma lesion (Fig. 1H). Maintenance chemotherapy (12 cycles of docetaxel 62 mg/d and gemcitabine 0.8 g/d) was continued for 1 year and no aggravation of the disease was observed during this period. She underwent her last ophthalmologic examination at 2 years after the onset of her symptoms. Visual acuity and field of the left eye remained stable (Fig. 1G); however, the left optic disc became somewhat pale (Fig. 1E) and thinned peripapillary RNFL was observed on OCT (Fig. 1F). After that the patient refused additional chemotherapy due to chemotoxicity and was lost to follow-up. We received informed consent from the patient for this report and its related images.

3. Discussion

Ewing sarcoma of the head and neck is rare^[1] and according to several case reports, the most common clinical symptoms are related to the tumor-mass value.^[2] In a study of 183 patients,^[3] Ewing sarcoma of the head and neck showed higher 10-year survival rates because of less metastasis and smaller tumor size compared with that of Ewing sarcomas at other sites. Nevertheless, the reason for the above characteristics is unclear.

In this case, the patient had sensory paralysis and neuropathy of the ipsilateral side accompanied by decreased visual acuity and dyschromatopsia. Based on these neurologic symptoms, the decision to perform brain imaging study was made by the physician. During the process of diagnosis, the tumor size rapidly increased and the visual acuity decreased significantly. Invasion of the orbit by the Ewing sarcoma is reported to be very rare^[1]; however, in this case, the optic nerve was compressed by the Ewing sarcoma, resulting in compressive optic neuropathy.

Tumor within the orbit or optic canal can cause damage to the optic nerve. Direct compression of the optic nerve can cause a reduction in visual acuity, visual field, and color vision. Implicated orbital disorders include meningiomas, optic gliomas, lymphomas, hemangiomas, inflammatory orbital pseudotumor, and dermoid cyst. Intracranial surgery, chemotherapy, or radiotherapy are conducted with the aim to decompress the nerve by attempting to free it of tumor mass, and thus, enable recovery of function. A dramatic return of vision after treatment of the tumor for compressive optic neuropathy is reported in many cases.^[4]

Monteiro et al reported that RNFL measurements have a stronger correlation with visual field loss and vision loss from

optic nerve compression. Furthermore, the degree of RNFL thinning is indicative of the degree of visual recovery. Despite the recovery of visual field, RNFL thinning can still persist suggesting the presence of residual damage which is similar to our case.^[5]

Ewing sarcoma is known to be both chemosensitive and radiosensitive. Treatment usually includes chemotherapy, radiotherapy, and excision. Especially, in head and neck Ewing sarcoma, treatment with chemotherapy is effective in shrinkage of the tumor with subsequent decrease in the morbidity of radiotherapy or surgery.^[6]

4. Conclusion

To the best of our knowledge, this is the first case report of Ewing sarcoma causing compressive optic neuropathy. Especially, as a treatment option, surgical excision, which may lead to optic nerve injury, can be avoided because of the high chemosensitivity feature of Ewing sarcoma. Our experience highlights that early diagnosis and immediate treatment by close cooperation between the ophthalmologist and oncologist can preserve the patient's life and prevent from permanent visual loss.

Author contributions

Conceptualization: Yong Un Shin.

Data curation: Min Jee Lee, Hoseok Yeom.

Formal analysis: Min Jee Lee, Min Ho Kang.

Funding acquisition: Yong Un Shin.

Investigation: Min Jee Lee, Heeyoon Cho, Mincheol Seong, Yong Un Shin.

Methodology: Min Jee Lee, Min Ho Kang, Hoseok Yeom, Yong Un Shin.

Project administration: Yong Un Shin.

Resources: Yong Un Shin.

Supervision: Heeyoon Cho, Mincheol Seong, Yong Un Shin.

Visualization: Min Ho Kang, Hoseok Yeom.

Writing – original draft: Min Jee Lee, Jong Hun Yeom.

Writing – review & editing: Min Ho Kang, Jong Hun Yeom, Heeyoon Cho, Mincheol Seong, Yong Un Shin.

Yong Un Shin orcid: 0000-0003-1251-8985.

References

- [1] Siegal GP, Oliver WR, Reinus WR, et al. Primary Ewing's sarcoma involving the bones of the head and neck. *Cancer* 1987;60:2829–40.
- [2] Davido N, Rigolet A, Kerner S, et al. Case of Ewing's sarcoma misdiagnosed as a periapical lesion of maxillary incisor. *J Endod* 2011;37:259–64.
- [3] Ellis MA, Gerry DR, Neskey DM, et al. Ewing sarcoma of the head and neck: analysis of 183 cases with comparison to non-head and neck sites. *Ann Otol Rhinol Laryngol* 2017;126:179–84.
- [4] Sleep T, Hodgkins P, Honeybul S, et al. Visual function following neurosurgical optic nerve decompression for compressive optic neuropathy. *Eye* 2003;17:571–8.
- [5] Monteiro ML, Cunha LP, Costa-Cunha LV, et al. Relationship between optical coherence tomography, pattern electroretinogram and automated perimetry in eyes with temporal hemianopia from chiasmal compression. *Invest Ophthalmol Vis Sci* 2009;50:3535–41.
- [6] Whaley JT, Indelicato DJ, Morris CG, et al. Ewing tumors of the head and neck. *Am J Clin Oncol* 2010;33:321–6.