

Local Cerebral Hemodynamics after Superficial Temporal Artery-Middle Cerebral Artery Bypass in Patients with Symptomatic Carotid Occlusions

Abstract

Context: Physiological insights into blood flow alterations in cortical vessels after superficial temporal artery-middle cerebral artery (STA-MCA) bypass surgery are important for the prognosis of bypass sustainability and hemodynamic patency. **Aims:** This study aims to assess the impact of STA-MCA bypass on local hemodynamics for patients with symptomatic carotid occlusions and Moyamoya disease. **Settings and Design:** This article presents a prospective nonrandomized study of intraoperative blood flow measurements in cortical branches of MCA and donor vessel before and after cerebral revascularization. **Materials and Methods:** Evaluation of local hemodynamic parameters was established for 112 patients with symptomatic carotid occlusive disease and cerebrovascular insufficiency during STA-MCA bypass surgery. We used intraoperative Doppler ultrasonography (89 patients – 72%), flowmetry (56 cases – 50%), and in 33 cases both methods. For physical justification of observed facts, we performed computational simulation with OpenFOAM CFD framework using Navier-Stokes nonstationary hemodynamic model. **Statistical Analysis Used:** All calculations were performed with IBM SPSS Statistics version 10.0 software. We used parametric (*Z*-test and Student's *t*-test) and nonparametric models (Wilcoxon, Mann-Whitney). For categorical values, we used Fisher's exact test. **Results:** Local cerebral hemodynamics after revascularization surgery significantly depended on initial perfusion deficit and the ability of bypass to reverse the blood flow in proximal parts of cortical artery (86 cases, 77%). Mechanism of cortical blood flow alteration was related to donor vessel cut flow value and potential consumption threshold of acceptor artery. **Conclusions:** Knowledge of hemodynamic principles of flow redistribution after STA-MCA bypass is important to improve bypass sustainability and leads to better revascularization results.

Keywords: Cerebral revascularization, extra-intracranial microanastomosis, ischemic stroke, perfusion deficit

Introduction

Since Yasargil performed first extra-intracranial bypass between the parietal branch of the superficial temporal artery (STA) and the cortical branch of the middle cerebral artery (MCA) in 1967,^[1] its surgical technique has undergone minimal changes. Nevertheless, the discussion about the conditions of sustainable functioning of the created anastomosis, its hemodynamic significance, and its role in the general blood supply of the brain is still alive among specialists. One of the reasons for this was the inconclusive results of large multicenter studies about the effectiveness of surgical revascularization of the brain in patients with chronic cerebral ischemia.^[2] That, in its turn, created the prerequisites for continuing scientific research^[3] to

improve the results of the STA-MCA bypass and reduce the frequency of perioperative complications. One of the directions of research is to identify the pathophysiological mechanisms of cerebral blood circulation in the condition of functioning anastomosis, where research of local cerebral hemodynamics in the donor and recipient arteries plays the key role. However, in the literature, there are only few publications devoted to this issue.^[4-8]

The main method for the study of local hemodynamics over a long period was selective cerebral angiography, which made possible to reveal the various impacts of anastomoses on cerebral blood flow (CBF).^[9-12] Angiographic criteria for hemodynamic efficiency were formulated depending on the degree of filling MCA territory through the anastomosis.^[11]

This is an open access journal, and articles are distributed under the terms of the Creative Commons Attribution-NonCommercial-ShareAlike 4.0 License, which allows others to remix, tweak, and build upon the work non-commercially, as long as appropriate credit is given and the new creations are licensed under the identical terms.

For reprints contact: reprints@medknow.com

How to cite this article: Shulgina A, Lukshin V, Usachev D, Shevchenko E. Local cerebral hemodynamics after superficial temporal artery-middle cerebral artery bypass in patients with symptomatic carotid occlusions. *Asian J Neurosurg* 2019;14:853-62.

**Anna Shulgina,
Vasily Lukshin,
Dmitry Usachev,
Elena Shevchenko**

*N. N. Burdenko National
Scientific and Practical Center
of Neurosurgery, Moscow,
Russia*

Address for correspondence:

*Dr. Anna Shulgina,
16, 4th Tverskaya-Yamskaya
Street, Moscow, Russia.
E-mail: ashulgina@nsi.ru*

Access this article online

Website: www.asianjns.org

DOI: 10.4103/ajns.AJNS_78_19

Quick Response Code:



However, these works provided only a qualitative analysis of local hemodynamics after the creation of bypass and did not allow to obtain quantitative information on changes in CBF in the territory of revascularization.

Spetzler and Owen were one of the first who presented the experience of using instrumental methods for the study of local hemodynamics in 1979–1980 in a series of works devoted to the creation of bypass in patients with giant aneurysms of the internal carotid artery (ICA). Based on the direct manometry in the donor and recipient arteries, he revealed a pressure gradient between the branches of external carotid artery (ECA) and ICAs, that exists even normally, increases in case of occlusion of the ICA and determines the value of blood flow through the anastomosis.^[13,14]

The introduction of intraoperative contact dopplerography and flowmetry into clinical practice^[15] made it possible to quantify the local blood circulation in the territory of revascularization immediately after creating the bypass, which opened up new possibilities for studying the pathophysiology of cerebral circulation in patients with chronic cerebral ischemia.^[5,8,16] In particular, retrograde and anterograde types of blood flow direction in cortical arteries in patients with Moyamoya disease (MMD)^[17] were detected, reference values of blood flow in cortical arteries in patients with signs of cerebral ischemia were obtained before and after performing STA-MCA bypass.^[5]

Nevertheless, the questions of studying the pathophysiological mechanisms of local blood supply reorganization in the territory of revascularization remain open. Their study can have great theoretical and practical importance. The aims of this work were to study the hemodynamic efficiency and sustainability of the anastomosis, identify criteria for the development of local hyperperfusion in the area of revascularization, and determine the parameters of cerebral hemodynamics depending on the initial value of perfusion deficit, based on intraoperative flowmetry, dopplerography, and direct measurement of pressure in the donor and recipient arteries.

Materials and Methods

A total of 112 patients with unilateral symptomatic occlusions of the carotid arteries, who were treated in Burdenko National Scientific and Practical Center for Neurosurgery from 1999 to 2015, were studied. Among them, there were 105 patients with occlusions of the ICA and 7 patients with MMD. Indications for surgical revascularization were unstable or undulating neurological symptoms in combination with the presence of gross perfusion deficit and reduced cerebrovascular reserves (CVR) in the territory of carotid occlusion. In all cases, the indications for surgical revascularization were discussed at the multidisciplinary commission, and the consent of patients and their relatives and approval of the

local ethical committee of the center for neurosurgery were obtained.

Cerebral revascularization was carried out by performing microanastomosis between the parietal branch of the STA and the cortical branches of the MCA according to the classical method. In all patients, local hemodynamic parameters were studied intraoperatively before and after the STA-MCA bypass using intraoperative contact Doppler sonography (89 patients – 72%) and flowmetry (56 observations – 50%). In 33 cases (29%), both modalities were used.

Intraoperative contact dopplerography was performed using a 16 MHz sensor (RIMED DigiLite, Israel). To exclude angular errors in measuring the Doppler signal, the sensor tightly pressed against the wall of the selected artery at a minimum angle to it. The depth of the location was set at 3–5 mm. The absolute values of the linear blood flow velocity (LFV) in the cortical artery were measured before performing the bypass. Then, based on these data, spectral patterns of blood flow were assessed by calculating of pulsation index (pulsating index [PI] - the ratio of the difference in the values of systolic and diastolic LFV to the average LFV), and the initial blood flow direction was determined. After performing of bypass, the LFV was measured in the created anastomosis, at the distal and proximal parts of the cortical artery, and the change in the direction of blood flow in the cortical artery after bypass was also evaluated [Figure 1a].

For intraoperative contact flowmetry, a two-channel digital flowmeter (Transonic, USA) was used with a set of sterilizable sensors with diameters of 1.5 and 2 mm. Measurement of volumetric blood flow (VBF) was performed in the donor artery during its harvesting (determination

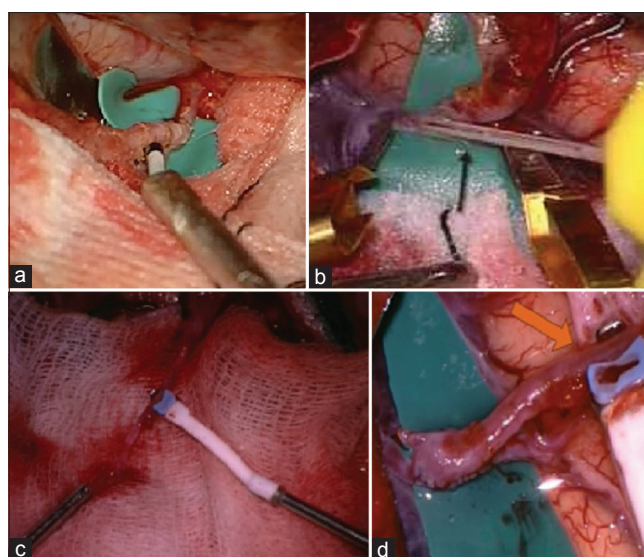


Figure 1: (a) Intraoperative contact dopplerography; (b) Direct intravascular pressure measurement in the recipient artery; (c) Free flow study ("Cut Flow") using a flowmeter; (d) Control of bypass function using flowmeter

of free blood flow-“Cut flow”) [Figure 1c], in the cortical artery, and in the created bypass [Figure 1d]. For determining the potential power of the donor artery, the volume of free blood outflow (without peripheral resistance) from the donor artery (“Cut flow”) was measured. For these aims, it was harvested from the tissues and crossed distally. Its lumen was thoroughly rinsed with a solution of papaverine until the maximum blood flow from the branch was obtained, and then VBF was measured using contact flowmetry.

In addition, in 15 patients (13%), a direct measurement of blood pressure in the donor and recipient arteries was performed. For this plastic catheter with 3–4 F size was used, and two arterial lines: One to study the blood flow in the donor and recipient arteries, the others were the control line in the radial artery to monitor systemic blood pressure. In the recipient artery, the pressure was measured after an arteriotomy and catheterization of the cortical artery proximally [Figure 1b].

To study the parameters of local hemodynamics based on the value of the perfusion deficit, 42 patients were examined with computed tomography perfusion (CTP) technique according to the standard protocol^[18] with intravenous bolus administration 40–60 ml of a contrast agent (“Ultravist,” 300 mg/ml) depending on the age and weight of the patient. The processing of cerebral perfusion data was carried out on a workstation (GE Advantage Workstation) using integrated software (CTP) and numerical deconvolution algorithms (singular-value decomposition).

Based on the changes in the parameters of CTP, three groups of patients with different types of perfusion deficit were distinguished. The first group consisted of six patients with acute occlusions of the ICA and signs of CBF decompensation, according to CTP. These signs were presented by an increase in hemispheric blood transit time (mean transit time [MTT]) on the occlusion side (>180% of contralateral values, or more than 10 s), in combination with an increase in cerebral blood volume (>115% of contralateral values) and a decrease in regional blood flow (CBF) (<80% of contralateral values).

The second group included 25 patients with the consequences of a disabled ischemic stroke, slow rehabilitation dynamics, and an undulate neurological

deficit. On CTP, they showed long-lasting extensive perfusion deficit with an increase in MTT (160%–180% of contralateral values, or >8 sec) with small ischemic lesions (ASPECTS >8) and exhausted CVR.

The third group of patients consisted of 11 patients with unstable neurological symptoms with the signs of subcompensation of chronic oligemia, unsusceptible for medical therapy. CTP changes were represented by an increase in blood transit time (140%–160% of contralateral values), with persistently reduced CVR with a slight decrease in regional blood flow (within 17% relative to the opposite intact side).

The evaluation of bypass patency was carried out on the 7th day after the operation and further during follow-up. The anastomosis was visualized with a cardiosynchronized measurement of the VBF velocity according to ultrasound data, followed by verification using CT-angiography.

For statistical evaluation, we use parametric and nonparametric methods with a significant level equal to 0.05. Parametric models included Z-test and Student’s *t*-test with verification of normal distribution for analyzed values with Kolmogorov–Smirnov normality test. Nonparametric models included Wilcoxon rank-sum test and Mann–Whitney U-test. For the evaluation of nonquantitative classified values we used Fisher’s exact test. All calculations were performed in IBM SPSS Statistics environment (IBM Corp., IBM SPSS Statistics for Mac, Version 23.0. Armonk, NY, USA).

In order to justify the hemodynamic patterns identified during the study, a computational experiment was conducted with two-dimensional geometric model of the anastomosis, which was imposed at an angle of 45° depending on the direction of blood flow in the donor and recipient arteries. Initial and boundary no-slip conditions were selected according to register *in vivo* measurements. All calculations were performed in OpenFOAM environment for nonstationary navier-stokes model with graphical postprocessing using ParaView 5.6 (Kitware Inc., USA).

Results

Totally, 112 STA-MCA bypasses were performed. No perioperative complications and mortality were seen.

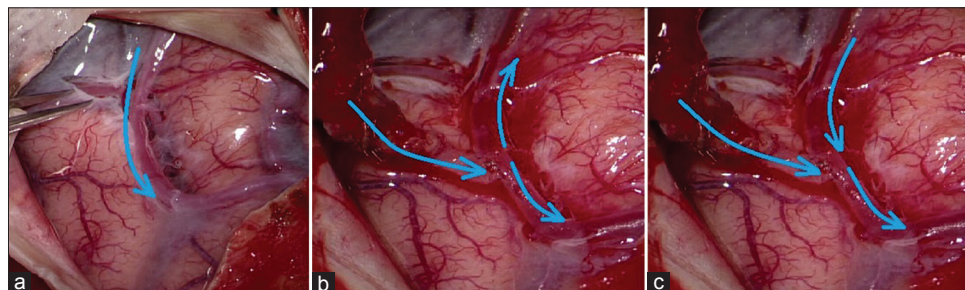


Figure 2: Changing the direction of blood flow in the cortical artery after the bypass: (a) The initial direction of blood flow; (b) Changing the direction of the blood flow (the blood flow reverses in the proximal part of the recipient artery); (c) No changes in blood flow after bypass

During follow-up examinations, a functioning anastomosis was confirmed in 108 cases (96.3%). The average VBF in bypass was 34.2 ± 5.7 ml/min. Thrombosis of the anastomosis during the follow-up was seen in 4 cases (3.7%).

The direction of blood flow in the cortical arteries before the bypass

The study revealed that in patients with ICA occlusion (105 patients) in all cases, blood flow in the distal direction was seen. For patients with MMD (7 observations), retrograde blood flow in the cortical arteries (proximal direction of blood flow) was seen more often in 5 cases (71%).

Parameters of hemodynamics in the cortical arteries before the bypass

The parameters of CBF obtained during the study differed significantly depending on the initial degree of perfusion deficit ($P = 0.045$; $|z| = 1.978$). At the same time, all studied patients had a reduced pressure in the cortical arteries that averaged 54.6 ± 5.4 mm Hg, which was almost two times less than the systemic arterial pressure [Table 1].

The obtained results confirm the dependence of the parameters of the cortical blood flow on the parameters of MTT, diagnosed during the preoperative CTP. Thus, the greatest reduction in blood pressure in the recipient artery was noticed in patients in the acute period with the greatest perfusion deficit (Group 1) – to 42.2 ± 7.4 mm Hg, while in patients with the least changes of cerebral perfusion (Group 3) blood pressure in the proximal cortical artery was only slightly inferior to the normal values. Thus, the results of preoperative CTP studies made it possible to correctly identify the degree of reduction in perfusion pressure in the branches of MCA. The consequence of the decrease in perfusion pressure in the analyzed group of patients was a decrease in the VBF in the cortical arteries. According to the results of flowmetry in the recipient

artery in patients with chronic cerebral ischemia, the value of blood flow ranged from 4.8 to 12.1 ml/min, averaging 8.9 ± 2.7 ml/min (blood flow in the M4 segment of the MCA normally is from 12 to 18 ml/min).^[4,19] The value of the blood flow significantly differed depending on the initial perfusion deficit. In patients with gross cerebrovascular insufficiency (group 1), the VBF was the smallest and amounted to only 6.7 ± 1.2 ml/min. For patients with long-lasting oligemia (Group 2), the value of VBF averaged 8.7 ± 2.2 ml/min, wherein significant variation in blood flow values was seen that varied from 7.4 to 12.5 ml/min. In patients with signs of chronic oligemia, the highest values of blood flow were registered – 11.3 ± 1.4 ml/min.

The described hemodynamic changes in patients with different perfusion deficits corresponded to the data of intraoperative contact Doppler sonography; wherein, there were changes in both patterns of LFV (systolic/diastolic) and spectral patterns indicating the value of peripheral resistance in the branches of MCA on the occlusion side – shown in Figure 3.

In patients with critical cerebrovascular insufficiency (group 1), the greatest decrease in systolic blood flow velocity was noted-up to 10.3 ± 1.2 cm/s. At the same time, a collateral type of blood flow was detected in the cortical artery ($PI < 0.6$) [Figure 3a and b]. A similar Doppler ultrasound picture was also observed in the group of patients with persisting gross cerebrovascular insufficiency; only slightly larger values of systolic LFV were observed 13.6 ± 1.8 cm/s [Figure 3c and d]. In the group of patients with chronic oligemia, the blood flow in the cortical artery was close to normal values (17–25 cm/s) [Figure 3e and f].^[4,19] No impact of the initial degree of perfusion deficit on the value of blood flow in the diastole was detected.

Parameters of hemodynamics after the bypass

Changes in local hemodynamics after the bypass, depending on its hemodynamic significance, are of great interest. For this

Table 1: Parameters of local hemodynamics depending on the initial degree of perfusion deficit (42 patients)

Parameters	Perfusion deficit			Mean
	I group	II group	III group	
Perfusion parameters on CTP	MTT >14 s (>180% of contralateral values)	MTT >8 s (>160% of contralateral values)	MTT >6 s (>140% of contralateral values)	
Mean blood pressure (mm Hg) ^a				
In cortical	42.2±7.4	53.2±7.4	61.8±6.8	54.6±5.4
In donor	91.1±8.1	94.7±7.1	99.2±10.1	96.8±8.2
Systemic	105±7.4	98.3±8.9	102±9.7	101.5±7.9
LFV in cortical (cm/s) ^b				
Systolic	10.3±1.2	13.6±1.8	16.8±1.7	14.2±1.5
Diastolic	8.7±0.9	8.3±0.7	8.6±0.9	8.5±0.8
VBF (ml/min) ^c	6.7±1.2	8.7±2.2	11.3±1.4	8.9±2.7
Total	6	25	11	42

^aDirect measurement in the proximal part of cortical arteries (15 patients); ^bDopplerography in the group of patients with CTP (42 patients); ^cFlowmetry in the group of patients with CTP (21 patients). MTT – Mean transit time; CTP – Computed tomography perfusion, LFV – Linear blood flow velocity; VBF – Volumetric blood flow

purpose, measurements of the values and directions of blood flow in the recipient artery in the proximal and distal to the anastomosis parts were made. The main parameters of local cerebral hemodynamics after the bypass are shown in Table 2.

The assessment of patency of the donor vessel was carried out by measuring the free blood flow (“Cut Flow”) after its marginal cutting and dilation with plastic catheter with papaverine. The obtained values of free VBF in the cutoff vessel with no peripheral resistance characterized the maximal available VBF in the bypass. In our study,

the free blood flow in the donor artery ranged from 11 to 42 ml/min, averaging 27.3 ± 14.8 ml/min ($P < 0.05$).

As shown in Table 2, local hemodynamics in the cortical arteries after revascularization significantly depended on the ability of bypass to reverse the blood flow in the proximal part of the recipient artery. Despite the presence of a pressure gradient between the donor artery (branches of ECA) and the proximal parts of the recipient artery in all cases, a reverse in the direction of blood flow was observed only in 86 cases (77%) [Figure 2b]. In 26 patients (23%),

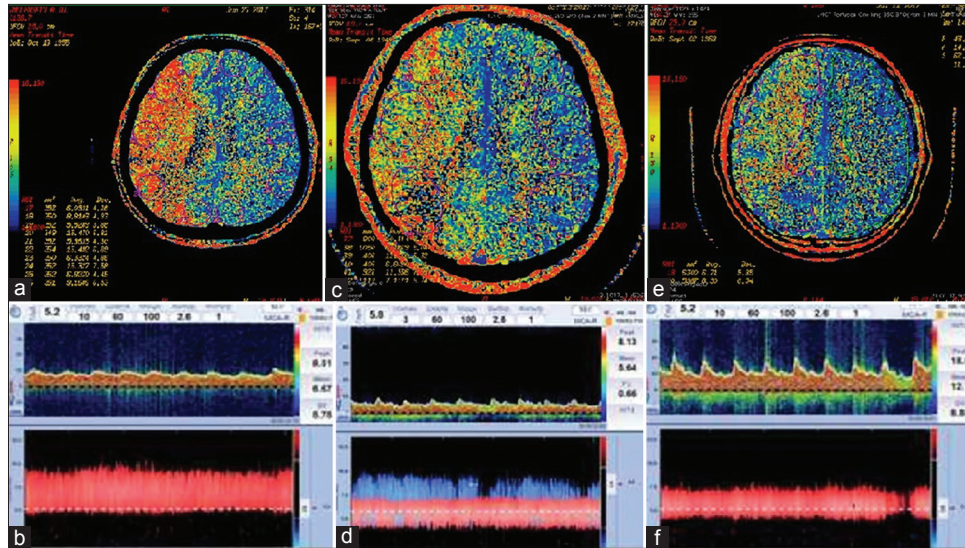


Figure 3: Contact Doppler ultrasonography patterns of blood flow in cortical M4 branches of middle cerebral artery according to the severity of perfusion deficit. (a) Gross perfusion deficit on computed tomography perfusion with mean transit time prolongation more than 14 s (>180% of contralateral values) and corresponding cortical blood flow (b); (c) Persistent severe perfusion deficit on computed tomography perfusion with mean transit time prolongation more than 8 s (>160% of contralateral values) and corresponding cortical blood flow (d); (e) Moderate perfusion deficit on computed tomography perfusion with mean transit time prolongation more than 6 s (>140% of contralateral values) and corresponding cortical blood flow (f)

Table 2: Local hemodynamics after the bypass

Parameters	Cortical artery proximally		P, z
	Reverse of blood flow	No reverse of blood flow	
“Cut flow” in donor artery (ml/min)	31.3±4.1, 18-42	15.7±2.3, 11-21	<0.031, 2.198
LFV in cortical artery			
Systolic	11.7±2.5	18.6±2.2	<0.047, 1.974
Diastolic	8.1±1.2	7.7±0.9	
Direction of bypass ^a (%)			
Proximal	55 (69)	11 (42)	n/s
Distal	31 (31)	15 (58)	
Blood flow after bypass (cortical artery)			
Doppler ultrasound			
Distally (cm/s)	23.7±2.8	21.3±3.6	n/s
Proximally (cm/s)	27.9±6.9	14.7±1.9	<0.001
Flowmetry			
Distally (ml/min)	16.7±1.8	14.3±0.9	n/s
Proximally (ml/min)	18.2±4.1	10.6±0.8	<0.001
Blood flow in bypass ^b (ml/min)	38.5±9.7	19.3±4.6	<0.05
Thrombosis of bypass	-	4	<0.001
Total (112) (%)	86 (77)	26 (23)	

^aAnastomosis was applied at an angle of 45° to the distal or proximal parts of acceptor artery; ^bAccording to postoperative ultrasound study. LFV – Linear blood flow velocity; n/s – Not statistically significant

the direction of blood flow in the cortical artery did not change [Figure 2c].

The direction of the bypass in relation to the initial direction of blood flow

The quality of the created anastomosis and its direction in relation to the initial direction of blood flow in the recipient artery are of great importance. In our group of patients, the bypass was oriented at an angle of 45° (like a fish mouth) in both proximal (66 cases, 59%) and distal (46 cases, 41%) directions in relation to the blood flow in the cortical artery. At the beginning of the study, the direction of the anastomosis was chosen randomly without taking into account associated factors. Subsequently, based on the results obtained during the study, the direction of the anastomosis was determined by indications, depending on the values of cut flow value in the donor artery. When analyzing the results of surgical revascularization in the group of patients with the changed direction of blood flow in the proximal part of recipient artery we reveal good patency of the bypass in all cases during the whole follow-up period. At the same time, there was no statistically significant impact of the direction of the bypass on the final value of blood flow through the bypass (39.1 ± 8.9 ml/min in the proximal direction of bypass, 36.9 ± 9.1 ml/min in the distal direction).

Different results were obtained in patients with the preserved direction of blood flow in the recipient artery after the bypass. Thus in this group of patients, there were four thromboses of bypasses during the long-term follow-up. Wherein in three cases thrombosis developed with the proximal direction of the bypass (11%), despite the fact that in all cases the blood flow in the donor artery was instrumentally confirmed during the operation. Moreover, only in one case of distally oriented anastomosis (3.8%), we noticed bypass failure that could be explained by the possible technical error of the suture. In addition, in patients with preserved direction of blood flow in the recipient artery after the bypass, a significant decrease in the volume blood flow was seen when the bypass was applied in the proximal direction (against the blood flow in the recipient artery) - 16.8 ± 2.9 ml/min compared to 21.1 ± 3.6 ml/min for the distal direction of bypass (along the blood flow in the recipient artery) ($P < 0.05$;

$|z| = 1.9697$; Student's *t*-test). Apparently, hemodynamic factors that obstruct blood flow through the anastomosis and associated physical phenomena of collision flow in the area of the anastomosis were the reason for the decreased blood flow in such cases.

To study them and to explain the reasons for decrease in the effectiveness of the anastomosis, when it was applied against the blood flow in the recipient artery, a series of mathematical calculations of the corresponding two-dimensional model was performed [Figure 4]. It was found that in case when the direction of blood flow in the acceptor artery is preserved after the bypass, the creation of the bypass in the proximal direction can lead to a collision of flows with the formation of a region of turbulence and hemodynamic stenosis [indicated by a red arrow on Figure 4a and b].

This may cause a decrease in blood flow both in the anastomosis and in the cortical artery [Figure 4b]. Modeling of the anastomosis along the direction of initial blood flow in the cortical artery [Figure 4c] revealed that no hemodynamic stenosis occurs, on the contrary, there is an increase in the velocity profile in the anastomosis area, which contributes to an increase in blood flow both in the distal part of the recipient artery and in the anastomosis itself. When comparing the results of calculations, the value of blood flow in the cortical artery after the anastomosis along flow direction in recipient artery (distal) was higher by 11%–13% than the value of blood flow in the anastomosis against the initial direction of cortical flow (proximal).

Discussion

Nowadays, modern methods of neuroimaging make it possible accurately to determine patients who need cerebral revascularization; however, the contradictory results of multicenter studies indicate the need for additional, more detailed, study of this problem. Obviously, the results of surgical intervention depend not only on the correct indications for surgery but also on the quality of the performed revascularization, the hemodynamic effectiveness of the created anastomoses, their ability to compensate the existing perfusion deficit and prevent possible complications of surgical treatment. In this regard,

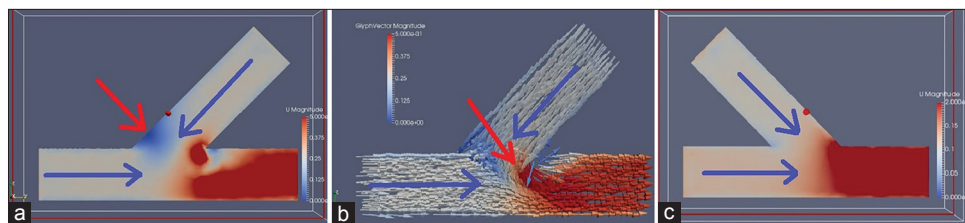


Figure 4: Results of mathematical modeling of blood flow in the anastomosis area, made at an angle of 45° (blue arrows indicate the direction of blood flow): The profile of blood flow velocity in the anastomosis against the blood flow in the recipient artery with the formation of hemodynamic stenosis and the turbulent blood flow region in a scalar (a) and vector representation (b); (c) A wide velocity profile in the anastomosis region “along the blood flow” without functional stenosis

studies of local hemodynamics are of great theoretical and practical interest, as evidenced by a series of actual works devoted to this problem.^[4-8]

When planning a surgery of creating STA-MCA bypass, preoperative diagnostics data of cerebrovascular insufficiency are very important. In our study, the method of CTP, widely used in clinical practice, was chosen as the main method for determining the perfusion deficit. When measuring blood flow in the cortical arteries, the MTT parameter was validated as a marker of gross cerebral ischemia, wherein the degree of its prolongation influenced the values and spectral patterns of blood flow in the cortical arteries. Thus, according to the data obtained by our group of patients, the LFV ranged from 10.3 to 16.8 cm/s, and the VBF ranged from 6.7 to 11.3 ml/min, while lower values were recorded in patients with gross perfusion deficit (prolongation of MTT more than 180% compared with the contralateral side). The obtained data correspond to the results of blood flow measurements in patients with signs of poor perfusion selected for surgery based on isotopic diagnostic methods - the average VBF in the cortical artery in them was 4.4 ml/min with an average linear blood flow rate of 9–15 cm/s.^[4-8]

Another important aspect of assessing the effectiveness of cerebral revascularization is the study of changes in blood flow after the bypass. It is known that the value of blood flow in the recipient artery after bypass largely depends on the size and throughput of the donor artery. Amin-Hanjani *et al.* introduced the term “Cut flow-index” – the maximum potential value of blood flow in a donor artery, which averages 68 ml/min (4–186 ml/min).^[15] In our work, the free blood flow in the donor artery ranged from 11 to 42 ml/min, averaging 27.3 ± 14.8 ml/min.

Exactly, the data on the volume of blood flow in the donor artery determine the change in the direction of blood flow in the recipient artery after the bypass. Greater hemodynamic significance was noted in patients with signs of proximal filling of the MCA territory, presented by a significantly higher value of the VBF rate in the bypass – 38.5 ± 9.7 ml/min compared to 19.3 ± 4.6 ml/min in patients with filling of only distal MCA territory ($P < 0.028$, $|z| = 2.2341$; Student's *t*-test).

Furthermore, the mechanism of the local CBF alteration in the recipient artery, observed in the study, is of great interest. In most cases, the value of the linear and VBF rates distally to the anastomosis did not exceed 20 ml/min and 30 cm/s, averaging 16.7 ± 1.8 ml/min, and 23.7 ± 2.8 cm/s, respectively, regardless of the direction of blood flow in the proximal part of the recipient artery. The small variability of the obtained values of the distal blood flow, apparently, indicates the physiological limit of the blood supply of the territory of the cortical artery, determined by the size of the distal branches and the mechanisms of CBF autoregulation.

With a higher power of the donor artery, the blood supply was redistributed toward proximal parts of the MCA branches. The saturation limit of the proximal parts of MCA is significantly greater than the distal one; therefore, the value of the proximal blood flow was limited only by the power of the donor artery. This explains the greater variation in the values of volumetric and linear blood flow rates in the proximal parts of the recipient artery, according to cut flow values of donor vessel, as well as their larger average values – 18.2 ± 4.1 ml/min and 27.9 ± 6.9 cm/s, respectively.

In patients with no proximal filling of the MCA territory, there was a significant increase in the distal blood flow up to the “saturation” threshold-on average, volumetric and linear blood flow rates were 14.3 ± 0.9 ml/min and 21.3 ± 3.6 cm/s, respectively. No changes in the proximal blood flow were noticed. The main factor affecting the ability of bypass to fill the proximal parts of the MCA territory was the potential power of the donor artery, and its importance in the ability to change the direction of blood flow in the acceptor artery was more significant than the pressure gradient. Hence, in the group of patients with changes in the direction of blood flow in the recipient artery after bypass, the free blood flow in the donor artery was significantly higher – 31.3 ± 4.1 ml/min compared to 15.7 ± 2.3 ml/min in the group without changes in blood flow direction ($P < 0.031$; $|z| = 2.198$; Student's *t*-test). When the free blood flow in the donor artery was higher than 28 ml/min, the blood flow in the proximal cortical artery changed its direction in all cases, <18 ml/min - the blood flow in the acceptor artery preserved its direction [Figure 2]. With a cut flow varied from 18 to 28 ml/min, the direction of blood flow in the cortical arteries after bypass depended on additional factors: the initial degree of perfusion deficit, diameter of the recipient artery, and volume of blood flow in recipient artery, the presence of spasm of the donor artery.

Thus, when determining the direction of the bypass creating, it is advisable to assess the probability of change in the direction of blood flow in the proximal cortical artery. In patients with medium-sized STA branches and low free blood flow through them, it is preferable to apply the bypass along the direction of blood flow in the cortical vessel (distal direction). The creation of the anastomosis in the distal direction is absolutely indicated when the free blood flow through the donor artery is <20 ml/min. Otherwise, due to the collision of streams, hemodynamic obstacles to the blood flow develop that reduce the effectiveness of the anastomosis and can lead to its malfunction. The proximal direction for the anastomosis can be confidently selected when the free blood flow through the donor artery is more than 28 ml/min. When the “Cut Flow” is in the range of 20–30 ml/min, both a change in the proximal blood flow and its preservation are possible. In the latter case,

the formation of the anastomosis in the distal direction is prognostically safer - this creates the best conditions for the functioning of the anastomosis even in the case of a change in the direction of blood flow in the proximal part of the recipient artery immediately or later.

This studied mechanism of the reorganization of blood circulation in the cortical arteries has another practical application - the early detection of a local hyperperfusion syndrome after the bypass. The hyperperfusion syndrome has been reported after carotid endarterectomy,^[20] carotid artery stenting,^[21] and also after bypass surgery in patients with atherosclerotic occlusions^[22] and MMD.^[23] After revascularization surgery, a rapid and significant increase in ipsilateral CBF beyond the metabolic demand of the brain tissue may occur.

Impairment of autoregulatory functions in the regions of chronic ischemia may contribute to a transient or permanent ischemic injury to an already susceptible area.^[8] Excessive blood flow directed into chronically ischemic brain through a bypass may induce a “luxury perfusion syndrome” resulting in neurological deterioration.^[24] Patients with poorer cerebrovascular reactivity are known to have potentially higher risk for hyperperfusion syndrome.^[23]

In our series of observations, the development of local hyperperfusion syndrome, verified by CTP-pattern of “luxury perfusion” [Figure 5], was connected with an increase in blood flow in the recipient artery above the indicated “saturation threshold”. In these cases, the cause of hyperperfusion syndrome is a breakdown of autoregulation mechanisms. Consequently, the blood flow in the distal part of the recipient artery is more than 30 cm/s in combination with high values of retrograde blood flow in the proximal direction [Figure 6].

Several methods have been proposed for the detection of cerebral hyperperfusion during operation or early after operation.^[25] Gesang *et al.*^[26] indicated that laser Doppler flowmeter is useful for postoperative real-time monitoring during the high-risk period. Intraoperative measurements such as thermography, infrared brain surface monitoring, and ICG fluorescence angiography predict postanastomosis cortical hemodynamics.^[25,27] Morisawa *et al.* in their study^[5] revealed that systolic

maximum flow velocity in recipient vessels after the bypass significantly elevates in patients with postoperative cerebral hyperperfusion on Xe-CT and is significantly higher than in those without cerebral hyperperfusion. Nakayama *et al.*^[6] defined that postoperative hyperperfusion syndrome is developed when there is an elevation of bypass blood flow over 50 ml/min.

The proposed method for the early diagnosis of hyperperfusion syndrome with an increase in blood flow in the recipient artery over 30 cm/s distally to bypass does not contradict the existing criteria and can supplement them to improve the accuracy of early detection. Thus, intraoperative diagnostics of local hemodynamics can also be helpful to predict postoperative hyperperfusion.

Conclusions

1. Planning of cerebral revascularization according to local hemodynamic measurements in donor and recipient vessels before and after STA-MCA bypass leads to better bypass patency during follow-up
2. Decrease of cortical blood flow on the side of carotid occlusion corresponds to the degree of perfusion deficit measured by MTT prolongation
3. Local hemodynamics in cortical recipient arteries depends on cut flow value in donor vessel and its potential power to reverse blood flow direction in proximal segments of the recipient artery. Retrograde blood flow is established after complete filling of the distal branches of the recipient artery. Described algorithm of local blood flow alteration after bypass can explain local hyperperfusion syndrome in cases of autoregulation failure
4. In cases of low flow in the donor vessel, the risk of its thrombosis is higher than the risk of hyperperfusion, so it is rational to perform bypass with low-flow donor vessels in distal direction to provide hemodynamic patency and power of STA-MCA bypass.

Financial support and sponsorship

Nil.

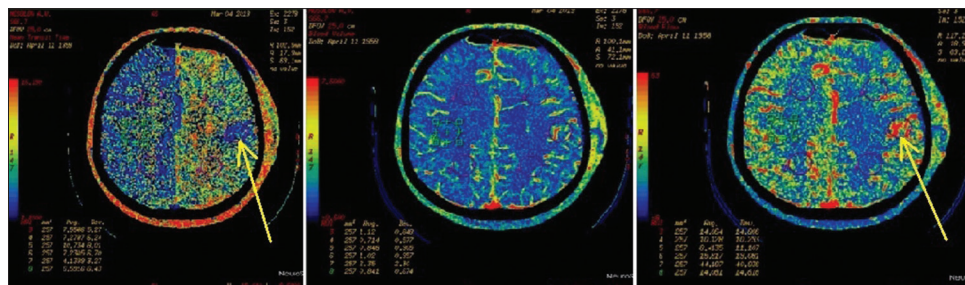


Figure 5: Computed tomography perfusion: local hyperperfusion (“luxury perfusion”) is registered as the area of increased blood flow (arrow) compared with the area of comparison with a sharply reduced mean transit time (r mean transit time <1; rCBF >> 1)

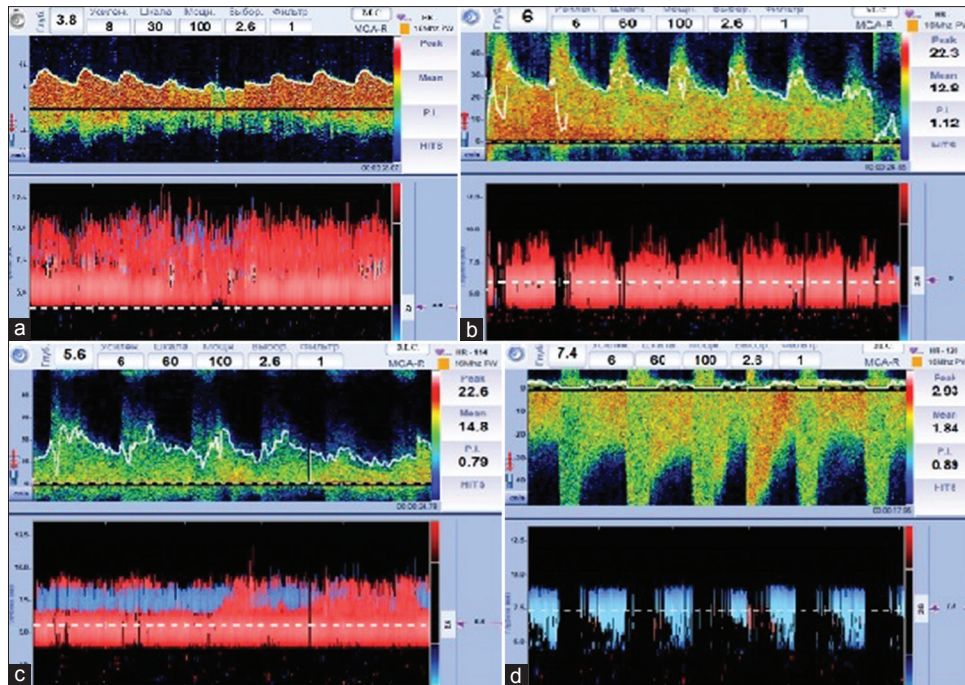


Figure 6: Local hemodynamics in a patient with carotid occlusion before and after the bypass - high risk for local hyperperfusion syndrome. (a) Blood flow velocity in the cortical artery before the bypass, <10 cm/s; (b) Blood flow velocity in the bypass, 50 cm/s; (c) Measurement of blood flow at the distal part of anastomosed site in the recipient artery, blood flow >30 cm/s. The distal direction of blood flow. US marker of local hyperperfusion; (d) Measurement of blood flow at the proximal part of the anastomosed site in the recipient artery, blood flow >55 cm/s. The reverse of blood flow – proximal direction of blood flow

Conflicts of interest

There are no conflicts of interest.

References

1. Yasargil MG. Anastomosis between the superficial temporal artery and a branch of the middle cerebral artery. In: *Microsurgery Applied to Neuro-Surgery*. Stuttgart: George Thieme Verlag; 1969. p. 105-15.
2. The international cooperative study of extracranial/Intracranial arterial anastomosis (EC/IC bypass study): Methodology and entry characteristics. The EC/IC bypass study group. *Stroke* 1985;16:397-406.
3. Grubb RL Jr., Derdeyn CP, Fritsch SM, Carpenter DA, Yundt KD, Videen TO. Importance of hemodynamic factors in the prognosis of symptomatic carotid occlusion. *JAMA* 1998;280:1055-60.
4. Carter LP, Crowell RM, Sonntag VK, Spetzler RF. Cortical blood flow during extracranial-intracranial bypass surgery. *Stroke* 1984;15:836-9.
5. Morisawa H, Kawamata T, Kawashima A, Hayashi M, Yamaguchi K, Yoneyama T, et al. Hemodynamics and changes after STA-MCA anastomosis in moyamoya disease and atherosclerotic cerebrovascular disease measured by micro-Doppler ultrasonography. *Neurosurg Rev* 2013;36:411-9.
6. Nakayama N, Kuroda S, Houkin K, Takikawa S, Abe H. Intraoperative measurement of arterial blood flow using a transit time flowmeter: Monitoring of hemodynamic changes during cerebrovascular surgery. *Acta Neurochir (Wien)* 2001;143:17-24.
7. Ashley WW, Amin-Hanjani S, Alaraj A, Shin JH, Charbel FT. Flow-assisted surgical cerebral revascularization. *Neurosurg Focus* 2008;24:E20.
8. Lee M, Guzman R, Bell-Stephens T, Steinberg GK. Intraoperative blood flow analysis of direct revascularization procedures in patients with moyamoya disease. *J Cereb Blood Flow Metab* 2011;31:262-74.
9. Bragina LK. Extra-Intracranial Features of Circulation in Occlusive Arterial Cerebral Disease (Angiographic Study). Thesis for Doctor of Medicine; T. Moscow; 1974.
10. Dobzhansky NV. Cerebral Hemodynamics and Extra-Intracranial Anastomosis in Patients with Occlusive Lesions of the Carotid Arteries. Thesis. Moscow; 1988.
11. Lavrentyev AV. Microsurgical Revascularization of the Brain. Thesis; Moscow; 2000.
12. Tissen TP, Ermekov ZM, Muchnik MS. The results of a dynamic angiographic examination following the microsurgical revascularization of the brain. *Zh Vopr Neurokhir Im N N Burdenko* 1990;2:20-4.
13. Spetzler RF, Owen MP. Extracranial-intracranial arterial bypass to a single branch of the middle cerebral artery in the management of a traumatic aneurysm. *Neurosurgery* 1979;4:334-7.
14. Spetzler RF, Schuster H, Roski RA. Elective extracranial-intracranial arterial bypass in the treatment of inoperable giant aneurysms of the internal carotid artery. *J Neurosurg* 1980;53:22-7.
15. Amin-Hanjani S, Du X, Mlinarevich N, Meglio G, Zhao M, Charbel FT. The cut flow index: An intraoperative predictor of the success of extracranial-intracranial bypass for occlusive cerebrovascular disease. *Neurosurgery* 2005;56:75-85.
16. Nakagawa A, Fujimura M, Arafune T, Suzuki H, Sakuma I, Tominaga T. Intraoperative infrared brain surface blood flow monitoring during superficial temporal artery-middle cerebral artery anastomosis in a patient with moyamoya disease: Clinical implication of the gradation value in postoperative clinical course – A case report. *Acta Neurochir Suppl* 2008;102:159-63.
17. Lee M, Zaharchuk G, Guzman R, Achrol A, Bell-Stephens T,

- Steinberg GK. Quantitative hemodynamic studies in moyamoya disease: A review. *Neurosurg Focus* 2009;26:E5.
18. Dani KA, Thomas RG, Chappell FM, Shuler K, MacLeod MJ, Muir KW, *et al.* Computed tomography and magnetic resonance perfusion imaging in ischemic stroke: Definitions and thresholds. *Ann Neurol* 2011;70:384-401.
 19. Ho SS, Chan YL, Yeung DK, Metreweli C. Blood flow volume quantification of cerebral ischemia: Comparison of three noninvasive imaging techniques of carotid and vertebral arteries. *AJR Am J Roentgenol* 2002;178:551-6.
 20. Ogasawara K, Yukawa H, Kobayashi M, Mikami C, Konno H, Terasaki K, *et al.* Prediction and monitoring of cerebral hyperperfusion after carotid endarterectomy by using single-photon emission computerized tomography scanning. *J Neurosurg* 2003;99:504-10.
 21. Ogasawara K, Sakai N, Kuroiwa T, Hosoda K, Iihara K, Toyoda K, *et al.* Intracranial hemorrhage associated with cerebral hyperperfusion syndrome following carotid endarterectomy and carotid artery stenting: Retrospective review of 4494 patients. *J Neurosurg* 2007;107:1130-6.
 22. Muroi C, Khan N, Bellut D, Fujioka M, Yonekawa Y. Extracranial-intracranial bypass in atherosclerotic cerebrovascular disease: Report of a single centre experience. *Br J Neurosurg* 2011;25:357-62.
 23. Fujimura M, Mugikura S, Kaneta T, Shimizu H, Tominaga T. Incidence and risk factors for symptomatic cerebral hyperperfusion after superficial temporal artery-middle cerebral artery anastomosis in patients with moyamoya disease. *Surg Neurol* 2009;71:442-7.
 24. Higashi S, Matsuda H, Fujii H, Ito H, Yamashita J. Luxury perfusion syndrome confirmed by sequential studies of regional cerebral blood flow and volume after extracranial to intracranial bypass surgery: Case report. *Neurosurgery* 1989;25:85-9.
 25. Kawamata T, Kawashima A, Yamaguchi K, Hori T, Okada Y. Usefulness of intraoperative laser Doppler flowmetry and thermography to predict a risk of postoperative hyperperfusion after superficial temporal artery-middle cerebral artery bypass for moyamoya disease. *Neurosurg Rev* 2011;34:355-62.
 26. Gesang DZ, Zhang D, Zhao JZ, Wang S, Zhao YL, Wang R, *et al.* Laser Doppler flowmeter study on regional cerebral blood flow in early stage after standard superficial temporal artery-middle cerebral artery bypass surgery for moyamoya disease. *Chin Med J (Engl)* 2009;122:2412-8.
 27. Okada Y, Kawamata T, Kawashima A, Hori T. Intraoperative application of thermography in extracranial-intracranial bypass surgery. *Neurosurgery* 2007;60:362-5.