

# Increased Surveillance or Increased Scrutiny: Curbing Inappropriate Screening of Endometrial Cancer in Transgender Men

Edy C. Adams; B.Sc.<sup>1</sup>, Thomas C. Varkey; MBA<sup>1,2</sup>, Afaf Aijaz; B.Sc.<sup>3</sup>,  
Jorge Taboada; M.D.<sup>1</sup>, Anne M. Nguyen; B.Sc.<sup>1</sup>

1 Department of Radiology, Dell Medical School, The University of Texas at Austin, Austin, Texas

2 The Colangelo College of Business, Grand Canyon University, Phoenix, Arizona

3 Dow International Medical University, Karachi, Pakistan

Received March 2022; Revised and accepted July 2022

## Abstract

**Objective:** The transgender male body is often considered a “black box” by even the most senior of attending physicians. Because of the stigma and fear associated with the utilization of Hormone Replacement Therapy (HRT) and the lack of clinical knowledge surrounding the subject, many transgender men will experience unnecessary testing for endometrial cancers.

**Materials and methods:** This narrative review looked through publicly available PubMed and GoogleScholar articles on the topic of the use of pelvic ultrasounds in gynecological screening in transgendered males. 18,000 articles were filtered by relevance, date, clarity of the topic, and clinical recommendations. Of these articles 37 were included for discussion.

**Results:** Of these 18,000 articles, only 37 were included for discussion. The resulting table, diagnostic tree, and discussion section are included within.

**Conclusion:** Herein, the authors discuss the current understanding of the role of imaging in the diagnosis and treatment of gynecological cancers in transgendered men and how unnecessary imaging studies can be curbed for the benefit of the patient and the medical system at large.

**Keywords:** Evidence Based Imaging; Transgendered Man; Cancer Screening; Transvaginal Ultrasound; Pelvic Ultrasound; Diagnostic Tree; Value Based Care

## Introduction

While clear guidelines have been established for the role of imaging in screening transgender male patients for breast cancer, no such unified guidelines exist for the screening of endometrial cancers (1). While routine screening for endometrial cancer in any

asymptomatic individuals with average risk is not recommended, historical misunderstandings about the effects of hormone replacement therapy have promoted unnecessary and invasive screenings in transgender men. Herein, the authors review the current literature on endometrial cancer in transgender patients, provide a diagnostic tree for the outpatient provider for screening purposes, and conclude with some general recommendations based on the currently available evidence in the literature.

## Correspondence:

Thomas C. Varkey

Email: [tvarkey@utexas.edu](mailto:tvarkey@utexas.edu)



Copyright © 2022 Tehran University of Medical Sciences. Published by Tehran University of Medical Sciences.

This work is licensed under a Creative Commons Attribution-NonCommercial 4.0 International license (<https://creativecommons.org/licenses/by-nc/4.0/>).

Noncommercial uses of the work are permitted, provided the original work is properly cited.

## Materials and methods

This narrative review looked through publicly available PubMed and GoogleScholar articles on the topic of the use of pelvic ultrasounds in gynecological screening in transgender patients. 18,000 articles were filtered by relevance, date, clarity of the topic, and clinical recommendations. Any articles not written in English, not relevant to the topic of transgender patients or found to be lacking in clinical recommendation for the imaging of these patients for pelvic conditions were excluded. Key details and recommendations were then collated and reviewed by three independent researchers, any disagreements were resolved through discussion and consensus.

## Results

Of these 18,000 articles, only 37 were included for discussion based on the relevance to the topic of pelvic ultrasonography and the transgender patients. Most of the articles were excluded for the reason of a lack of relevance or discussion of other groups not pertaining to the transgender patients. The resulting table, diagnostic tree, and discussion section are included below.

## Discussion

Hormone replacement therapy (HRT) is generally regarded as a safe and effective way for transgender and gender-diverse patients to enhance desired secondary sex characteristics, while reducing those characteristics that contribute to gender dysphoria (2, 3). While each patient’s personal gender expression is different, common HRT treatment goals

for patients who are assigned female at birth (AFAB) include increased facial and body hair, changes in muscle and body fat composition, deeper voice, and cessation of menses (2). A full list of changes to the body of the patient is presented in Table 1. Persistent amenorrhea is often the benchmark at which testosterone levels are considered “physiologically male,” as serum testosterone values do not always directly correlate with the degree or rate of virilization achieved (2, 4-6).

While similar in many ways to the menopause experienced by cisgender women, the amenorrhea induced by exogenous testosterone administration is a unique physiologic process that has yet to be fully delineated. Theoretical concerns around the possibility of a testosterone-induced anovulatory state and subsequent “unopposed” estrogen production by the aromatization of free testosterone have led to the false assumption that testosterone HRT increases the risk of breast, endometrial, and ovarian cancer in transgender men (4). In the past, studies have suggested that transgender men were more likely to possess polycystic ovaries, even without a history of testosterone usage (9, 10). Routine histologic evaluations of ovaries taken from transgender men during gender-affirming oophorectomy have shown thecal and cortical hyperplasia similar to that seen in Polycystic Ovarian Syndrome (PCOS), and increased incidence of polycystic appearance (11,12). The Rotterdam criteria for diagnosing PCOS states that 2 of 3 of the following findings must be present: at least one polycystic ovary identified on transvaginal US, oligomenorrhea, and clinical or biochemical evidence of hyperandrogenism (13).

**Table 1:** Testosterone-Induced Changes in AFAB Patients

Bodily System	Change Experienced with the Use of Hormone Replacement Therapy	Timeframe from the Start of Hormone Replacement Therapy to see Some Effect	Timeframe from the Start of Hormone Replacement Therapy to see Maximum Effect
Reproductive Tract	Cessation of Menses	Two to Six Months	Two to Six Months
External Genitalia	Enlargement of the glans clitoris and atrophy of the vaginal tissues	Three to Twelve Months	Twelve to Twenty-Four Months (One to Two Years)
Adipose Tissue	Redistribution of body fat	Three to Six Months	Twenty-Four to Sixty Months (Two to Five Years)
Cardiovascular	Increase in the hematocrit within circulation.	Within Days	Around Six Months
Musculoskeletal	Increase in the patient’s muscular mass and distribution of the musculature.	Six Months to One year	One to Two Years
Musculoskeletal	Increase in the patient’s bone density	Six Months to One year	One to Two Years
Larynx	Increase in the anterior-posterior size of the larynx leading to a “deepening” of the voice	Three to Twelve Months	Twelve to Twenty-Four Months

Polycystic ovaries alone do not confer PCOS, but it was assumed that the intentional administration of exogenous testosterone to suppress menses satisfied the other criteria. However, more recent research confirms that exogenous testosterone administration in transgender men does not induce PCOS (14). Furthermore, data shows that while PCOS does increase the likelihood of developing endometrial cancer, there is currently no evidence to suggest an increased risk of breast and ovarian cancer secondary to this disorder (15, 16). While screening guidelines for cisgender women have been appropriately updated, considerations for transgender men have lagged, leaving patients open to the potential harms of inappropriate imaging. As written in a recent publication in the *Cureus Journal of Medicine*, no medical testing, treatment, or intervention is without its risks and effects on the entire bodily system (17). Many, if not all imaging studies are costly, and if there is a low chance that imaging results will change the management of a patient's medical care, these studies serve only to raise the cost of the patient's treatment without increasing the value received from that medical care (17).

### **Endometrial Cancer Screening**

Endometrial cancer is the most common gynecologic cancer in the United States and is most often diagnosed in post-menopausal patients (18). It is directly related to long-term exposure to excess estrogen levels, but the vast majority of cancers are diagnosed in early, treatable stages when patients present with abnormal vaginal bleeding. Excessive or prolonged vaginal bleeding in pre/perimenopausal people or any amount of vaginal bleeding in post-menopausal people is the hallmark symptom of endometrial hyperplasia and cancer. Endometrial hyperplasia is considered a precursor lesion and can often be seen on a transvaginal ultrasound as part of the workup for abnormal vaginal bleeding (19). Nevertheless, tissue biopsy, as referred to in the classic statement "tissue is the issue", is required to confirm the diagnosis (19). While some transgender men may experience persistent vaginal bleeding for several months after initiating testosterone HRT, most patients will experience amenorrhea in 6 months of initiating therapy, and virtually all bleeding resolves within 12 months of starting HRT (20). Breakthrough bleeding after this time frame is possible but is most likely a reflection of inaccurate or missed dosing, as both sub- and supraphysiologic levels of testosterone can result in abnormal vaginal

bleeding (20, 21). It is principal to note that changes in body habitus can affect the dose needed to achieve physiologic levels, as people with more adipose tissue have both higher endogenous estrogen levels and increased peripheral aromatization of testosterone to estradiol (22). There are no current guidelines for the appropriateness of transvaginal US in evaluating abnormal vaginal bleeding in transgender men on HRT. Previous guidelines from the Endocrine Society suggested annual screening transvaginal ultrasounds for all amenorrheic transgender men with intact uteri, but there is no evidence that screening any patients with uteri for endometrial cancer leads to a decrease in mortality, and this practice risks false-positives and overtreatment (19, 23). The current UCSF Transgender Care and Treatment Guidelines state that, in the absence of missed or changed testosterone dosing, vaginal bleeding in transgender men with testosterone-induced amenorrhea should be evaluated (23). Long-term testosterone use at appropriate dosing has not been shown to increase endometrial proliferation in transgender men (13). One retrospective case-series study suggests testosterone HRT may even have a slightly protective effect due to endometrial atrophy, but further investigation is needed to fully characterize this claim (24). With these findings in mind, it is the authorial team's highest recommendation that in transgender men with otherwise average cancer risk, transvaginal ultrasound should only be utilized in the assessment of persistent vaginal bleeding if:

- Patient has consistently been using testosterone HRT for at least 12 months
- Patient had previously achieved persistent amenorrhea on HRT
- Bleeding does not resolve with adjustments to HRT dose or frequency of administration

### **Costs of Inappropriate Screening**

While transvaginal US has no radiation exposure and is a relatively low-cost test for insured patients, it is an invasive exam that comes with a high risk of negative psychological effects in transgender men. Transgender patients face higher rates of unemployment, poverty, and homelessness than their non-transgender peers and are more likely to be uninsured (25). With the national average price of a transvaginal ultrasound estimated between \$89 and \$142 for insured patients, this is not an insignificant cost to the patient or the healthcare system (26). Furthermore, according to the most recent US Transgender Survey (2015) one-third of respondents

indicated they had at least one negative experience with a healthcare provider within the past year, including verbal harassment, refusal of treatment, or having to educate their provider on transgender identity and their own medical needs. One-quarter of respondents indicated that they declined to seek medical treatment within the last year out of fear of mistreatment by providers (27). Transgender men face unique challenges navigating the strongly gendered world of “women’s health,” where they are often met with confusion, invalidation, and even hostility. While transgender men are at increased risk of HPV infection, they are far more likely than cisgender women to have never received Pap testing due to a mix of prohibitive cost and psychological distress that leads them to avoid screening (28, 29). Limiting transvaginal ultrasound evaluation to only persistently symptomatic patients who have not responded to adjustments in HRT is a concrete step that can be made toward reducing the financial and emotional costs of healthcare for transgender men. Included is a diagnostic tree for improving decision making in the outpatient setting (Figure 1).

#### **Patient-Centered Care**

One of the most important pieces of the treatment and care of transgender men is building a strong rapport with the patient. Like with all patients, this can be partially accomplished through explaining the steps that are being taken to ensure that the patient has an understanding of why the provider is ordering the imaging study or not, what the potential risks or benefit are to either ordering the testing or not, and finally what are warning signs that the patient should look for which would warrant further examination. However, special consideration should be taken when discussing anatomy, symptoms, and procedures that could potentially exacerbate gender dysphoria or trauma with transgender patients. Avoid gendering body parts (ex: “female organs” to refer to uterus and ovaries) and use the patient’s preferred terminology whenever possible to discuss their anatomy (ex: some transmen prefer the term “chest tissue” instead of “breasts”). Transgender patients are also more likely to be survivors of sexual violence, and the risk of re-

traumatization should always be assessed against the potential benefits of invasive exams and procedures during clinical decision making (30). Through providing this dialogue early with the patient, ensuring that they have the necessary information to advocate for their own care, and then opening the space for the patient to ask questions regarding the clinical decision that was made - not only is the patient more likely to trust the physician, but compliance with medications and treatment also increases (31-33).

#### **Conclusion**

This article examined the current understanding of the role of imaging in the diagnosis and treatment of gynecological cancers in transgendered men and exhibited how unnecessary imaging studies can be curbed for the benefit of the patient and the medical system at large. As explained in the patient centered care section, through ensuring that patients are treated as humans first and foremost, clinicians will be able to provide the necessary care and compassion for the benefit of the overall patient’s health leading to increased compliance and trust from the patient. Further research into the risk ratios and the cost-benefit analysis of implementing less screenings for transgender patients and the resulting health outcomes on a longitudinal cohort remain necessary. It is the highest recommendation of the authorial team that this be conducted relatively soon. It is the highest desire of the authorial team that the care of the patient (financially, emotionally, and physically) be considered to guarantee that they are provided for holistically. As the famous father of modern medicine is quoted as saying, “The good physician treats the disease; the great physician treats the patient who has the disease” (34).

#### **Conflict of Interests**

Authors have no conflict of interests.

#### **Acknowledgments**

The Authorial team would like to acknowledge Dr. Aliza Norwood for her dedication to the care of all patients and their specific needs.

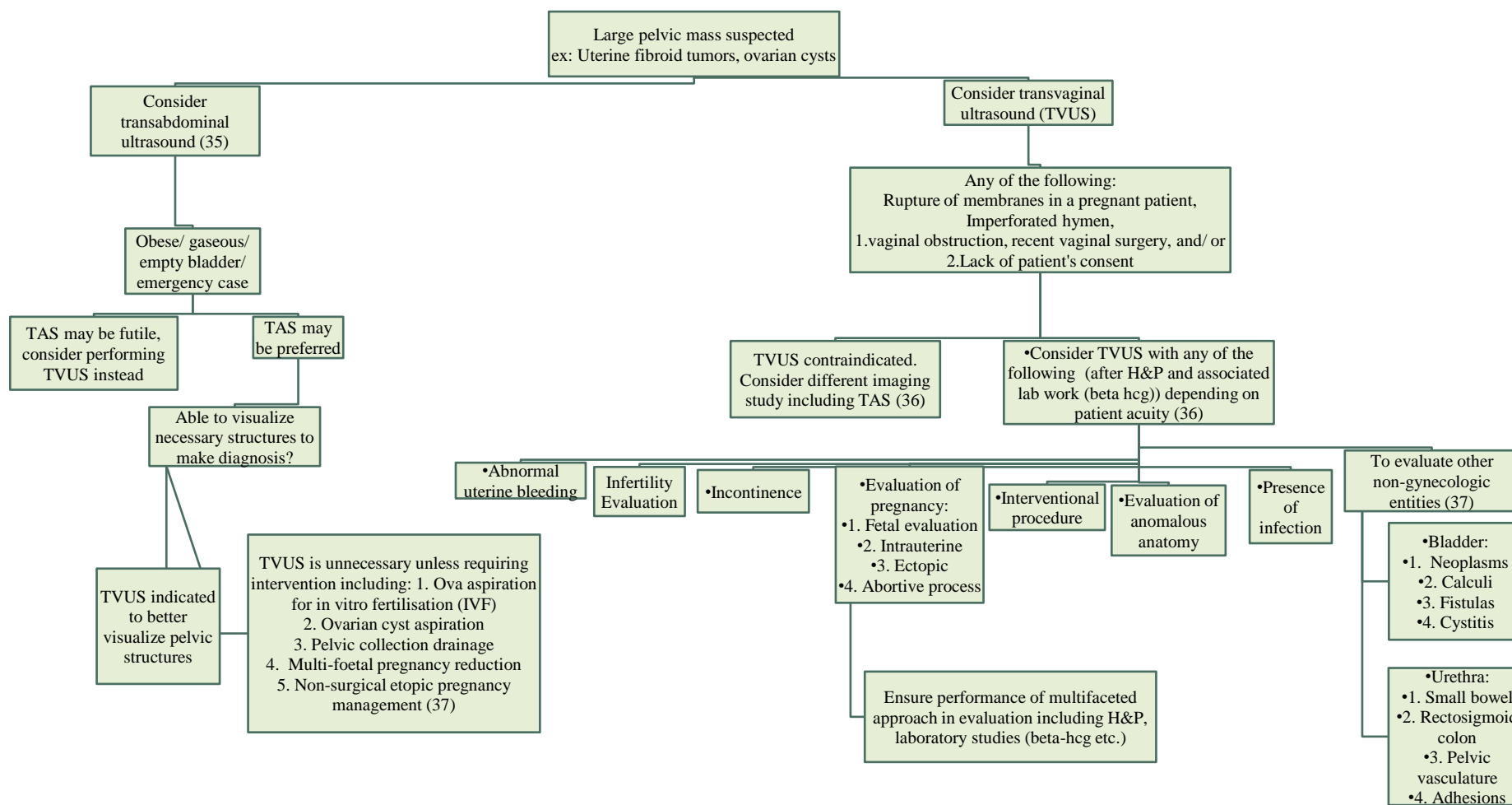


Figure 1. This is a new diagnostic decision tree for pelvic US based on currently available resources (35-37).

## References

1. Coleman E, Bockting W, Botzer M, Cohen-Kettenis P, DeCuypere G, Feldman J, Fraser L, Green J, Knudson G, Meyer W J, Monstrey S, Adler RK, Brown GR, Devor AH, Ehrbar R, Ettner R, Eyster E, Garofalo R, Karasic DH, Lev AI, Mayer G, Meyer-Bahlburg H, Hall BP, Pfaefflin F, Rachlin K, Robinson B, Schechter LS, Tangpricha V, van Trotsenburg M, Vitale A, Winter S, Whittle S, Wylie KR, Zucker K. Standards of Care for the Health of Transsexual, Transgender, and Gender-Nonconforming People, Version 7, Inter Journal of Transgenderism 2012; 13:4, 165-232.
2. Unger CA. Hormone therapy for transgender patients. *Transl Androl Urol.* 2016 Dec;5(6):877-884.
3. Hembree WC, Cohen-Kettenis P, Delemarre-van de Waal HA, Gooren LJ, Meyer WJ 3rd, Spack NP, Tangpricha V, Montori VM; Endocrine Society. Endocrine treatment of transsexual persons: An Endocrine Society clinical practice guideline. *J Clin Endocrinol Metab.* 2009 Sep;94(9):3132-54.
4. University of California San Francisco's Gender Affirming Health Program, Overview of masculinizing hormone therapy. <https://transcare.ucsf.edu/guidelines/masculinizing-therapy> (Accessed 09 June 2022).
5. Olson J, Schrage SM, Clark LF, Dunlap SL, Belzer M. Subcutaneous Testosterone: An Effective Delivery Mechanism for Masculinizing Young Transgender Men. *LGBT Health.* 2014 Sep;1(3):165-7.
6. Carswell JM, Roberts SA. Induction and Maintenance of Amenorrhea in Transmasculine and Nonbinary Adolescents. *Transgend Health.* 2017 Nov 1;2(1):195-201.
7. Turner A, Chen TC, Barber TW, Malabanan AO, Holick MF, Tangpricha V. Testosterone increases bone mineral density in female-to-male transsexuals: a case series of 15 subjects. *Clin Endocrinol (Oxf).* 2004 Nov;61(5):560-6.
8. Defreyne J, Vantomme B, Van Caenegem E, Wierckx K, De Blok CJM, Klaver M, Nota NM, Van Dijk D, Wiepjes CM, Den Heijer M, T'Sjoen G. Prospective evaluation of hematocrit in gender-affirming hormone treatment: results from European Network for the Investigation of Gender Incongruence. *Andrology.* 2018 May;6(3):446-454.
9. Baba T, Endo T, Honnma H, Kitajima Y, Hayashi T, Ikeda H, Masumori N, Kamiya H, Moriwaka O, Saito T. Association between polycystic ovary syndrome and female-to-male transsexuality. *Hum Reprod.* 2007 Apr;22(4):1011-6.
10. Bosinski HA, Peter M, Bonatz G, Arndt R, Heidenreich M, Sippell WG, Wille R. A higher rate of hyperandrogenic disorders in female-to-male transsexuals. *Psychoneuroendocrinology.* 1997 Jul;22(5):361-80.
11. Loverro G, Resta L, Dellino M, Edoardo DN, Cascarano MA, Loverro M, Mastrolia SA. Uterine and ovarian changes during testosterone administration in young female-to-male transsexuals. *Taiwan J Obstet Gynecol.* 2016 Oct;55(5):686-691.
12. Grimstad FW, Fowler KG, New EP, Ferrando CA, Pollard RR, Chapman G, Gray M, Gomez Lobo V. Ovarian Histopathology in Transmasculine Persons on Testosterone: A Multicenter Case Series. *J Sex Med.* 2020 Sep;17(9):1807-1818.
13. Williams T, Mortada R, Porter S. Diagnosis and Treatment of Polycystic Ovary Syndrome. *Am Fam Physician.* 2016 Jul 15;94(2):106-13.
14. Ikeda K, Baba T, Noguchi H, Nagasawa K, Endo T, Kiya T, Saito T. Excessive androgen exposure in female-to-male transsexual persons of reproductive age induces hyperplasia of the ovarian cortex and stroma but not polycystic ovary morphology. *Hum Reprod.* 2013 Feb;28(2):453-61.
15. Yin W, Falconer H, Yin L, Xu L, Ye W. Association Between Polycystic Ovary Syndrome and Cancer Risk. *JAMA Oncol.* 2019 Jan 1;5(1):106-107.
16. Barry JA, Azizia MM, Hardiman PJ. Risk of endometrial, ovarian and breast cancer in women with polycystic ovary syndrome: a systematic review and meta-analysis. *Hum Reprod Update.* 2014 Sep-Oct;20(5):748-58.
17. Siu VJ, Varkey T, Khan UN, Ding JB, Gandhi S. Lend Me a Hand: A Value-Based Care Case Study on Pan Plexopathy of Unknown Origin. *Cureus.* 2021 Dec 12;13(12): e20354.
18. Trabert B, Wentzensen N, Felix AS, Yang HP, Sherman ME, Brinton LA. Metabolic syndrome and risk of endometrial cancer in the United States: a study in the SEER-medicare linked database. *Cancer Epidemiol Biomarkers Prev.* 2015 Jan;24(1):261-7.
19. National Cancer Institute, PDQ Endometrial Cancer Screening. <https://www.cancer.gov/types/uterine/hp/endometrial-screening-pdq>, 2022 (Accessed 09 June 2022).
20. Defreyne J, Vanwonderghem Y, Collet S, Iwamoto SJ, Wiepjes CM, Fisher AD, et al. Vaginal bleeding and spotting in transgender men after initiation of testosterone therapy: A prospective cohort study (ENIGI). *Int J Transgend Health.* 2020 Feb 12;21(2):163-175.
21. Carswell JM, Roberts SA. Induction and Maintenance of Amenorrhea in Transmasculine and Nonbinary Adolescents. *Transgend Health.* 2017 Nov 1;2(1):195-201.
22. University of California San Francisco's Gender Affirming Health Program, Pelvic pain and persistent menses in transgender men.

- <https://transcare.ucsf.edu/guidelines/pain-transmen>  
(Accessed 09 June 2022)
23. University of California San Francisco's Gender Affirming Health Program, Ovarian and endometrial cancer considerations in transgender men. <https://transcare.ucsf.edu/guidelines/ovarian-cancer>  
(Accessed 09 June 2022)
24. Hawkins M, Deutsch MB, Obedin-Maliver J, Stark B, Grubman J, Jacoby A, Jacoby VL. Endometrial findings among transgender and gender nonbinary people using testosterone at the time of gender-affirming hysterectomy. *Fertil Steril*. 2021 May;115(5):1312-1317.
25. Puechl AM, Russell K, Gray BA. Care and Cancer Screening of the Transgender Population. *J Womens Health (Larchmt)*. 2019 Jun;28(6):761-768.
26. Medicare Services, Procedure price lookup for outpatient services. <https://www.medicare.gov/procedure-price-lookup/cost/76830/>, 2022 (Accessed 09 June 2022)
27. James S, Herman J, Rankin S, Keisling M, Mottet L, Anafi MA. The report of the 2015 US transgender survey. National Center for Transgender Equality. Published online 2016. Accessed August 30, 2018. Available from: <https://transequality.org/sites/default/files/docs/usts/USTS-Full-Report-Dec17.pdf>
28. Peitzmeier SM, Khullar K, Reisner SL, Potter J. Pap test use is lower among female-to-male patients than non-transgender women. *Am J Prev Med*. 2014 Dec;47(6):808-12.
29. University of California San Francisco's Gender Affirming Health Program, Screening for cervical cancer in transgender men. <https://transcare.ucsf.edu/guidelines/cervical-cancer>  
(Accessed 12 February 2022)
30. McKinnish TR, Burgess C, Sloan CA. Trauma-informed care of sexual and gender minority patients. Cham: Springer International Publishing, 2022.
31. Robinson JH, Callister LC, Berry JA, Dearing KA. Patient-centered care and adherence: definitions and applications to improve outcomes. *J Am Acad Nurse Pract*. 2008 Dec;20(12):600-7.
32. Lowes R. Patient-centered care for better patient adherence. *Fam Pract Manag*. 1998 Mar;5(3):46-7, 51-4, 57.
33. Clay AM, Parsh B. Patient- and Family-Centered Care: It's Not Just for Pediatrics Anymore. *AMA J Ethics*. 2016 Jan 1;18(1):40-4.
34. Centor RM. To be a great physician, you must understand the whole story. *MedGenMed*. 2007 Mar 26;9(1):59.
35. Qureshi IA, Ullah H, Akram MH, Ashfaq S, Nayyar S. Transvaginal versus transabdominal sonography in the evaluation of pelvic pathology. *J Coll Physicians Surg Pak*. 2004 Jul;14(7):390-3.
36. Nahlawi S, Gari N. Sonography Transvaginal Assessment, Protocols, And Interpretation. In: *StatPearls*. Treasure Island: StatPearls Publishing; 2022.
37. Moorthy RS. Transvaginal sonography. *Med J Armed Forces India*. 2000 Jul;56(3):181-183.

**Citation:** Adams EC, Varkey TC, Aijaz A, Taboada J, Nguyen AM. **Increased Surveillance or Increased Scrutiny: Curbing Inappropriate Screening of Endometrial Cancer in Transgender Men.** *J Family Reprod Health* 2022; 16(3): 170-6.