

# Clinical Analysis of Patients Diagnosed with Cutaneous Sporotrichosis in China

Yunyan Zheng<sup>1,\*</sup>, Weiwei Shi<sup>1,2,\*</sup>, Huiying Wang<sup>1</sup>, Ruzhi Zhang<sup>3</sup>

<sup>1</sup>Department of Dermatology, The Third Affiliated Hospital of Soochow University, Changzhou, People's Republic of China; <sup>2</sup>Department of Dermatology, Affiliated Hospital 2 of Nantong University, Nantong, People's Republic of China; <sup>3</sup>Department of Dermatology, The Second Affiliated Hospital of Wannan Medical College, Wuhu, People's Republic of China

\*These authors contributed equally to this work

Correspondence: Ruzhi Zhang, Department of Dermatology, The Second Affiliated Hospital of Wannan Medical College, 10 Kangfu Road, Wuhu, 241000, People's Republic of China, Email zhangruzhi628@163.com

**Purpose:** This study aimed to improve the understanding of sporotrichosis by analyzing the epidemiological characteristics, clinical manifestations, mycological features, and pathological characteristics of the disease in eastern China.

**Methods:** Clinical data of 49 patients diagnosed with cutaneous sporotrichosis in dermatology clinics over a 20-year period were collected and analyzed retrospectively. The analysis included patient demographics, occupations, clinical types, lesion sites, misdiagnosis rates, laboratory investigations, treatment and outcomes.

**Results:** The study included 22 male and 27 female patients, with a mean age of 52.4 years. Farmers (42.86%) and manual workers (28.57%) had a higher risk of infection. The most common clinical types were lymphocutaneous (30.61%) and fixed (69.39%), predominantly affecting the face and upper limbs. Misdiagnosis as other infectious skin diseases occurred in 35 patients (71.43%). Fungal culture and histopathological examination were important diagnostic tools. Treatment with oral itraconazole for three months led to relief and regression of the skin lesions in most patients, although a few experienced recurrences.

**Conclusion:** Cutaneous sporotrichosis mainly affects individuals working in agriculture and manual labour, with lymphocutaneous and fixed types being the predominant clinical manifestations. The high misdiagnosis rate emphasizes the importance of early recognition, accurate diagnosis and standardized treatment for the prognosis and cure of sporotrichosis. Fungal culture and histopathological examination are essential for diagnosis, and oral itraconazole is an effective treatment option.

**Keywords:** sporotrichosis, cutaneous form, clinical analysis, epidemiology, misdiagnosis

## Introduction

Sporotrichosis is a chronic fungal infection caused by pathogenic species of *Sporothrix* that primarily affects the skin, subcutaneous tissues and adjacent lymphatic system.<sup>1</sup> The *Sporothrix schenckii* complex includes *S. schenckii sensu stricto*, *S. globosa*, *S. brasiliensis*, and *S. luriei*, each with distinct geographical distributions and transmission patterns.<sup>2</sup> In China, the incidence of sporotrichosis has increased significantly over the past decade, with *S. globosa* emerging as the dominant etiological agent.<sup>3,4</sup> Infection typically occurs by two primary routes: the classical route through handling plants, vegetation and soil, and the zoonotic route through contact with infected animals.<sup>5–7</sup> Cutaneous sporotrichosis can manifest as fixed, lymphocutaneous or disseminated forms, with clinical presentations varying depending on the host immune response and the specific species involved.<sup>8</sup>

Despite the rising incidence, initial screening methods still rely heavily on clinical judgment, resulting in relatively high rates of misdiagnosis and underdiagnosis. This highlights the need for a better understanding of the clinical manifestations and laboratory characteristics of the disease. This study aims to improve our understanding of sporotrichosis through a comprehensive retrospective analysis of 49 patients diagnosed with cutaneous sporotrichosis over a 20-year period. By examining the epidemiological characteristics, clinical presentations, mycological features and pathological characteristics of the disease, we aim to provide guidance to improve clinical diagnosis and management strategies.

## Methods

### Patients

Patients diagnosed with cutaneous sporotrichosis were selected from the Department of Dermatology at the Third Affiliated Hospital of Soochow University over a 20-year period (2003 to 2023). The inclusion criteria were: (1) outpatients and inpatients of our hospital, (2) patients diagnosed based on clinical manifestation, positive mycological culture and pathological changes, and (3) patients with available records in our hospital. This study was approved by the Ethics Committee of the Third Affiliated Hospital of Soochow University (Ethics No. 81673078–202006).

### Data Collection

Patient data collected included age, sex, occupation, trigger, disease course, lesion location and type, mycological culture results, histopathological examination results and treatment history. Analysis of these data provided insights into two main aspects of lesion types. First, the clinical type of sporotrichosis was classified into fixed, lymphocutaneous and disseminated cutaneous forms. Second, the morphology of the lesions varied significantly, appearing as erythema, maculopapular, plaques, nodules, cysts, verrucous hyperplasia, ulceration, and varying in the number of lesions.

Clinical specimens, including exudates, pus, crusts and tissue fragments from lesions, were incubated on Sabouraud's dextrose agar (SDA) at 25°C for 2 weeks, followed by slide culture. Cultures were then incubated for a further 4 weeks before being reported as negative or discarded.

### Statistical methods

Descriptive statistics were used to analyse the demographic and clinical characteristics of the patients. Continuous variables were expressed as mean  $\pm$  standard deviation, while categorical variables were expressed as frequencies and percentages.

## Results

### Clinical Information

The study included 22 men and 27 women (man/woman ratio: 1:1.2), ranging in age from 6 to 85 years (mean age: 52.4 years). Twenty-nine patients (59.18%) were over 50 years of age. The occupations of the patients included farmers (21 cases, 42.86%) and labourers (14 cases, 28.57%), such as builders, gardeners, canal workers and machinists. Twelve patients (24.49%) had a documented history of trauma: 7 cases of wood or plant stings, 4 cases of insect or animal bites and 1 case of spectacle frame injury. [Table 1](#) shows demographic information and detailed clinical data.

The lesions usually began as dark red micronodules and progressed to nodules, cysts or plaques, manifesting as ulceration, pyorrhoea and crusting ([Figure 1](#)). Thirty-five patients (71.43%) had previously been seen in departments such as surgery, ophthalmology, dermatology and otolaryngology, and had been misdiagnosed with conditions such as non-specific bacterial skin infections, subacute eczema, cutaneous tuberculosis, skin tumours, pyogenic granuloma, necrotizing pyoderma, scars, epidermal cysts or rosacea. Among these 35 patients, the interval between initial presentation and correct diagnosis ranged from 2 to 48 months, with a mean time to diagnosis of  $8.94 \pm 8.52$  months. [Table 2](#) summarises the misdiagnosis rates for these patients.

### Laboratory Investigations

Direct microscopy of clinical specimens from all 49 patients was negative. Fungal cultures on Sabouraud's dextrose agar (SDA) produced characteristic *Sporothrix* colonies within 4–5 days. These colonies were initially grayish-white, gradually darkening to gray-brown or dark brown, with a distinct central fold ([Figure 2A](#)). Microscopic examination revealed thin, branching, septate hyphae with daisy-like microconidia at the hyphal tips or sleeve-like conidia arranged along the hyphal sides ([Figure 2B](#)). All cultures were positive and identified as *Sporothrix* based on morphological characteristics. Histological examination, performed in 43 of 49 patients, showed mixed cell granulomas in 27 cases (62.79%), non-specific inflammatory cell infiltration in 6 cases (13.95%), pyogenic granulomas in 6 cases (13.95%) and tuberculous granulomas in 4 cases (9.30%) ([Figure 2C](#)). Notably, no asteroid bodies were observed in any of the samples.

**Table 1** Demographic and Clinical Data of 49 Patients

Characteristics		Number of Patients (%) n=49
Gender	Males (M)	22 (44.90)
	Females (F)	27 (55.10)
Age	$\bar{x} \pm s$ (min, max)	52.4±20.1 (6.85)
Occupations	Farmers	21 (42.86)
	Labourers	14 (28.57)
	Students	5 (10.20)
	Retiree	5 (10.20)
	Housewives	2 (4.08)
	Office workers	2 (4.08)
Season of Disease	Spring	10 (20.40)
	Summer	9 (18.37)
	Autumn	9 (18.37)
	Winter	21 (42.86)
Duration of Disease	M±Q (min, max)	3.0±4.0 (1.48)
	<3 months	14 (28.57)
	3–6 months	21 (42.86)
	6–9 months	9 (18.37)
	>9 months	5 (10.20)
History of skin trauma	Had a clear history of trauma	12 (24.49)
	Not remembered	21 (42.86)
	Denied	16 (32.65)
Clinical type	Lymphocutaneous form	15 (30.61)
	Fixed cutaneous form	34 (69.39)
Lesion site	Head	19 (38.78)
	Upper Limbs	28 (57.14)
	Lower Limbs	2 (4.08)

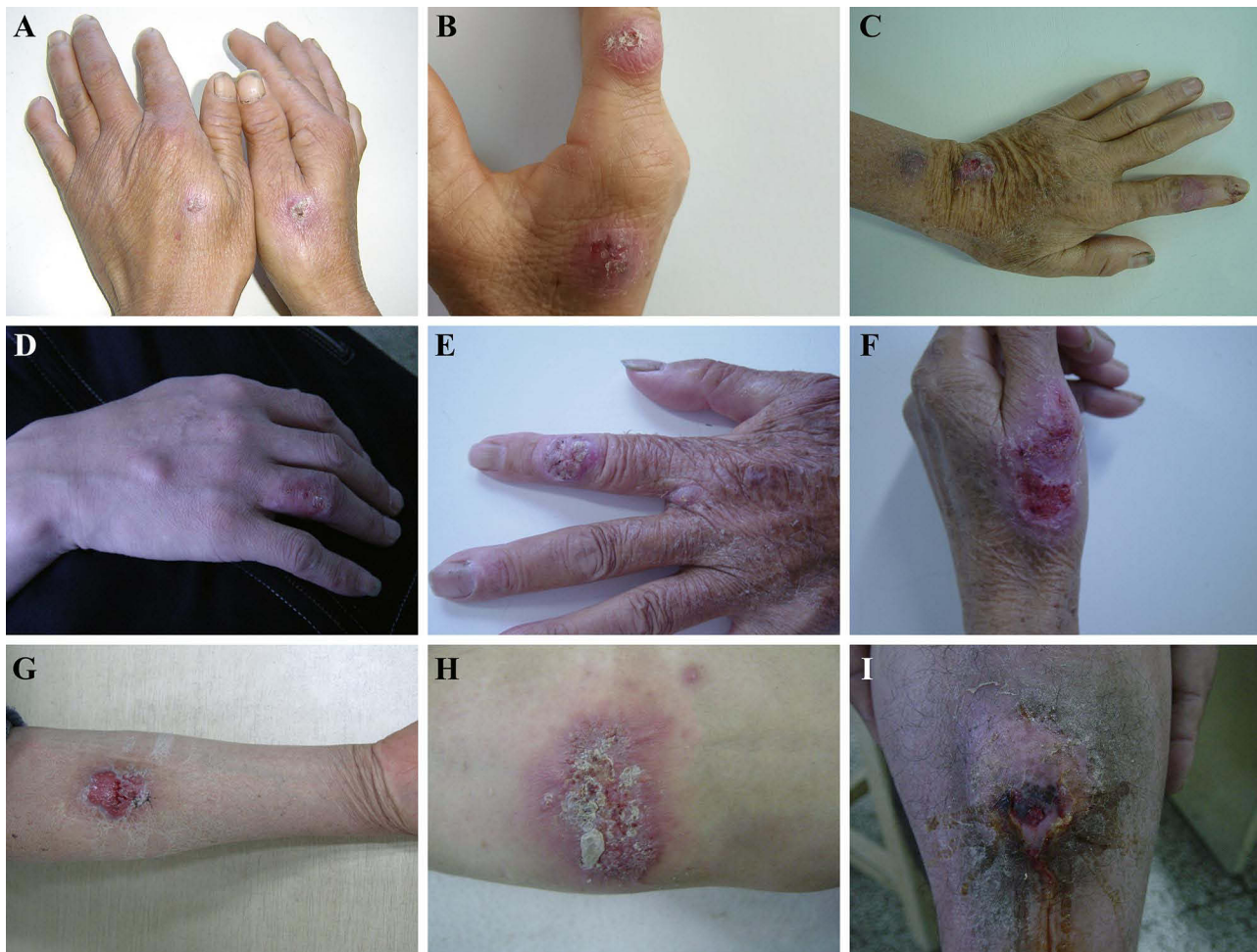Due to the definitive nature of the fungal culture results, which served as the primary diagnostic method, additional examinations such as PAS staining were not performed on these confirmed cases.

## Treatment and Outcome

All 49 patients underwent comprehensive hematological and biochemical tests prior to treatment, with results within normal ranges, indicating no contraindications to antifungal therapy. Patients received oral itraconazole at a dose of 200 mg daily for three months. During follow-up, 42 patients (85.7%) achieved complete remission without relapse (Figure 3). Three patients (6.1%) experienced a relapse at six months post-treatment due to non-adherence, but were successfully treated with a subsequent three-month course of itraconazole. One patient (2.0%) relapsed at 18 months, while six patients (12.2%) were lost to follow-up. No significant adverse events were reported throughout the study.

## Discussion

Our results indicate a higher prevalence of infection among middle-aged and older people who work in agriculture and manual labour, particularly in dark and humid environments that are conducive to fungal growth and spread. Importantly, 59.18% of our study population was over 50 years old, influenced by two main factors. Firstly, the persistence of traditional lifestyles may increase exposure to environmental pollutants and potential sources of infection.<sup>3</sup> Secondly, age-related declines in skin immune function may increase susceptibility to fungal infections. Although a history of trauma is an important factor in the development of sporotrichosis, it is not essential. The absence of a history of trauma does not rule out sporotrichosis; our study found that only 24.49% of patients had a documented history of trauma. Sources of trauma varied and included scratches from agricultural tools, plant scratches, and insect or animal bites.<sup>9,10</sup>



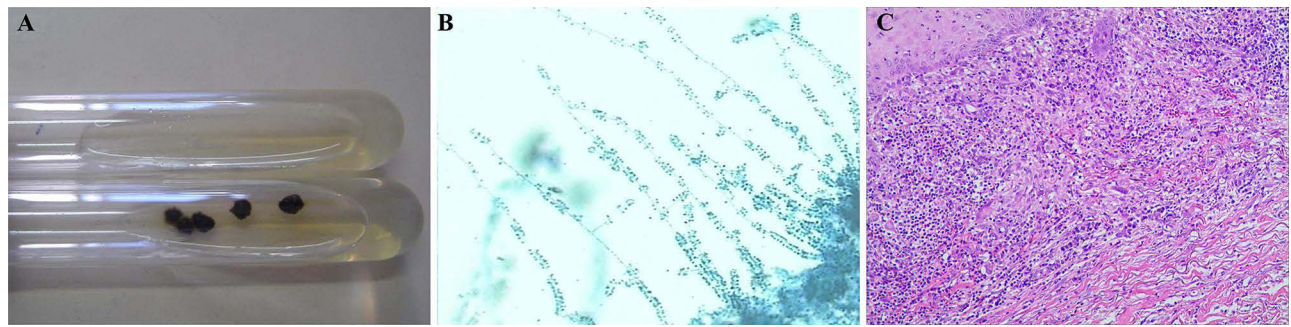
**Figure 1** Clinical manifestations of sporotrichosis in a patient. (A) Crusted plaques on the dorsum of both hands. (B) Crusted plaques on the dorsum of the hand. (C) Fluctuating nodules on the left upper extremity. (D) Solid nodules distributed along lymphatic vessels. (E) Verrucous nodule with scaling on the extensor aspect of the right finger. (F) Plaques with central erosions and crusted margins on the dorsum of the hand. (G) Plaques with slightly raised margins and central pitting. (H) Linear red maculopapular eruption with ulceration and thick crusts on the right upper extremity. (I) Infiltrative ulcer with crusting on the extensor aspect of the right lower extremity.

Many patients were unable to recall a specific trauma history, probably due to the several-month incubation period of *Sporothrix* or the potential for even minor abrasions to cause infection, leading to vague patient recall.

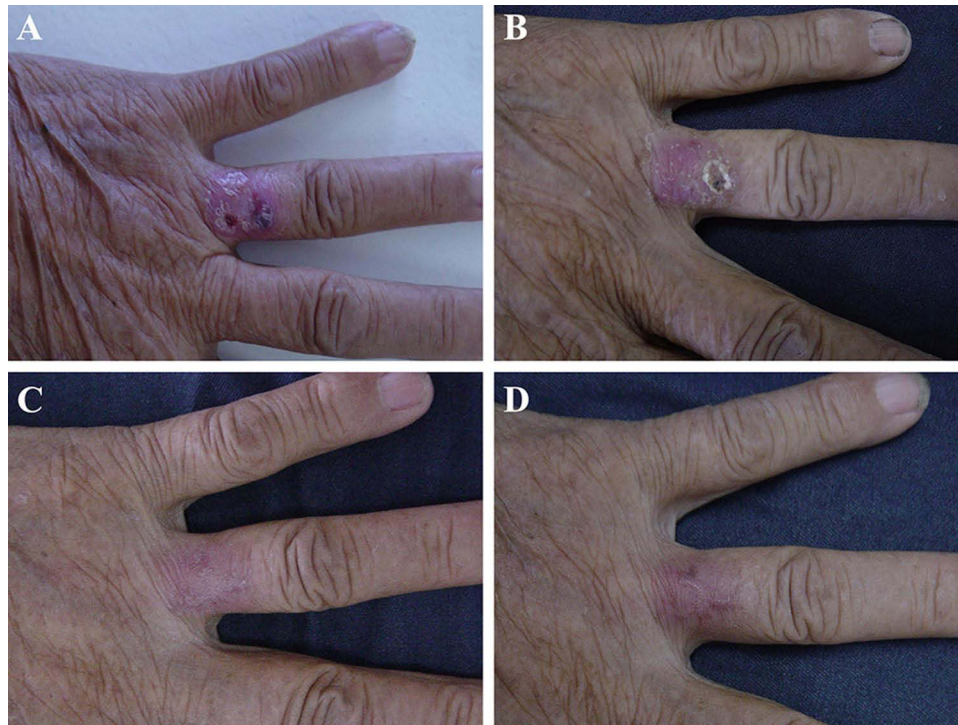
Cutaneous sporotrichosis poses a substantial diagnostic challenge due to its diverse clinical presentations. This complexity is especially evident in the fixed type, where lesions at the original site of infection have a variety of

**Table 2** Misdiagnosis Rates in the 35 Patients

Misdiagnosis	Number of Patients (%) n=35
Non-specific bacterial skin infection	11 (31.43)
Subacute eczema	6 (17.14)
Cutaneous tuberculosis	3 (8.57)
Cutaneous neoplasm	5 (14.29)
Suppurative granuloma	3 (8.57)
Pyoderma gangrenosum	2 (5.71)
Scar	2 (5.71)
Epidermoid cyst	2 (5.71)
Rosacea	1 (2.86)



**Figure 2** Results of laboratory tests. (A) Brown-black wrinkled colonies in mycological culture. (B) Conidiophores distributed on microconidiophore stalks. (C) Mixed cell infiltration (H&Ex100).



**Figure 3** Skin lesions before and after treatment. (A) Crusted plaque on finger. (B) Two weeks after treatment, a red plaque with residual crust. (C) Four weeks after treatment, a localized red patch. (D) Three months after treatment, a light red patch with slight palpable scarring.

morphologies. In the early stages, subjective symptoms are often absent, further delaying diagnosis. As the disease progresses, ulcers, nodules and verrucous lesions may mimic other conditions such as cutaneous tuberculosis, basal cell carcinoma and various bacterial or fungal infections.<sup>5,11,12</sup> The high misdiagnosis rate of 71.43% in our study highlights the significant diagnostic challenge. And common misdiagnoses included pyogenic granuloma, abscess, tumor, cutaneous tuberculosis and scar lump. These findings underscore the importance of considering sporotrichosis in the differential diagnoses, particularly in endemic regions. To improve diagnostic accuracy, we recommend maintaining a high index of suspicion for sporotrichosis when encountering treatment-resistant inflammatory papules, nodules, ulcers or verrucous lesions, especially in the absence of clear subjective symptoms. In addition, a thorough history, including occupational exposure and possible trauma, is essential for early recognition and appropriate management.

Direct microscopic examination of clinical specimens is often inconclusive due to low fungal counts. Diagnosis of sporotrichosis relies on fungal culture, which typically yields filamentous colonies within 4–5 days, ranging in colour from

cream to light brown and finally dark brown.<sup>5</sup> Microscopically, small conidiophores may show a cluster or sleeve-like arrangement of conidia. Despite its gold standard status, fungal culture has limitations in sensitivity and species identification. Advanced molecular biology techniques offer promising solutions to these challenges. Polymerase chain reaction (PCR) and peptide fingerprinting analysis, where available, can significantly improve diagnostic accuracy and allow precise species identification within the *Sporothrix* genus.<sup>13</sup> Implementation of such advanced techniques in clinical practice could revolutionize the management of sporotrichosis by allowing more rapid and targeted treatment strategies. In addition, histopathological examination plays a crucial role by providing valuable diagnostic clues.<sup>14,15</sup> Histopathological findings in patients with sporotrichosis typically show mixed purulent and granulomatous inflammatory reactions in the dermis.<sup>16,17</sup> However, non-specific inflammatory cell infiltrates are often observed, especially in specimens taken from early or peripheral lesions that have not fully developed.

Sporotrichosis, a deep fungal infection, can cause significant damage to dermal and subdermal tissues, potentially resulting in scarring. Early diagnosis and appropriate treatment are essential for optimal patient outcomes. Treatment options include systemic antifungals, heat therapy, cryotherapy, surgery and photodynamic therapy.<sup>18,19</sup> Combination therapy has also shown promise.<sup>20,21</sup> Itraconazole is the recommended first-line treatment, with alternative options such as terbinafine or potassium iodide, typically administered for 3 to 6 months or longer.<sup>22</sup> Our study demonstrated the efficacy of itraconazole, with 40 patients achieving complete resolution of skin lesions with regular and adequate treatment. However, 3 patients experienced relapse after 6 months due to non-compliance, highlighting the importance of adherence to prescribed regimens and regular follow-up.

This study has several limitations that need to be considered. The relatively small sample size (n=49) and single-center design may limit the comprehensive representation of clinical features of cutaneous sporotrichosis and introduce selection bias, potentially affecting the generalizability of the results. To address these limitations and improve our understanding of cutaneous sporotrichosis, future research should prioritize: (1) Conducting larger, multicenter prospective studies to improve data quality and representativeness. (2) Integrating molecular methods and additional histological techniques such as PAS staining for more precise species-level identification and potential discovery of additional histopathological features of infection. (3) Conducting comparative analyses of different treatment regimens to assess both efficacy and safety profiles.

## Conclusions

This retrospective study provides an insights into the epidemiological, clinical, mycological and pathological characteristics of cutaneous sporotrichosis. The findings underline the prevalence of the disease in agricultural and manual workers, presenting predominantly as lymphocutaneous and fixed types. The high misdiagnosis rate highlights the urgent need for increased awareness, early detection, accurate diagnosis and standardized treatment to improve patient outcomes. Fungal culture and histopathological examination are essential diagnostic tools, with oral itraconazole identified as an effective treatment option. However, the limitations of the study, including the small sample size and single-center design, warrant further research through larger, multicenter prospective studies to improve data quality and generalizability. Future research should also focus on improving techniques and comparing treatment regimens to improve the management and control of cutaneous sporotrichosis.

## Data Sharing Statement

The data supporting the findings of this study are available from the corresponding author on reasonable request.

## Ethics Declarations

This study was approved by the Ethics Committee of the Third Affiliated Hospital of Soochow University (Ethics No. 81673078-202006) and was conducted in accordance with the Helsinki Declaration of 1964 and its subsequent amendments or equivalent ethical standards. Written informed consent was obtained from each participant or their legal guardian.

## Author Contributions

All authors have made a substantial contribution to the work reported, be it in conception, design, conduct, acquisition of data, analysis and interpretation, or all of these; have been involved in drafting, revising, or critically reviewing the article; have given final approval for the version to be published; have agreed on the journal to which the article will be submitted; and agree to accept responsibility for all aspects of the work.

## Funding

There is no funding to report.

## Disclosure

Yunyan Zheng and Weiwei Shi are co-first authors for this work. The authors declare that they have no competing interests in this work.

## References

1. Rodrigues AM, Della Terra PP, Gremião ID, et al. The threat of emerging and re-emerging pathogenic *Sporothrix* species. *Mycopathologia*. 2020;185(5):813–842. doi:10.1007/s11046-020-00425-0
2. Marimon R, Gené J, Cano J, et al. Molecular phylogeny of *Sporothrix schenckii*. *J Clin Microbiol*. 2006;44(9):3251–3256. doi:10.1128/JCM.00081-06
3. Yao L, Song Y, Zhou JF, et al. Epidemiological and clinical comparisons of paediatric and adult sporotrichosis in Jilin Province, China. *Mycoses*. 2020;63(3):308–313. doi:10.1111/myc.13045
4. Yu X, Wan Z, Zhang Z, et al. Phenotypic and molecular identification of *Sporothrix* isolates of clinical origin in Northeast China. *Mycopathologia*. 2013;176(1–2):67–74. doi:10.1007/s11046-013-9668-6
5. Orofino-Costa R, Macedo PM, Rodrigues AM, et al. Sporotrichosis: an update on epidemiology, etiopathogenesis, laboratory and clinical therapeutics. *An Bras Dermatol*. 2017;92(5):606–620. doi:10.1590/abd1806-4841.2017279
6. Rodrigues AM, de Melo Teixeira M, de Hoog GS, et al. Phylogenetic analysis reveals a high prevalence of *Sporothrix brasiliensis* in feline sporotrichosis outbreaks. *PLoS Negl Trop Dis*. 2013;7(6):e2281. doi:10.1371/journal.pntd.0002281
7. Etchecopaz A, Toscanini MA, Gisbert A, et al. *Sporothrix brasiliensis*: a review of an emerging South American Fungal Pathogen, Its Related Disease, Presentation and Spread in Argentina. *J Fungi (Basel)*. 2021;7(3):170. doi:10.3390/jof7030170
8. Xia X, Zhi H, Liu Z. Cutaneous disseminated sporotrichosis associated with diabetes: a case report and literature review. *PLoS Negl Trop Dis*. 2023;17(9):e0011647. doi:10.1371/journal.pntd.0011647
9. Rodrigues AM, de Hoog GS, de Camargo ZP. Sporothrix species causing outbreaks in animals and humans driven by animal-animal transmission. *PLoS Pathog*. 2016;12(7):e1005638. doi:10.1371/journal.ppat.1005638
10. Yeow YY, Tan XT, Low LL. Mucosal sporotrichosis from zoonotic transmission: descriptions of four case reports. *Infect Dis Rep*. 2023;15(1):102–111. doi:10.3390/idr15010011
11. Queiroz-Telles F, Bonifaz A, Cognialli R, et al. Sporotrichosis in children: case series and narrative review. *Curr Fungal Infect Rep*. 2022;16(2):33–46. doi:10.1007/s12281-022-00429-x
12. Saeed L, Weber RJ, Puryear SB, et al. Disseminated cutaneous and osteoarticular sporotrichosis mimicking pyoderma gangrenosum. *Open Forum Infect Dis*. 2019;6(10):ofz395. doi:10.1093/ofid/ofz395
13. Rodrigues AM, Najafzadeh MJ, de Hoog GS, et al. Rapid identification of emerging human-pathogenic *Sporothrix* species with rolling circle amplification. *Front Microbiol*. 2015;6:1385. doi:10.3389/fmicb.2015.01385
14. Arenas R, Sánchez-Cardenas CD, Ramirez-Hobak L, et al. Sporotrichosis: from KOH to molecular biology. *J Fungi*. 2018;4(2):62. doi:10.3390/jof4020062
15. Rabello VBS, Almeida MA, Bernardes-Engemann AR, et al. The historical burden of sporotrichosis in Brazil: a systematic review of cases reported from 1907 to 2020. *Braz J Microbiol*. 2022;53(1):231–244. doi:10.1007/s42770-021-00658-1
16. Tai F, Jakubovic H, Alabdulrazzaq S, et al. A case of sporotrichosis infection mimicking pyoderma gangrenosum and the role of tissue culture in diagnosis: a case report. *SAGE Open Med Case Rep*. 2020;8:2050313X20919600. doi:10.1177/2050313X20919600
17. Sharma R, Mahajan VK, Singh Chauhan P, et al. The clinico-epidemiological characteristics and therapeutic experience of 152 patients with cutaneous sporotrichosis: a 10-year retrospective study from India. *Int J Dermatol*. 2021;60(1):99–106. doi:10.1111/ijd.15299
18. Fichman V, Do Valle ACF, Freitas DFS, et al. Cryosurgery for the treatment of cutaneous sporotrichosis: experience with 199 cases. *Br J Dermatol*. 2019;180(6):1541–1542. doi:10.1111/bjd.17532
19. Li J, Zhu M, An L, et al. Fungicidal efficacy of photodynamic therapy using methylene blue against *Sporothrix globosa* in vitro and in vivo. *Eur J Dermatol*. 2019;29(2):160–166. doi:10.1684/ejd.2019.3527
20. Takazawa M, Harada K, Kakurai M, et al. Case of pyoderma gangrenosum-like sporotrichosis caused by *Sporothrix globosa* in a patient with ulcerative colitis. *J Dermatol*. 2018;45(8):e226–e227. doi:10.1111/1346-8138.14276
21. Martínez-Herrera E, Arenas R, Hernández-Castro R, et al. Uncommon clinical presentations of sporotrichosis: a two-case report. *Pathogens*. 2021;10(10):1249. doi:10.3390/pathogens10101249
22. Zhu H, Xia X, Zhi H, et al. Retrospective analysis of 71 patients with cutaneous sporotrichosis. *Mycoses*. 2023;66(7):621–631. doi:10.1111/myc.13588

Infection and Drug Resistance

Dovepress

## Publish your work in this journal

Infection and Drug Resistance is an international, peer-reviewed open-access journal that focuses on the optimal treatment of infection (bacterial, fungal and viral) and the development and institution of preventive strategies to minimize the development and spread of resistance. The journal is specifically concerned with the epidemiology of antibiotic resistance and the mechanisms of resistance development and diffusion in both hospitals and the community. The manuscript management system is completely online and includes a very quick and fair peer-review system, which is all easy to use. Visit <http://www.dovepress.com/testimonials.php> to read real quotes from published authors.

Submit your manuscript here: <https://www.dovepress.com/infection-and-drug-resistance-journal>