

# Transcatheter coil embolization of iatrogenic coronary artery–left ventricle fistula after mitral valve replacement



Ata Firuzi <sup>a</sup>, Mohammad Javad Alemzadeh-Ansari <sup>a,\*</sup>, Hamid Reza Pouraliakbar <sup>b</sup>

<sup>a</sup> Cardiovascular Intervention Research Center, Rajaie Cardiovascular Medical and Research Center, Iran University of Medical Sciences, Tehran;

<sup>b</sup> Radiology Department, Rajaie Cardiovascular Medical and Research Center, Iran University of Medical Sciences, Tehran

<sup>a,b</sup> Iran

Acquired causes of coronary fistulas are rare disorders and may develop following coronary atherosclerosis, infection, or trauma (iatrogenic). Iatrogenic coronary fistulas may be acquired secondary to surgical or nonsurgical interventions. We describe a case of an iatrogenic coronary artery–left ventricle fistula following mitral valve replacement surgery, presented with ventricular arrhythmia and heart failure. In a unique technique, we implanted three coils with the aid of a Scepter C balloon with inflation at the ostial portion of the left circumflex artery.

© 2016 The Authors. Production and hosting by Elsevier B.V. on behalf of King Saud University. This is an open access article under the CC BY-NC-ND license (<http://creativecommons.org/licenses/by-nc-nd/4.0/>).

**Keywords:** Coil embolization, Coronary fistulas, Left circumflex artery

## Introduction

Coronary artery fistulas are congenital or acquired anastomoses through which blood bypasses the myocardial capillary network and is shunted into cardiac chambers or major thoracic vessels. The majority of coronary fistulas arise from the right coronary artery (RCA) or the left anterior descending artery, whereas the circumflex coronary artery is rarely involved [1]. These fistulas vary widely in their morphological appearances and presentations such as dyspnea,

heart failure, endocarditis, arrhythmias, and myocardial ischemia; nevertheless, about half of the cases may be asymptomatic and clinically undetectable [2]. While coronary artery fistulas are usually asymptomatic in younger patients, with increasing age, symptoms begin to appear and there may be a rise in the incidence of complications [3]. Acquired causes of coronary fistulas are rare disorders and may develop following coronary atherosclerosis, infection, or trauma (iatrogenic) [4–8]. Iatrogenic coronary fistulas may be acquired secondary to surgical or nonsurgical interventions [9]. Herein, we describe an

**Disclosure:** Authors have nothing to disclose with regard to commercial support.

Received 26 August 2016; revised 25 October 2016; accepted 31 October 2016.

Available online 9 November 2016

\* Corresponding author at: Cardiovascular Intervention Research Center, Rajaie Cardiovascular Medical and Research Center, Iran University of Medical Sciences, Tehran, Iran.

E-mail address: [mj.aansari@gmail.com](mailto:mj.aansari@gmail.com) (M.J. Alemzadeh-Ansari).



P.O. Box 2925 Riyadh – 11461KSA  
Tel: +966 1 2520088 ext 40151  
Fax: +966 1 2520718  
Email: [sha@sha.org.sa](mailto:sha@sha.org.sa)  
URL: [www.sha.org.sa](http://www.sha.org.sa)



1016–7315 © 2016 The Authors. Production and hosting by Elsevier B.V. on behalf of King Saud University. This is an open access article under the CC BY-NC-ND license (<http://creativecommons.org/licenses/by-nc-nd/4.0/>).

Peer review under responsibility of King Saud University.

URL: [www.ksu.edu.sa](http://www.ksu.edu.sa)

<http://dx.doi.org/10.1016/j.jsha.2016.10.009>



Production and hosting by Elsevier

unusual case presenting with heart failure and ventricular arrhythmia, which was treated with a unique approach of coil embolization.

### Case report

A 46-year-old woman was referred to our hospital for the device closure of an iatrogenic coronary artery-left ventricle fistula. She had undergone mitral valve replacement surgery 22 years earlier because of severe rheumatic mitral valve stenosis. Our review of the surgery report revealed that the mitral valve was replaced with a St. Jude 31 metallic prosthetic valve, but because of a tear in the left circumflex artery (LCx) during surgery, the proximal portion of the LCx was ligated and a saphenous vein graft was implanted on the obtuse marginal (OM) from the aorta.

The patient complained of chronic functional dyspnea (New York Heart Association Class II) and palpitation. She had experienced frequent episodes of lightheadedness about 2 weeks previously, but after a week referred to another hospital because of loss of consciousness. At presentation, she was treated with electrical cardioversion due to ventricular tachycardia. Further evaluation showed reduced systolic left ventricular ejection fraction (25%) and good prosthetic valve function. Laboratory examinations were unremarkable, but single-photon emission computed tomography revealed significant ischemia in the anterior region. So, the patient underwent coronary angiography, which illustrated a fistula from the proximal LCx to the left ventricular cavity. In addition, the saphenous vein graft was occluded, but the OM and the distal portion of the LCx were

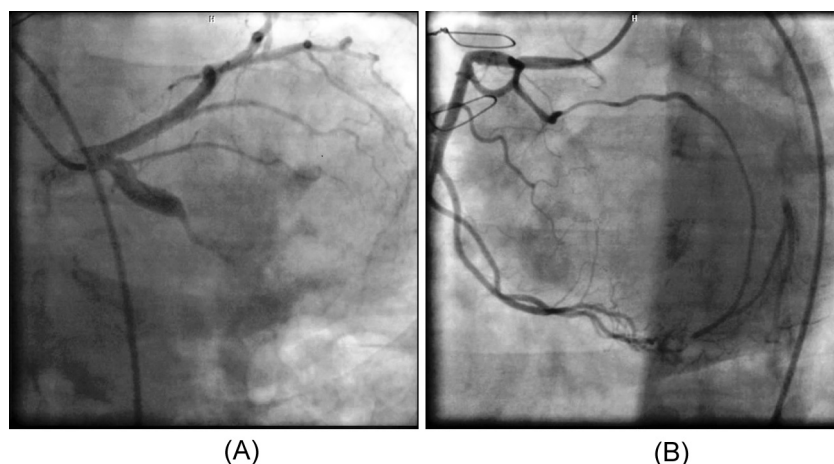


Figure 1. Selective coronary angiography shows a fistula between the proximal left circumflex artery and the left ventricular cavity after mitral valve replacement (A). Additionally, the distal portion of the left circumflex artery and the obtuse marginal is filled via the collaterals from the right coronary artery (B).

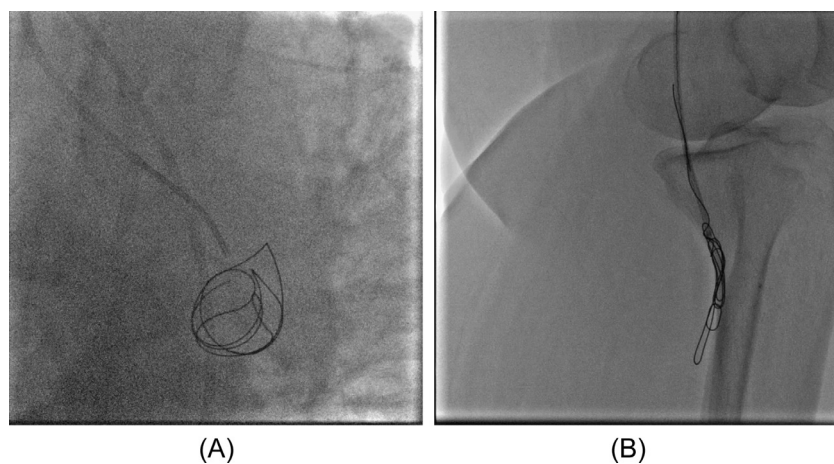


Figure 2. First, the coil immediately drops into the left ventricular cavity (A). The coil is, thereafter, snared at the level of the left popliteal artery (B).

filled retrogradely by a collateral branch from the RCA (Fig. 1). The patient refused redo-surgery; consequently, she was referred to our hospital for coil embolization at the proximal portion of the LCx.

The patient was transferred to the catheterization lab, where she underwent coronary intervention. Firstly, we tried to implant an Axium 3D Coils ev3, Covidien, USA (6 mm × 20 cm), but the coil dropped into the left ventricle (Fig. 2). We then sought to remove the coil from the left ventricle using a pigtail. After reaching the aorta, we succeeded in snaring the coil in the left popliteal artery (Fig. 2). Thereafter, we deployed a 4 mm × 15 mm Scepter C balloon (MicroVention-Terumo, USA) in the ostio-proximal portion of the LCx to decrease the blood flow toward the LCx (Fig. 3). This is an over-the-wire balloon catheter.

After removing the guide wire, the coils are introduced via the central lumen of the Scepter C balloon catheter while the balloon was inflated. Finally, we implanted three coils in the LCx (10 mm × 36 cm MicroPlex-10 (Microvention, Terumo), 7 mm × 20 cm Axium 3D (Covidien Axium), and 7 mm × 30 cm Axium Helix (Covidien, USA); Fig. 3).

Two days later, the patient underwent echocardiography, which showed significant improvement in left ventricular ejection fraction (reaching 40%). At 10 months' follow-up, she was asymptomatic and single-photon emission computed tomography demonstrated no ischemia in the anterior territory. Additionally, coronary computed tomography angiography illustrated no residual shunt from the LCx to the left ventricular cavity (Fig. 4).

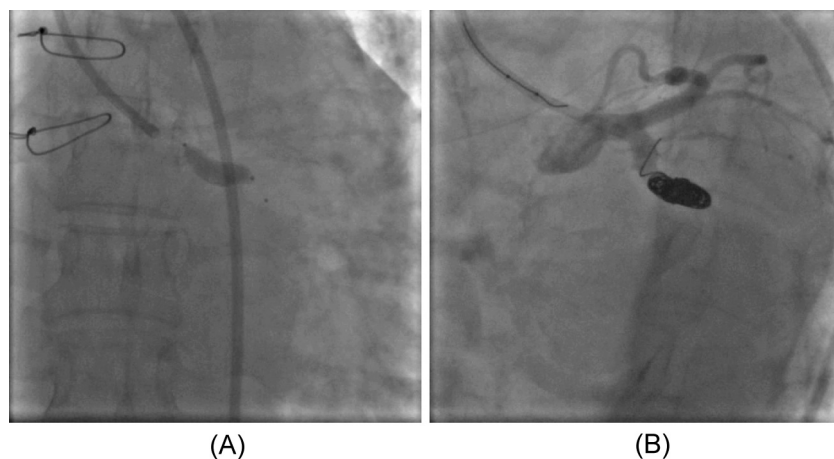


Figure 3. A 4 mm × 15 mm Scepter C balloon is deployed in the ostio-proximal portion of the left circumflex artery (LCx) to decrease the blood flow toward the LCx (A), and then three coils are implanted in the LCx (B).

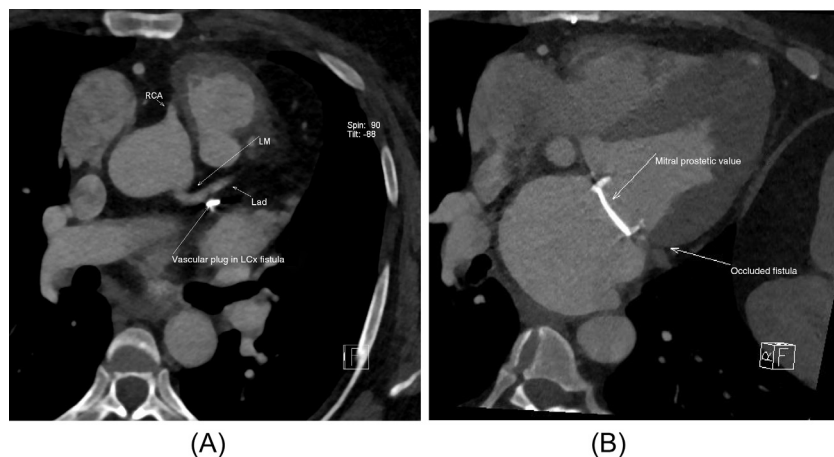


Figure 4. (A, B) At 10 months' follow-up, coronary computed tomography angiography illustrated no residual shunt from the left circumflex artery (LCx) to the left ventricular cavity. LAD = left anterior descending artery; LM = left main artery; RCA = right coronary artery.

## Discussion

Iatrogenic coronary fistulas in surgical procedures may develop secondary to septal myectomy, coronary artery bypass grafting, valvular replacement or repair, or correction of congenital anomalies [10–12]. They may also develop in some nonsurgical interventions such as endomyocardial biopsy, electrophysiological procedures, and percutaneous coronary interventions [13–17]. Because of the proximity of the LCx to the mitral valve annulus, this artery is more susceptible to either direct injury or distortion during mitral valve surgery [18].

For the first time, Danielson and colleagues [19] in 1967 described injury to the LCx following mitral valve surgery. Somekh and colleagues [20] described a patient who experienced early myocardial infarction secondary to the occlusion of the LCx following mitral valve repair. The authors described how percutaneous coronary intervention aimed at opening the LCx occlusion led to the development of a fistula from the coronary artery to the left atrium and explained that they performed redo-surgery to directly close the fistula. Barceló and colleagues [21] described an iatrogenic fistula from the left anterior descending artery to the right ventricle after mitral and aortic valve replacement. The authors closed the ostial part of the fistula with direct implantation of a polytetrafluoroethylene-coated stent. By contrast, in our patient, although the fistula developed directly after valvular surgery, the symptoms of heart failure and ventricular arrhythmia manifested themselves very late (22 years later). Interestingly, according to the existing literature, the majority of the cases having experienced iatrogenic fistulas from the coronary artery to the left ventricular cavity were asymptomatic. This may be because of spontaneous occlusion, especially in patients who experience coronary fistulas after surgical myectomy and in those with hypertrophic cardiomyopathy [9,22].

There is currently a paucity of data on the management of iatrogenic coronary fistulas. The limited number of available case reports are on the use of surgical closure [23] or percutaneous interventions such as the placement of a covered stent [21,24] and a detachable balloon [25] in symptomatic patients. In our literature review, we did not find any studies on the use of transcatheter coil embolization for the management of iatrogenic coronary fistulas. In our case, after the patient refused redo-surgery, we opted for percutaneous intervention to close the fistula. Because the fistula was between the proximal portion of

the LCx and the left ventricle and the distal portion of the LCx and the OM was filled by collaterals from the RCA, we scheduled the patient for coil embolization. In our first attempt, however, the coil (Axium 3D Coils ev3) immediately dropped into the left ventricular cavity—probably because of the high flow from the LCx to the left ventricle. As a result, in a unique technique, we implanted another three coils with the aid of a Scepter C balloon with inflation at the ostial portion of the LCx, which helped diminish the coronary flow. At follow-up, the patient was asymptomatic and coronary computed tomography angiography showed no residual shunt.

Although iatrogenic coronary artery fistulas constitute a rare condition that may be asymptomatic, in some cases, they may present with life-threatening conditions. We herein introduced a case of fistula from the LCx to the left ventricular cavity after mitral valve replacement that presented with very late heart failure and ventricular arrhythmia. Because of the patient's special coronary artery anatomy, we performed transcatheter coil embolization for the occlusion of the proximal portion of the LCx.

## References

- [1] Gowda RM, Vasavada BC, Khan IA. Coronary artery fistulas: clinical and therapeutic considerations. *Int J Cardiol* 2006;107:7–10.
- [2] Loukas M, Germain AS, Gabriel A, John A, Tubbs RS, Spicer D. Coronary artery fistula: a review. *Cardiovasc Pathol* 2015;24:141–8.
- [3] Mangukia CV. Coronary artery fistula. *Ann Thorac Surg* 2012;93:2084–92.
- [4] Ercan E, Tengiz I, Yakut N, Gurbuz A, Bozdemir H, Bozdemir G. Takayasu's arteritis with multiple fistulas from three coronary arteries to lung paranchima. *Int J Cardiol* 2003;88:319–20.
- [5] Bruschi G, Oreglia J, Colombo P, De Marco F, Frigerio M, Martinelli L, et al. Percutaneous iatrogenic coronary fistula closure in heart transplant recipient. *Asian Cardiovasc Thorac Ann* 2012;20:188–90.
- [6] Fanari Z, Thapa J, Barekain A, Copeland K, Hopkins JT. Iatrogenic aortocoronary arteriovenous fistula: percutaneous management of a surgical complication. *JACC Cardiovasc Interv* 2015;8:1124–5.
- [7] Bas A, Kandemirli SG, Gulsen F, Cantasdemir M, Numan F. Endovascular treatment of inadvertent left internal mammarian artery to great cardiac vein fistula. *Hellenic J Cardiol* 2016;57:138–40.
- [8] Said S, Werf TVD. Acquired coronary cameral fistulas: are these collaterals losing their destination? *Clin Cardiol* 1999;22:297–302.
- [9] Said SA, Schiphorst RH, Derksen R, Wagenaar LJ. Coronary-cameral fistulas in adults: acquired types (second of two parts). *World J Cardiol* 2013;5:484–94.
- [10] Chiu SN, Wu MH, Lin MT, Wu ET, Wang JK, Lue HC. Acquired coronary artery fistula after open heart surgery for congenital heart disease. *Int J Cardiol* 2005;103:187–92.
- [11] Nguyen-Do P, Bannon P, Leung DY. Coronary artery to the left atrial fistula after resection of atrial appendages. *Ann Thorac Surg* 2004;78:e26–7.

- [12] Renard VP, Vandenberg J. Fistula between the left internal thoracic artery and the coronary sinus. *N Engl J Med* 2000;343:149-50.
- [13] Härle T, Reimers J, Schaumann A. Coronary artery fistula caused by an endocardial active fixation ICD lead. *Europace* 2008;10:458.
- [14] Shalaby A, Refaat M, Lacomis JM, Amidi M. Iatrogenic coronary-cameral fistula after left ventricular radiofrequency ablation. *Heart Rhythm* 2009;6:720-1.
- [15] Park SH, Rha SW, Cho AR, Lee HG, Choi CU, Oh DJ. Successful management of iatrogenic coronary arteriovenous fistula developed during chronic total occlusion intervention. *J Cardiol Cases* 2012;6:e96-9.
- [16] Oh SW, Kim YJ, Lim JG, Choi WG. An iatrogenic coronary arteriovenous fistula caused by guidewire trauma during percutaneous coronary intervention. *Korean J Med* 2012;82:337-40.
- [17] Fitchett DH, Forbes C, Guerraty AJ. Repeated endomyocardial biopsy causing coronary arterial-right ventricular fistula after cardiac transplantation. *Am J Cardiol* 1988;62:829-31.
- [18] Grande AM, Fiore A, Massetti M, Viganò M. Iatrogenic circumflex coronary lesion in mitral valve surgery. *Tex Heart Inst J* 2008;35:179-83.
- [19] Danielson GK, Cooper E, Tweeddale DN. Circumflex coronary artery injury during mitral valve replacement. *Ann Thorac Surg* 1967;4:53-9.
- [20] Somekh NN, Haider A, Makaryus AN, Katz S, Bello S, Hartman A. Left circumflex coronary artery occlusion after mitral valve annuloplasty: "a stitch in time". *Tex Heart Inst J* 2012;39:104-7.
- [21] Barceló JLM, Tahoces LS, del Busto AdR, López AC, Mur JLM, Illera JP. Closure of an iatrogenic coronary artery fistula with a PTFE-coated stent. *Rev Esp Cardiol* 2004;57:699-701 [in Spanish].
- [22] Sgalambro A, Olivetto I, Rossi A, Nistri S, Baldini K, Baldi M, et al. Prevalence and clinical significance of acquired left coronary artery fistulas after surgical myectomy in patients with hypertrophic cardiomyopathy. *J Thorac Cardiovasc Surg* 2010;140:1046-52.
- [23] Uchida N, Baudet E, Roques X, Laborde N, Billes M. Surgical experience of coronary artery-right ventricular fistula in a heart transplant patient. *Eur J Cardiothorac Surg* 1995;9:106-8.
- [24] Lee CH, Neto PL, Serruys P. Acquired coronary artery fistula leading to acute myocardial infarction after endomyocardial biopsy. *Heart* 2003;89:495.
- [25] Hartog J, Van den Brand M, Pieterman H, Di Mario C. Closure of a coronary cameral fistula following endomyocardial biopsies in a cardiac transplant patient with a detachable balloon. *Cathet Cardiovasc Diagn* 1993;30:156-9.