

EFFECT OF LASER PHOTOCOAGULATION ON MACULAR EDEMA ASSOCIATED WITH MACULAR HOLES

Anibal Francone, MD,* Juliet Essilfie, MD,† David Sarraf, MD,‡ Rony C. Preti, MD, PhD,§ Mario L. R. Monteiro, MD, PhD,§ Jean-Pierre Hubschman, MD*

Purpose: To report the outcomes of laser therapy to barricade eccentric full-thickness macular hole with associated cystoid macular edema.

Methods: We report two patients who developed an eccentric full-thickness macular hole with persistent cystoid macular edema after pars plan vitrectomy with and without internal limiting membrane peel for epiretinal membrane and the results of argon laser therapy.

Results: Barricade argon laser therapy was applied concentric to the full-thickness macular hole. Associated cystoid macular edema was noted to resolve within 1 to 3 months of therapy in both cases.

Conclusion: Barricade laser therapy surrounding a macular hole can lead to resolution of associated cystoid macular edema. Pathogenic mechanisms to explain this favorable outcome are discussed.

RETINAL CASES & BRIEF REPORTS 15:730–733, 2021

*From the *Division of Retina, Stein Eye Institute, University of California Los Angeles Geffen School of Medicine, Los Angeles, CA; †Stein Eye Institute, Department of Ophthalmology, University of California Los Angeles Geffen School of Medicine, Los Angeles, CA; ‡Stein Eye Institute, Department of Ophthalmology, University of California, David Geffen School of Medicine, Los Angeles (UCLA), California; VA Greater Los Angeles Healthcare System, Los Angeles, California; and §Division of Ophthalmology, University of São Paulo Medical School, Sao Paulo, Brazil.*

Eccentric macular hole (MH) is a rare but established complication after pars plana vitrectomy with or without internal limiting membrane peel (PPV/ILM) and may occur in 0.3 to 6% of cases after PPV for various macular disorders including epiretinal membrane, MH, and persistent cystoid macular edema (CME).^{1–3} The pathophysiology of eccentric MH formation has yet to be elucidated. Proposed theories include contraction of the persistent ILM, secondary epimacular proliferation stimulated by the ILM peel,

and iatrogenic traction to the retina with the forceps during membrane peeling.^{4–6}

Eccentric MHs are generally stable without vision loss but can be complicated by CME.² We present two cases of eccentric MH formation, after PPV with and without ILM peel, complicated by CME that resolved after treatment with laser retinopexy to barricade the iatrogenic MH.

Case Reports

Case 1

A 71-year-old woman presented to the Stein Eye Institute for management of visually significant CME associated with iatrogenic eccentric MH formation in the right eye. Ocular history was notable for PPV/ILM for epiretinal membrane and macular pucker in the right eye 6 months earlier. Shortly after surgery, the patient developed significant CME that was persistent despite two intravitreal triamcinolone injections. Ocular history included bilateral uncomplicated cataract extraction with lens implantation a few years before presentation.

On examination, best-corrected visual acuity was 20/70 in the right eye and 20/20 in the left eye. Dilated retinal examination demonstrated an iatrogenic full-thickness eccentric MH temporal to the macula of the right eye. Macular spectral domain optical coherence tomography of

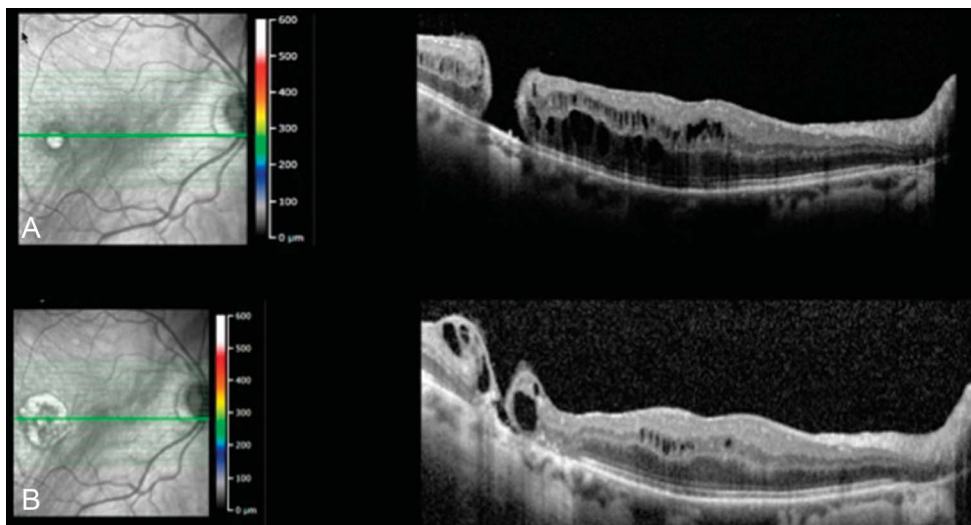


Fig. 1. Optical coherence tomography imaging of Case 1 (right eye) demonstrating an eccentric full-thickness MH temporal to the fovea. **A.** Note the presence of intraretinal fluid in the inner and outer nuclear layers adjacent to the hole and extending to the fovea. **B.** Improvement in CME following laser barricade around the eccentric MH.

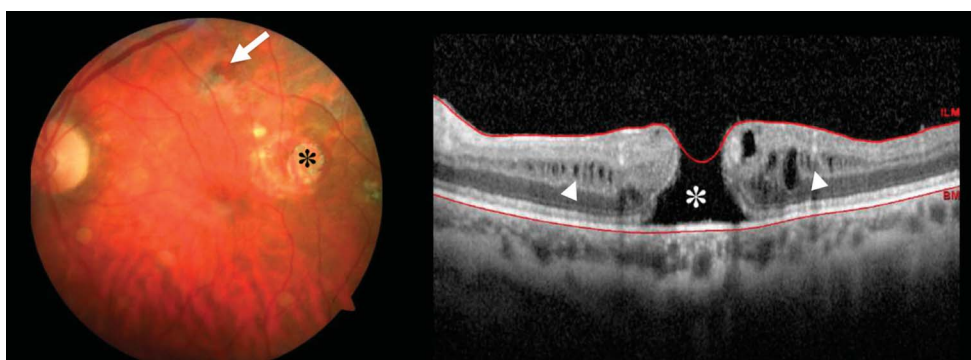


Fig. 2. (Left image) Color fundus retinal photography of Case 2 demonstrating an eccentric MH located superior to the fovea (white arrow) and an area of chorioretinal atrophy temporal to the fovea (black asterisk). (Right image) Optical coherence tomography scan shows the full-thickness eccentric MH (white asterisk) and CME mainly in the inner nuclear layer (white arrowheads). BM, Bruch membrane.

the right eye illustrated severe CME extending from the MH to the fovea (Figure 1A). The edema and hole were stable for several months and unimproved after intravitreal steroid injection when compared with previous imaging from the referring ophthalmologist. Due to recalcitrant CME, the decision was made to barricade the MH with argon laser therapy (PASCAL Topcon Corporation, Japan). The laser parameters applied included a power of 300 mW, a pulse duration of 300 ms, a spot size of 200 μm , and a total number of 181 shots. The patient was pretreated with one 1.25-mg/0.05-mL bevacizumab

injection to reduce retinal edema around the hole and improve laser energy absorption. Vision improved, and the CME resolved within 3 months of the laser procedure (Figure 1B). Best-corrected visual acuity remained at 20/30 with continued resolution of fluid at the most recent follow-up, 1 year after laser treatment.

Case 2

A 70-year-old woman was evaluated at the University of São Paulo for management of chronic CME after extracapsular cataract surgery of the left eye. Of note, she presented with a history of PPV for epiretinal membrane of the left eye that was complicated by a full-thickness eccentric MH (Figure 2). Best-corrected visual acuity was 20/50 in the left eye. Treatment with one intravitreal triamcinolone acetonide (0.1 mL/4 mg) and two intravitreal bevacizumab (1.25 mg/0.05 mL) injections over the course of 5 months was not associated with any visual or anatomical improvement. Given the persistent CME, the decision was made to barricade the eccentric MH with argon laser therapy (PUREPOINT 532 nm; Alcon Laboratories, Inc, Fort Worth, TX). The laser parameters applied included a power of 250 mW, a duration of 0.1 ms, and a spot size of 150 μm . One month after laser treatment, the CME was nearly resolved and vision was improved to 20/25 in the left eye (Figure 3). Of note, the patient's last anti-vascular endothelial growth factor treatment was 10 months before the laser treatment.

Research To Prevent Blindness, New York, NY.

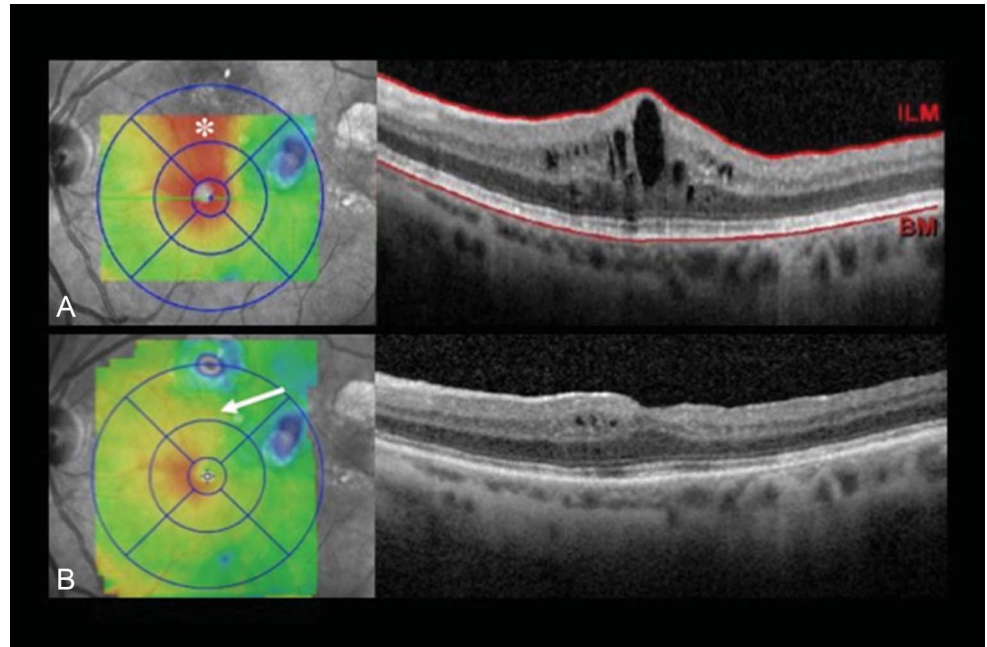
Case Presented at Doheny/Stein Case Conference, Los Angeles, CA, February 21, 2018.

J.-P. Hubschman is a consultant for Allergan, and Alcon. D. Sarraf receives research grants from Allergan, Genentech, Heidelberg, Regeneron, and Optovue and is a consultant for Amgen, Bayer, Novartis, Optovue, and Genentech. The remaining authors have no conflicts of interests to disclose.

Reprint requests: Jean-Pierre Hubschman, MD, Division of Retina, Stein Eye Institute, University of California Los Angeles Geffen School of Medicine, 200 Stein Plaza, Los Angeles, CA 90095; e-mail: Hubschman@jsei.ucla.edu

This is an open-access article distributed under the terms of the Creative Commons Attribution-Non Commercial-No Derivatives License 4.0 (CCBY-NC-ND), where it is permissible to download and share the work provided it is properly cited. The work cannot be changed in any way or used commercially without permission from the journal.

Fig. 3. Optical coherence tomography thickness map and spectral domain optical coherence tomography of Case 2. **A.** Fluid tract between the eccentric MH and the fovea (white asterisk) and CME before treatment. **B.** Fluid tract resolution (white arrow) 1 month after laser photocoagulation. Optical coherence tomography image demonstrates a remarkable improvement in macular edema after laser treatment. ILM, Bruch membrane.



Discussion

Eccentric MH formation after PPV/ILM is an unusual complication. Patients are typically asymptomatic and the risk of retinal detachment is negligible.^{2,7} Prophylactic laser retinopexy to decrease the low risk of retinal detachment may be considered in some cases.

Severe CME may complicate a postoperative eccentric MH; however, the pathogenesis of fluid accumulation associated with MH formation remains unclear. Possible mechanisms for CME development include postsurgical inflammation or persistent fluid after ILM peel. Alternatively, the cystic abnormalities may represent degenerative cavitation, possibly related to Muller cell disruption, as recently proposed.⁸ Hydration of the retina from the vitreous through the MH (Figure 4) versus disruption and leakage of the deep

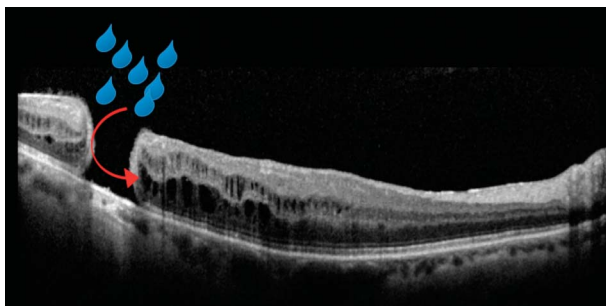


Fig. 4. Optical coherence tomography of Case 1 (right eye). Hypothetical mechanism of macular edema is presented. Fluid from the vitreous cavity (blue drops) flows through the eccentric full-thickness hole into the adjacent retinal tissue.

retinal capillary plexus have also been proposed.^{9,10} Retinal pigment epithelium decompensation may serve to further complicate these hydrostatic mechanisms. The pattern of edema on the macular thickness map in our cases suggested a mechanism of vitreous hydration as the fluid localized around the hole with a linear tract of edema extending from the hole to the fovea in both cases (Figure 5). This configuration is similar to the pattern of fluid secondary to an optic nerve pit.

Both patients were treated with barricade laser therapy. The goal of the laser treatment was to create a strong adherence between the retinal pigment epithelium and neuroretina and induce local scarring in the full-thickness retina, to block fluid movement through the interstitial retinal tissue. Consequently, a stronger laser setting (higher power and longer duration) was implemented than is typical for a routine retinopexy.¹¹ After laser therapy, the CME briskly resolved in each case, perhaps the result of a barricade effect of the retinal scar (Figures 3 and 6), suggesting that vitreous hydration of the retina may be the etiology of CME. Mild cystoid fluid persisted inside the zone of laser scars where a patent conduit of vitreous fluid was still present, which may be further evidence of the barricade effect of the laser therapy.

Nevertheless, we cannot exclude the possibility that the laser energy exerted a cellular or microvascular effect leading to resorption of intraretinal fluid.¹² Focal macular laser photocoagulation for diabetic macular edema and other retinal vascular disorders associated with CME has been an important modality of therapy for many years, and various mechanisms have been

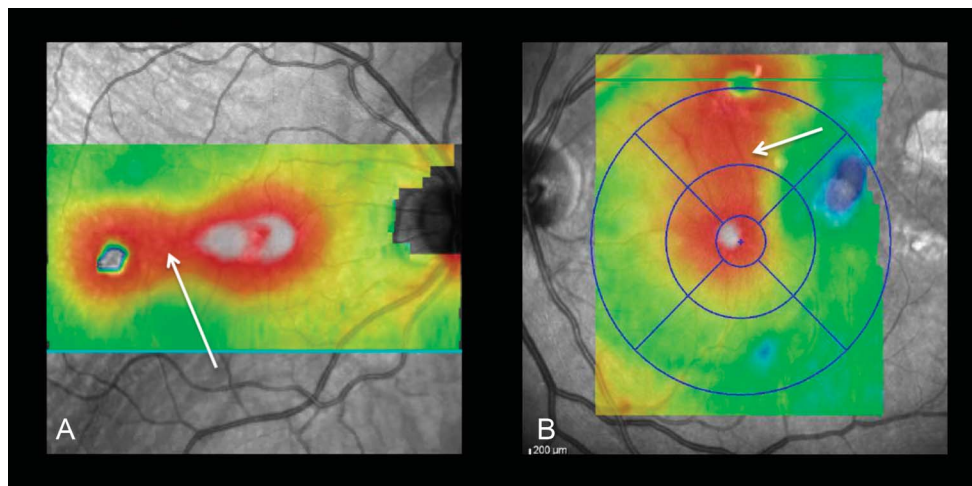


Fig. 5. Optical coherence tomography thickness map of Case 1 (A) and Case 2 (B) illustrating localized edema around the eccentric full-thickness retinal hole and the fovea. Note the tract (arrows) of fluid between the retinal hole and fovea.

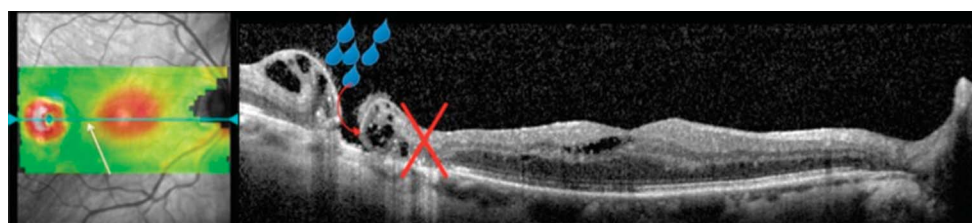


Fig. 6. Optical coherence tomography of Case 1 (right eye) 1 year after laser retinal treatment. A full-thickness chorioretinal scar surrounding the MH is noted. Macular edema has remarkably improved. The red cross indicates the barricade effect of the retinal scar, and the arrow

indicates the vitreous hydration of the retina.

proposed to explain the deturgescence effect of the laser energy on the retina including retinal vascular endothelial turnover and retinal pigment epithelium pump enhancement.¹³

More robust investigation with larger numbers of patients and longer follow-up will help to elucidate the mechanism of fluid resolution in these cases. However, the creation of a laser photocoagulation full-thickness barricade around the hole may be considered for the treatment of severe CME complicating eccentric MH formation.

Key words: macular hole, eccentric macular hole, cystoid macular edema, epiretinal membrane, PPV/ILM, laser retinopexy, argon laser, laser barricade.

References

1. Sandali O, El Sanharawi M, Basli E, et al. Paracentral retinal holes occurring after macular surgery: incidence, clinical features, and evolution. *Graefes Arch Clin Exp Ophthalmol* 2012;250:1137–1142.
2. Rush RB, Simunovic MP, Aragon AV, Ysasaga JE. Postoperative macular hole formation after vitrectomy with internal limiting membrane peeling for the treatment of epiretinal membrane. *Retina* 2014;34:890–896.
3. Garnavou-Xirou C, Xirou T, Kabanarou S, et al. Eccentric macular hole after pars plana vitrectomy for epiretinal membrane without internal limiting membrane peeling: a case report. *Ophthalmol Ther* 2017;6:391–395.
4. Rubinstein A, Bates R, Benjamin L, Shaikh A. Iatrogenic eccentric full thickness macular holes following vitrectomy with ILM peeling for idiopathic macular holes. *Eye* 2005;19:1333–1335.
5. Steven P. Secondary paracentral retinal holes following internal limiting membrane removal. *Br J Ophthalmol* 2006;90:293–295.
6. Mason JO, Feist RM, Albert MA. Eccentric macular holes after vitrectomy with peeling of epimacular proliferation. *Retina* 2007;27:45–48.
7. Brouzas D, Dettoraki M, Lavaris A, et al. Postoperative eccentric macular holes after vitrectomy and internal limiting membrane peeling. *Int Ophthalmol* 2017;37:643–648.
8. Matet A, Savastano MC, Rispoli M, et al. En face optical coherence tomography of foveal microstructure in full-thickness macular hole: a model to study perifoveal müller cells. *Am J Ophthalmol* 2015;159:1142–1151.e3.
9. Tornambe PE. Macular hole genesis: the hydration theory. *Retina Phila Pa* 2003;23:421–424.
10. Antcliff RJ, Marshall J. The pathogenesis of edema in diabetic maculopathy. *Semin Ophthalmol* 1999;14:223–232.
11. Jain At. Effect of pulse duration on size and character of the lesion in retinal photocoagulation. *Arch Ophthalmol* 2008;126:78.
12. Spranger J, Osterhoff M, Reimann M, et al. Loss of the antiangiogenic pigment epithelium-derived factor in patients with angiogenic eye disease. *Diabetes* 2001;50:2641–2645.
13. Bresnick GH. Diabetic maculopathy. *Ophthalmology* 1983;90:1301–1317.