

## ORIGINAL ARTICLE

# Bakers' cyst and tibiofemoral abnormalities are more distinctive MRI features of symptomatic osteoarthritis than patellofemoral abnormalities

A W Visser,<sup>1</sup> B Mertens,<sup>2</sup> M Reijniere,<sup>3</sup> J L Bloem,<sup>3</sup> R de Mutsert,<sup>4</sup> S le Cessie,<sup>2,4</sup> F R Rosendaal,<sup>4,5</sup> M Kloppenburg,<sup>1,4</sup> for the NEO Study Group

**To cite:** Visser AW, Mertens B, Reijniere M, et al. Bakers' cyst and tibiofemoral abnormalities are more distinctive MRI features of symptomatic osteoarthritis than patellofemoral abnormalities. *RMD Open* 2016;**2**:e000234. doi:10.1136/rmdopen-2015-000234

► Prepublication history for this paper is available online. To view these files please visit the journal online (<http://dx.doi.org/10.1136/rmdopen-2015-000234>).

Received 17 December 2015  
Revised 11 April 2016  
Accepted 14 April 2016



CrossMark

For numbered affiliations see end of article.

**Correspondence to**  
Dr A W Visser;  
[a.w.visser@lumc.nl](mailto:a.w.visser@lumc.nl)

## ABSTRACT

**Objective:** To investigate which structural MR abnormalities discriminate symptomatic knee osteoarthritis (OA), taking co-occurrence of abnormalities in all compartments into account.

**Methods:** The Netherlands Epidemiology of Obesity (NEO) study is a population-based cohort aged 45–65 years. In 1285 participants (median age 56 years, 55% women, median body mass index (BMI) 30 kg/m<sup>2</sup>), MRI of the right knee were obtained. Structural abnormalities (osteophytes, cartilage loss, bone marrow lesions (BMLs), subchondral cysts, meniscal abnormalities, effusion, Baker's cyst) at 9 patellofemoral and tibiofemoral locations were scored following the knee OA scoring system. Symptomatic OA in the imaged knee was defined following the American College of Rheumatology criteria. Logistic ridge regression analyses were used to investigate which structural abnormalities discriminate best between individuals with and without symptomatic OA, crude and adjusted for age, sex and BMI.

**Results:** Symptomatic knee OA was present in 177 individuals. Structural MR abnormalities were highly frequent both in individuals with OA and in those without. Baker's cysts showed the highest adjusted regression coefficient (0.293) for presence of symptomatic OA, followed by osteophytes and BMLs in the medial tibiofemoral compartment (0.185–0.279), osteophytes in the medial trochlear facet (0.262) and effusion (0.197).

**Conclusions:** Baker's cysts discriminate best between individuals with and without symptomatic knee OA. Structural MR abnormalities, especially in the medial side of the tibiofemoral joint and effusion, add further in discriminating symptomatic OA. Baker's cysts may present as a target for treatment.

## INTRODUCTION

The knee joint is composed of three compartments: the medial and lateral tibiofemoral compartments and the patellofemoral

## Key messages

### What is already known about this subject?

- Structural abnormalities in the knee joint assessed by MRI are frequent in individuals with and without symptomatic osteoarthritis (OA).

### What does this study add?

- Co-occurrence of all structural abnormalities in all compartments of the knee was taken into account when investigating which abnormalities can best discriminate between individuals with and without symptomatic OA.
- Baker's cysts discriminate best between individuals with and without symptomatic OA. Structural MR abnormalities, especially in the medial side of the tibiofemoral joint and effusion, add further in discriminating symptomatic OA.

### How might this impact on clinical practice?

- The presence of Baker's cysts may especially present as a target for treatment.

compartment. Research in knee osteoarthritis (OA) focused mainly on the tibiofemoral joint,<sup>1</sup> although OA can occur in all these compartments, either isolated or concurrent.<sup>2</sup> OA in all compartments has been related to symptoms as pain and disability.<sup>3–4</sup> However, the underlying relationships and attributions of osteoarthritic abnormalities in the different compartments to symptoms in OA are incompletely understood.

The knee joint comprises bone, cartilage, menisci and synovial tissue. Structural abnormalities have been observed in all these joint tissues, increasing with age.<sup>5</sup> These structural abnormalities are not specific for OA, since they have also been observed in persons without OA.<sup>6–9</sup> Clinical or symptomatic OA is classified on the basis of the presence of

pain, clinical characteristics and abnormalities observed during physical examination,<sup>10</sup> but which structural abnormalities contribute to symptoms and whether and which structural abnormalities can discriminate symptomatic OA is not clear.

Previous studies on the association between structural abnormalities, such as bone marrow lesions (BMLs), synovitis or cartilage defects, and symptoms in OA showed conflicting results; while some studies found an association between these structural abnormalities and OA symptoms, other did not.<sup>11–14</sup> These discrepancies could be caused by the co-occurrence of structural abnormalities in different tissues, but it may all have resulted from the analyses, which were univariate or limited multivariate analyses, not adjusting for all tissue abnormalities in all joint locations.

Therefore, this study investigates which specific structural abnormalities in all compartments of the knee as assessed by MRI can best discriminate between individuals with and without symptomatic OA within the same knee, using a model that takes co-occurrence of all abnormalities into account.

## PATIENTS AND METHODS

### Study design and study population

The Netherlands Epidemiology of Obesity (NEO) study is a population-based prospective cohort study including 6671 individuals aged 45–65 years, with an oversampling of persons with overweight or obesity. Detailed information about the study design and data collection has been described elsewhere.<sup>15</sup> In short, men and women between 45 and 65 years with a self-reported body mass index (BMI) of 27 kg/m<sup>2</sup> or higher living in the greater area of Leiden were eligible to participate. In addition, all inhabitants aged 45–65 years from one municipality (Leiderdorp) were invited irrespective of their BMI.

All participants completed questionnaires on demographic and clinical data and visited the NEO study centre for several baseline measurements, including measurement of weight (kg) and height (cm) to calculate the BMI (kg/m<sup>2</sup>), and an extensive physical examination. A random sample of 1285 study participants without contraindications (metallic devices, claustrophobia, body circumference >170 cm) underwent MRI of the right knee. The present study is a cross-sectional analysis of baseline measurements of these 1285 participants. The study was approved by the medical ethics committee of the Leiden University Medical Center and all participants gave written informed consent.

### Magnetic resonance image

MRI was performed using a dedicated knee coil in a 1.5T system (Philips, Medical Systems, Best, The Netherlands). Our standardised scanning protocol consisted of<sup>1</sup> Coronal proton density (PD) turbo spin echo (TSE), repetition time (TR)/echo time (TE) 2335/35 ms; echo train length (ETL) 6,<sup>2</sup> coronal frequency

selective fat-suppressed PD TSE (TR/TE 2334/35 ms; ETL 6, 3 mm slice thickness);<sup>3</sup> sagittal PD TSE (TR/TE 2338/35; ETL 6; 3.5 mm slice thickness);<sup>4</sup> sagittal frequency selective fat-suppressed T1-weighted three-dimensional gradient echo sequence (TR/TE 11/5.5; 25° flip angle; 150 mm field of view, 272×512 acquisition matrix, 2 mm slice thickness with a 1 mm overlap between images);<sup>5</sup> axial frequency selective fat-suppressed PD TSE (TR/TE 3225/15; ETL 6, 4 mm slice thickness). In all TSE sequences, we used a 150–160 mm field of view and a 304×512 acquisition matrix. Total acquisition time, including the initial survey sequence, was 30 min.

### Scoring of MRI

A trained reader (AWV, supervised by JLB) used the validated semiquantitative knee OA scoring system blinded to clinical data.<sup>16</sup> Presence or absence of osteophytes, cartilage loss, subchondral BMLs and subchondral cysts was scored at the following locations: patellar crest, medial and lateral patellar facet, medial and lateral trochlear articular facet, medial and lateral femoral condyle and medial and lateral tibial plateau.

Osteophytes were defined as focal bony excrescences, extending from a cortical surface and measured from base to tip, graded 0 (absent), 1 (<3 mm), 2 (3–5 mm) or 3 (5 mm).

Cartilage loss was graded 0 (absent), 1 (<50% reduction), 2 (≥50% reduction) or 3 (full-thickness cartilage loss).

BMLs were defined as ill-defined areas of increased signal intensity on T2-weighted images in the subchondral bone extending away from the articular surface and graded 0 (absent), 1 (diameter <5 mm), 2 (5 mm–2 cm) or 3 (>2 cm).

Subchondral cysts were defined as well-defined foci of high signal intensity on T2-weighted images in the subchondral bone and graded on the basis of their measured greatest dimension as 0 (absent), 1 (<3 mm), 2 (3–5 mm) or 3 (>5 mm). Both BMLs and cysts were required not to be associated with meniscal or ligamentous attachments.

The menisci were reviewed for presence of subluxation, maceration and degenerative tears. Subluxation was defined as protrusion over the tibial plateau edge and graded 0 (absent), 1 (<1/3 meniscal width bulging), 2 (1/3–2/3 bulging) or 3 (>2/3 involved). Maceration was defined as an intrameniscal focus of intermediate signal intensity and graded 0 (absent), 1 (a small, central focus in meniscus), 2 (intrameniscal focus surrounded by a broad, hypointense peripheral rim) or 3 (a thin, hypointense peripheral rim outlining the intrameniscal focus). Tears were defined as regions of intermediate signal intensity within the meniscus, communicating with the surface or inner margin on more than one section, graded 0 (absent) or 1 (present).

Joint effusion was graded 0 (a small physiological sliver of synovial fluid), 1 (a small amount of fluid distending 1 or 2 joint recesses), 2 (>2 joint recesses partially distended), or 3 (full, marked distention of all joint recesses).

A Baker's cyst was defined when a circumscribed mass with intermediate signal intensity on PD-weighted and high signal intensity on T2-weighted dual SE sequences was observed, originating from the dorsomedial tibiofemoral joint space. Baker's cysts were graded 0 (absent), 1 (minimal), 2 (moderate) or 3 (severe).

A random 10% of the MRI (n=120) were scored twice to test the reproducibility; intraclass correlation coefficients were for meniscal maceration 0.61, meniscal tear 0.87, meniscal subluxation 0.93, cyst 0.64, BML 0.93, cartilage loss 0.90, osteophytes 0.97.

### Symptomatic knee OA

Self-reported pain and morning stiffness were measured using standardised questionnaires. Physical examination of both knee joints was performed by trained research nurses, using a standardised scoring form. OA was defined on the basis of the clinical criteria of the American College of Rheumatology as presence of pain on most days of the prior month and at least three of the following criteria:<sup>1</sup> age >50 years,<sup>2</sup> stiffness <30 min duration,<sup>3</sup> crepitus on active motion,<sup>4</sup> bony tenderness,<sup>5</sup> bony enlargement,<sup>6</sup> no palpable warmth.<sup>10</sup>

### Statistical analysis

Data were analysed using SPSS V.20 (SPSS Inc, Chicago, Illinois, USA), Matlab version R2014a (MathWorks, Natick, Massachusetts, USA) and R V.3.0.1 (R foundation; <http://www.r-project.org>).

The prevalence of structural abnormalities was analysed in the total study population and stratified by symptomatic OA status. The relation between different structural abnormalities was visualised by network graphs, constructed using R (package 'glasso'), by estimating a sparse inverse covariance matrix using a lasso (L1) penalty. The basis for the graphical lasso calculation was the pooled variance-covariance matrix across both outcome groups (individuals with and without symptomatic OA).

To investigate which specific abnormalities discriminate best between individuals with and without symptomatic OA, the following analyses were performed including all structural abnormalities graded 0–3 (only meniscal tears were graded 0/1).

Since the number of individuals without symptomatic OA was much higher than the number of OA cases, we split the set of individuals without OA into three parts and repeated the subsequently described model analysis for each of these three parts to assess stability of computations. Individuals without OA were randomly assigned to three mutually exclusive sets; each of these sets was then combined with the OA cases, rendering three calibration sets. The subsequently described discriminant analysis was then applied (repeated) for each of these sets. A logistic ridge regression model (see Hastie *et al*<sup>17</sup> for description) was fitted to each of the above constructed calibration sets using a double cross-validated approach.<sup>18</sup> The double cross-validated approach provides unbiased class

probabilities for each individual in each of the above three calibration sets. Cross-validated deviances were used to select optimal models within the double cross-validated assessment. Receiver-operating characteristic curves, area under the curve (AUC) and classification statistics were used to summarise the double cross-validated classifications. Double cross-validation uses a separate model fit for each left-out datum to generate unbiased classification summaries. For model parameter interpretation, we therefore refitted the logistic ridge regression model to the calibration data, using the optimum shrinkage (penalty) term identified in the preceding double cross-validated calculation. Regression coefficients for all assessed structural abnormalities in the different locations within the joint were calculated on the basis of this final fitted model. Penalised estimates such as those provided by ridge regression reduce variance of estimation by allowing for bias in the estimation of the effects, which implies that classical estimates of the variance of these estimates can no longer be meaningfully interpreted.

Both crude analyses and analyses adjusted for age, sex and BMI were performed. Higher regression coefficients reflect better discrimination between presence or absence of symptomatic OA, taking co-occurrence of all abnormalities into account.

## RESULTS

### Population characteristics

After exclusion of individuals with missing data of physical examination (n=1), data from 1284 participants were analysed. Of the studied individuals, 55% were women. Median age was 56 years (IQR 50–61), median BMI 30.0 kg/m<sup>2</sup> (27.9–33.0). Symptomatic OA in the imaged knee was present in 177 individuals. The 1107 individuals without symptomatic OA were divided into three mutually exclusive sets of 369 individuals for further analyses.

### Prevalence of structural MR abnormalities

The prevalence of structural abnormalities in the total study population is presented in [table 1](#). All assessed structural abnormalities except for subchondral cysts were observed frequently. However, the prevalence differed across locations within the joint.

In the tibiofemoral and patellofemoral compartment, osteophytes were commonly observed, especially in the medial tibiofemoral compartment (medial femoral condyle 86%, medial tibial plateau 38%) and the medial patellar facet (59%). Cartilage defects were also frequently observed in both compartments, especially medially (medial femoral condyle 58%, medial tibial plateau 68%, medial patellar facet 65%, medial trochlear facet 53%) and in the patellar crest (65%). BMLs were observed less frequently, mostly located in the patellar crest (22%).

Meniscal abnormalities were observed most commonly in the medial meniscus; maceration was most prevalent (35%), followed by tears (23%) and subluxation (15%).

**Table 1** Prevalence of structural abnormalities as assessed on MRI on different locations in the knee in the total NEO study population

	n=1284			
	Grade 0 (n (%))	Grade 1 (n (%))	Grade 2 (n (%))	Grade 3 (n (%))
Baker's cyst	894 (70)	245 (19)	100 (8)	45 (4)
Effusion	253 (20)	848 (66)	163 (13)	20 (2)
<i>Tibiofemoral compartment:</i>				
Osteophytes				
Femoral condyle medial/lateral	186 (14)/293 (23)	946 (74)/882 (69)	122 (10)/88 (7)	30 (2)/21 (2)
Tibial plateau medial/lateral	801 (62)/929 (72)	436 (34)/310 (24)	41 (3)/36 (3)	6 (0)/9 (1)
Cartilage defects				
Femoral condyle medial/lateral	544 (42)/1031 (80)	563 (44)/180 (14)	142 (11)/65 (5)	35 (3)/8 (1)
Tibial plateau medial/lateral	409 (32)/1077 (84)	733 (57)/102 (8)	129 (10)/88 (7)	13 (1)/17 (1)
Bone marrow lesions				
Femoral condyle medial/lateral	1078 (84)/1185 (92)	109 (8)/49 (4)	95 (7)/48 (4)	2 (0)/2 (0)
Tibial plateau medial/lateral	1136 (88)/1199 (93)	61 (5)/36 (3)	82 (6)/45 (4)	5 (0)/4 (0)
Cysts				
Femoral condyle medial/lateral	1268 (99)/1268 (99)	15 (1)/12 (1)	0 (0)/4 (0)	1 (0)/0 (0)
Tibial plateau medial/lateral	1251 (97)/1257 (98)	18 (1)/15 (1)	11 (1)/6 (0)	4 (0)/6 (0)
<i>Patellofemoral compartment:</i>				
Osteophytes				
Patellar crest	1270 (99)	7 (1)	5 (0)	2 (0)
Patellar facet medial/lateral	527 (41)/1057 (82)	642 (50)/200 (16)	103 (8)/27 (2)	12 (1)/0 (0)
Trochlear facet medial/lateral	897 (70)/1006 (78)	325 (25)/241 (19)	42 (3)/28 (2)	19 (1)/9 (1)
Cartilage defects				
Patellar crest	448 (35)	393 (31)	275 (21)	168 (13)
Patellar facet medial/lateral	445 (35)/770 (60)	346 (27)/336 (26)	332 (26)/126 (10)	161 (13)/52 (4)
Trochlear facet medial/lateral	607 (47)/837 (65)	513 (40)/362 (28)	149 (12)/58 (5)	15 (1)/27 (2)
Bone marrow lesions				
Patellar crest	1005 (78)	109 (8)	170 (13)	0 (0)
Patellar facet medial/lateral	1173 (91)/1218 (95)	69 (5)/41 (3)	42 (3)/24 (2)	0 (0)/1 (0)
Trochlear facet medial/lateral	1208 (94)/1210 (94)	45 (4)/27 (2)	30 (2)/45 (4)	1 (0)/2 (0)
Cysts				
Patellar crest	1244 (97)	35 (3)	5 (0)	0 (0)
Patellar facet medial/lateral	1269 (99)/1280 (100)	14 (1)/4 (0)	1 (0)/0 (0)	0 (0)/0 (0)
Trochlear facet medial/lateral	1274 (99)/1274 (99)	9 (1)/8 (1)	1 (0)/2 (0)	0 (0)/0 (0)
<i>Menisci:</i>				
Subluxation medial/lateral	1092 (85)/1112 (87)	171 (13)/156 (12)	19 (1)/16 (1)	2 (0)/0 (0)
Maceration medial/lateral	837 (65)/955 (74)	341 (27)/262 (20)	102 (8)/63 (5)	4 (0)/4 (0)
Tear medial/lateral	985 (77)/1090 (85)	299 (23)/194 (15)	NA	NA

Numbers (%), rounded to whole numbers).

NA, not applicable; NEO, the Netherlands Epidemiology of Obesity study.

As presented in [table 2](#), a higher prevalence of osteophytes, cartilage defects, BMLs and meniscal abnormalities were seen in individuals with symptomatic OA as compared to individuals without.

Effusion was also highly prevalent (80%), in individuals with and without symptomatic OA. Higher grades of effusion were especially observed more often in individuals with symptomatic OA than in those without. The same was observed for Baker's cysts (overall prevalence 30%); grade 2 and grade 3 were especially observed most often in individuals with OA.

### Relation between structural abnormalities

In the total study population, including individuals with and without symptomatic OA, the relation between structural abnormalities was visualised by network graphs, showing multiple relations between abnormalities on

different locations within the joint. A number of network graphs were performed, the number of relations shown in the graph depending on the used lasso penalty. All network graphs showed relations between osteophytes on different locations within all compartments of the knee and between cartilage defects on different locations. Furthermore, osteophytes and cartilage defects within the same compartment were also related. [Figure 1](#) shows 15 structural abnormalities with 22 relations between them. Besides osteophytes and cartilage defects at different locations within the joint, BMLs in the patellar crest were present in the network graph, related to cartilage defects in the patellar crest and medial patellar facet.

### Structural abnormalities discriminating symptomatic OA

Next, we investigated which specific abnormalities could best discriminate between individuals with and without

**Table 2** Prevalence of structural abnormalities as assessed on MRI on different locations in the knee stratified by symptomatic knee OA status

	No symptomatic OA (n=1107) Grade 0-1-2-3 (%)	Symptomatic OA (n=177) Grade 0-1-2-3 (%)
Baker's cyst	71-19-7-2	60-17-11-12
Effusion	21-68-10-1	14-52-29-6
<i>Tibiofemoral compartment:</i>		
Osteophytes		
Femoral condyle medial/lateral	16-76-8-1/24-70-5-1	8-59-20-12/16-59-19-6
Tibial plateau medial/lateral	66-32-2-0/76-22-2-1	38-47-12-3/53-36-9-2
Cartilage defects		
Femoral condyle medial/lateral	44-44-10-2/82-13-4-0	30-42-20-8/70-18-10-2
Tibial plateau medial/lateral	33-58-9-1/85-7-7-1	28-53-15-5/76-12-9-2
Bone marrow lesions		
Femoral condyle medial/lateral	87-8-6-0/93-3-3-0	67-15-19-NP/88-6-6-NP
Tibial plateau medial/lateral	91-5-4-0/94-3-3-0	75-5-19-2/88-4-7-2
Cysts		
Femoral condyle medial/lateral	99-1-NP-0/99-1-0-NP	98-2-NP-NP/98-2-1-NP
Tibial plateau medial/lateral	98-1-1-0/98-1-1-0	96-3-1-1/97-1-1-1
<i>Patellofemoral compartment:</i>		
Osteophytes		
Patellar crest	99-0-0-0	96-2-2-0
Patellar facet medial/lateral	44-49-7-0/85-14-1-NP	25-54-17-6/68-25-7-NP
Trochlear facet medial/lateral	74-24-2-1/81-17-1-0	46-36-11-7/61-28-8-3
Cartilage defects		
Patellar crest	37-30-21-12	22-32-25-22
Patellar facet medial/lateral	36-28-25-12/62-26-9-3	27-24-32-18/50-29-12-9
Trochlear facet medial/lateral	48-40-11-1/66-28-5-1	42-37-16-5/59-29-5-7
Bone marrow lesions		
Patellar crest	80-8-12-NP	71-10-20-NP
Patellar facet medial/lateral	91-5-4-NP/95-3-2-0	93-6-1-NP/92-5-3-NP
Trochlear facet medial/lateral	94-4-2-0/95-2-3-0	94-3-3-NP/88-5-7-NP
Cysts		
Patellar crest	97-3-1-NP	97-3-NP-NP
Patellar facet medial/lateral	99-1-0-NP/100-0-NP-NP	100-NP-NP-NP/99-1-NP-NP
Trochlear facet medial/lateral	99-1-0-NP/99-1-0-NP	98-2-NP-NP/99-1-NP-NP
<i>Menisci:</i>		
Subluxation medial/lateral	87-12-1-0/87-12-1-NP	75-19-6-1/83-16-1-NP
Maceration medial/lateral	66-27-7-0/75-20-5-0	63-23-14-1/71-21-6-2
Tear medial/lateral	78-22-NA-NA/86-14-NA-NA	71-29-NA-NA/79-22-NA-NA

Numbers are rounded to percentages as whole numbers.  
NP, not present, NA, not applicable; OA, osteoarthritis.

symptomatic OA, taking co-occurrence of all abnormalities into account.

Regression coefficients of the assessed structural abnormalities for presence of OA as obtained by logistic ridge regression analyses are listed in table 3. Depicted are regression coefficients for all three analyses sets and a mean regression coefficient for these sets. The higher the regression coefficient, the better the corresponding structural abnormality discriminates symptomatic OA, adjusted for co-occurrence of abnormalities. The regression coefficients for subchondral cysts were all below 0.030.

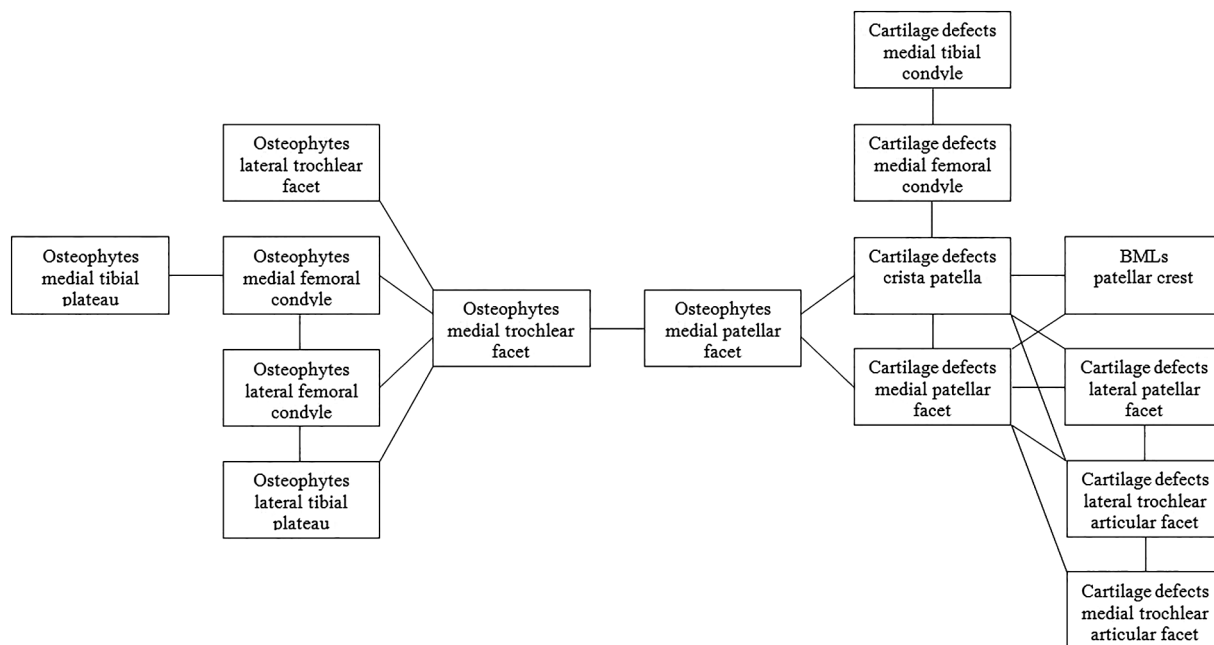
Baker's cysts showed the highest regression coefficient for OA, followed by osteophytes in the medial tibial plateau and medial trochlear facet. The next strongest

regression coefficient was found for effusion, followed by BMLs in the medial tibiofemoral compartment and osteophytes in the medial femoral condyle.

The three separate analyses sets were comparable. After adjustment for age, sex and BMI, the same structural abnormalities were observed to discriminate symptomatic OA best. The AUC for the three sets were 0.719, 0.698 and 0.693 (figure 2). Figure 3 illustrates the structural abnormalities best discriminating symptomatic knee OA.

## DISCUSSION

This large population-based study investigates which structural abnormalities as assessed on MRI discriminate



**Figure 1** Network graph illustrating the relation between the assessed structural abnormalities on different locations within the knee joint in the total NEO study population. Lines represent a relation between the presence of two abnormalities. BMLs, bone marrow lesions; NEO, the Netherlands Epidemiology of Obesity study.

symptomatic OA within the same knee best, taking co-occurrence of all structural abnormalities at different locations within the joint into account. In the entire study population, comprising individuals with and without symptomatic OA, structural abnormalities were highly frequent in the tibiofemoral and patellofemoral compartments, most prominent at the medial side. Presence of osteophytes and cartilage defects in different locations were related to each other. The structural abnormalities that discriminate best between individuals with and without symptomatic OA were general abnormalities as Baker's cysts and effusion, in addition to osteophytes and BMLs in the medial tibiofemoral compartment. In the patellofemoral joint, only osteophytes in the medial trochlear facet seemed of importance.

This is not the first study associating structural abnormalities with symptomatic knee OA or symptoms as pain, but it is the first one investigating this relationship involving structural abnormalities in all patellofemoral and tibiofemoral locations, using a model taking co-occurrence of all abnormalities into account.

Baker's cysts showed the highest regression coefficient for symptomatic OA. The relationship between Baker's cysts and OA symptoms has been assessed in a few studies that show conflicting results.<sup>11 19–21</sup> Baker's cysts have not been studied before to discriminate symptomatic OA. Inflammation seems to play a role in development of Baker's cysts since the presence and grade of synovial inflammation has been associated with Baker's cysts.<sup>22</sup> Although the grade of synovial inflammation has not been assessed in this study, since no contrast enhancement was used, effusion also discriminated symptomatic OA. The

prevalence of grade 2 or 3 Baker's cysts was 23% in individuals with symptomatic OA compared to 9% in those without. Perhaps, treatment of knee OA has to focus on prevention of development of Baker's cysts by treatment of synovial inflammation. Studies on treatment of Baker's cysts by steroid injections showed a significant reduction of symptoms after intra-articular infiltration, and even more after direct injection into the cyst.<sup>23 24</sup>

As described in a systematic review on structural abnormalities in relation to symptoms in OA, the discriminative role of effusion and BMLs found in this study is in accordance with the previous literature.<sup>14</sup> Osteophytes and cartilage defects do not show a clear relation with OA symptoms.<sup>14</sup> This study, taking co-occurrence of structural abnormalities into account, showed osteophytes especially in the medial tibiofemoral joint to discriminate symptomatic OA. Although a high prevalence of cartilage defects was observed, they were found to discriminate symptomatic OA less well. This can be understood when looking at the network graph presented in figure 1, showing relations between structural abnormalities that co-occur frequently within the total study population. Since cartilage defects co-occur frequently with osteophytes, only one of these abnormalities will discriminate symptomatic OA when taking this co-occurrence into account.

The Baker's cyst, found to discriminate individuals with symptomatic OA best, was not present in the network graph. This is probably due to the lower prevalence of Baker's cysts. Although Baker's cysts also co-occur with other abnormalities in the knee, they especially discriminate symptomatic OA.

**Table 3** Regression coefficients for presence of symptomatic knee OA as obtained by logistic ridge regression analyses

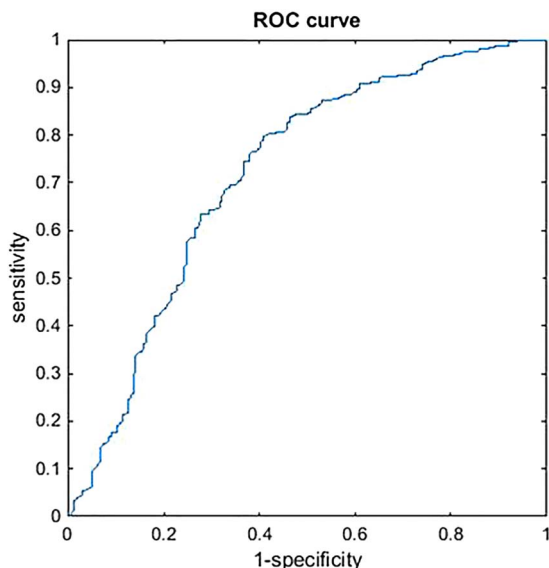
	Set 1	Set 2	Set 3	Mean coefficient
Baker's cyst	0.391	0.235	0.254	<b>0.293</b>
Effusion	0.255	0.220	0.116	<b>0.197</b>
<i>Tibiofemoral compartment:</i>				
Osteophytes				
Medial femoral condyle	0.184	0.205	0.166	<b>0.185</b>
Lateral femoral condyle	0.008	0.066	0.123	0.065
Medial tibial plateau	0.314	0.250	0.273	<b>0.279</b>
Lateral tibial plateau	0.019	0.081	0.149	0.083
Cartilage defects				
Medial femoral condyle	0.245	0.075	0.154	0.158
Lateral femoral condyle	0.038	0.074	0.130	0.081
Medial tibial plateau	-0.054	0.046	0.041	0.011
Lateral tibial plateau	-0.119	-0.028	-0.018	-0.055
Bone marrow lesions				
Medial femoral condyle	0.211	0.138	0.230	<b>0.193</b>
Lateral femoral condyle	0.003	0.013	-0.053	-0.012
Medial tibial plateau	0.101	0.179	0.283	<b>0.188</b>
Lateral tibial plateau	0.175	0.056	0.034	0.088
<i>Patellofemoral compartment:</i>				
Osteophytes				
Patellar crest	0.033	0.009	0.024	0.022
Medial patellar facet	0.135	0.170	0.124	0.143
Lateral patellar facet	0.158	0.037	0.099	0.098
Medial trochlear facet	0.275	0.258	0.252	<b>0.262</b>
Lateral trochlear facet	0.047	0.048	0.135	0.077
Cartilage defects				
Patellar crest	0.188	0.123	0.127	0.146
Medial patellar facet	0.184	0.133	0.011	0.109
Lateral patellar facet	0.073	0.095	0.120	0.096
Medial trochlear facet	0.078	0.117	0.021	0.072
Lateral trochlear facet	-0.035	0.105	0.020	0.030
Bone marrow lesions				
Patellar crest	0.070	0.179	0.149	0.133
Medial patellar facet	-0.077	-0.061	-0.097	-0.078
Lateral patellar facet	0.071	0.000	0.014	0.029
Medial trochlear facet	-0.026	-0.024	-0.062	-0.037
Lateral trochlear facet	0.016	0.039	-0.017	0.012
<i>Menisci:</i>				
Subluxation medial/lateral	0.053/0.050	0.035/-0.021	0.016/-0.021	0.035/0.003
Maceration medial/lateral	0.202/0.090	0.052/-0.013	0.070/0.109	0.108/0.062
Tear medial/lateral	0.004/0.092	0.009/0.014	0.050/0.034	0.021/0.047

The strongest mean regression coefficients for presence of symptomatic knee osteoarthritis (OA) are shown in bold typeface. All three sets include all individuals with symptomatic OA in the imaged knee and a random 1/3 of individuals without symptomatic OA.

Although research on knee OA has been focusing increasingly on the patellofemoral compartment during past years,<sup>1-3</sup> this study shows that most of the abnormalities discriminating symptomatic OA are general abnormalities (Baker's cysts and effusion) and structural abnormalities located within the medial tibiofemoral compartment. In the current literature on patellofemoral OA, it has been suggested that abnormalities in the patellofemoral compartment may represent an early stage of OA and precede tibiofemoral OA.<sup>25-27</sup> This is in contrast with the minor role of the patellofemoral compartment in discriminating symptomatic OA found in this study.

The strengths of this study are the size of the study population and extensive assessment of structural abnormalities using MRI and analyses accounting for the co-occurrence of abnormalities at different locations within the joint. Symptoms as pain, assessed by self-report, may be influenced by unknown determinants or causes other than OA. Moreover, we lacked information on medication taken by the participants. Therefore, we used symptomatic OA defined by highly sensitive and specific criteria<sup>10</sup> instead of only pain as the outcome measure.

Owing to the large number of individuals without symptomatic OA, the logistic ridge regression analyses



**Figure 2** ROC curve of one of the three analyses sets (set 1, AUC=0.7189). The ROC curves of set 2 and set 3 were comparable (AUC set 2=0.698, AUC set 3=0.693). AUC, area under the curve; ROC, receiver operating characteristic.

were performed in three sets of data, consisting of a random one-third of individuals without symptomatic OA in addition to the individuals with symptomatic OA. Analyses of these three sets prevent loss of information due to the high proportion of individuals without OA. Furthermore, abnormalities that were found to discriminate symptomatic OA in all three sets support the importance of especially these abnormalities. The AUC of the three analyses (around 0.7) showed that assessment of all structural abnormalities results in fair discrimination of symptomatic OA.<sup>28</sup>

Although there was an oversampling of persons with overweight or obesity in our study population, obesity is not likely to influence the results since adjustment for BMI did not alter the results. Chondrocalcinosis can

co-occur with OA,<sup>29</sup> which could result in pseudogout and pain. However, on MRI, chondrocalcinosis is not assessed and could therefore not be included in our analysis.

This study suggests that Baker's cysts discriminate symptomatic knee OA best, followed by effusion and structural abnormalities as osteophytes and BMLs, especially on the medial side of the tibiofemoral joint. More research is necessary to gain more insight into the precise underlying mechanisms; longitudinal research will be of help. The role of Baker's cysts especially in symptomatic OA may provide potential targets for treatment of knee OA.

#### Author affiliations

<sup>1</sup>Department of Rheumatology, Leiden University Medical Center, Leiden, The Netherlands

<sup>2</sup>Department of Medical Statistics and Bio-informatics, Leiden University Medical Center, Leiden, The Netherlands

<sup>3</sup>Department of Radiology, Leiden University Medical Center, Leiden, The Netherlands

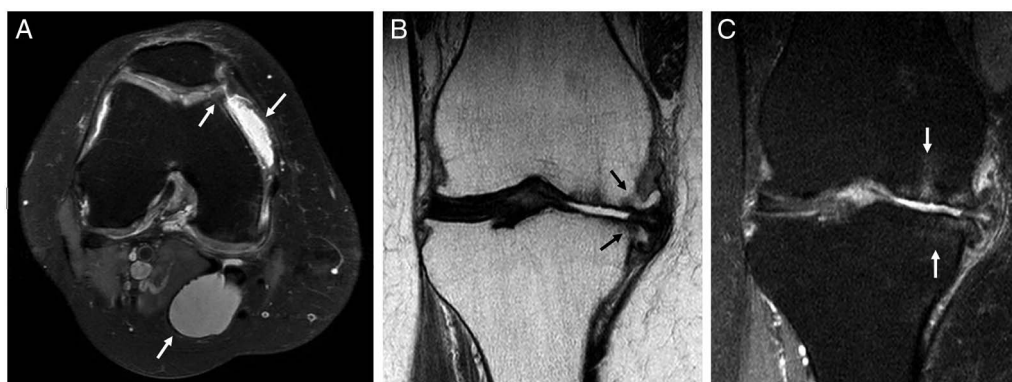<sup>4</sup>Department of Clinical Epidemiology, Leiden University Medical Center, Leiden, The Netherlands

<sup>5</sup>Department of Thrombosis and Homeostasis, Leiden University Medical Center, Leiden, The Netherlands

**Acknowledgements** The authors express their gratitude to all the individuals who participated in the Netherlands Epidemiology in Obesity study. The authors are grateful to all participating general practitioners for inviting eligible participants. The authors furthermore thank all research nurses for collection of data and I. de Jonge, MSc for all data management of the NEO study.

**Contributors** AWV performed the statistical analysis, interpreted the data and drafted the manuscript. BM performed the statistical analysis, interpreted the data and revised the manuscript for important intellectual content. MR, SLC and FRR participated in the study design and revised the manuscript for important intellectual content. MR and JLB contributed to the acquisition of data and revised the manuscript for important intellectual content. MK participated in the study design, was involved in analysing and interpreting the data and in drafting and revising the manuscript. All authors read and approved the final version of the manuscript.

**Funding** The NEO study is supported by the Dutch Arthritis Foundation (project number 10-1-309), the participating Departments, the Division and



**Figure 3** MRI in individuals with symptomatic knee osteoarthritis illustrating the structural abnormalities that discriminate symptomatic knee osteoarthritis best. (A) Axial fat suppressed proton density (PD) MRI showing a Baker's cyst, effusion and an osteophyte in the medial trochlear facet. (B) Coronal PD MRI showing osteophytes in the medial femoral condyle and medial tibial plateau. (C) Coronal fat suppressed PD MRI showing BMLs in the medial femoral condyle and medial tibial plateau. BML, bone marrow lesions.



the Board of Directors of the Leiden University Medical Center, and by the Leiden University, Research Profile Area 'Vascular and Regenerative Medicine'.

**Competing interests** None declared.

**Patient consent** Obtained.

**Ethics approval** Leiden University Medical Center.

**Provenance and peer review** Not commissioned; externally peer reviewed.

**Data sharing statement** No additional data are available.

**Open Access** This is an Open Access article distributed in accordance with the Creative Commons Attribution Non Commercial (CC BY-NC 4.0) license, which permits others to distribute, remix, adapt, build upon this work non-commercially, and license their derivative works on different terms, provided the original work is properly cited and the use is non-commercial. See: <http://creativecommons.org/licenses/by-nc/4.0/>

## REFERENCES

- Crossley KM, Hinman RS. The patellofemoral joint: the forgotten joint in knee osteoarthritis. *Osteoarthritis Cartilage* 2011;19:765–7.
- Stefanik JJ, Niu J, Gross KD, *et al*. Using magnetic resonance imaging to determine the compartmental prevalence of knee joint structural damage. *Osteoarthritis Cartilage* 2013;21:695–9.
- Peat G, Duncan RC, Wood LR, *et al*. Clinical features of symptomatic patellofemoral joint osteoarthritis. *Arthritis Res Ther* 2012;14:R63.
- Stefanik JJ, Neogi T, Niu J, *et al*. The diagnostic performance of anterior knee pain and activity-related pain in identifying knees with structural damage in the patellofemoral joint: the Multicenter Osteoarthritis Study. *J Rheumatol* 2014;41:1695–702.
- van Saase JL, van Romunde LK, Cats A, *et al*. Epidemiology of osteoarthritis: Zoetermeer survey. Comparison of radiological osteoarthritis in a Dutch population with that in 10 other populations. *Ann Rheum Dis* 1989;48:271–80.
- Beattie KA, Boulos P, Pui M, *et al*. Abnormalities identified in the knees of asymptomatic volunteers using peripheral magnetic resonance imaging. *Osteoarthritis Cartilage* 2005;13:181–6.
- Baranyay FJ, Wang Y, Wluka AE, *et al*. Association of bone marrow lesions with knee structures and risk factors for bone marrow lesions in the knees of clinically healthy, community-based adults. *Semin Arthritis Rheum* 2007;37:112–18.
- Guymer E, Baranyay F, Wluka AE, *et al*. A study of the prevalence and associations of subchondral bone marrow lesions in the knees of healthy, middle-aged women. *Osteoarthritis Cartilage* 2007;15:1437–42.
- Hayashi D, Felson DT, Niu J, *et al*. Pre-radiographic osteoarthritic changes are highly prevalent in the medial patella and medial posterior femur in older persons: Framingham OA study. *Osteoarthritis Cartilage* 2014;22:76–83.
- Altman R, Asch E, Bloch D, *et al*. Development of criteria for the classification and reporting of osteoarthritis. Classification of osteoarthritis of the knee. Diagnostic and Therapeutic Criteria Committee of the American Rheumatism Association. *Arthritis Rheum* 1986;29:1039–49.
- Kornaat PR, Bloem JL, Ceulemans RY, *et al*. Osteoarthritis of the knee: association between clinical features and MR imaging findings. *Radiology* 2006;239:811–17.
- Felson DT, Chaisson CE, Hill CL, *et al*. The association of bone marrow lesions with pain in knee osteoarthritis. *Ann Intern Med* 2001;134:541–9.
- Lo GH, McAlindon TE, Niu J, *et al*. Bone marrow lesions and joint effusion are strongly and independently associated with weight-bearing pain in knee osteoarthritis: data from the osteoarthritis initiative. *Osteoarthritis Cartilage* 2009;17:1562–9.
- Yusuf E, Kortekaas MC, Watt I, *et al*. Do knee abnormalities visualised on MRI explain knee pain in knee osteoarthritis? A systematic review. *Ann Rheum Dis* 2011;70:60–7.
- de Mutsert R, den Heijer M, Rabelink TJ, *et al*. The Netherlands Epidemiology of Obesity (NEO) study: study design and data collection. *Eur J Epidemiol* 2013;28:513–23.
- Kornaat PR, Ceulemans RY, Kroon HM, *et al*. MRI assessment of knee osteoarthritis: Knee Osteoarthritis Scoring System (KOSS)—inter-observer and intra-observer reproducibility of a compartment-based scoring system. *Skeletal Radiol* 2005;34:95–102.
- Hastie T, Tibshirani R, Friedman J. *The elements of statistical learning*. Springer, 2007.
- Mertens BJ, De Noo ME, Tollenaar RA, *et al*. Mass spectrometry proteomic diagnosis: enacting the double cross-validated paradigm. *J Comput Biol* 2006;13:1591–605.
- Guerhazi A, Hayashi D, Roemer FW, *et al*. Cyst-like lesions of the knee joint and their relation to incident knee pain and development of radiographic osteoarthritis: the MOST study. *Osteoarthritis Cartilage* 2010;18:1386–92.
- Hill CL, Gale DG, Chaisson CE, *et al*. Knee effusions, popliteal cysts, and synovial thickening: association with knee pain in osteoarthritis. *J Rheumatol* 2001;28:1330–7.
- Hill CL, Gale DR, Chaisson CE, *et al*. Periarticular lesions detected on magnetic resonance imaging: prevalence in knees with and without symptoms. *Arthritis Rheum* 2003;48:2836–44.
- Chatzopoulos D, Moralidis E, Markou P, *et al*. Baker's cysts in knees with chronic osteoarthritic pain: a clinical, ultrasonographic, radiographic and scintigraphic evaluation. *Rheumatol Int* 2008;29:141–6.
- Handy JR. Popliteal cysts in adults: a review. *Semin Arthritis Rheum* 2001;31:108–18.
- Bandinelli F, Fedi R, Generini S, *et al*. Longitudinal ultrasound and clinical follow-up of Baker's cysts injection with steroids in knee osteoarthritis. *Clin Rheumatol* 2012;31:727–31.
- Duncan R, Peat G, Thomas E, *et al*. Incidence, progression and sequence of development of radiographic knee osteoarthritis in a symptomatic population. *Ann Rheum Dis* 2011;70:1944–8.
- Schipf D, van Middelkoop M, de Klerk BM, *et al*. Crepitus is a first indication of patellofemoral osteoarthritis (and not of tibiofemoral osteoarthritis). *Osteoarthritis Cartilage* 2014;22:631–8.
- Lankhorst NE, Damen J, Oei EH, *et al*. Incidence, prevalence, natural course and prognosis of patellofemoral osteoarthritis: data of cohort hip and cohort knee study. *Osteoarthritis Cartilage* 2015: A42–3.
- Hanley JA. Receiver operating characteristic (ROC) methodology: the state of the art. *Crit Rev Diagn Imaging* 1989;29:307–35.
- Felson DT, Anderson JJ, Naimark A, *et al*. The prevalence of chondrocalcinosis in the elderly and its association with knee osteoarthritis: the Framingham Study. *J Rheumatol* 1989;16:1241–5.