

Received: 2016.02.10
Accepted: 2016.04.06
Published: 2016.06.17

ISSN 1941-5923
© Am J Case Rep, 2016; 17: 412-416
DOI: 10.12659/AJCR.897998

Inhibition of SA Node at Supine Position in Right Atrial Thrombus Complicating Behçet's Disease – From Cardiac Surgical Point of View

Authors' Contribution:
Study Design A
Data Collection B
Statistical Analysis C
Data Interpretation D
Manuscript Preparation E
Literature Search F
Funds Collection G

ABCDEFG **Emad Mohamed Hijazi**
F **Rasheed Khaled Ibdah**
F **Sukina Ismael Rawashdeh**
A **Abdullah Mahmoud Saadeh**
BF **Hamzeh Ibrahim Al-Balas**

Division of Cardiac Surgery and Cardiology, Princess Muna AL-Hussein Cardiac Center, King Abdullah University Hospital and Jordan University of Science and Technology, Irbid, Jordan

Corresponding Author: Emad Mohamed Hijazi, e-mail: emad_hijazi@hotmail.com, emhijazi@just.edu.jo
Conflict of interest: None declared

Patient: Female, 27
Final Diagnosis: Right atrial thrombus compressing the sinoatrial node
Symptoms: Dyspnea • cough and hemoptysis with supine bradycardia reaching 36/min and dizziness
Medication: —
Clinical Procedure: Cardiac surgical intervention removing the mechanical cause if conservative management failed can be done safely
Specialty: Surgery

Objective: Rare disease

Background: Behçet's disease (BD) is a chronic multi-systemic disease of unknown cause. Intra-cardiac thrombus (ICT) complicating BD is extremely rare. In general, cardiac manifestations in BD are associated with poor prognosis. Chest computed tomography (CT) scan and echocardiogram are excellent modalities for diagnosis and patient assessment. Cardiac surgical intervention can be done safely using an on-pump technique when medical management has failed.

Case Report: We report on a case of a 27-year-old Jordanian woman diagnosed with BD who presented with dyspnea, cough, and hemoptysis, with supine bradycardia reaching 36 beats/minute and dizziness which disappear on sitting or standing position, and with heart rate reaching 76 beats/minute. Right atrial thrombus was identified using transthoracic echocardiogram and chest CT scan. After medical management failed, cardiac surgical intervention became an option and targeted extraction of the right atrial thrombus compressing the sinoatrial node (SA node).

Conclusions: In BD, right atrial thrombus compressing the SA node is rare. If conservative management has failed, cardiac surgical intervention removing the mechanical cause can be done safely, either using on-pump with cross clamp or on-pump with beating heart technique.

MeSH Keywords: Arrhythmia, Sinus • Arrhythmias, Cardiac • Behçet Syndrome

Full-text PDF: <http://www.amjcaserep.com/abstract/index/idArt/897998>




1275



—



8



21



Background

Intra-cardiac thrombus (ICT) complicating Behçet's disease (BD) is extremely rare; only 50 cases have been registered worldwide [1–5]. In general, cardiac manifestations in BD include cardiomegaly, pericarditis, endocarditis, and rarely myocardial infarction and myocarditis [6,7]. These cardiac manifestations, which are indication of poor prognosis, have been reported to occur in about 1–5% of cases [8]. CT scan and echocardiogram are excellent modalities for diagnosis and patient assessment. Cardiac surgical intervention can be done safely using on-pump or off-pump techniques when medical management fails.

Case Report

A 27-year-old Jordanian woman, with a known diagnosis of BD and a negative history of smoking and oral contraceptive use, was doing well until one month prior to admission when she presented to the emergency department with dyspnea, cough, and a history of frequent hemoptysis 2–3 times daily of two weeks duration which had stopped spontaneously.

The cough was persistent throughout the day without any diurnal variation; at day of presentation, she also complained of fatigue, dizziness, nausea, tachypnea, and high grade fever.

Upon physical examination, the patient was unstable, with respiration rate (RR) of 24 cycles/minute, and heart rate (HR) of 25 bpm during supine position (Figure 1) which became 72 bpm at sitting position. Her blood pressure (BP) was 125/80 mm Hg. Her neck veins were distended with multiple superficial dilated veins over the chest wall and groin, but no other significant findings were observed.

Laboratory tests showed anemia (9 g/dL) and elevation of inflammatory parameters; C reactive protein concentration (CRP) was 96 mg/L (normal is <6 mg/L), negative markers of myocardial necrosis, but D-dimers were 3 µg/mL (reference value <0.5 µg/mL) with normal liver and kidney function.

The patient was being followed by a chest physician and a rheumatologist with experience in diagnosis of complicated BD with pulmonary involvement, such as pulmonary artery aneurysms, pulmonary thromboembolism, and superior vena cava thrombosis.

The new presenting event was severe supine bradycardia, which disappear during standing or semi-sitting position. The cardiologist was consulted and the patient was put on conservative management including colchicine, corticosteroids, immunosuppressive agents, anticoagulant heparin (heparin conservative management started with 5,000 IU IV bolus, followed

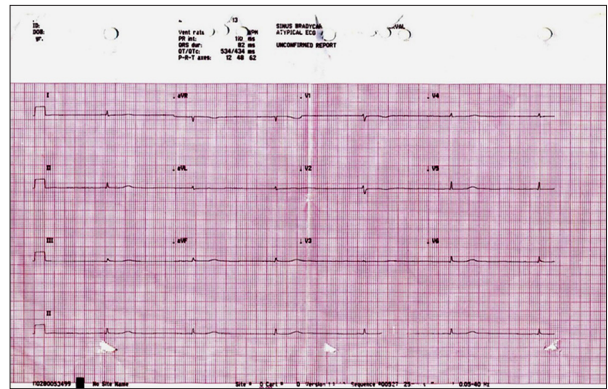


Figure 1. ECG pre-operative: severe bradycardia.

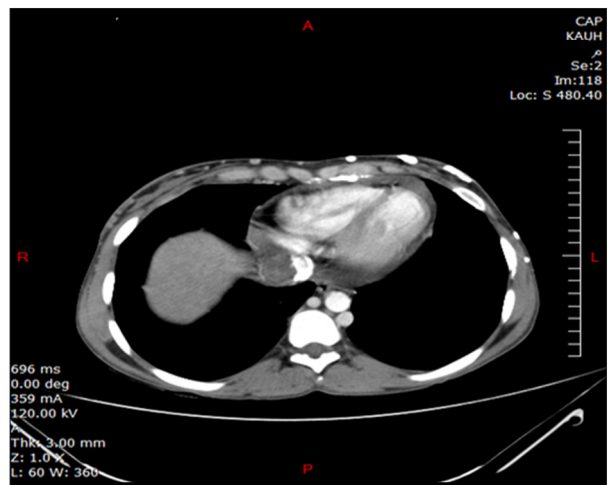


Figure 2. CT scan pre-operative: large right atrial thrombus.

by continuous infusion (18 IU/kg/hour) to maintain a PTT of 50–70 seconds) and low dose aspirin. Chest x-ray demonstrated hilar enlargement. Transthoracic echocardiography, done by an expert cardiologist, showed a mass (3x4 cm) filling the right atrium. A CT scan was done and showed a large right atrium thrombus and thickened atrium (Figure 2). The cardiologist initially started two weeks of conservative management and recommend continuation of anticoagulation and starting thrombolytic therapy (streptokinase loading dose 250,000 U/30 minute followed by 100,000 U/hour for 24 hours) which resulted in no observable benefit regarding resolution of the thrombus or the bradycardia. The patient developed significant hemoptysis so medical treatment was stopped and the consensus for treatment was surgical excision. Histopathologic confirmation of the diagnosis was agreed upon by the cardiologist and the cardiac surgeon.

The patient provided consent to publish her case but without any photos of her body showing dilated superficial veins over the chest wall and groin. Unfortunately, a technical record error occurred resulting in the loss of the echocardiogram video.

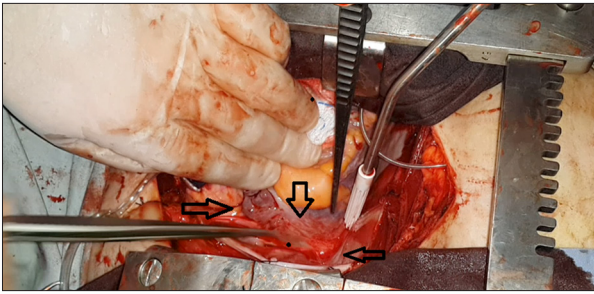


Figure 3. Right arrow shows thrombosed inferior vena cava (cord like); left arrow shows thrombosed superior vena cava (cord like); middle arrow shows small thickened right atrium.

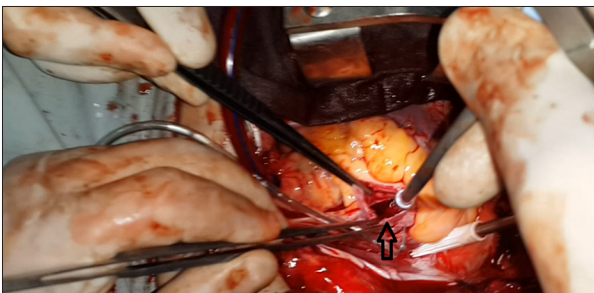


Figure 4. Arrow shows opened right atrial appendage, pump suction inside.

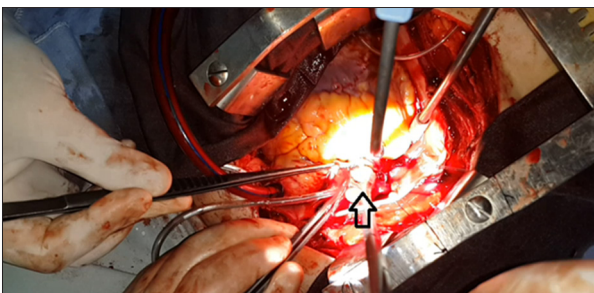


Figure 5. Arrow shows the floating mass after mobilization from within tricuspid valve by surgeon finger, cached by ovum forceps.

Surgical procedure

Classical on-pump open-heart surgery with cross clamp could not be carried out because the subclavian, femoral veins, and superior and inferior vena cavae were thrombosed. We instead used on-pump beating heart technique. The HR was 32 bpm on the operating table.

The sternum was opened, heparinization was as usual for the possibility of cannulation on-pump techniques. Unfortunately, the superior and inferior vena cavae were thrombosed and cord like, the right atrium was small due to thickened wall and organized thrombus (Figure 3). Aortic cannula was inserted, but the venous cannula failed to fit inside the atrium down to

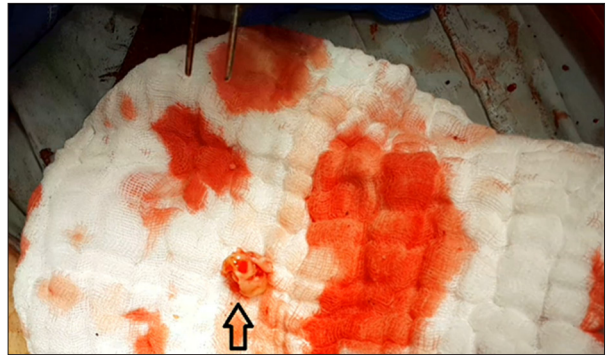

Figure 6. Arrow shows mass after extraction.

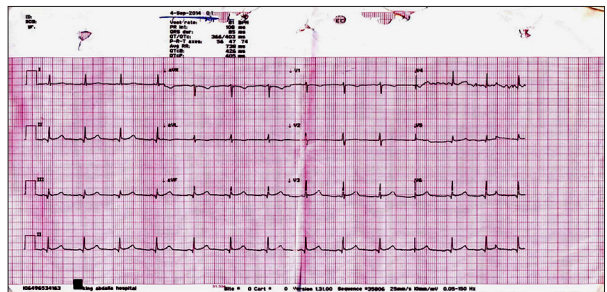


Figure 7. Post-operative supine position ECG.

inferior vena cava due to a small right atrial cavity and thrombosed inferior vena cava, so the venous cannula was taken out and two pump suctions were used to return the venous blood from inside the right atrium and from outside (mediastinum) to the heart-lung machine. This enabled us to look at the inside of the atrium, however, we could not see the thrombus (Figure 4). We then used an on-pump beating heart technique for as short a procedure as possible; a forefinger was inserted into the right atrium through the opened right atrial appendage, which was controlled by an appendage bursting suture. The thrombus was mobilized and floated up to the opening of the appendage, becoming visible at this stage, and preventing the atrial venous blood from coming outside when the bursting suture was released. The thrombus was extracted using ovum forceps through the right atrium opened appendage (Figures 5, 6). Immediately the HR went to 72 bpm (Figure 7). Post-operative, the patient was hemodynamic stable with no inotrope administered in the cardiac intensive care unit, and the patient was discharged home on the seventh day. A CT scan done one-week post-surgery showed absence of the previous mass (Figure 8). The histopathology report noted organized thrombus.

During follow up at 4, 8, and 12 weeks post-surgery, the patient was seen in the cardiology clinic where her BD was stable, with BP 130/80 mmHg, and HR was stable between 70–85 bpm. The patient was asymptomatic regarding positional dizziness and shortness of breath.

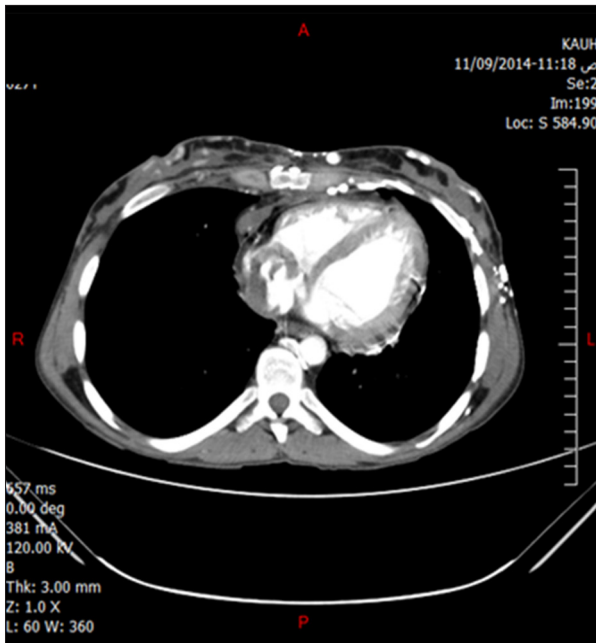


Figure 8. CT Post-operative.

Discussion

Intra-cardiac thrombus (ICT) usually is located in the right side of the heart, and most commonly affects the right ventricle, but ICT located in the left ventricle or affecting both ventricles has also been described [1,9–12].

It is believed that the pathogenesis of the thrombotic formation in patients with BD is due to endothelial cell ischemia or disruption that leads to enhancement of platelet aggregation; other possible pathogenic mechanisms, which affect approximately 18% of cases, is due to the presence of anti-phospholipid antibodies [13–15].

ICT has also been frequently associated with superficial thrombophlebitis and deep venous thrombosis [3,16,17] or thrombosis of vena cava [9].

It has been speculated that pulmonary embolism or pulmonary infarction might have originated from deep vein thrombosis or

right ventricular thrombi [12,18–20]. Pulmonary vascular manifestations are a result of *in situ* pulmonary pathology rather than embolization from systemic veins [1].

In our case, the complication of BD was diagnosed by echocardiography and CT scan followed by an intraoperative excisional biopsy removing the mechanical complication.

While conformation of the diagnosis is determined either at necropsy or after surgery, CT scan and MRI are considered an important tool in the diagnosis and assessment of a patient condition and might show vascular complications and give more information about lung parenchyma [21].

Although medical management has been associated with a better outcome, surgical removal has the advantage of providing material for histological examination [21].

Both anticoagulants and thrombolytic are considered first-line medical treatment of ICT [1], but in the presence of pulmonary aneurysms this therapy might lead to fatal hemoptysis, especially in bilateral and large aneurysms.

Right atrial thrombus is extremely rare, and our review the literature did not find reported case of right atrial thrombus that comprised the SA node causing positional bradycardia.

Conclusions

We conclude that thrombi in the right atrium of the heart can be present as an extremely rare case in BD, causing compression of SA node or a mechanical filling defect. Echocardiogram and CT scan are considered important tools in the diagnosis of these condition.

Cardiac surgical intervention should be considered in cases where medical treatment has failed to dissolve the thrombus, and surgery can be done safely using on-pump technique with cross clamp and cardiac arrest or on-pump technique with beating heart. This intervention can provide material for histological examination and confirmation of diagnosis.

References:

1. Mogulkoc N, Burgess MI, Bishop PW: Intracardiac thrombus in Behçet's disease. A systematic review. *Chest*, 2000;118: 479–87
2. Yochida S, Fujimori K, Hareyama M, Nakata T: Cardiac thrombus in Behçet's disease. *Chest*, 2001; 120: 688–89
3. Duzgun N, Anil C, Ozer F, Acican T: The disappearance of pulmonary artery aneurysms and intracardiac thrombus with immunosuppressive treatment in a patient with Behçet's disease. *Clin Exp Rheumatol*, 2002; 20: S56–57
4. Kaya A, Ertan C, Gurkan OU et al: Behçet's disease with right ventricle thrombus and bilateral artery aneurysms: A case report. *Angiology*, 2004; 55: 573–75
5. Ben Ghorbel I, Ibn Elhadj Z, Khanfir M et al: Intracardiac thrombus in Behçet's disease. A report of three cases. *J Mal Vasc*, 2004; 29: 159–61
6. BayKan M, Celik S, Erdol C et al: Behçet's disease with a large intracardiac thrombus: A case report. *Heart*, 2001; 85: E7
7. Le Thi Huong D, Wechsler B, Papo T et al: Endomyocardial fibrosis in Behçet's disease. *Ann Reum Dis*, 1997; 56: 205–8
8. Wechsler B, Du LT, Kieffer E: Cardiovascular manifestations of Behçet's disease. *Ann Med Interne*, 1999; 150: 542–54

9. Kajiya T, Anan R, Kameko M, Mizukami N et al: Intracardiac thrombus, superior vena cava syndrome, and pulmonary embolism in a patient with Behçet's disease: A case report and literature review. *Heart Vessels*, 2007; 22(4): 278-83
10. Hiwarkar P, Stasi R, Sutherland G, Shannon M: Deep vein and intracardiac thrombosis during the post-partum period in Behçet's disease. *Int J Hematol*, 2010; 91(4): 679-86
11. Seyahi E, Melikoglu M, Akman C et al: Pulmonary artery involvement and associated lung disease in Behçet disease: a series of 47 patients. *Medicine (Baltimore)*, 2012; 91(1): 35-48
12. Hammami R, Abid L, Frikha F et al: Intracardiac thrombus in young man: Don't forget Behçet's disease. *Intern Med*, 2012; 51(14): 1865-67
13. Schmitz-Huebner U, Knop J: Evidence for an endothelial cell dysfunction in association with Behçet's disease. *Thromb Res*, 1984; 34: 277-85
14. Hull RG, Harris EN, Gharavi AE et al: Anticardiolipin antibodies: Occurrence in Behçet's syndrome. *Ann Rheum Dis*, 1984; 43: 746-48
15. Harmouche H, Tazi Mezalek Z, Adnaoui M et al: Association of pulmonary artery aneurysm, right heart thromboses and antiphospholipid antibodies in Behçet's disease. *Rev Med Interne*, 1998;19: 512-15
16. Fekih M, Fennira S, Ghodhbane L, Zaouali RM: Intracardiac thrombosis: On uncommon complication of Behçet's disease. *Tunisie Medicale*, 2004; 82(8): 785-90
17. Piga M, Puchades F, Mayo I, D'Cruz D: Successful thrombolytic therapy for recurrent right ventricular thrombosis in Behçet's disease. *Clin Exp Rheumatol*, 2010; 28(4, Suppl. 60): 576-78
18. Louali FE, Tamdy A, Soufiani A et al: Cardiac thrombosis as a manifestation of Behçet syndrome. *Tex Heart Inst J*, 2010; 37(5): 568-71
19. Yasuo M, Nagano S, Yazaki Y et al: Pulmonary embolism due to right ventricular thrombus in a case of Behçet's disease. *Jpn Circ Soc*, 1999; 63(11): 909-11
20. Goktekin O, Korkmaz C, Timuralp B et al: Widespread thrombosis associated with recurrent intracardiac thrombus in a patient with Behçet's disease. *Int J Cardiovasc Imaging*, 2002; 18(6): 431-34
21. Hammami S, Mahjoub S, Ben-Hamda K et al: Intracardiac thrombus in Behçet's disease: Two case reports. *Thromb J*, 2005; 3: 9