

# Very late stent expansion with intracoronary lithotripsy: a case report

Andrea Demarchi \*, Fabrizio Ugo , Chiara Cavallino, and Francesco Rametta

Division of Cardiology, S. Andrea Hospital, Corso Mario Abbiate 21, 13100 Vercelli, Italy

Received 11 February 2020; first decision 3 April 2020; accepted 25 June 2020; online publish-ahead-of-print 17 October 2020

## Background

Underexpanded stent in heavily calcified coronary lesion is common and persists over years. It is related to long-term failure and negative outcomes. Treatment of this situation after many years with intracoronary lithotripsy (ICL-Shockwave<sup>®</sup>) could be an option.

## Case summary

We report a case of a man with underexpanded coronary stent implanted 11 years earlier. Optical coherence tomography highlighted the mechanism of stent underexpansion showing the presence of calcium stones under the old struts. Intracoronary lithotripsy crushed calcium under the stent struts causing its geometric change (from elliptical to round shape) and a consequent better transmission of the true radial force of the old stent.

## Discussion

Heavily calcified coronary lesions lead to stent underexpansion which persists over years. Intracoronary lithotripsy could be a very late option to manage this unfavourable common result.

## Keywords

Coronary intervention • Lithotripsy • Underexpanded stent • Angioplasty • Case report

## Learning points

- Percutaneous treatment of calcified coronary lesions requires dedicated devices.
- Intracoronary lithotripsy could be an option to correct underexpanded stents.
- Intravascular imaging is very useful in-stent failure. New technologies like optical coherence tomography co-registration are crucial to detect site and mechanisms of failure.
- The crushing of calcium under stent struts permits transmission of the true radial force of stent implanted many years earlier.

## Introduction

Treatment of heavily calcified coronary lesions remains challenging. For many years, the strategies to manage these situations have been cutting and scoring balloons, high pressure balloons and rotational atherectomy.<sup>1,2</sup> Also post-dilatation with non-compliant balloons

could fail. The resulting underexpanded stent is related to long-term failure and negative outcomes.<sup>3</sup> Intracoronary lithotripsy (ICL-Shockwave<sup>®</sup>) is a new option for these issues. Intracoronary lithotripsy has been designed for preparation of calcified lesions, but its use after the stent implantation remains uncertain.<sup>4–6</sup> We report a case of a patient admitted at our department after positive stress

\*Corresponding author. Email: [demaki@virgilio.it](mailto:demaki@virgilio.it)

Handling Editor: Pierre Deharo

Peer-reviewers: Elad Asher and Magdy Abdelhamid

Compliance Editor: Stefan Simovic

Supplementary Material Editor: Peysh A Patel

© The Author(s) 2020. Published by Oxford University Press on behalf of the European Society of Cardiology.

This is an Open Access article distributed under the terms of the Creative Commons Attribution Non-Commercial License (<http://creativecommons.org/licenses/by-nc/4.0/>), which permits non-commercial re-use, distribution, and reproduction in any medium, provided the original work is properly cited. For commercial re-use, please contact [journals.permissions@oup.com](mailto:journals.permissions@oup.com)

test. Coronary angiography showed severe in-stent restenosis on ostial left anterior descending (LAD) and development of severe atherosclerosis in the intermediate portion of native vessel. Optical coherence tomography (OCT-Abbott<sup>®</sup>) highlighted struts underexpansion in the middle of the old stent. Intracoronary lithotripsy caused calcium micro-fractures under the stent struts with final good expansion.

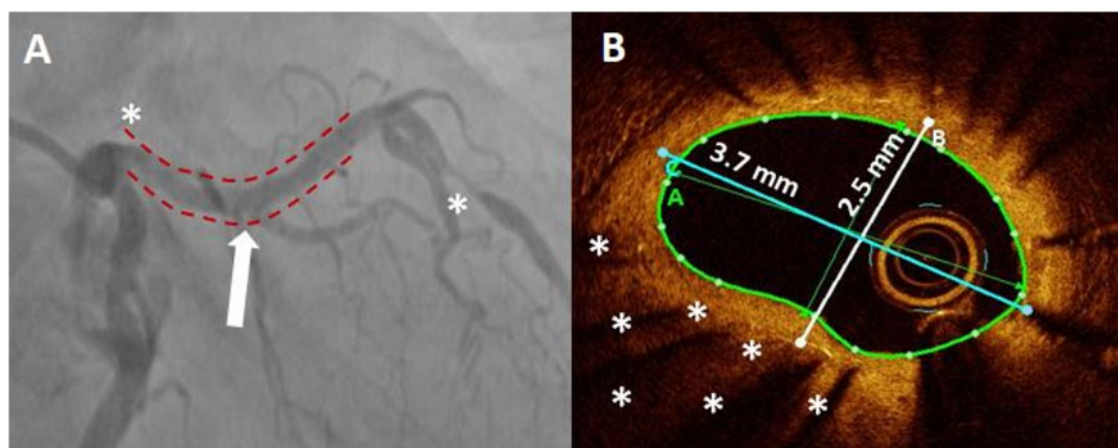
## Timeline

2008	Drug-eluting stent implantation on proximal left anterior descending for angina
2019	Underexpansion of the old stent and development of atherosclerosis
	Optical tomography coherence confirms under expansion and its mechanism
	Intracoronary lithotripsy inside the old stent is performed causing its geometric change and a consequent better transmission of the true radial force

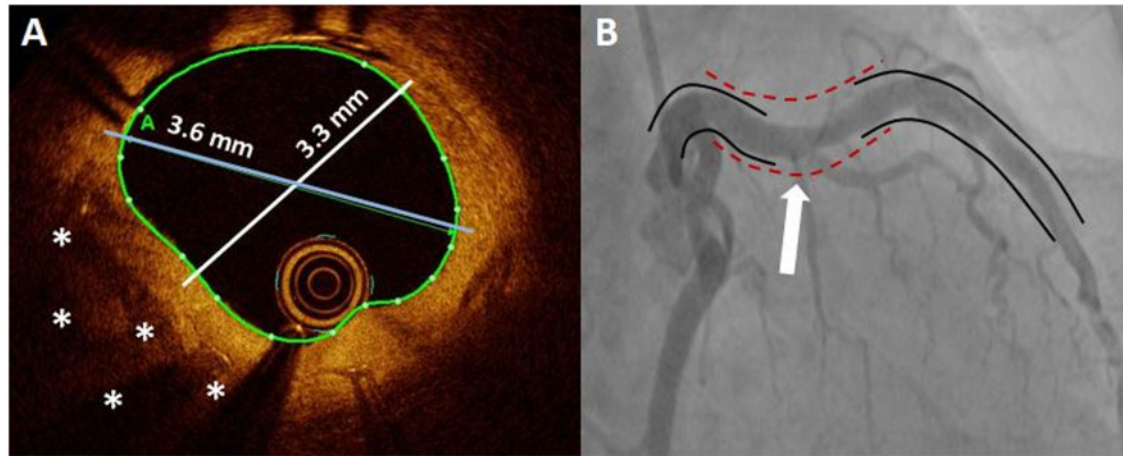
## Case presentation

An 83-year-old male with hypertension, dyslipidaemia, former smoker was admitted at our division after a positive stress test. Eleven years before, he underwent drug-eluting stent implantation in ostial-proximal LAD [sirolimus-eluting stent (SES) 3.5/28 mm] for angina symptoms. The cardiovascular and respiratory examinations

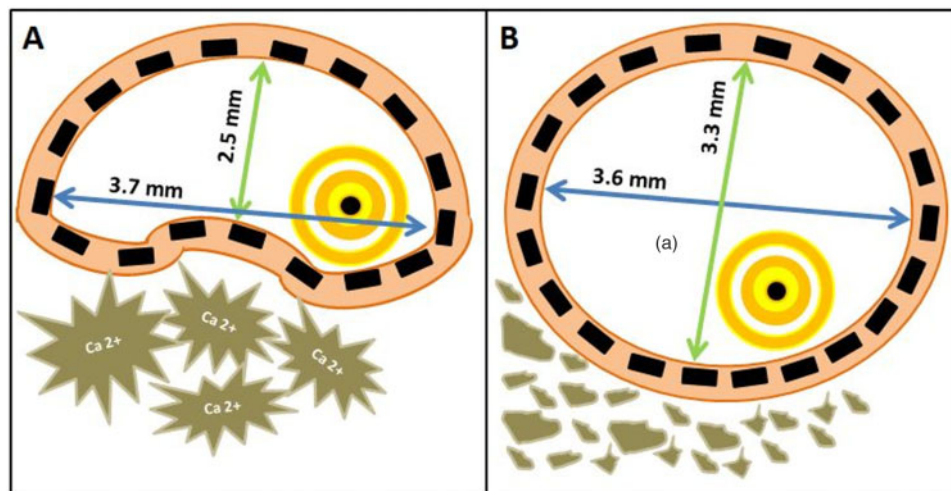
on admission were normal. Blood pressure was 130/80 mmHg, electrocardiogram showed regular heart rate of 65 b.p.m. First-line blood test was normal. His medical therapy on admission was: aspirin 100 mg/day, ramipril 2.5 mg/day, bisoprolol 1.25 mg/day, and simvastatin 20 mg/day. Coronary angiography showed severe ostial in-stent restenosis and atherosclerotic progression in mid-LAD (*Figure 1A*, [Supplementary material online, Video S1](#)). By 6-Fr radial approach, two SESs (SES 2.75/12 mm + SES 3.0/28 mm) were implanted in mid-distal portion of LAD overlapping the distal portion of the old stent. The OCT was subsequently performed confirming the good apposition of new stents and the severe in-stent neo-atherosclerosis in ostial LAD (*Figure 1B*). Real-time co-registration highlighted diffuse calcifications under the central portion of the old stent struts that have led to underexpansion [minimal lumen area (MLA) 4.1 mm<sup>2</sup>, *Figure 1B*, [Supplementary material online, Video S2](#)]. Multiple prolonged inflations in underexpanded site with non-compliant balloon were performed (3.5/20 mm + 3.5/12 mm at 28 atm for 30 s). Hourglass images persisted during all inflations. Therefore, four cycles of 10 impulses of ICL were performed (4.0/12 mm balloon inflated at 6 atm). Better expansion of non-compliant balloons was obtained. Provisional stenting in left main bifurcation with one-stent crossover into LAD (SES 4.0/18 mm) was followed by non-compliant balloon post-dilatations (4.0/15 mm + 5.0/12 mm). Final OCT scan showed the crushed calcium under the old struts (*Figure 2A*, [Supplementary material online, Video S3](#)) confirming the good angiographic result (MLA 6.81 mm<sup>2</sup>, *Figure 2B*, [Supplementary material online, Video S4](#)). Geometric change of the old stent, from elliptical to a round shape, was highlighted by OCT analysis (*Figure 3*). No major complications during the procedure or hospitalization occurred. Dual antiplatelet therapy with clopidogrel and aspirin was prescribed for 6 months. At 1 year of follow-up, the patient was free of angina and on good clinical status.



**Figure 1** (A) Basal angiogram. Sub-occlusive stenosis in the mid part of left anterior descending and severe in-stent restenosis on ostial left anterior descending (asterisks). Full arrow points underexpanded struts of the old stent (dashed line). (B) Pre-lithotripsy optical coherence tomography scan (frame position is pointed by full arrow in A). Elliptical-shape underexpanded stent (MLA 4.1 mm<sup>2</sup>) with calcium stones under the struts (asterisks).



**Figure 2** (A) Post-lithotripsy optical coherence tomography scan (frame position is pointed by full arrow in B). Round-shape expansion of the old stent (MLA  $6.81 \text{ mm}^2$ ) with crushed calcium under the struts (asterisks). (B) Final angiogram. New stents (continuous lines) partially overlapped with the old stent (dashed line).



**Figure 3** (A) Basal calcium distribution and stent size. (B) Crushed calcium and geometric change after lithotripsy.

## Discussion

Percutaneous treatment of calcified coronary lesions is challenging. Evidences suggest an optimal lesion preparation before stent implantation. This has been obtained for many years with cutting and scoring balloons or rotational atherectomy.<sup>1,2</sup> Underutilization of these techniques has led to the current evidence of underexpanded stents.<sup>3</sup>

Anecdotal reports propose the treatment of these situations with atherectomy of the stent.<sup>7,8</sup> Intracoronary lithotripsy is a new technique based on calcium rupture by ultrasound waves.<sup>4</sup> Recent reports support the use of ICL as bail-out therapy for underexpanded stents.<sup>9,10</sup>

Although little is known about the effect of ICL on stents implanted recently, even less is known about its utilization on stents implanted many years earlier.

Intravascular imaging is very useful in these situations. New technologies like OCT co-registration are crucial to detect the site and the mechanisms of stent failure.<sup>2</sup>

In our case, the OCT permitted to describe the mechanism of stent underexpansion showing the presence of calcium stones under the old struts. Intravascular measurements were useful to predict the deliverability and balloon size of ICL device.

Its recommended to maintain 1:1 ratio between ICL balloon and vessel diameter.<sup>2</sup> Reassured by the presence of old supportive struts, we decided to perform ICL with a higher ratio (ICL balloon of 4.0 mm in a vessel medium diameter of 3.5 mm, 1.15:1 ratio).

Intracoronary lithotripsy acted in-stent underexpanded part causing its geometric change (from elliptical to round shape) and a

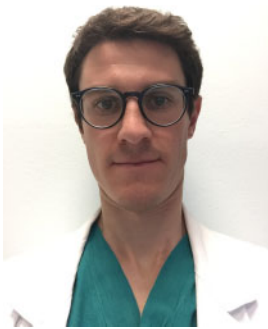consequent better transmission of the true radial force of stent implanted 11 years before.

The circumferential stent expansion significantly improved after ICL (stent symmetry index: pre 0.67 vs. post 0.91).

## Conclusion

Percutaneous treatment of heavily calcified coronary lesions remains challenging. Late failure due to stent underexpansion and malapposition is common. Intravascular imaging is crucial to detect the site and the mechanisms of the stent failure. Intracoronary lithotripsy in underexpanded stents implanted many years before is safe and effective. Intracoronary lithotripsy is able to crush calcium stone under the stent struts. Interventional cardiologists should keep in mind this new device and approach to manage complex coronary interventions.

## Lead author biography



Andrea Demarchi, MD, was born in 1986 in Italy. He completed his School of Medicine at University of Pavia in 2011. He started his activity as interventional cardiologist in 2015. Specialized in Cardiology at University of Pavia on 2017 with a thesis 'Acute Coronary Syndrome in patients with previous CABG: treatment and long term prognosis'. His professional training in interventional cardiology passed through University of Pavia, Legnano and Crema

Hospital, Polyclinic of Monza. At present, he is a MD at Cardiology in S. Andrea Hospital, Vercelli.

## Supplementary material

[Supplementary material](#) is available at *European Heart Journal - Case Reports* online.

**Slide sets:** A fully edited slide set detailing this case and suitable for local presentation is available online as [Supplementary data](#).

**Consent:** The author/s confirm that written consent for submission and publication of this case report including image(s) and associated text has been obtained from the patient in line with COPE guidelines.

**Conflict of interest:** none declared.

## References

1. Barbato E, Shlofmitz E, Milkas A, Shlofmitz R, Azzalini L, Colombo A. State of the art: evolving concepts in the treatment of heavily calcified and undilatable coronary stenoses from debulking to plaque modification, a 40-year-long journey. *EuroIntervention* 2017;**13**:696–705.
2. Kassimis G, Raina T, Kontogiannis N, Patri G, Abramik J, Zaphiriou A et al. How should we treat heavily calcified coronary artery disease in contemporary practice? From atherectomy to intravascular lithotripsy. *Cardiovasc Revasc Med* 2019; **20**:1172–1183.
3. Gènèreux P, Madhavan MV, Mintz GS, Maehara A, Palmerini T, LaSalle L et al. Ischemic outcomes after coronary intervention of calcified vessels in acute coronary syndromes. Pooled analysis from the HORIZONS-AMI (Harmonizing Outcomes With Revascularization and Stents in Acute Myocardial Infarction) and ACUITY (Acute Catheterization and Urgent Intervention Triage Strategy) TRIALS. *J Am Coll Cardiol* 2014;**63**:1845–1854.
4. Wong B, El-Jack S, Newcombe R, Glenie T, Armstrong G, Khan A. Shockwave intravascular lithotripsy for calcified coronary lesions: first real-world experience. *J Invasive Cardiol* 2019;**31**:46–48.
5. La Manna A, D'Agosta G, Venuti G, Tamburino C. Cracking the plaque with coronary lithotripsy: mechanistic insights from optical coherence tomography. *J Invasive Cardiol* 2020;**32**:E14.
6. Yeoh J, Cottens D, Cosgrove C, Mallek K, Strange J, Anderson R et al. Management of stent underexpansion using intravascular lithotripsy—defining the utility of a novel device. *Catheter Cardiovasc Interv* 2020;doi: 10.1002/ccd.28715.
7. Ferri LA, Jabbar RJ, Giannini F, Benincasa S, Ancona M, Regazzoli D, Mangieri A, Montorfano M, Colombo A, Latib A. Safety and efficacy of rotational atherectomy for the treatment of undilatable underexpanded stents implanted in calcific lesions. *Cathet Cardiovasc Intervent* 2017;**90**:E19–E24.
8. Whiteside H, Nagabandi A, Kapoor D. Safety and efficacy of stentablation with rotational atherectomy for the management of underexpanded and undilatable coronary stents. *Cardiovasc Revasc Med* 2019;**20**:985–989.
9. Tumminello G, Cavallino C, Demarchi A, Rametta F. Bail-out unexpanded stent implantation in acute left main dissection treated with intra coronary lithotripsy: a case report. *Eur Heart J Case Rep* 2019;**3**:1–5.
10. Watkins S, Good R, Hill J, Brinton TJ, Oldroyd KG. Intravascular lithotripsy to treat a severely underexpanded coronary stent. *EuroIntervention* 2019;**5**:124–125.