

Outcomes in colorectal endoscopic submucosal dissection for large protruded lesions: A retrospective multicenter study

OPEN
ACCESS

Authors

Hideyuki Chiba¹, Ken Ohata², Akimichi Hayashi¹, Yu Ebisawa¹, Mikio Kobayashi¹, Jun Arimoto¹, Hiroki Kuwabara¹, Yohei Minato², Michiko Nakaoka¹

Institutions

- 1 Gastroenterology, Omori Red Cross Hospital, Ota-Ku, Japan
- 2 Gastroenterology, NTT Medical Center Tokyo, Shinagawa-ku, Japan

Keywords

Endoscopy Lower GI Tract, Colorectal cancer, Endoscopic resection (polypectomy, ESD, EMRc, ...), Diagnosis and imaging (inc chromoendoscopy, NBI, iSCAN, FICE, CLE...), Polyps / adenomas / ...

received 8.1.2024

accepted after revision 19.4.2024

accepted manuscript online 29.4.2024

Bibliography

Endosc Int Open 2024; 12: E757–E763

DOI 10.1055/a-2316-7755

ISSN 2364-3722

© 2024. The Author(s).

This is an open access article published by Thieme under the terms of the Creative Commons Attribution-NonDerivative-NonCommercial License, permitting copying and reproduction so long as the original work is given appropriate credit. Contents may not be used for commercial purposes, or adapted, remixed, transformed or built upon. (<https://creativecommons.org/licenses/by-nc-nd/4.0/>)

Georg Thieme Verlag KG, Rüdigerstraße 14,
70469 Stuttgart, Germany

Corresponding author

Dr. Hideyuki Chiba, Omori Red Cross Hospital,
Gastroenterology, 4-30-1, Chuo, 1438527 Ota-Ku, Japan
h.chiba04@gmail.com

ABSTRACT

Background and study aims Colorectal endoscopic submucosal dissection (ESD) is increasingly used for treating early-stage colorectal cancer, including large, protruded lesions (LPL). However, the challenges posed by LPLs, especially those accompanied by severe fibrosis or muscle-retracting sign (MRS), remain unclear. This study aims to investigate ESD outcomes for LPL, focusing on factors such as tumor size and, submucosal fibrosis.

Patients and methods In a multicenter retrospective study (June 2012 to May 2023), data from 526 patients with 542 LPL lesions (≥ 2 cm) were analyzed. Parameters included lesion size, procedure time, dissection speed, physician experience, submucosal fibrosis, and adverse events. The tunnel method, including the double tunnel method, was used for cases with severe fibrosis or MRS. Multivariate analysis assessed factors affecting procedure difficulty, particularly LPLs ≥ 4 cm.

Results The study revealed an impressive en bloc resection rate of 97.8% and a curative resection rate of 78.6% for LPLs. Notably, fibrosis and MRS were present in 25% and 18% of 4-cm LPLs, respectively, and their frequency tended to increase as the tumor diameter increased. One treatment strategy for LPLs was the tunneling method, which was used most frequently (41 cases, 7.6%). Factors affecting dissection speed included larger tumor size, submucosal fibrosis, MRS, and physician experience.

Conclusions Treating LPLs through colorectal ESD presents significant challenges, especially in patients with fibrosis and MRS. This study highlights the importance of recognizing these complexities, and that more reliable resection strategy must be established for accurate pathological evaluation

Introduction

Colorectal endoscopic submucosal dissection (ESD) has become a popular treatment for early-stage colorectal cancer, with recent reports from Western countries as well as Japan

and Asian countries [1, 2, 3]. Because of developments in treatment strategies, endoscopic devices, and endoscopic equipment, ESD is now aggressively performed for large and fibrotic lesions [4, 5, 6]. However, it is still difficult to overcome challenges in all cases, especially in the colon, where the bends and

folds can make a stable approach to the tumor difficult, and when the tumor is accompanied by severe fibrosis or muscle-retracting sign (MRS). In such cases, the procedure may have to be interrupted [7, 8, 9]. Large, protruded lesions are among the most difficult cases to treat, which is well known, but their clinical characteristics, size at which fibrosis and MRS appear, and frequency of curative resection have not been clarified. For large, protruded lesions (0-Is in the Paris classification [10]) with MRS, there are currently no established strategies, although a few case reports have been published about strategies such as the double tunnel method (DTM) [11] and the pocket creation method (PC) [12].

Therefore, the aim of this study was to examine results of large, protruded lesion (LPL) treatment, excluding pedunculated lesions (0-Ip in the Paris classification [10]), and factors that make them difficult to treat,

Patients and methods

This was a multicenter, observational, retrospective study, which included all LPLs ≥ 2 cm resected by ESD from June 2012 to May 2023 at Omori Red Cross Hospital and one affiliate hospital (NTT Medical Center Tokyo). To consider only pure protruded lesions in this study, all non-polypoid lesions including laterally spreading tumors and all 0-Ip (in the Paris classification) lesions were excluded from this study. Diagnostic colonoscopy with image-enhanced endoscopy was used to identify indications for ESD in all cases. Among the protruded lesions, if a tumor was accompanied by an obvious expanded change with white light imaging or deep depressed surfaces, or if it was clearly Vi high or VN irregular with magnifying endoscopy, it was diagnosed as submucosal (SM) invasive carcinoma (T1b; submucosal infiltration depth >1000 μm) and was not an indication for ESD [13]. Moreover, inflammatory elevated lesions (e.g., mucosal prolapse syndrome), post-endoscopic treatment recurrent elevated lesions, subepithelial lesions, and other cases of interrupted endoscopic treatment, such as endoscopic mucosal resection (EMR), were not considered pure LPLs and were also excluded from the present study.

All ESDs were planned according to Japanese guidelines for ESD and EMR of colorectal cancer [14]. Antithrombotic and anticoagulant agents were stopped before the procedure in accordance with current guidelines [15].

ESD procedure

Colorectal ESD was performed using a single-channel endoscope (PCF-Q260J, GIF-Q260J, or GIF-H290T; Olympus, Tokyo, Japan) with carbon dioxide insufflation. Intravenous sedation was performed using a combination of midazolam or flunitrazepam and pethidine according to the judgment of each endoscopist. All procedures were performed by or under the supervision of experienced endoscopists who had previously performed > 100 colorectal ESD procedures. After injecting undiluted 0.4% sodium hyaluronate (MucoUp, Boston Scientific, Tokyo, Japan; KSmart, Olympus, Tokyo, Japan) and indigo carmine with diluted epinephrine, the procedures were primarily performed using one or two ESD knives. A Dual knife (KD-650L;

Olympus, Tokyo, Japan) and a Tech Knife (Micro-Tech, Nanjing, China) were mainly used for mucosal incision and submucosal dissection. In addition, the IT knife nano (KD-612; Olympus, Tokyo, Japan) was also used for submucosal dissection, especially for making a submucosal tunnel. We used an Erbe electro-surgical unit (VIO300D or VIO3 [Erbe, Tübingen, Germany]).

Regarding conventional ESD, we use gravity-focused strategies without device assistance. The ESD strategy for standard lesions was as follows. Initially, a mucosal flap was created from the distal side using mainly cutting waves of sufficient size to allow the scope to dive behind the lesion (VIO300D and VIO3: EndoCut I, effect 2, duration 2, interval 2). A sufficient endpoint was then created to the lesion. Next, the direction of fluid collection was taken as the direction of gravity, and incisional dissection was performed on that side. The submucosal layer on the gravitational side was then thoroughly dissected by entering behind the mucosal flap again. Finally, the procedure was completed with the remaining gravitational contralateral mucosal incision and dissection of the remaining submucosa. Endoscopic hemostasis was achieved with the tip of the knife in coagulation mode (VIO300D: forcedCOAG 45 W, VIO3: forced or sprayCOAG 3.5). When hemostasis could not be achieved with the knife alone, hemostatic forceps were used.

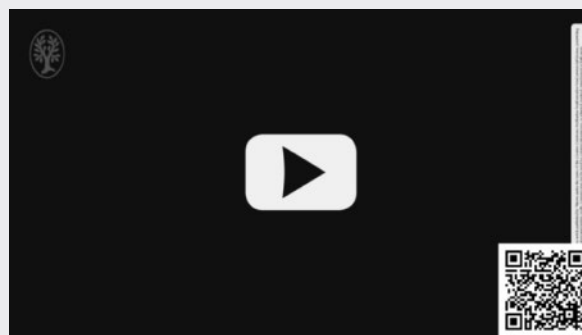
Since 2018, the DTM has been used mainly to treat LPL. The strategy is to penetrate two tunnels on both sides of the fibrotic tissue, and finally resect the fibrotic and MRS areas (DTM), especially when wide and severe fibrosis or MRS is observed in the center of a lesion [11, 16] (►Video 1, ►Fig. 1).

Data analysis and evaluations

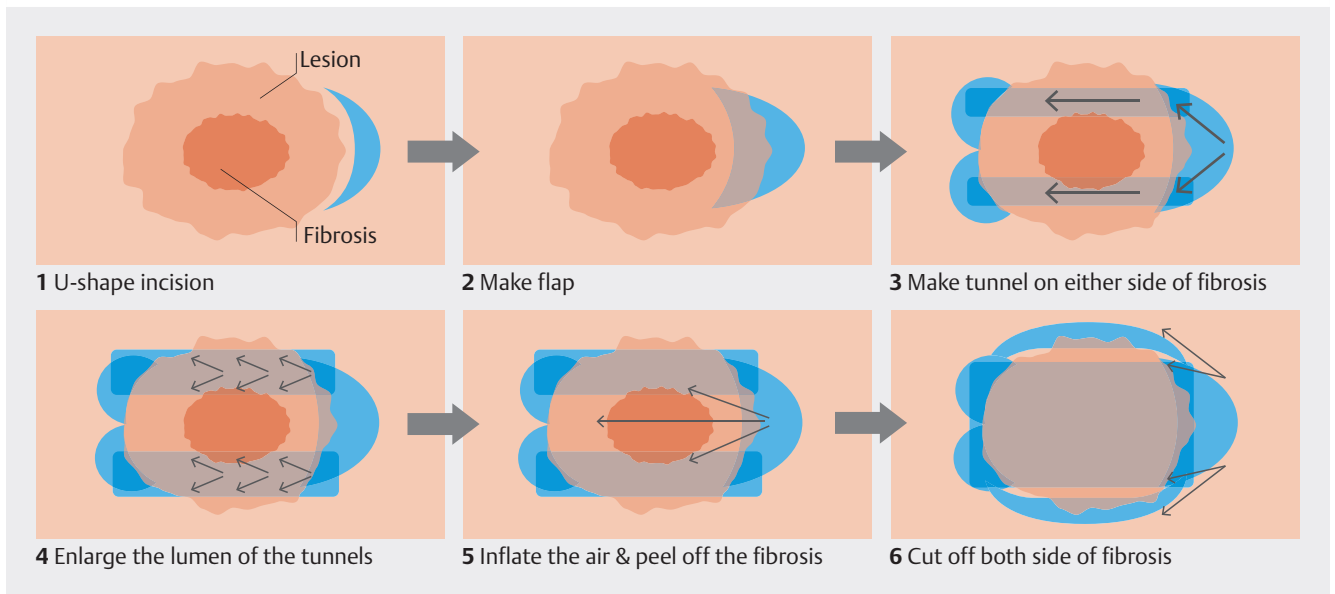
In the present study, the primary outcome was the en bloc resection rate. Treatment outcomes including size, location, procedure time, dissection speed, physician experience, submucosal fibrosis (including the presence of MRS, curative resection rate, post-procedure bleeding, and intraoperative/delayed perforation), as well as post-ESD coagulation syndrome (PECS) were evaluated.

In addition, a subanalysis was performed in this study. We evaluated the difficulty in treating LPLs ≥ 2 cm from the point of slower dissection speed (DS) with multivariate analysis. DS

► VIDEO



► Video 1 Endoscopic submucosal dissection with double tunnel method for the large protruded lesion in the rectum.



► **Fig. 1** Strategy for double tunnel method. 1) First, create a U-shaped entry of the tunnel from the distal side. 2) A mucosal flap is created and the submucosa within the tunnel is dissected. 3) If severe fibrosis is observed in the center of the lesion, one tunnel is penetrated on each side of the fibrotic area. 4) Enlarge the tunnel to expose the fibrosis. (5) Air insufflation stretches the fibrotic area and makes it easier to identify the line of dissection. (6) Once the fibrotic area has been removed, the remaining sides are resected, and the procedure is completed.

was calculated by dividing the area of the resected specimen by the procedure time (cm^2/min). We considered the area of the resected specimen to be oval shaped. Thus, the area was calculated as follows: $3.14 \times .25 \times \text{long axis} \times \text{minor axis}$. In the present study, $\text{DS} \leq 0.15 \text{ cm}^2/\text{min}$ was defined as a lower DS group because the mean DS was $0.25 \text{ cm}^2/\text{min}$ and the 25th percentile (the first percentile) was $0.157 \text{ cm}^2/\text{min}$.

Histopathological assessment

En bloc resection was defined as a tumor that was removed whole in a single piece. Patients were defined as having undergone “curative resection” when all the following criteria based on the Japanese Classification for Cancer of the Colon and Rectum were met: lateral and vertical margins were free of tumor, well/moderately differentiated or papillary carcinoma, no vascular invasion, submucosal invasion depth $< 1000 \text{ mm}$, and grade 1 budding [14].

Definitions

Delayed bleeding was defined as presentation of bloody stools within 14 days after ESD, followed by emergency colonoscopy. Intraoperative perforation was defined as occurrence of an immediately recognizable hole in the bowel wall. Delayed perforation was defined as perforation of the colon that occurred after the scope had been withdrawn following completion of ESD in which intraprocedural perforation did not occur [15]. PECS was defined as presence of pain and fever caused by inflammation of the peritoneum, which occasionally occurs after electrocoagulation, even when there is no subsequent perforation [17]. MRS was defined as the appearance of the muscle layer under a colorectal tumor being drawn by the tumor to form a triangular shape during ESD [8]. Severe fibrosis was defined as the ap-

pearance of a whitish submucosa or a white muscle-like structure without a blue transparent layer in the submucosal layer [4]. In this study, all lesions with MRS were judged as cases with fibrosis. Interruption of ESD was defined as cessation of submucosal dissection, which resulted in termination of the procedure without tumor removal.

Statistical analysis

For statistical analyses, we used the Chi-squared test, Fisher’s exact test, Student’s *t*-test, and Mann–Whitney U test. Factors identified as being significant on univariate analysis ($P < 0.10$) were entered into the multivariate logistic regression analysis model. The odds ratio and 95% confidence interval (CI) were calculated for each variable. All analyses were performed using SPSS 23 for Windows. $P \leq 0.05$ was considered to denote statistical significance.

Ethics

The study was conducted in accordance with the principles of the Declaration of Helsinki. Informed consent was obtained from all patients before the procedures.

The Institutional Review Board at our hospital approved this study (no. 23–19).

Results

Patient and lesion characteristics

Of 5011 colorectal ESD procedures performed in our centers, a total of 526 patients (542 lesions) underwent ESD for treatment of LPLs $\geq 2 \text{ cm}$ (► **Table 1**). The mean patient age was 65.6 ± 13.3 years and 285 of 526 (54.2%) were male. According to the Paris classification, 433 (79.9%) were 0-Is lesions, 106

► **Table 1** Patient characteristics and outcomes.

Lesions/patients, n	542/526
Sex, male, n (%)	285 (54.2)
Age, mean, years	65.6±13.3
Location, n (%)	
▪ Cecum	59 (10.9)
▪ Ascending	111 (20.5)
▪ Transverse	42 (7.7)
▪ Descending	25 (4.6)
▪ Sigmoid	104 (19.2)
▪ Rectum	201 (37.1)
Morphology in Paris classification, n (%)	
▪ 0-Is	433 (79.9)
▪ 0-Is + IIa/ 0-Is + IIc	106 (19.6)/ 3 (0.6)
Lesion size, median (range), mm	27 (20–115)
Procedure time, median (range), min	33.5 (3–390)
Dissection speed, median (range), cm ² /min	0.25 (0.018–1.18)
Experienced physician, n (%)	265 (48.9)
Interruption, n (%)	12 (2.2)
Submucosal fibrosis, n (%)	129 (21.8)
Muscle-retracting sign, n (%)	49 (9.0)
Use of tunnel method (single: double), n (%)	41 (26: 15) (7.6)
En bloc resection, n (%)	530 (97.8)
Curative resection, n (%)	426 (78.6)
Depth, n (%)	
▪ Adenoma (low grade)	63 (11.9)
▪ Tis	364 (68.7)
▪ T1a	24 (4.5)
▪ T1b or deeper	79 (14.9)
Adverse events	35 (6.5)
▪ Delayed bleeding	12 (2.2)
▪ Intra perforation	15 (2.8)
▪ Delayed perforation	1 (0.2)
▪ Post-ESD coagulation syndrome	7 (1.3)
Emergency surgery	1 (0.2)
ESD, endoscopic submucosal dissection	

(19.6%) were 0-Is + IIa lesions, and three (0.6%) were 0-Is + IIc lesions.

Outcomes

Median lesion size was 27.0 mm (range, 20–115) (► **Table 1**). The median procedure time was 33.5 minutes (range, 3–390) and the median DS (cm²/min) was 0.25 (range, 0.018–1.18). Of the total ESDs performed by experienced physicians in 48.9% of cases, 12 cases (2.2%) required ESD interruption. Intraoperative submucosal fibrosis was relatively common, occurring in 129 lesions (21.8%), and MRS was present in 49 cases (9.0%). ► **Fig. 2** shows incidence rates for fibrosis and MRS positivity at 1-cm intervals. In particular, the MRS incidence rate was found to be 20% higher when the size exceeded 4 cm. Among them, ESD was mostly performed using conventional methods, but the tunnel method was applied to 41 lesions (7.6%) (single tunnel; 25 lesions/double tunnel; 16 lesions). En bloc and curative resection rates were 97.8% and 78.6%, respectively. ► **Fig. 3** shows the percentage of histopathologic depth for each 1 cm of tumor size. When the tumor size reached 6 to 7 cm, the occurrence of T1b or deeper carcinomas was as high as 20%; however, even at 2 cm, 9.7% of T1b or deeper carcinomas still occurred. Regarding adverse events, delayed bleeding occurred in 12 lesions (2.2%). Intraoperative perforation and delayed perforation occurred in 15 cases (2.8%) and one case (0.2%), respectively, and in one case of delayed perforation, emergency surgery was required. PECS occurred in seven lesions (1.3%).

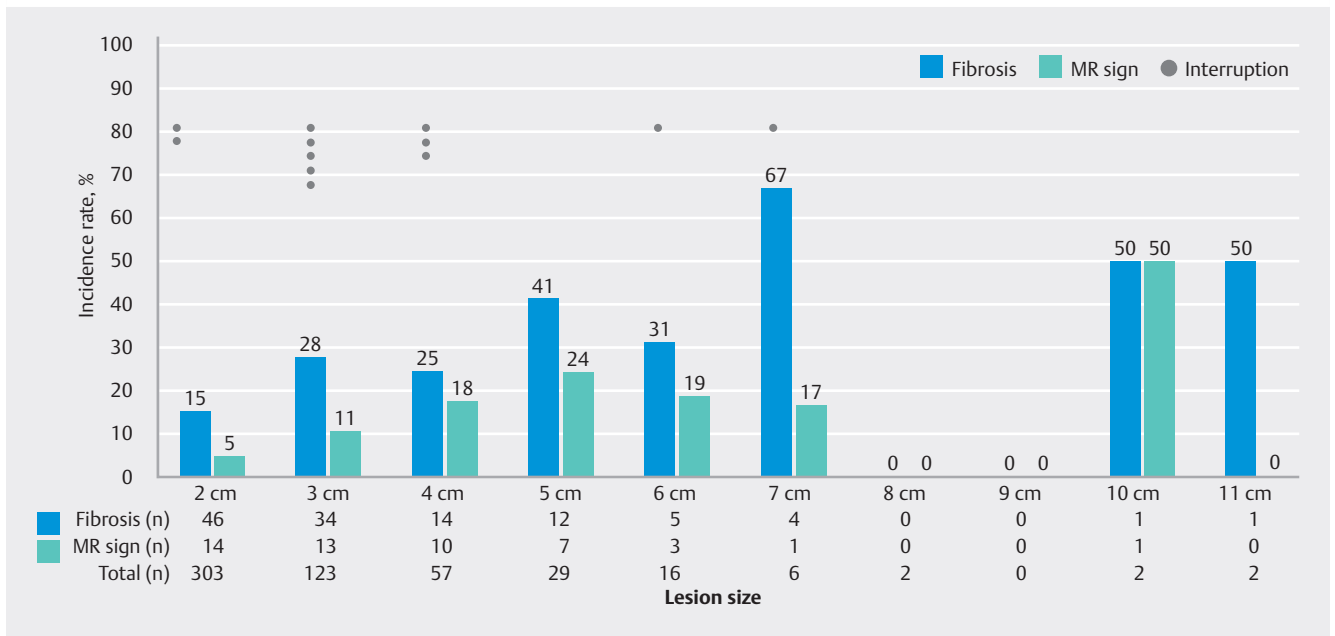
Risk factor analysis of slow resection speed for LPL > 2 cm

Regarding the difficulty in performing colorectal ESD for LPLs ≥ 2 cm according to the lower DS of < 0.15 cm²/min, multivariate logistic regression analysis revealed that larger size (≥ 4 cm), presence of submucosal fibrosis, MRS, and procedure performance by non-experienced physicians (< 100 colorectal ESD procedures performed) decreased procedure speed (► **Table 2**).

Discussion

It is very crucial for endoscopists to understand the reality of colorectal ESD for LPLs because of the high degree of treatment difficulty, which sometimes results in interruptions. This study demonstrated that fibrosis and MRS appeared in more than 25% and 15% of LPLs ≥ 4 cm, respectively, and that treatment difficulty increased.

Colorectal ESD has evolved not only through development of endoscopic equipment, but also through various strategies such as traction methods, the PCM, and the tunnel method to achieve high en bloc resection rates [18, 19, 20]. Challenges in performing colorectal ESD can be categorized into endoscopic operability (due to respiratory movement and difficulties in approaching lesions) and lesion-related factors (location, macroscopic type, tumor size, and fibrosis) [5, 6, 9]. Among macroscopic types, it is believed that protruded type tumors are more challenging, considering the frequency of fibrosis and the risk of MRS occurrence. In this study, ESD for LPLs ≥ 2 cm achieved a high en bloc resection rate of 97.8%, but treatment interruptions were observed in 12 cases (2.2%). Research focus-



► **Fig. 2** Incidence rates for fibrosis/muscle-retracting sign positivity and interrupted cases at 1-cm intervals.

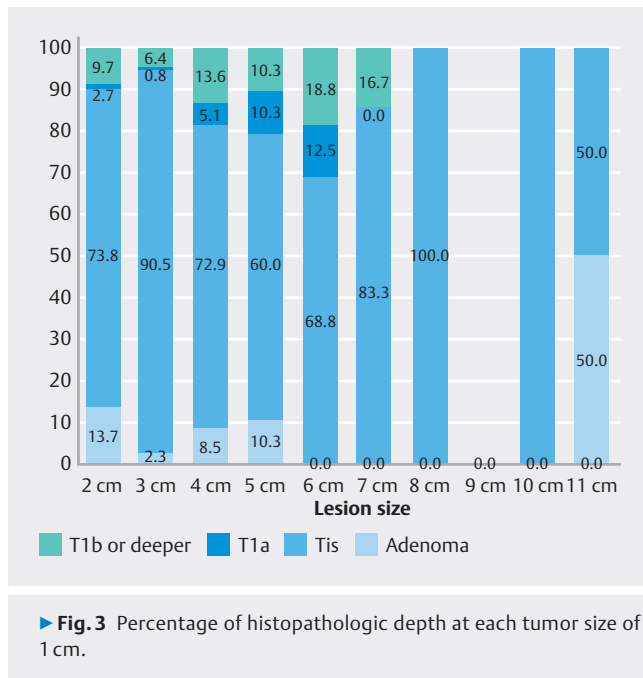
ing on protruded tumors has been limited, and the main purpose of this study was to clarify which characteristics of protruded lesions require special attention. Among LPLs, there are also pedunculated polyps (0-Ip in the Paris classification), but they were excluded from this study due to differences in treatment strategies [21]. In addition, other dominant-type macroscopic lesions such as 0-IIa+Is (laterally spreading tumor - granular - mixed type) were all excluded. Preoperative diagnosis of MRS enables establishment of an easier treatment strategy. This study revealed that when the tumor size reaches approximately 3 to 4 cm, MRS occurs in 11% to 18% of cases. Furthermore, Fukuchi et al. reported a moderate correlation between tumor size and MRS positivity, with a sensitivity of 79.4% and specificity of 65.2% when using a size cutoff of 27 mm [7]. While preoperative endoscopic ultrasound was associated with a sensitivity and specificity for MRS positivity in protruding lesions of 87.5% and 83.3%, respectively, the total number of cases was limited to 20, thus warranting further verification [12]. MRS is considered to be caused by severe fibrosis associated with mechanical forces and the desmoplastic reaction to cancer invasion [8]. Although MRS tends to appear more frequently as tumor size increases (► **Fig. 2**), it is noteworthy that MRS was observed in 5% of cases even with a size < 2 cm. Of these 14 cases, 11 (78.6%) were T1b (submucosal infiltration depth > 1000 μ m) or deeper carcinomas, which may have been partly due to tumor invasion and the desmoplastic reaction. In addition, half of these cases were in highly movable sites with mesentery (five in the sigmoid colon and two in the transverse colon), and the tumors themselves were affected by peristalsis, resulting in traction in the muscularis propria.

In a study of treatment difficulty factors evaluated from the DS of LPLs, tumor size \geq 4 cm, MRS, fibrosis, and a non-experienced physician (colorectal ESD experience < 100 cases) were

each identified as independent factors. MRS and fibrosis are intraoperative findings, but tumor size can be assumed preoperatively. Therefore, it would be advisable to have an experienced physician perform the procedure in cases where a tumor measures \geq 4 cm. Furthermore, the tunnel method may be useful. Because a certain tumor size is necessary to create a tunnel entry, the usefulness of the DTM is likely to increase in tumors large than 3 to 4 cm. The presence of severe fibrosis or MRS can only be determined once it is within the submucosal layer. For this reason, we believe that the DTM is useful in all cases of LPLs larger than 3 to 4 cm, with tunnels created on both sides when MRS or advanced fibrosis is detected. If no MRS or advanced fibrosis is observed, ESD will be completed using the single tunnel method. This study was retrospective and conducted after 2018, and the aim was to verify whether the tunneling method was useful for LPLs in randomized controlled trials (RCTs) with a larger number of patients. In this study, the tunnel method was performed in 41 lesions (7.6%). Of these, the single tunnel method was performed in 25 lesions (61%) and the DTM in 16 lesions (39%).

The single tunnel technique is sometimes compared with the PCM in its strategy similarity; both can stabilize scope maneuverability by entering behind the mucosal flap. PCM is a strategy that creates a wide entry over time, followed by a peripheral incision and endpoint, whereas the tunnel method creates a tunnel the width of one scope and proceeds with dissection in a straight line. Therefore, creating a single tunnel is relatively easy with experience, and multiple tunnels can be formed. Sometimes, however, it is not possible to clearly distinguish between the two procedures.

The overall curative resection rate of ESD for LPLs in this study was 78.6% (► **Fig. 3**). In addition, accurate preoperative diagnosis of LPL is difficult. Although it is important to deter-



mine whether the muscularis mucosae is involved, it is difficult to predict the invasive area based on the pit pattern and other surface structures alone in tumors with a high elevation type. ESD for diagnostic evaluation is considered acceptable to avoid unnecessary surgery, if white light is used to visualize tumors with expanded changes and deep depressions, and a comprehensive evaluation is conducted of the site (e. g., rectal lesions) and the patient's background (age and underlying disease). On

the other hand, it is not easy to determine whether intraoperative severe fibrosis is due to cancer or to MRS as a mechanical and benign change. If the fibrosis is due to cancer, interruption is acceptable because SM invasive cancer is suspected first, but if the fibrosis is benign, the patient is expected to continue treatment despite the difficulty. Considering that 6.4% to 9.7% of LPLs < 3 cm were T1b (submucosal infiltration depth > 1000 μ m) or deeper carcinomas, it is desirable to try en bloc resection with ESD for LPLs of this size, even if they have advanced fibrosis or MRS. However, at present, the issue of difficulty in preoperative diagnosis has not been resolved, and when treatment is initiated, it should ideally be performed safely and on pathologically diagnosable specimens using various strategies, including the tunnel method.

There are some limitations to this study. First, this retrospective study may have an institutional selection bias. All cases were treated in a high-volume center with some experienced endoscopists. This fact may have led to an overestimate of the outcomes and the feasibility of the technique with the tunnel method. Second, there may have been cases in which endoscopic curative resection was obtained pathologically, even though preoperative endoscopic examination determined that ESD was not indicated and surgery was performed. Considering the relatively small number of cases of tumors measuring > 6 cm in this study, it is possible that surgery was chosen because many tumors > 6 cm fill the lumen, making accurate preoperative diagnosis difficult and assurance of technical safety impossible (detailed data not available). Future studies including surgical cases are needed to provide more accurate information about pathologic trends in LPLs.

► **Table 2** Difficulty factors for large protruded lesions.

	Univariate, odds ratio (95% CI)	P value	Multivariate, odds ratio (95% CI)	P value
Lesion size \geq 4 cm	1.779 (1.014 - 3.123)	0.045	2.662 (1.349 - 5.254)	0.005
Location*				
▪ Rectum	1			
▪ Left colon	0.670 (0.390 - 1.153)	0.148		
▪ Right colon	0.708 (0.439 - 1.140)	0.155		
Mixed type	1.551 (0.892 - 2.698)	0.12		
Muscle-retracting sign	6.237 (3.188 - 12.201)	< 0.001	4.581 (1.901 - 10.942)	0.001
Fibrosis	3.53 (2.255 - 5.528)	< 0.001	3.930 (2.133 - 7.238)	< 0.001
Non-experienced physician**	2.455 (1.591 - 3.788)	< 0.001	3.945 (2.340 - 6.652)	< 0.001

*The right colon refers to the transverse colon-cecum, and the left colon to the sigmoid colon-descending colon.

** Non-experienced endoscopists: These physicians had previously performed less than 100 colorectal endoscopic submucosal dissection (ESD) procedures.

Conclusions

In conclusion, understanding the challenges in treating LPLs through colorectal ESD is essential because of procedure difficulty and the potential for treatment interruptions. This novel study summarizes the substantial number of pure LPLs ≥ 2 cm, excluding other macroscopic types such as lateral spreading tumors, and underscores the increased treatment difficulty in cases of LPL ≥ 4 cm with fibrosis and MRS. For tumors ≥ 4 cm, experienced endoscopists are recommended. However, further research, including RCTs, is needed to validate these findings.

Conflict of Interest

The authors declare that they have no conflict of interest.

References

- [1] Ohata K, Kobayashi N, Sakai E et al. Long-term outcomes after endoscopic submucosal dissection for large colorectal epithelial neoplasms: a prospective, multicenter, cohort trial from Japan. *Gastroenterology* 2022; 163: 1423–1434
- [2] Libânio D, Pimentel-Nunes P, Bastiaansen B et al. Endoscopic submucosal dissection techniques and technology: European Society of Gastrointestinal Endoscopy (ESGE) Technical Review. *Endoscopy* 2023; 55: 361–389 doi:10.1055/a-2031-0874
- [3] Draganov PV, Aihara H, Karasik MS et al. Endoscopic submucosal dissection in North America: a large prospective multicenter study. *Gastroenterology* 2021; 160: 2317–2327 doi:10.1053/j.gastro.2021.02.036
- [4] Matsumoto A, Tanaka S, Oba S et al. Outcome of endoscopic submucosal dissection for colorectal tumors accompanied by fibrosis. *Scand J Gastroenterol* 2010; 45: 1329–37 doi:10.3109/00365521.2010.495416
- [5] Chiba H, Tachikawa J, Arimoto J et al. Predictive factors of mild and severe fibrosis in colorectal endoscopic submucosal dissection. *Dig Dis Sci* 2020; 65: 232–242 doi:10.1007/s10620-019-05735-y
- [6] Chiba H, Ohata K, Tachikawa J et al. The feasibility of endoscopic submucosal dissection for colorectal lesions larger than 10 cm. *Surg Endosc* 2022; 36: 5348–5355
- [7] Fukuchi T, Hirasawa K, Sato C et al. Factors influencing interruption of colorectal endoscopic submucosal dissection. *Surg Endosc* 2021; 35: 5497–5507 doi:10.1007/s00464-020-08042-0
- [8] Toyonaga T, Tanaka S, Man- I et al. Clinical significance of the muscle-retracting sign during colorectal endoscopic submucosal dissection. *Endosc Int Open* 2015; 3: E246–51
- [9] Imai K, Hotta K, Yamaguchi Y et al. Preoperative indicators of failure of en bloc resection or perforation in colorectal endoscopic submucosal dissection: implications for lesion stratification by technical difficulties during stepwise training. *Gastrointest Endosc* 2016; 83: 954–62 doi:10.1016/j.gie.2015.08.024
- [10] Participants in the Paris Workshop. The Paris endoscopic classification of superficial neoplastic lesions, esophagus, stomach, and colon. *Gastrointest Endosc* 2003; 58: S3–S43
- [11] Chiba H, Ohata K, Takita M et al. Double-tunnel method for treatment of colorectal lesions with severe fibrosis with endoscopic submucosal dissection. *Endoscopy* 2018; 50: E168–E169
- [12] Tanaka H, Takehara Y, Morimoto S et al. Diagnostic and therapeutic strategies for colorectal tumor with positive muscle-retracting sign. *DEN Open* 2023; 30: e278
- [13] Matsuda T, Fujii T, Saito Y et al. Efficacy of the invasive/non-invasive pattern by magnifying chromoendoscopy to estimate the depth of invasion of early colorectal neoplasms. *Am J Gastroenterol* 2008; 103: 2700–2706 doi:10.1111/j.1572-0241.2008.02190.x
- [14] Hashiguchi Y, Muro K, Saito Y et al. Japanese Society for Cancer of the Colon and Rectum (JSCCR) Guidelines 2019 for the treatment of colorectal cancer. *Int J Clin Oncol* 2020; 25: 1–42 doi:10.1007/s10147-019-01485-z
- [15] Tanaka S, Kashida H, Saito Y et al. Japan Gastroenterological Endoscopy Society guidelines for colorectal endoscopic submucosal dissection/endoscopic mucosal resection. *Dig Endosc* 2020; 32: 219–223 doi:10.1111/den.13545
- [16] Kurebayashi M, Ohata K, Chiba H et al. Recurrent tumor involving a diverticulum after colonic endoscopic submucosal dissection successfully resected by the double-tunnel method. *Endoscopy* 2021; 53: E185–E186 doi:10.1055/a-1230-3203
- [17] Arimoto J, Higurashi T, Kato S et al. Risk factors for post-colorectal endoscopic submucosal dissection (ESD) coagulation syndrome: a multicenter, prospective, observational study. *Endosc Int Open* 2018; 6: E342–E349 doi:10.1055/s-0044-101451
- [18] Yamasaki Y, Takeuchi Y, Uedo N et al. Traction-assisted colonic endoscopic submucosal dissection using clip and line: a feasibility study. *Endosc Int Open* 2016; 4: E51–E55 doi:10.1055/s-0041-107779
- [19] Suzuki Y, Ohata K, Sakai E et al. Palisade technique as an effective endoscopic submucosal dissection tool for large colorectal tumors. *Endosc Int Open* 2021; 9: E210–E215 doi:10.1055/a-1313-7026
- [20] Li B, Shi Q, Xu EP et al. Prediction of technically difficult endoscopic submucosal dissection for large superficial colorectal tumors: a novel clinical score model. *Gastrointest Endosc* 2020; 19: S0016–5107(20) 34960 doi:10.1016/j.gie.2020.11.012
- [21] Chiba H, Tachikawa J, Arimoto J et al. Endoscopic submucosal dissection of large pedunculated polyps with wide stalks: a retrospective multicenter study. *Endoscopy* 2021; 53: 77–80