



CASE REPORT

REVISED Case Report: Mitral valve obstruction by metastatic malignant phyllodes tumor [version 2; peer review: 2 approved]

Chamtouri Ikram ¹, Amdouni Nesrine¹, Kaddoussi Rania², Ahlem Bellalah³, Kortas Chokri⁴, Achour Asma ⁵, Joobar Sameh², Maatouk Faouzi¹

¹cardiology B department, Fattouma Bourguiba University Hospital, Monastir, MONASTIR, 5000, Tunisia

²pneumology, Fattouma Bourguiba University Hospital, Monastir, MONASTIR, 5000, Tunisia

³anatomic pathology, Fattouma Bourguiba University Hospital, Monastir, MONASTIR, 5000, Tunisia

⁴cardiovascular surgery, Sahloul University Hospital, MONASTIR, 5000, Tunisia

⁵radiology, Fattouma Bourguiba University Hospital, Monastir, MONASTIR, 5000, Tunisia

v2 First published: 14 Mar 2022, 11:309
<https://doi.org/10.12688/f1000research.110022.1>

Latest published: 25 Jul 2022, 11:309
<https://doi.org/10.12688/f1000research.110022.2>

Abstract

Cardiac metastases are rare. Herein, we report a case of a 37-year-old female patient with a history of borderline breast phyllodes tumor (PT) treated by surgery, admitted to our department for concomitant cardiac and pulmonary metastases of malignant PT. Cardiac metastasis occurred through direct extension from pulmonary metastasis to the left atrium via the right inferior pulmonary vein, causing severe mitral valve obstruction. Although the total surgical removal of metastases, the patient had a huge relapse of the mediastinal metastasis resulting in her death.

Keywords

Breast cancer, cardiac metastasis, mitral stenosis, acute heart failure

Open Peer Review

Approval Status

	1	2
version 2 (revision) 25 Jul 2022		 view
version 1 14 Mar 2022	 view	 view

1. **Hassen Ibn Hadj Amor** , Taher Sfar
 university hospital, Mahdia, Tunisia
 Faculty of Medicine of Monastir, Monastir,
 Tunisia

2. **Chien-Liang Fang** , Ditmanson Medical
 Foundation Chia-Yi Christian Hospital, Chia-Yi,
 Taiwan

Any reports and responses or comments on the article can be found at the end of the article.

Corresponding author: Chamtouri Ikram (ikram_chamtouri@hotmail.fr)

Author roles: **Ikram C:** Writing – Original Draft Preparation; **Nesrine A:** Data Curation; **Rania K:** Methodology; **Bellalah A:** Investigation; **Chokri K:** Supervision; **Asma A:** Visualization; **Sameh J:** Supervision; **Faouzi M:** Supervision

Competing interests: No competing interests were disclosed.

Grant information: The author(s) declared that no grants were involved in supporting this work.

Copyright: © 2022 Ikram C *et al.* This is an open access article distributed under the terms of the [Creative Commons Attribution License](#), which permits unrestricted use, distribution, and reproduction in any medium, provided the original work is properly cited.

How to cite this article: Ikram C, Nesrine A, Rania K *et al.* **Case Report: Mitral valve obstruction by metastatic malignant phyllodes tumor [version 2; peer review: 2 approved]** F1000Research 2022, 11:309 <https://doi.org/10.12688/f1000research.110022.2>

First published: 14 Mar 2022, 11:309 <https://doi.org/10.12688/f1000research.110022.1>

REVISED Amendments from Version 1

- In the abstract, “the patient had a huge relapse of the mediastinal metastasis resulting in her death” was added.
- Breast tumor size and description were added in the case presentation.
- Surgical treatment were described in the case presentation.
- Figure 6 was added, showing the relapse of the mediastinal metastasis.
- References were corrected.

Any further responses from the reviewers can be found at the end of the article

List of abbreviations

CT: computed tomography

LA: left atrium

LSPV: left superior pulmonary vein

MRI: magnetic resonance imaging

Pts: Phyllodes tumors

TTE: trans thoracic echocardiography

Background

Phyllodes tumors (PTs) represent a rare category of breast neoplasm, with a prevalence accounting for <1% of all breast tumors.¹ PTs predominantly occur in women aged 35-50 years,² and they range from benign to malignant forms according to the histological features.³ Malignant PTs account for 16% to 30% of all PTs and they have an inherent recurrence and/or metastasis potential.^{4,5} Cardiac metastases are more frequent than primary cardiac tumors.⁶ Herein, we report a case of concomitant cardiac and pulmonary metastases of malignant PTs, causing severe mitral valve obstruction.

Case report

A 37-year-old Maghrebian female patient was presented to the cardiology department due to complaints of dyspnea, progressing over one month. She had a dry cough and had been resistant to symptomatic treatment. The patient was diagnosed with borderline breast PTs ten years earlier. Tumor size was $8 \times 7 \times 5$ cm removed surgically with no skin involvement and safe margin of resection. No recurrence was noted during the first years of follow-up. Upon examination, her dyspnea was classified as class IV on the New York Heart Association Functional Classification with orthopnea. Her transcutaneous oxygen saturation was 92%, and pulmonary auscultation revealed bibasilar crackles. Additionally, the patient’s chest x-ray showed a homogeneous opacity located in the basal part of the right lung. Transthoracic echocardiography (TTE) revealed 5×4 cm homogenous mass occupying nearly all the left atrium (LA), resulting in severe mitral valve obstruction (mean gradient = 17 mmHg) (Figure 1).

A second huge mass compressed the right atrium posterior wall. Following respiratory stabilization, transesophageal echocardiography confirmed TTE results and revealed an extended mass into LA via the right inferior pulmonary vein

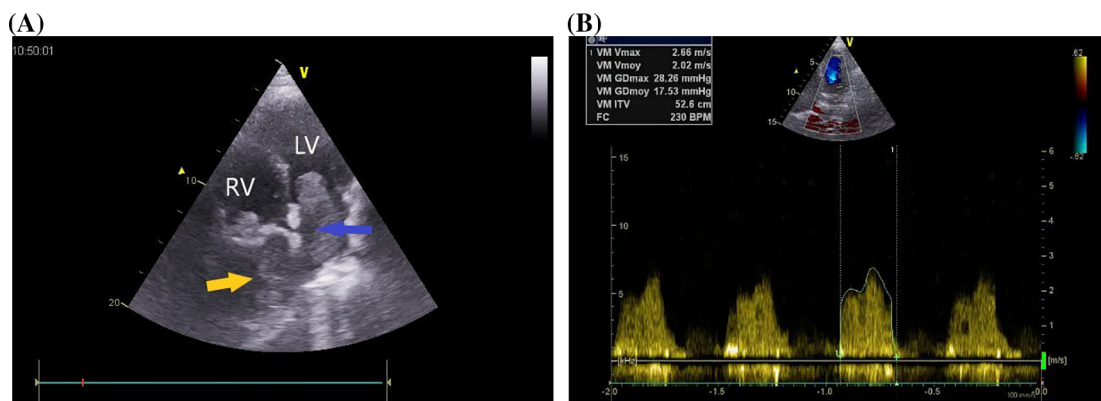


Figure 1. A: Transthoracic echocardiography in four-chamber view showing large mass in the left atrium (blue arrow) and a retro right atrial mass (yellow arrow). B: Transmitral valve gradient in continuous Doppler showing severe mitral stenosis. LV: left ventricle, MV: mitral valve, RV: right ventricle.

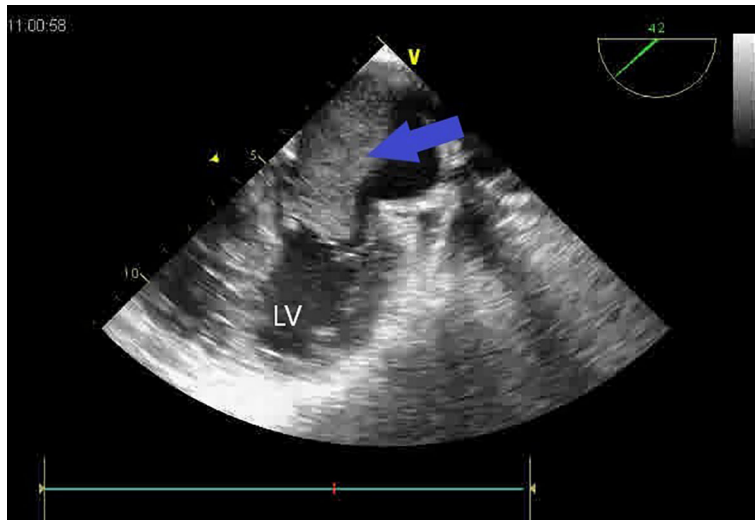


Figure 2. Transesophageal echocardiography showing a large mass, occupying nearly all the left atrium (blue arrow) and mitral obstruction.

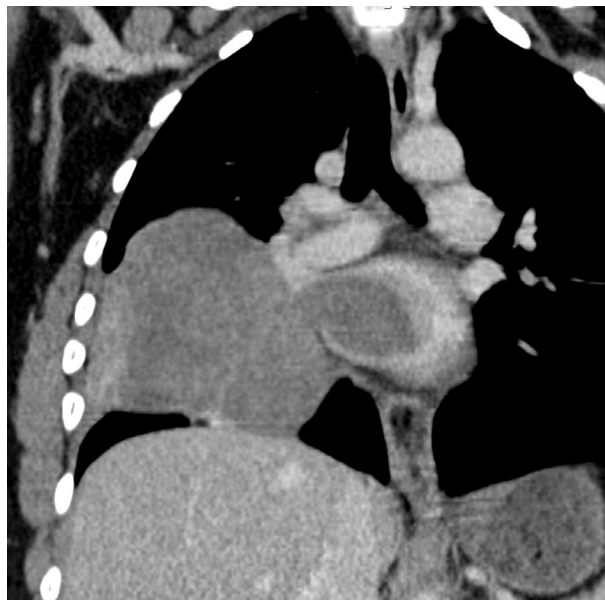


Figure 3. CT (coronal reconstruction): Right pulmonary mass, slightly enhanced after injection of contrast product with extension to the LA via the RIPV.

(RIPV) (Figure 2). Cardiac computed tomography (CT) revealed a large ($100 \times 70 \times 100$) mediastino-pulmonary mass extending to LA via RIPV (Figure 3).

The Cardiac magnetic resonance imaging (MRI) results showed low signal on T1-weighted imaging and high signal on T2-weighted imaging of the mediastino-pulmonary mass (Figure 4). The patient accepted to undergo an urgent mass resection surgery to avoid total mitral valve obstruction and sudden death. Surgery consisted on total intra cardiac metastasis resection with mitral valve conservation and right pneumonectomy without reconstruction. The histological study of the resected mass confirmed the metastatic spread of malignant PTs to LA (Figure 5). The patient was discharged from the hospital after having an echocardiographic check-up, which demonstrated no residual tumor. However, three months after the surgery, she died from a huge relapse of mediastinal mass cardiac and tracheal compression (Figure 6).

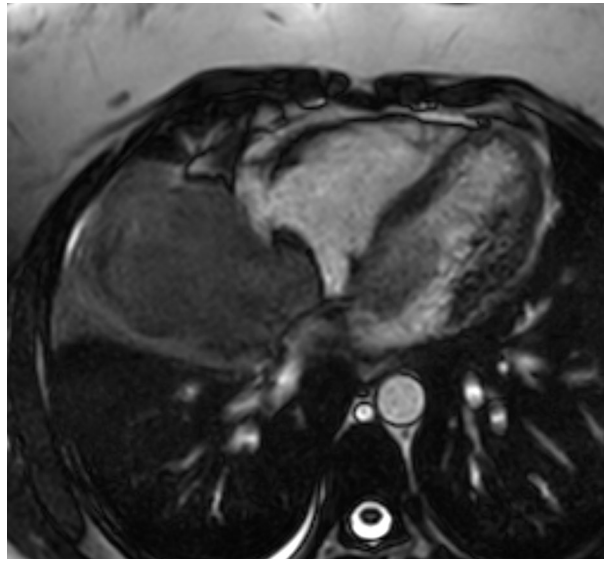


Figure 4. Cardiac MRI (axial cine-MRI sequence): prolapse of the mass of LA via the mitral valve.

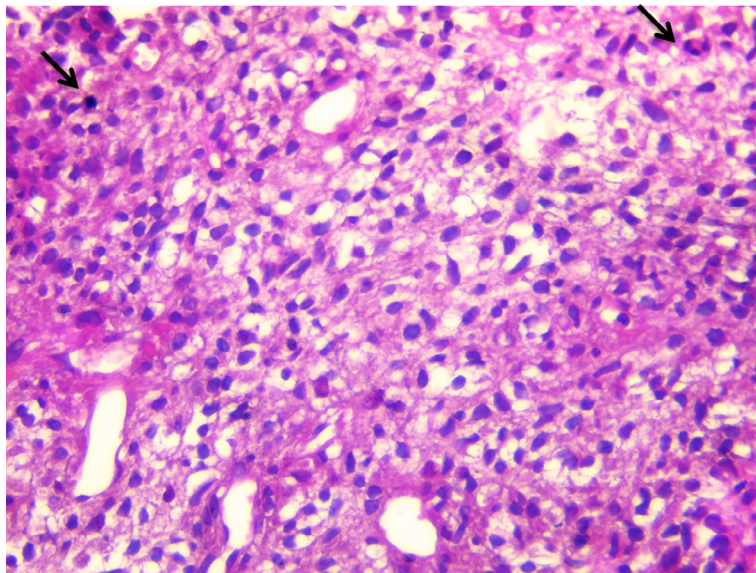


Figure 5. Mesenchymal pattern of a malignant phyllode tumor with a high stromal cellularity, nuclear atypia and mitosis (arrows) (HE stain $\times 400$).

Discussion

PTs or cystosarcoma is a rare breast neoplasm.¹ These types of tumors are commonly manifested in the breast tissue and are usually benign; however, they might rarely be malignant.^{2,3} A malignant tumor has a potential to metastasize to distant organs, such as lung, bone, and liver.⁸ Our case revealed concomitant pulmonary and cardiac metastases, which is unusual, and it is associated with poor prognosis. It has been reported that cardiac invasion could be caused by hematogenous spread, direct extension, or via the lymphatic route.⁹ In the case of this patient, direct extension from pulmonary metastasis to RIPV is the probable route of metastasis. Reported cases of cardiac metastasis are mostly located in the right heart with the possibility of right ventricle outflow tract obstruction.¹⁰ To the best of our knowledge, this is the first case of LA location, complicated by severe mitral obstruction and acute heart failure. The clinical expression of cardiac metastasis is mainly dependent on the tumor burden and location.⁶ As in the case of our patient, cardiac metastasis can manifest with dyspnea and chest pain, or it can be asymptomatic. Previously, malignant cardiac metastasis had poor prognosis and very rare cases were identified at autopsy.¹¹ However, advances in imaging tools such as echocardiography

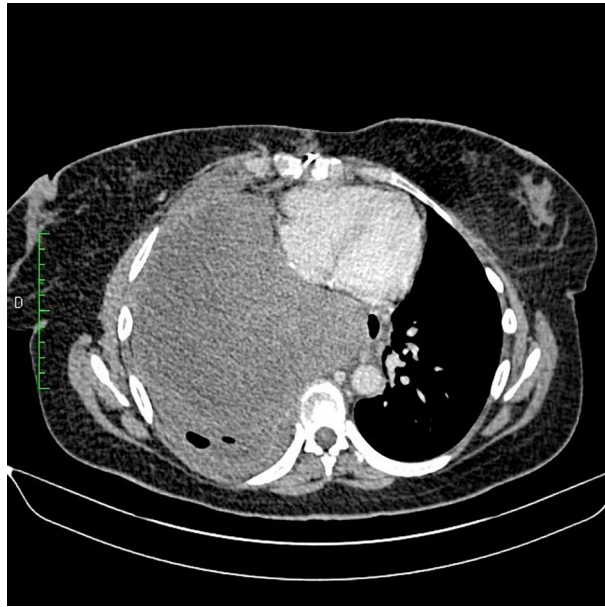


Figure 6. CT (coronal reconstruction): huge relapse of mediastinal mass with cardiac and tracheal compression.

allows for detection and confirmation of intra-cardiac mass and eventual valve or cavity obstruction. However, echocardiography is limited in the differentiation between PTs, myxoma, fibroadenoma, and thrombus.¹¹ In our case, echocardiography revealed severe mitral obstruction by an intra-LA mass. Cardiac CT and MRI provide multiple views in different axes with a precision of limits as well as intra, and extra cardiac extension, thus allowing a better distinction between the thrombus and other masses.¹² The results of the echocardiography, cardiac CT, and MRI for our patient confirmed the intra and extra cardiac location of the tumor and its LA access from RIPV to the mitral valve. Therapeutic approaches, including chemotherapy, radiotherapy, and hormonal therapy are still controversial.⁷ The surgical excision of cardiac metastasis from a malignant PTs was described in few reports.¹³ This type of intervention could be an urgent life-saving therapeutic strategy in case of right ventricle outflow obstruction or mitral obstruction, and it can also improve the patient's quality of life in the short term, as it was in our case.^{14,15} However, intra-operative mass manipulation could cause tumor dissemination, thus leading to a risk of further metastasis development.^{11,16} This may explain the huge relapse of mediastinal mass with tracheal invasion in our patient. In this case report the major limitations were the delay in diagnosing cardiac and pulmonary metastases and the lack of immunohistochemical analysis of the tumor.

Conclusion

Cardiac metastases from PTs are rare. Tumor surgical excision might be indicated to avoid sudden death and to improve the patient's quality of life despite the extremely unfavorable prognosis. Nevertheless, urgent surgical removal could be unavoidable in case of valve obstruction. Early diagnosis and immunohistological analysis of PTs, especially the malignant type, is imperative given that there is little effective treatment for metastatic disease.

Data availability

All data underlying the results are available as part of the article and no additional source data are required.

Author contributions

NA, AA and AB were actively involved in data collection and processing. IC and RK were involved in manuscript preparation. CK, SJ and FM were involved in manuscript reviewing. All authors have read and approved the manuscript.

Consent

A written informed consent was received from the patient's brother.

References

1. Parker SJ, Harries SA: **Phyllodes tumors**. *Postgrad. Med. J.* 2001; **77**: 428–435.
[PubMed Abstract](#) | [Publisher Full Text](#) | [Free Full Text](#)
2. Jing P, Wei B, Yang X: **Phyllodes tumor of the breast with nipple discharge: A case report**. *Medicine (Baltimore)*. 2018; **97**: e13767.
[PubMed Abstract](#) | [Publisher Full Text](#)
3. Zhang Y, Kleer CG: **Phyllodes Tumor of the Breast: Histopathologic Features, Differential Diagnosis, and Molecular/Genetic Updates**. *ArchPatholLab Med.* 2016; **140**: 665–671.
4. Rosenfeld JC, DeLaurentis DA, Lerner H: **Cystosarcoma phyllodes. Diagnosis and management**. *Cancer Clin. Trials.* 1981; **4**: 187–193.
[PubMed Abstract](#)
5. Jones AM, Mitter R, Poulosom R, *et al.*: **mRNA expression profiling of phyllodes tumours of the breast: identification of genes important in the development of borderline and malignant phyllodes tumours**. *Phyllodes. Tumour Consortium. J. Pathol.* 2008; **216**: 408–417.
[Publisher Full Text](#)
6. Bussani R, De-Giorgio F, Abbate A, *et al.*: **Cardiac metastases**. *J. Clin. Pathol.* 2007; **60**(1): 27–34.
[PubMed Abstract](#) | [Publisher Full Text](#)
7. Telli ML, Horst KC, Guardino AE, *et al.*: **Phyllodes tumors of the breast: natural history, diagnosis, and treatment**. *J. Natl. Compr. Cancer Netw.* 2007; **5**: 324–330.
[Publisher Full Text](#)
8. Kessinger A, Foley JF, Lemon HM, *et al.*: **Metastatic cystosarcoma phyllodes: a case report and review of the literature**. *J. Surg. Oncol.* 1972; **4**: 131–147.
[Publisher Full Text](#)
9. Schoen FJ, Berger BM, Guerina NG: **Cardiac effects of non cardiac neoplasms**. *Cardiol. Clin.* 1984; **2**: 657–670.
[Publisher Full Text](#)
10. Nakatsu T, Koshiji T, Sakakibara Y, *et al.*: **Pulmonary artery obstruction due to a metastatic malignant phyllodes tumor of the breast**. *Gen. Thorac. Cardiovasc. Surg.* 2010; **58**(8): 423–426.
[PubMed Abstract](#) | [Publisher Full Text](#)
11. Garg N, Moorthy N, Agrawal SK, *et al.*: **Delayed cardiac metastasis from phyllodes breast tumor presenting as cardiogenic shock**. *Tex Heart Inst. J.* 2011; **38**: 441–444.
12. Chiles C, Woodard PK, Gutierrez FR, *et al.*: **Metastatic involvement of the heart and pericardium: CT and MR imaging**. *Radiographics.* 2001; **21**: 439–449.
[Publisher Full Text](#)
13. Ya'qoub L, Larson S, Deedy M, *et al.*: **Treatment of recurrent isolated right atrial metastatic cavitory mass from breast cancer with radiation therapy: A case report and review of literature**. *Echocardiography.* 2018; **35**: 1680–1683.
[Publisher Full Text](#)
14. Yoshidaya F, Hayashi N, Takahashi K, *et al.*: **Malignant phyllodes tumor metastasized to the right ventricle: a case report**. *Surg. Case Rep.* 2015; **1**: 121.
15. Chachques JC, Argyriadis PG, Latremouille C, *et al.*: **Cardiomyoplasty-ventricular reconstruction after tumor resection**. *J. Thorac. Cardiovasc. Surg.* 2002; **123**: 889–894.
[Publisher Full Text](#)
16. Goh CH, Lim YP, Su JW, *et al.*: **Cardio pulmonary thrombo embolism of epithelioid angiosarcoma arising from malignant phyllodes tumour of the breast**. *J. Clin. Pathol.* 2014; **67**: 450–454.
[PubMed Abstract](#) | [Publisher Full Text](#)

Open Peer Review

Current Peer Review Status:  

Version 2

Reviewer Report 02 August 2022

<https://doi.org/10.5256/f1000research.136136.r145275>

© 2022 Fang C. This is an open access peer review report distributed under the terms of the [Creative Commons Attribution License](#), which permits unrestricted use, distribution, and reproduction in any medium, provided the original work is properly cited.



Chien-Liang Fang 

Division of Plastic and Reconstruction Surgery, Department of Surgery, Ditmanson Medical Foundation Chia-Yi Christian Hospital, Chia-Yi, Taiwan

I approve this manuscript for indexing.

Competing Interests: No competing interests were disclosed.

Reviewer Expertise: Breast and plastic surgery

I confirm that I have read this submission and believe that I have an appropriate level of expertise to confirm that it is of an acceptable scientific standard.

Version 1

Reviewer Report 01 July 2022

<https://doi.org/10.5256/f1000research.121589.r140668>

© 2022 Fang C. This is an open access peer review report distributed under the terms of the [Creative Commons Attribution License](#), which permits unrestricted use, distribution, and reproduction in any medium, provided the original work is properly cited.



Chien-Liang Fang 

Division of Plastic and Reconstruction Surgery, Department of Surgery, Ditmanson Medical Foundation Chia-Yi Christian Hospital, Chia-Yi, Taiwan

This is a rare case of mitral valve obstruction by metastatic malignant phyllodes tumor. They provide clear and complete images for a complete preoperative assessment and they can keep

patients alive for more than three months after surgery for such a severe mitral valve obstruction. They did a great job but this case report still needs further revision and correction.

In the abstract:

1. The authors write “we report a case of a 37-year-old female patient with a history of borderline breast PTs”, please add previous breast PT surgery treatments.
2. “The patient had an uncommon complication”, please mention the complication.

In the report itself:

1. “The patient was diagnosed with borderline breast PTs ten years earlier, which was treated by surgical excision.” Which breast, tumor size, skin involvement, safe margin of surgical resection, recurrence or not?
2. What is the operation of metastatic malignant phyllodes tumor resection, including resection of mitral valve or cardiac tissue, lung resection (lobectomy) or debulking surgery? Reconstruction or not?
3. “The patient was discharged from the hospital after having an echocardiographic check-up, which demonstrated no residual tumor.” Please show the echocardiographic image.
4. “Three months after the surgery, she died from a huge relapse of mediastinal mass with tracheal invasion.”, please show the CT image.
5. In discussion, I could find more than a dozen articles on metastatic malignant phyllodes tumor of the heart, please summarize and discuss the differences between your case and theirs.
6. There are many errors in the references, please correct them.

Is the background of the case’s history and progression described in sufficient detail?

Yes

Are enough details provided of any physical examination and diagnostic tests, treatment given and outcomes?

Yes

Is sufficient discussion included of the importance of the findings and their relevance to future understanding of disease processes, diagnosis or treatment?

Partly

Is the case presented with sufficient detail to be useful for other practitioners?

Yes

Competing Interests: No competing interests were disclosed.

Reviewer Expertise: breast and plastic surgery

I confirm that I have read this submission and believe that I have an appropriate level of expertise to confirm that it is of an acceptable scientific standard, however I have significant reservations, as outlined above.

Author Response 12 Jul 2022

IKRAM CHAMTOURI, Fattouma Bourguiba University Hospital, Monastir, MONASTIR, Tunisia

Dear editorial board

Thank you for giving me the opportunity to submit a revised draft of my manuscript. We have highlighted the changes within the manuscript. Here is a point-by-point the response to the reviewers' comments.

In the abstract:

1. The authors write "we report a case of a 37-year-old female patient with a history of borderline breast PTs", please add previous breast PT surgery treatments

Response: changes made in the new version

2. The patient had an uncommon complication", please mention the complication.

Response: mediastinal location of metastasis

In the report itself:

1. "The patient was diagnosed with borderline breast PTs ten years earlier, which was treated by surgical excision." Which breast, tumor size, skin involvement, safe margin of surgical resection, recurrence or not?

Response: Tumor size was 8 x7 x5 cm, removed surgically with no skin involvement and safe margin of resection (added in the new version)

2. What is the operation of metastatic malignant phyllodes tumor resection, including resection of mitral valve or cardiac tissue, lung resection (lobectomy) or debulking surgery? Reconstruction or not?

Response: Surgery consisted on total intra cardiac metastasis resection with mitral valve conservation and right pneumonectomy without reconstruction.(added in the new version)

3. "The patient was discharged from the hospital after having an echocardiographic check-up, which demonstrated no residual tumor." Please show the echocardiographic image.

Response: no echocardiographic image was available

4. "Three months after the surgery, she died from a huge relapse of mediastinal mass with tracheal invasion.", please show the CT image.

Response: CT image added in the new version

5. In discussion, I could find more than a dozen articles on metastatic malignant phyllodes tumor of the heart, please summarize and discuss the differences between your case and theirs.

Response: changes were made in the new version

6. There are many errors in the references, please correct them.

Response: errors were corrected

Competing Interests: no competing interests

Reviewer Report 15 June 2022

<https://doi.org/10.5256/f1000research.121589.r139615>

© 2022 Ibn Hadj Amor H. This is an open access peer review report distributed under the terms of the [Creative Commons Attribution License](#), which permits unrestricted use, distribution, and reproduction in any medium, provided the original work is properly cited.



Hassen Ibn Hadj Amor 

¹ Taher Sfar university hospital, Mahdia, Tunisia

² Faculty of Medicine of Monastir, Monastir, Tunisia

This is an excellent case report of a young patient presenting with dyspnea class IV on the New York Heart Association functional classification, including a cascade of exploration including Transthoracic echocardiography, Transesophageal echocardiography, CT-scan and cardiac magnetic resonance imaging as well as the histological study, concluded that the mitral valve was obstructed by a metastatic malignant phyllodes tumor. The patient required emergency valve surgery with the particularity of preserving the native valve and removing only the metastatic mass (urgent life-saving therapeutic strategy). It is a very rare cause of mitral obstruction where only the histological examination allowed to differentiate it with certainty.

The iconography is well done. Discussion is sufficient with a good review of the literature

Is the background of the case's history and progression described in sufficient detail?

Yes

Are enough details provided of any physical examination and diagnostic tests, treatment given and outcomes?

Yes

Is sufficient discussion included of the importance of the findings and their relevance to future understanding of disease processes, diagnosis or treatment?

Yes

Is the case presented with sufficient detail to be useful for other practitioners?

Yes

Competing Interests: No competing interests were disclosed.

Reviewer Expertise: Cardiology

I confirm that I have read this submission and believe that I have an appropriate level of expertise to confirm that it is of an acceptable scientific standard.

The benefits of publishing with F1000Research:

- Your article is published within days, with no editorial bias
- You can publish traditional articles, null/negative results, case reports, data notes and more
- The peer review process is transparent and collaborative
- Your article is indexed in PubMed after passing peer review
- Dedicated customer support at every stage

For pre-submission enquiries, contact research@f1000.com

F1000Research