

Transcatheter Closure of Atrial Septal Defects Improves Cardiac Remodeling and Function of Adult Patients with Permanent Atrial Fibrillation

Liang Chen¹, Yuan Bai¹, Fei-Yu Wang¹, Zhi-Gang Zhang², Xing-Hua Shan³, Tao Chen¹, Xian-Xian Zhao¹, Yong-Wen Qin¹

¹Department of Cardiology, Changhai Hospital, Second Military Medical University, Shanghai 200433, China

²Department of Cardiology, Fuzhou General Hospital of Nanjing Military Command, Fuzhou, Fujian 350025, China

³Standardized Base for Training Residents, Changhai Hospital, Second Military Medical University, Shanghai 200433, China

Abstract

Background: Permanent atrial fibrillation (AF) is the most common form of dysrhythmia associated with atrial septal defects (ASDs) in patients older than 40 years. However, little is known about cardiac remodeling after transcatheter closure in patients with permanent AF. This study was designed to compare cardiac events and remodeling effects after transcatheter closure in such patients.

Methods: Clinical data of 289 adult patients older than 40 years who underwent ASD closure at our center were analyzed retrospectively. Of them, 63 patients with permanent AF were assigned to the case group, and the other 226 patients without permanent AF were assigned to the control group. Cardiac events and changes in left and right cardiac cavity dimensions before the procedure and 6 months after the procedure were compared between the two groups.

Results: Patients in the case group were significantly older than those in the control group. The right ventricular (RV) volume and right atrial (RA) volume were decreased significantly in both the groups during a median follow-up period of 6 months after closure ($P < 0.001$). The left atrial dimensions, left ventricular end-systolic dimensions, left ventricular end-diastolic dimensions and left ventricular ejection fraction showed no significant change before and after the procedure in both the groups. Changes of the RV volume and RA volume in the case group were significantly smaller than those in the control group ($P = 0.005$ and $P < 0.001$). The New York Heart Association cardiac function was improved in both the groups during the 6 months follow-up period.

Conclusions: The transcatheter closure of ASD can improve the cardiac remodeling and cardiac function in patients with or without AF.

Key words: Atrial Fibrillation; Cardiac Catheterization; Heart Septal Defects; Atrial

INTRODUCTION

Atrial septal defect (ASD) is one of the most common congenital heart diseases in adults. Adult patients with unrepaired ASD are at risk of developing major cardiovascular events, especially atrial fibrillation (AF). Transcatheter closure has evolved as a standard therapeutic option for the treatment of ASD in adult patients.^[1] Correction of ASD can not only improve the symptoms and increase exercise tolerance but improve cardiac chamber geometry and hemodynamics.^[1] There is an increased incidence of AF in adult patients with ASD, especially in those over 40 years.^[2,3] AF-related remodeling is believed to underlie the progressive nature of the arrhythmia and contribute to the

complexity of long-term management.^[4-6] Up to now, little is known about whether transcatheter closure could reverse cardiac remodeling in ASD patients with permanent AF. In this retrospective clinical study, we analyzed ASD patients admitted in our center with and without AF who underwent successful transcatheter closure in an attempt to determine the feasibility of device closure of ASD and observe resultant hemodynamic changes in such patients.

METHODS

Study population

The clinical medical records of 289 consecutive adult patients older than 40 years who underwent transcatheter ASD closure at our center between October 2009 and October 2013 were analyzed retrospectively. The exclusion criteria were, patients with transthoracic

Access this article online

Quick Response Code:



Website:
www.cmj.org

DOI:
10.4103/0366-6999.152617

Address for correspondence: Dr. Yong-Wen Qin,
Department of Cardiology, Changhai Hospital,
Second Military Medical University, Shanghai 200433, China
E-Mail: chqinyw@163.com

echocardiographic maximal ASD diameter >40 mm and rims <5 mm. Of the 289 ASD patients, 63 (21.8%) patients with permanent AF were selected as the case group and the other 226 (78.2%) patients without permanent AF as the control group.

Transcatheter atrial septal defect closure

The whole procedure was performed under local anesthesia. Complete hemodynamic evaluation right-heart catheterization and pulmonary arteriography were performed. The size of ASD was determined by transthoracic echocardiography during the procedure. The SHSMA™ (Shanghai Shape Memory Alloy Co., Ltd., Shanghai, China) ASD occluder was used in all patients. The selected device was 3–6 mm larger than the defect diameter. When the occluder was deployed across the defect, its position and stability were assessed by fluoroscopy and transthoracic echocardiography.

Transthoracic echocardiography

Echocardiography was performed using a Sonos iE33 Machine (Philips Medical Systems, USA) according to a standard protocol including color Doppler data. Measurement was performed by two trained cardiologists independently, and any disagreement was solved by discussion. The right and left ventricular volumes were measured in an apical four-chamber view at end-diastole. The right atrial (RA) volume and left atrial (LA) dimension were measured in the same view at end-systole. The left ventricular end-systolic dimension (LVESD), left ventricular end-diastolic dimension (LVEDD) and left ventricular ejection fraction were also measured. Each measurement was averaged from five consecutive cardiac cycles.

Follow-up protocol

All patients were followed-up for at least 6 months after the procedure. An appropriate long-term warfarin dose was used in the case group with the international normalized ratio maintained between 2.0 and 2.5. Aspirin (3–5 mg/kg per day) was administered for 6 months in the control group. Electrocardiographic monitoring, chest X-ray, and transthoracic echocardiography were performed at 1 and 6 months after the procedure. The cardiac geometric location of the occluder, thrombi, valvular regurgitation and residual shunt were also evaluated by transthoracic echocardiography.

Statistical analysis

Nominal data presented as frequencies and percentages. Continuous data are presented as median and range if not normally distributed and as mean ± standard deviation if normally distributed. Nominal data between groups were compared using Chi-square or Fisher's exact test. The variables of pre and postprocedure were compared using paired, two-sided Student's *t*-test. Continuous data between groups were compared using unpaired, two-sided Student's *t*-test. *P* < 0.05 was defined as significant. Data were analyzed using Statistical Package for Social Sciences, version 20.0, for Mac (SPSS Inc., Chicago, Illinois, USA).

RESULTS

Clinical characteristics

In the case group, there were 27 (42.9%) males and 36 (57.1%) females with a mean age of 68.3 ± 15.4 years. In the control group, there were 99 (43.8%) males and 127 (56.2%) females with a mean age of 47.4 ± 13.9 years. Patients in the case group were significantly older than those in the control group (*P* < 0.001). The clinical characteristics of the two groups are listed in Table 1.

Cardiac geometry before and after closure in patients with atrial fibrillation

The cardiac geometry was significantly improved immediately after the procedure and during the follow-up period in both groups. In the case group, the right ventricular (RV) end-diastolic volume decreased from 81.57 ± 31.47 ml preprocedure to 62.92 ± 19.07 ml postprocedure during a median interval of 6 months after closure (*P* < 0.001), and the RA volume decreased from 106.93 ± 54.17 ml preprocedure to 79.07 ± 40.39 ml postprocedure (*P* < 0.001). The LA dimension, LVESD, LVEDD and left ventricular ejection fraction remained unchanged significantly [Table 2].

Cardiac geometry before and after closure in patients without atrial fibrillation

Both RV end-diastolic volume and RA volume decreased significantly in the control group during the follow-up period from 76.72 ± 27.56 to 59.39 ± 10.21 ml (*P* < 0.001) and from 84.27 ± 32.68 to 43.21 ± 20.48 ml, respectively (*P* < 0.001). The LA dimension, LVESD, LVEDD and left ventricular ejection fraction remained unchanged significantly [Table 2].

Comparison of cardiac geometric change between the two groups

The RV and RA volumes were decreased significantly in both the groups during the 6 months follow-up period after closure. Changes of the RV volume and RA volume in the case group were significantly smaller as compared with those of the control group (20.74 ± 10.68 ml to 24.69 ± 9.46 ml, *P* = 0.005; 27.53 ± 12.68 ml to 36.63 ± 13.79 ml, *P* < 0.001) [Figure 1]. Of the 63 patients with permanent AF in the case

Table 1: Baseline clinical characteristics

Variable	Case group (<i>n</i> = 63)	Control group (<i>n</i> = 226)	<i>P</i>
Age (years)	68.3 ± 15.4	47.4 ± 13.9	<0.001
Female, <i>n</i> (%)	36 (57.1)	127 (56.2)	0.947
ASD diameter (mm)	17.8 ± 9.3	18.4 ± 8.9	0.738
Device size (mm)	22.6 ± 7.2	23.1 ± 6.6	0.681
Hypertension, <i>n</i> (%)	24 (38.1)	67 (29.6)	0.216
Diabetes mellitus, <i>n</i> (%)	5 (7.9)	9 (4.0)	0.201
Cardiac function, <i>n</i> (%)			
NYHA I	25 (39.7)	95 (42.0)	0.756
NYHA II	19 (30.2)	129 (57.1)	<0.001
NYHA III	9 (14.3)	2 (0.9)	<0.001

ASD: Atrial septal defect; NYHA: New York Heart Association.

group, 25 (39.7%), 29 (46.0%), and 9 (14.3%) patients were considered to have New York Heart Association (NYHA) Class I, II and III, respectively. Of the 226 patients in the control group, 95 (42.0%), 129 (57.1%), and 2 (0.9%) were graded as having NYHA Class I, II and III, respectively. NYHA functional classification was improved in both the groups after the procedure [Figure 2].

DISCUSSION

Our study demonstrated that the transcatheter closure of ASD in patients with permanent AF is safe and feasible as in the case with patients without AF. Transcatheter ASD closure can improve the patient's quality of life and cardiac remodeling even in patients with permanent AF.^[7,8] In addition, it can improve the symptoms and reverse remodeling of the right-heart in adults of all ages.^[1] Majunke *et al.*^[9] studied 650 adult ASD patients and concluded that ASD in adults is safe and effective, offering excellent long-term outcomes. Patel *et al.*^[8] also showed that ASD closure could decrease the RV size and improve the clinical symptoms significantly with an extremely high success rate. In our study, the NYHA cardiac function was improved in both groups after transcatheter closure. The right-heart size was decreased significantly in all patients. Although most adult ASD patients with permanent AF in our series were older

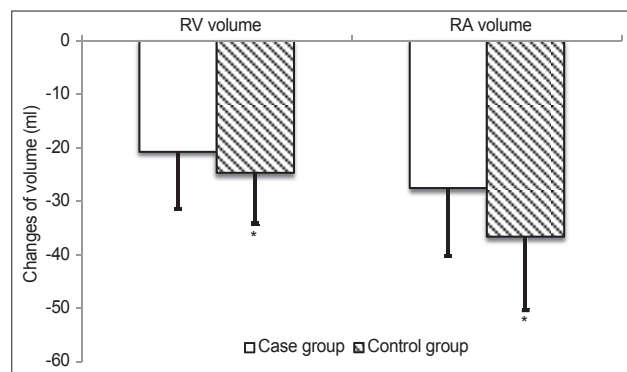


Figure 1: Changes of the right ventricular (RV) volume and right atrial (RA) volume. The 6 months follow-up period showed that changes of the RV volume and RA volume in the case group were significantly less than those in the control group ($P < 0.05$; RV: Right ventricular; RA: Right atrial).

and often had significant comorbidities, our study still brought encouraging outcomes in the cardiac function and structural improvement. Above all, transcatheter ASD closure should be recommended as the treatment of choice in patients with and without permanent AF.^[10]

The present study showed that the magnitude of the decrease in the RA and RV size in patients with permanent AF was smaller than that in patients without AF. This may be partly due to the older age of the patients in the case group. Patients with significant shunting are more likely to develop RV failure and atrial tachycardia, which can lead to significant morbidity and potential mortality.^[1] AF is more frequently seen in older patients, and not a few patients may continue to experience fibrillation after ASD closure.^[11,12] Rosas *et al.*^[13] analyzed 200 un-operated patients over 40 years and found that age was a predictor of poor outcomes.^[13] Thus, ASD closure should be

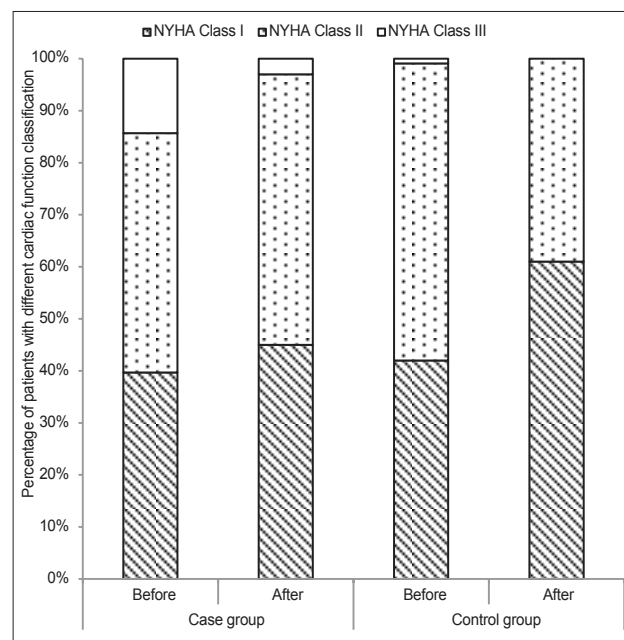


Figure 2: Heart function improvement in both the groups. In the case group, 25 (39.7%), 29 (46.0%) and 9 (14.3%) patients were considered to have NYHA Class I, II and III. In the control group, 95 (42.0%), 129 (57.1%) and 2 (0.9%) were graded as having NYHA Class I, II and III. NYHA cardiac function was improved in both the groups after the procedure (NYHA: New York Heart Association).

Table 2: Echocardiographic variables before and 6 months after ASD closure

Variable	Case group (n = 63)			Control group (n = 226)		
	Before	After	P	Before	After	P
LVESD (mm)	26.35 ± 2.92	26.91 ± 2.95	0.186	23.63 ± 3.26	23.89 ± 2.95	0.698
LVEDD (mm)	40.71 ± 4.24	41.55 ± 3.51	0.132	37.28 ± 4.44	36.17 ± 3.91	0.063
LVEF (%)	65.18 ± 4.66	64.83 ± 4.38	0.727	66.21 ± 3.12	65.89 ± 3.92	0.725
LA dimensions (mm)	42.70 ± 9.55	40.96 ± 10.07	0.263	35.19 ± 7.43	33.97 ± 8.15	0.365
RV volume (ml)	81.57 ± 31.47	62.92 ± 19.07	<0.001	76.72 ± 27.56	59.39 ± 10.21	<0.001
RA volume (ml)	106.93 ± 54.17	79.07 ± 40.39	<0.001	84.27 ± 32.68	43.21 ± 20.48	<0.001

LVESD: Left ventricular end-systolic dimensions; LVEDD: Left ventricular end-diastolic dimensions; LVEF: Left ventricular ejection fraction; LA: Left atrial; RV: Right ventricular; RA: Right atrial; ASD: Atrial septal defect.

considered as early as possible after confirmation of the diagnosis.

However, many adult ASD patients in China remain unrepaired even though the transcatheter procedure has been well practiced for nearly two decades.^[14,15] One reason is the unbalanced development of the medical conditions; for instance echocardiography remains unavailable and inaccessible in many central and western regions of China, especially in remote mountainous areas, and therefore ASD cannot be detected at an early age in many patients. Another reason is the economic gap between the urban and rural populations. Although ASD was detected in some patients during their youth hood, treatment was often delayed because of the economic reason. These patients often progressed to right-heart failure and AF. Taniguchi *et al.*^[2] analyzed nine old ASD patients with permanent AF and found that the NYHA cardiac function was improved in all patients. RV remodeling was also improved significantly in terms of both right and left diameter ratios and plasma B-type natriuretic peptide level. Our study confirmed that both the structure and function of the right-heart were improved significantly in all ASD patients with AF after occlusion. As a result, the quality of life in these patients was also improved significantly. It can be concluded that the closure of the defect is still the right thing to do in patients with ASD and AF.^[16]

Additionally, as patients with AF are at high risk of developing ischemic events, anticoagulation therapy should be considered instead of antiplatelet medication.^[17,18] No device thrombosis or major bleeding complications were observed during the 6 months follow-up period in both the groups, indicating that anticoagulation therapy with warfarin is safety and effective. In addition, given potential thrombi in the LA appendage, transesophageal echocardiography should be performed before the procedure. In the present study, transesophageal echocardiography was not taken in all patients with AF. However, no ischemic complication occurred during the follow-up period, partly because of the relatively small sample size in the case group.

The present study has several limitations, including those inherent to the retrospective design and the relatively short follow-up period. Although thrombus formation was not detected during the follow-up period, long-term follow-up evaluation is mandatory. Evaluation by transesophageal echocardiography may be helpful to examine thrombus formation more closely.

In conclusion, closure of ASD in patients with permanent AF is safe and feasible. Our study has demonstrated that the procedure can improve cardiac remodeling and heart function in patients both with and without AF, even in patients with permanent AF.

REFERENCES

1. Dehghani H, Boyle AJ. Percutaneous device closure of secundum atrial

- septal defect in older adults. *Am J Cardiovasc Dis* 2012;2:133-42.
2. Taniguchi M, Akagi T, Ohtsuki S, Okamoto Y, Tanabe Y, Watanabe N, *et al.* Transcatheter closure of atrial septal defect in elderly patients with permanent atrial fibrillation. *Catheter Cardiovasc Interv* 2009;73:682-6.
3. Berger F, Vogel M, Kramer A, Alexi-Meskishvili V, Weng Y, Lange PE, *et al.* Incidence of atrial flutter/fibrillation in adults with atrial septal defect before and after surgery. *Ann Thorac Surg* 1999;68:75-8.
4. Climent AM, Guillem MS, Atienza F, Fernández-Avilés F. Electrophysiological characteristics of permanent atrial fibrillation: insights from research models of cardiac remodeling. *Expert Rev Cardiovasc Ther* 2015;13:1-3.
5. Kwak JG, Seo JW, Oh SS, Lee SY, Ham EK, Kim WH, *et al.* Histopathologic analysis of atrial tissue in patients with atrial fibrillation: Comparison between patients with atrial septal defect and patients with mitral valvular heart disease. *Cardiovasc Pathol* 2014;23:185-92.
6. Nattel S, Harada M. Atrial remodeling and atrial fibrillation: Recent advances and translational perspectives. *J Am Coll Cardiol* 2014;63:2335-45.
7. Komar M, Przewlocki T, Olszowska M, Sobien B, Podolec P. The benefit of atrial septal defect closure in elderly patients. *Clin Interv Aging* 2014;9:1101-7.
8. Patel A, Lopez K, Banerjee A, Joseph A, Cao QL, Hijazi ZM. Transcatheter closure of atrial septal defects in adults > or = 40 years of age: Immediate and follow-up results. *J Interv Cardiol* 2007;20:82-8.
9. Majunke N, Bialkowski J, Wilson N, Szkutnik M, Kusa J, Baranowski A, *et al.* Closure of atrial septal defect with the Amplatzer septal occluder in adults. *Am J Cardiol* 2009;103:550-4.
10. Baumgartner H, Bonhoeffer P, De Groot NM, de Haan F, Deanfield JE, Galie N, *et al.* ESC Guidelines for the management of grown-up congenital heart disease (new version 2010). *Eur Heart J* 2010;31:2915-57.
11. Berger F, Vogel M, Kretschmar O, Dave H, Prêtre R, Dodge-Khatami A. Arrhythmias in patients with surgically treated atrial septal defects. *Swiss Med Wkly* 2005;135:175-8.
12. Giardini A, Donti A, Sciarra F, Bronzetti G, Mariucci E, Picchio FM. Long-term incidence of atrial fibrillation and flutter after transcatheter atrial septal defect closure in adults. *Int J Cardiol* 2009;134:47-51.
13. Rosas M, Attie F, Sandoval J, Castellano C, Buendia A, Zabal C, *et al.* Atrial septal defect in adults > or = 40 years old: Negative impact of low arterial oxygen saturation. *Int J Cardiol* 2004;93:145-55.
14. Chen QH, Liu FY, Wang XQ, Qi GR, Liu PF, Jin XH, *et al.* A cross-sectional study of congenital heart disease among children aged from 4 to 18 years at different altitudes in Qinghai province, China (in Chinese). *Chin J Epidemiol* 2009;30:1248-51.
15. Wang G, Chen L, Wang Y, Wen C, Li T, Zhi G, *et al.* Transcatheter closure of secundum atrial septal defects using Amplatzer device. *Chin Med J* 2000;113:967-71.
16. Moodie DS. Transcatheter closure of adults with atrial septal defect and atrial fibrillation – The right thing to do. *Catheter Cardiovasc Interv* 2009;73:687.
17. January CT, Wann LS, Alpert JS, Calkins H, Cigarroa JE, Cleveland JC Jr, *et al.* 2014 AHA/ACC/HRS guideline for the management of patients with atrial fibrillation: Executive summary: A report of the American College of Cardiology/American Heart Association Task Force on practice guidelines and the Heart Rhythm Society. *Circulation* 2014;130:2071-104.
18. Camm AJ, Lip GY, De Caterina R, Savelieva I, Atar D, Hohnloser SH, *et al.* 2012 focused update of the ESC Guidelines for the management of atrial fibrillation: An update of the 2010 ESC Guidelines for the management of atrial fibrillation. Developed with the special contribution of the European Heart Rhythm Association. *Eur Heart J* 2012;33:2719-47.

Received: 16-12-2014 **Edited by:** Li-Shao Guo

How to cite this article: Chen L, Bai Y, Wang FY, Zhang ZG, Shan XH, Chen T, Zhao XX, Qin YW. Transcatheter Closure of Atrial Septal Defects Improves Cardiac Remodeling and Function of Adult Patients with Permanent Atrial Fibrillation. *Chin Med J* 2015;128:780-3.

Source of Support: Nil. **Conflict of Interest:** None declared.