

Understanding The Endometrium At Menopause: A Sonologist's View

Dr Mamata Deenadayal MD

Department of Infertility, Mamta Fertility Centre, Secunderabad, Telangana, India

INTRODUCTION

Pathology of the endometrium is common, the presentation and management of the disease depends on a woman's age, her menstrual history, reproductive history, co-morbidities and use of medications. It is important to distinguish benign from malignant premalignant conditions.

The most common and first line used imaging modality for evaluating the endometrium is pelvic ultrasound with transvaginal and transabdominal

This pictorial review depicts the normal and abnormal appearance of the endometrium at post menopause

TIMING AND METHOD

- Transvaginal is an ideal method. A transabdominal scan may be needed in cases of large fibroids, a globally enlarged uterus, virgins, and is vaginismus or secondary vaginal stenosis. Transrectal -If transabdominal is inconclusive and is acceptable to the woman.
- In a postmenopausal woman not on hormone therapy or on a continuous combined regime endometrium is assessed by a transvaginal scan, on any day when on cyclic combined regime 5–10 days after the last progestin pill^[1].

TECHNIQUE

- Start with the identification of the bladder and cervix.
- The position of the uterus is noted and measurements taken.
- The uterus is scanned in the sagittal plane from cornu to cornu and in the (oblique) transverse plane from the cervix to the fundus.
- In cases of difficulty to trace endometrium
 - a. Trace from the endocervical canal
 - b. The angle of insonation between the endometrium and the ultrasound beam should be 90° to optimize image quality, if possible
 - c. Enhanced sonography by instilling saline or gel

THE INTERNATIONAL ENDOMETRIAL TUMOR ANALYSIS (IETA)

The International Endometrial Tumor Analysis (IETA)

group was formed in Chicago at the World Congress of Ultrasound in Obstetrics and Gynecology in 2008 with the aim of agreeing on terms and definitions to describe ultrasound findings in the uterine cavity. A consensus opinion from the International Endometrial Tumor Analysis (IETA) group was developed on the terms, definitions and measurements to describe the sonographic features of the endometrium and intrauterine lesions^[2].

STUDY OF THE ENDOMETRIUM IN MENOPAUSE IETA GUIDELINES:

Quantitative:

Thickness of the endometrium-visible, interrupted, invisible

Qualitative:

1. Echogenicity
 - a. Uniform-homogeneous, hyperechogenic, isoechogenic or hypoechogenic
 - b. Non-uniform-homogeneous with regular or irregular cysts, heterogeneous with or without cysts.
2. Pattern-three-layer or monolayer pattern.
3. Endometrial midline-linear, non-linear, irregular or not defined
4. Bright edge-A bright edge is the echo formed by the interface between an intracavitary lesion and the endometrium.
5. Endo-myometrial junction-regular, irregular, interrupted or not visible.
6. Intracavity fluid.

Color-Doppler

The Color-Doppler score is a subjective assessment of the amount of color, reflecting the vascularity, and is scored as

- a.1 (no color), b.2 (minimal color), c.3 (moderate color)
- d. 4(abundant color).

The vascular pattern may be a

- a. single dominant vessel with or without branching
- b. multiple vessels of focal or multifocal origin,
- c. scattered flow
- d. circular

Sonohysterography

In fluid-instillation sonography or enhanced ultrasonography, fluid is instilled into the uterine cavity transcervically to provide enhanced endometrial visualization during transvaginal ultrasound examination. The technique improves sonographic detection of

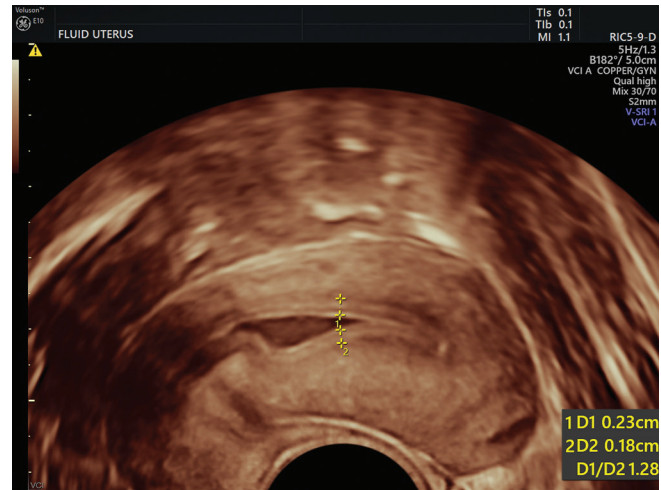
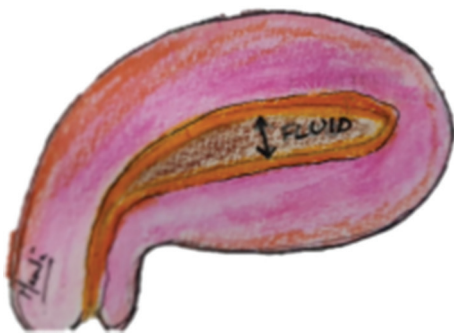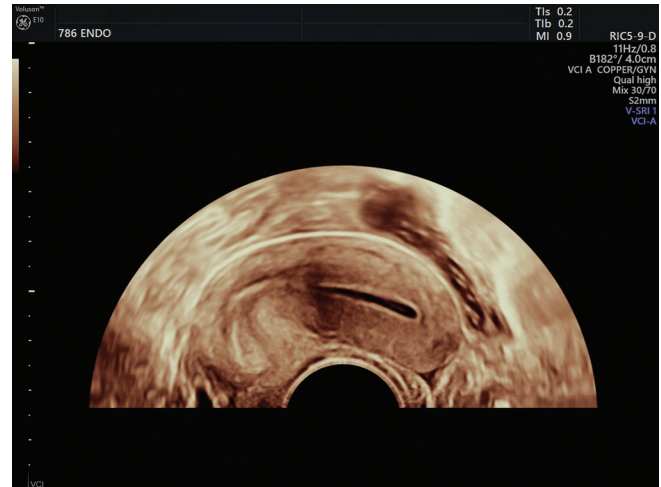
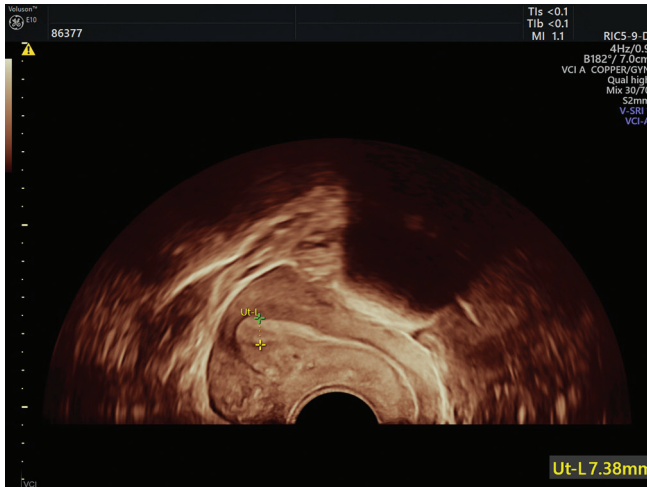
endometrial pathology, such as polyps, hyperplasia, cancer, leiomyomas, and adhesions. Endometrial thickness of both endometrial layers.

In the presence of an intracavitary lesion, look for extent, type of localized lesion, echogenicity, outline, color score and vascular pattern.

ENDOMETRIUM-IMPLEMENTATION OF IETA

Quantitative Assesment

Endometrial thickness : how should it be measured?

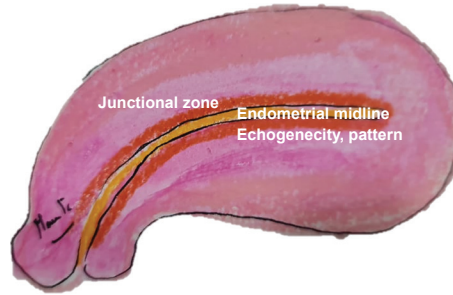
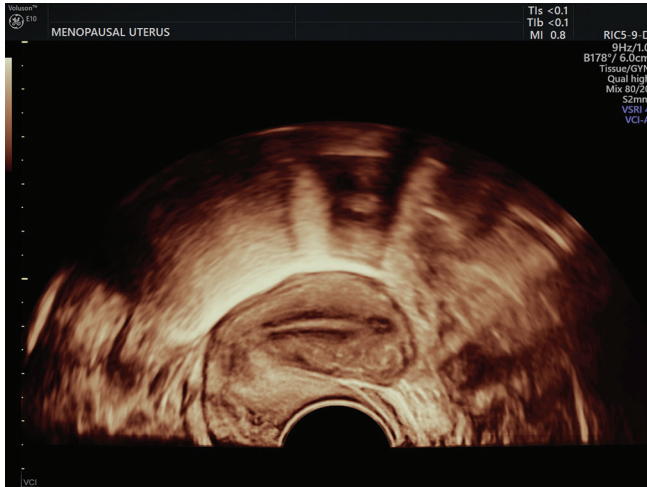


The endometrium should be measured where it appears to be at its thickest.

When intracavitary fluid is present, the thickness of both single layers is measured in the sagittal plane and the sum is recorded.

If the endometrium is thickened asymmetrically, the anterior and posterior endometrial thicknesses should also be reported separately.

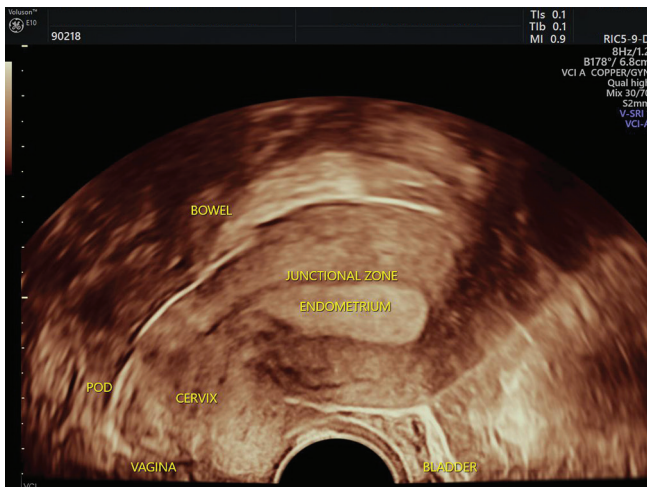
QUALITATIVE ASSESMENT



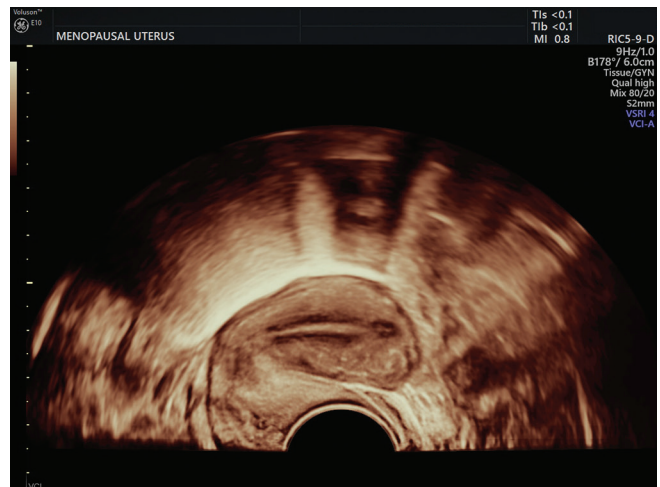- Endometrial echogenicity and pattern
- Endometrial midline
- “Bright edge”
- Endo-myometrial junction

ENDOMETRIUM AT REPRODUCTIVE STAGE, AT MENOPAUSE AND POSTMENOPAUSE

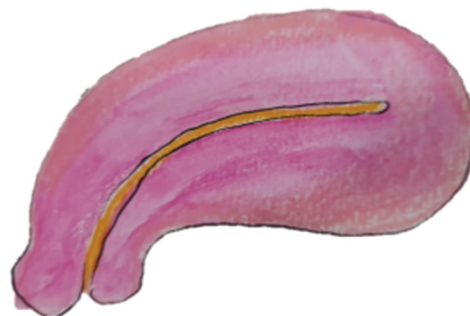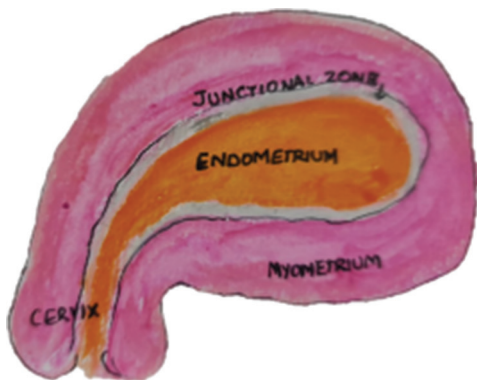
Reproductive age



Menopause



Normally the menopausal endometrium is thin. Sometimes it is difficult to see and measure as in upright position, vascular calcifications and calcified fibroids.



POST MENOPAUSAL UTERUS

- Smaller in size <7.5 cm
- Uterine body to cervix 1;1
- Calcified arcuate vessels – elderly post menopausal women

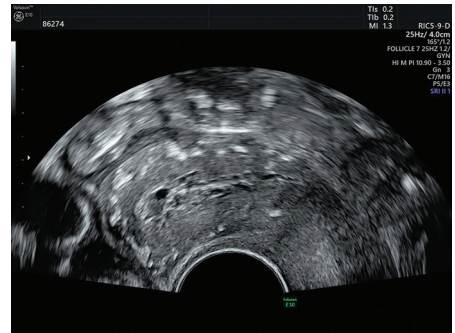
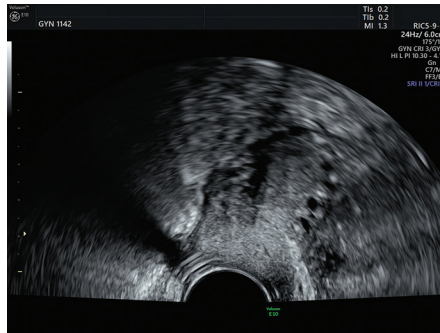
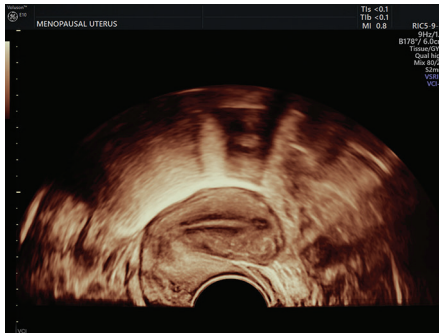
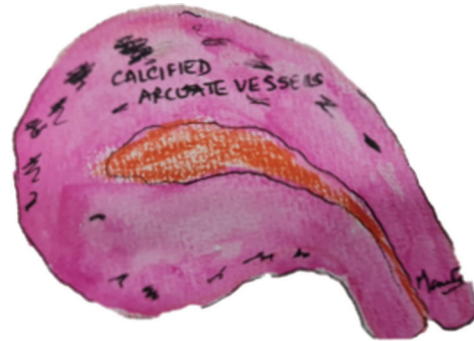Median endometrial thickness 2.9-3mm

Not measurable /not visible 10 %

>5 mm 7-24%

<5 mm 76-93 %^[3]

Do not measure the endometrium if you do not see it
Plan a sonohysterography



APPROACH TO POSTMENOPAUSAL ENDOMETRIUM

Asymptomatic - Pathology discovered incidentally on scan

Symptomatic - Scan on indication

Aim:

To understand the cause of bleeding

To estimate risk of endometrial cancer

In women with cancer to assess the tumor invasion

To determine the optimal biopsy procedure

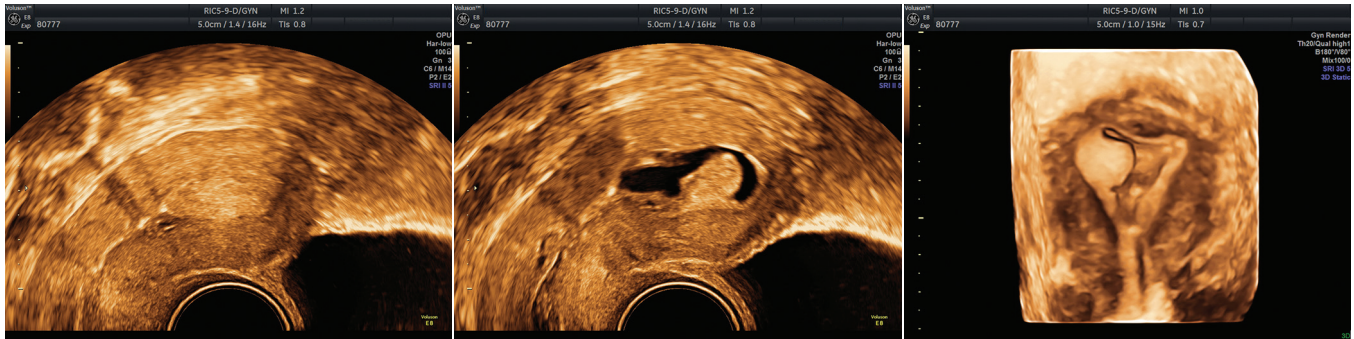THICKENED ENDOMETRIUM DIFFERENTIAL DIAGNOSIS

- Endometrial polyp
- Submucus myoma
- Hyperplasia endometrium
- Endometrial carcinoma

Endometrial hyperplasia and endometrial carcinoma (EC) are histological diagnosis

how to recognize on sonography?

FOLLOW THE IETA RULES



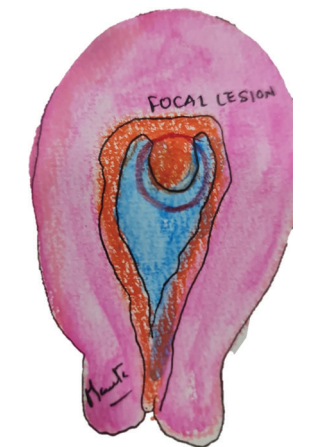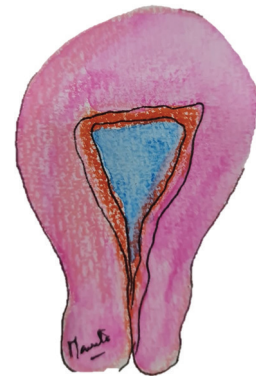WHAT ARE FOCAL LESIONS?

WHEN ENDOMETRIUM > 5 mm

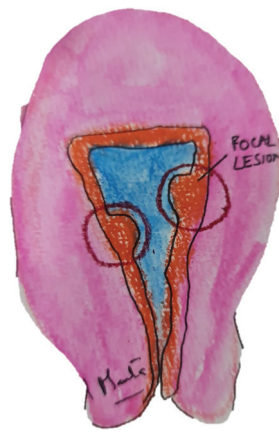
No focal lesions at SIS

Decreases the odds of pathology 30 times

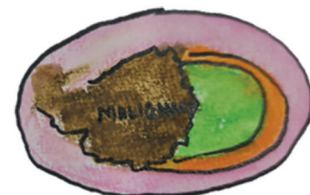
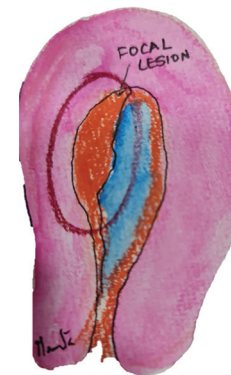Decreases the odds of cancer 20 times^[4]



POLYP



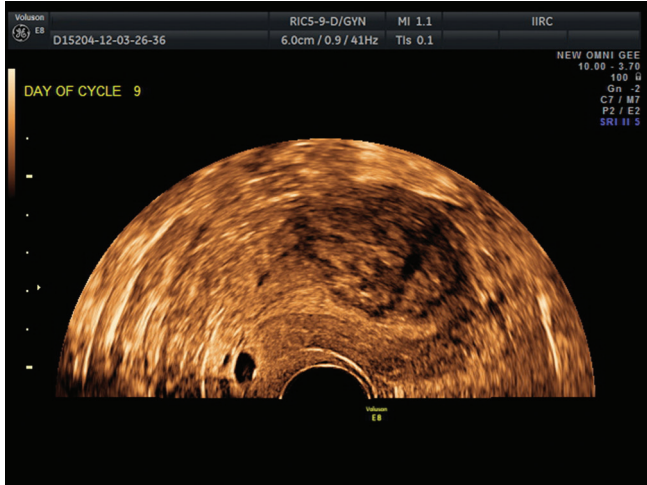
SUBMUCUS MYOMA



MALIGNANCY

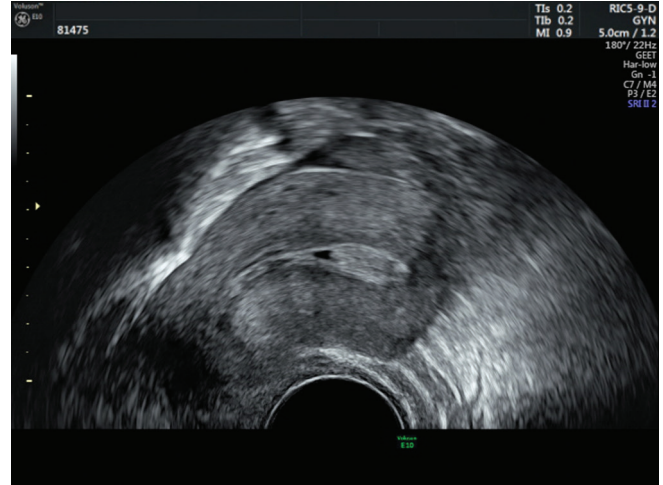
Irregular focal lesion is a strong sign of malignancy

MEASURING ENDOMETRIUM WITH AN INTRACAVITARY LESION



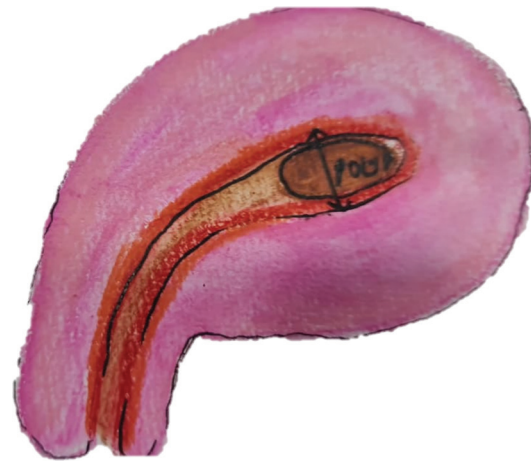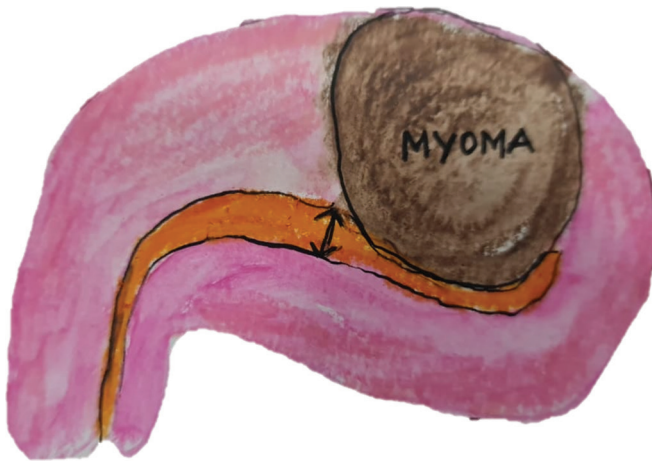
AN INTRACAVITARY MYOMA

Myoma should not be included in the measurement of endometrial thickness



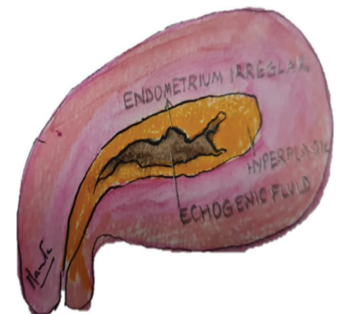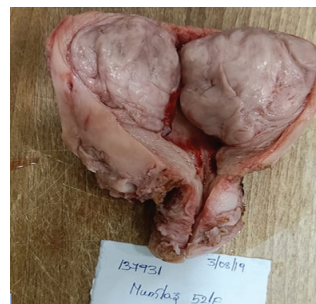
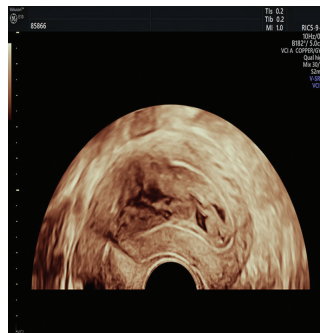
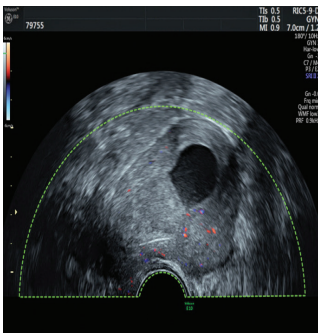
IF INTRACAVITARY PATHOLOGY PRESENT

The total endometrial thickness including the lesion should be recorded.



FLUID IN THE CAVITY

Fluid in the cavity in post menopausal uterus always exclude malignancy particularly if associated with a focal irregular lesion⁵



UNDERSTANDING ENDOMETRIAL THICKNESS IN POSTMENOPAUSAL BLEEDING

Endometrial thickness

- < 4 mm low risk cancer risk- Endometrial sampling if rebleed or at high risk for EC
- > 5 mm High risk - Endometrial pathology 80%, Uterine malignancy 25%
- Endometrium >4.5 mm saline sonography to determine focal or non focal

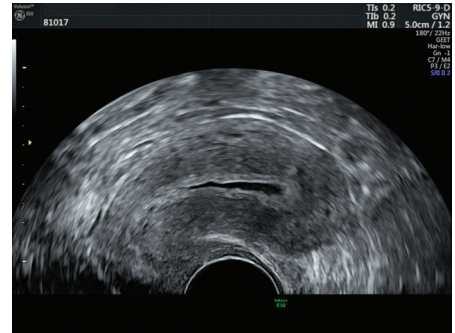
Normal looking polyp will have a malignant or premalignant potential of 6%

Unmeasurable not necessarily thin beware of cancer 5 % always perform hydrosalpingography

The sensitivity for detecting EC at 3mm is 98%, at 4mm is 95%, and at 5 mm is 90%. However, using a low threshold is associated with a high false-positive rate.

In women with homogeneous and normal morphology, those on MHT, and hypertensive medication, the acceptable combined thickness is 6 mm

A focal increased echogenicity or a diffuse heterogeneity in the endometrium in a thin endometrium -Endometrial sampling⁶

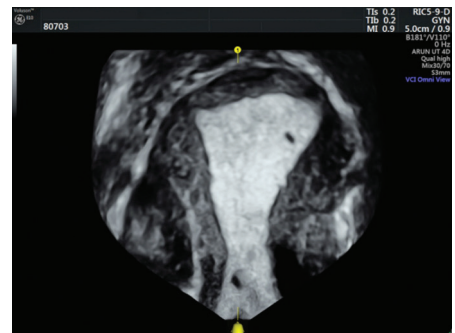
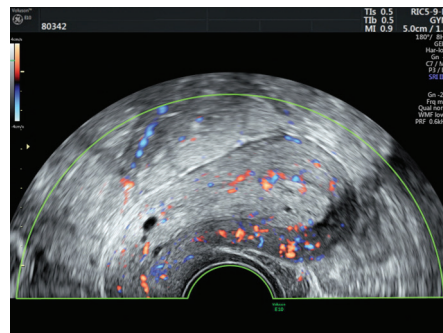
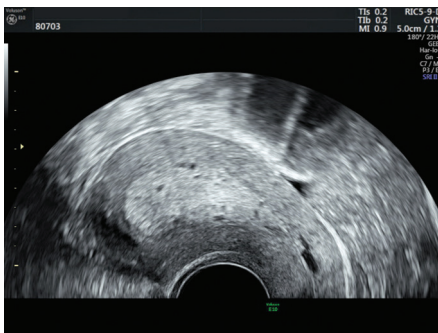


UNDERSTANDING ENDOMETRIAL THICKNESS IN ASYMPTOMATIC WOMEN

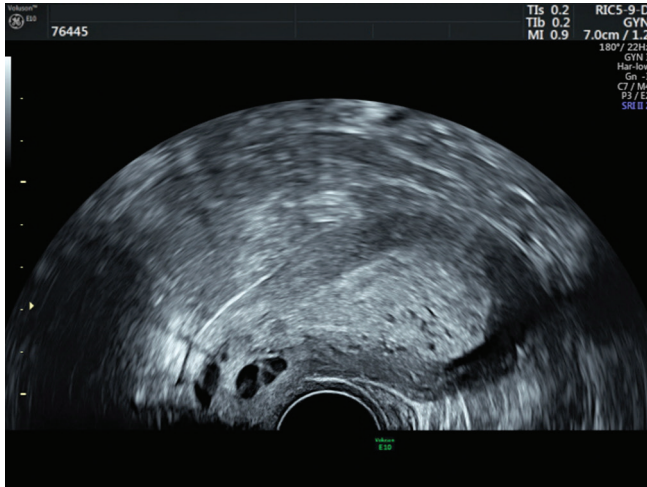
In an asymptomatic early postmenopausal woman, an endometrial thickness of >11 should prompt an endometrial biopsy⁷

ENDOMETRIAL HYPERPLASIA

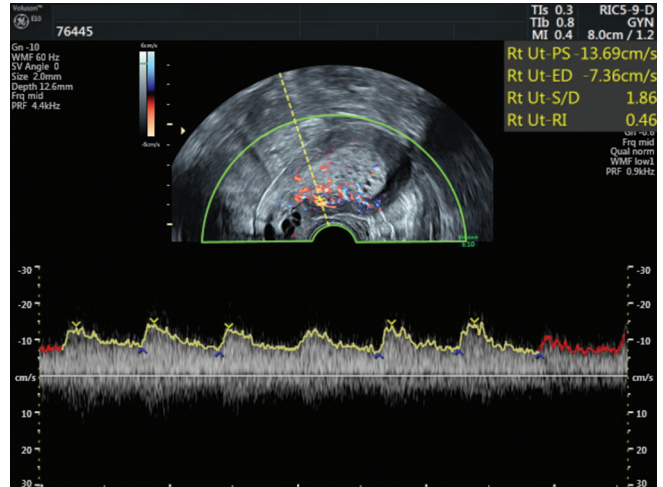
- Thick endometrium
- Hyperechogenic
- Possibly cysts in the endometrium
- Midline echo present
- No feeding vessel
- No polyp at hydrosalpingography



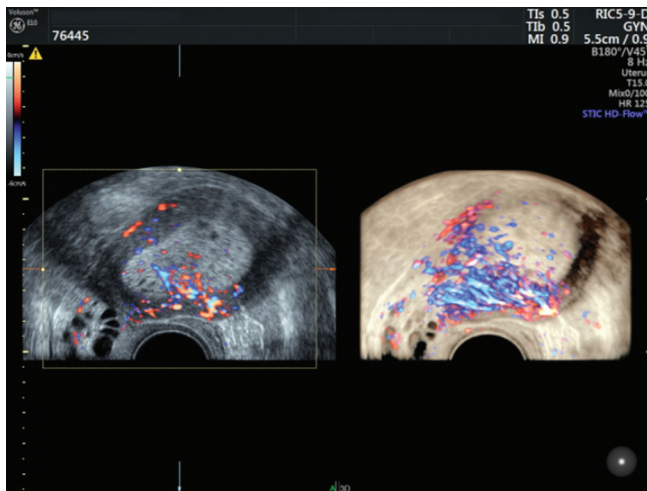
ENDOMETRIAL CANCER



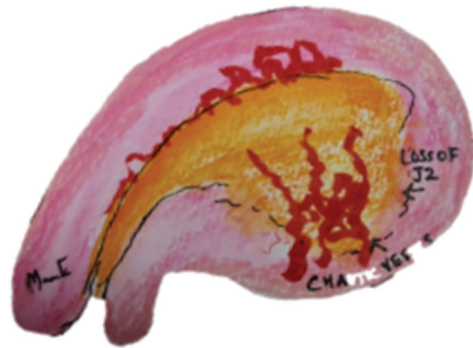Interrupted endo myometrial junctional zone



High color score > or equal to 3-4 - Malignant

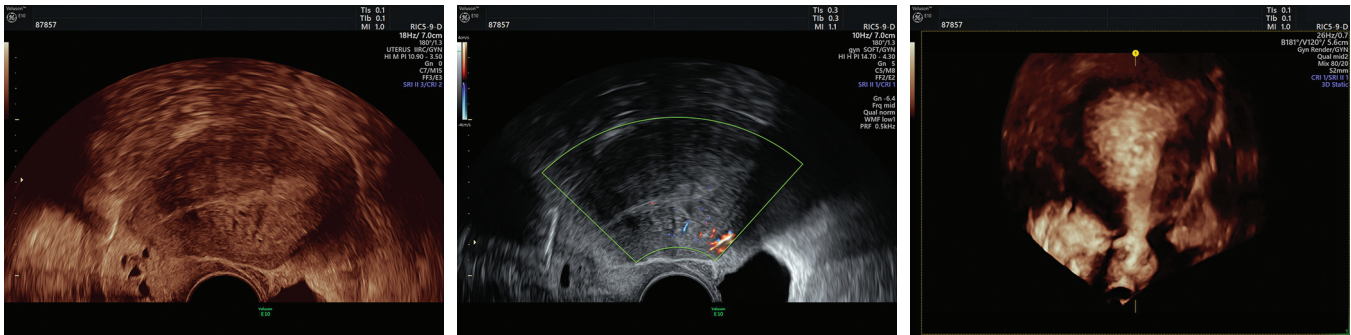
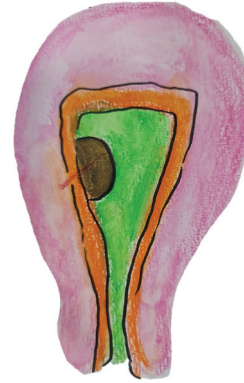

Multiple and densely packed irregular branching vessels



ENDOMETRIAL CARCINOMA

Thickened endometrium with heterogenous echotexture
 loss of endomyometrial junctional zone
 Color score 3-4
 Random dispersed not arising from EMJ
 Myometrium normal



EC LIMITED TO ENDOMETRIUM IN AN ASYMPTOMATIC POSTMENOPAUSAL WOMAN

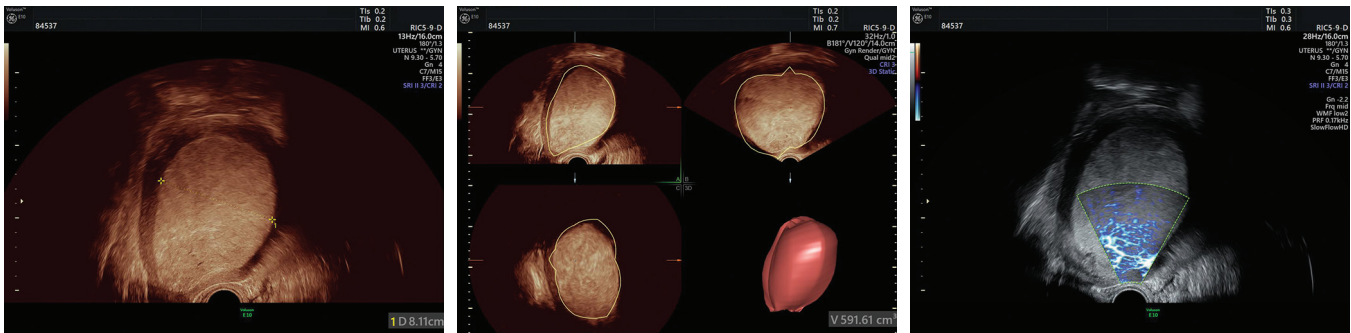
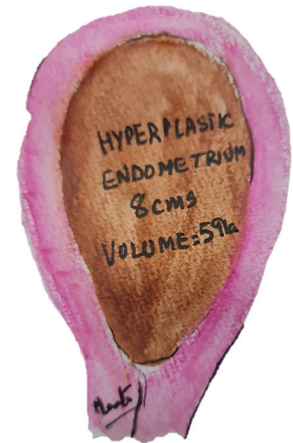
49 year old, asymptomatic, family h/o endometrial malignancy, detected during routine screening, endometrium 8 cm, volume 591cc, normal myometrium intact junctional zone marked increased vascularity

HISTOPATHOLOGY

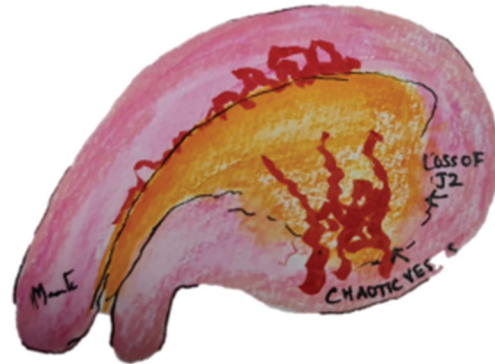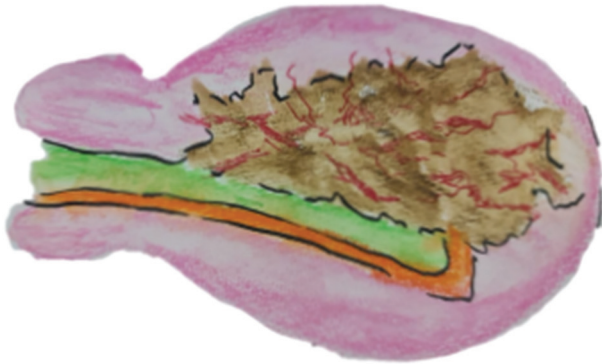
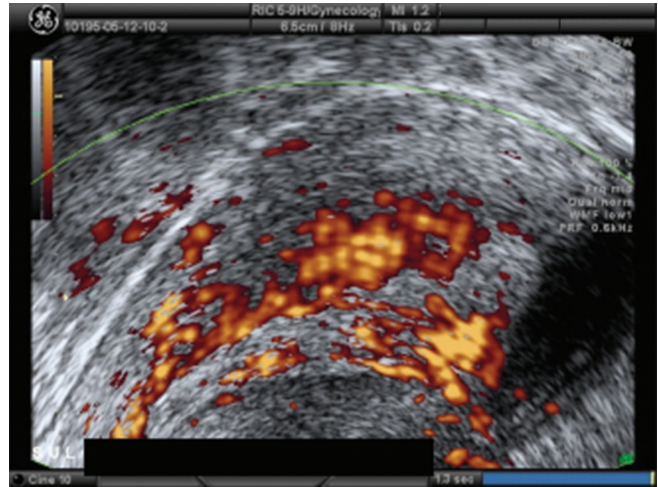
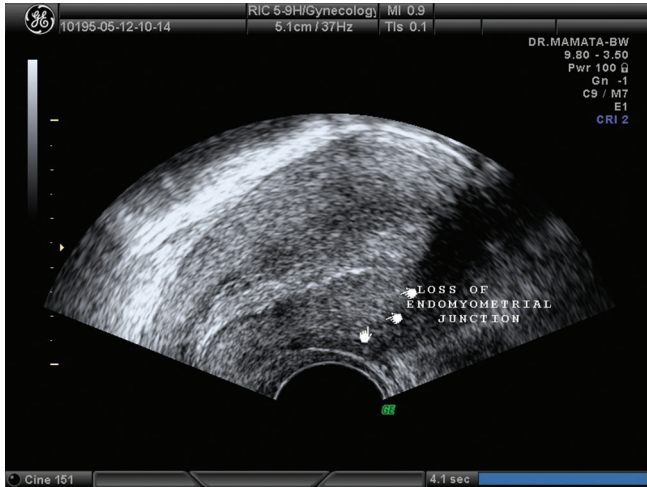
Endometrial intraepithelial neoplasia with atypia, few foci of endometrioid adenocarcinoma

INVASION LESS LIKELY

Echogenicity – hyperechogenicity
 Size – small tumor volume
 Regular junctional zone
 Thick tumor free myometrium
 Low tumor perfusion score 1-2 single /no vessel
 Histological grading low



ENDOMETRIAL CANCER IN POST MENOPAUSAL WOMAN WITH POSTMENOPAUSAL BLEEDING



Thickened endometrium 9.5 mm
Loss of endo myometrial junctional zone
Echogenicity – hypo or mixed echogenicity
Size - larger tumor volume

High tumor perfusion– score 3 -4
Histological grading - high

Declaration of patient consent

The authors certify that they have obtained all appropriate patient consent forms. In the form the patient(s) has/have given his/her/their consent for his/her/their images and other clinical information to be reported in the journal. The patients understand that their names and initials will not be published and due efforts will be made to conceal their identity, but anonymity cannot be guaranteed.

Financial support and sponsorship

Nil.

Conflicts of interest

There are no conflicts of interest.

REFERENCES

1. Omodei U, Ferrazzi E, Ramazzotto F, Becorpi A, Grimaldi E, Scarselli G, Spagnolo D, Spagnolo L, Torri W. Endometrial evaluation with transvaginal ultrasound during hormone therapy: a prospective multicenter study. *Fertil Steril* 2004; 81: 1632–1637.
2. Leone FP, Timmerman D, Bourne T, Valentin L, Epstein E, *et al.* (2010) Terms, definitions and measurements to describe the sonographic features of the endometrium and intrauterine lesions: a consensus opinion from the International Endometrial Tumor Analysis (IETA) group. *Ultrasound Obstet Gynecol* 35(1): 103-112.
3. L. JOKUBKIENE, P. SLADKEVICIUS and L. VALENTIN, Transvaginal ultrasound examination of the endometrium in postmenopausal women without vaginal bleeding *Ultrasound Obstet Gynecol* 2016; 48: 390–396. DOI: 10.1002/uog.15841

4. Epstein E, Ramirez A, Skoog L, Valentin L. Transvaginal sonography, saline contrast sonohysterography and hysteroscopy for the investigation of women with postmenopausal bleeding and endometrium >5 mm. *Ultrasound Obstet Gynecol.* 2001 Aug;18(2):157-62. doi: 10.1046/j.1469-0705.2001.00472.x. PMID: 11529998.
5. Patricia C. Davis, Mary Jane O'Neill, Isabel C. Yoder, Susanna I. Lee, and Peter R. Sonohysterographic Findings of Endometrial and Subendometrial Conditions *MuellerRadioGraphics* 2002 22:4, 803-816
6. Timmermans A, Opmeer BC, Khalid KS, Bachmann LM, Epstein E, T Justin Clark TJ, et al. Endometrial thickness measurement for detecting endometrial cancer in women with postmenopausal bleeding: a systematic review and meta-analysis. *Obstet Gynecol.* 2010;116:160-167.
7. Smith-Bindman R, Weiss E, Feldstein V. How thick is too thick? When endometrial thickness should prompt biopsy in postmenopausal women without vaginal bleeding. *Ultrasound Obstet Gynecol* 2004;24:558.

Address for correspondence: Dr. Mamata Deenadayal, 9-1-192, St Marys Rd, Madhuranagar, Kummari Guda, Shivaji Nagar, Secunderabad, Telangana 500 003, India.
E-mail: mamata@iirc.in

Submitted: 20-Mar-2021

Revised: 28-Mar-2021

Accepted: 30-Mar-2021

Published: 17-Apr-2021

Access this article online

Quick Response Code:



Website: www.jmidlifehealth.org

DOI: 10.4103/0976-7800.313985

This is an open access journal, and articles are distributed under the terms of the Creative Commons Attribution-NonCommercial-ShareAlike 4.0 License, which allows others to remix, tweak, and build upon the work non-commercially, as long as appropriate credit is given and the new creations are licensed under the identical terms.

For reprints contact: WKHLRPMedknow_reprints@wolterskluwer.com

How to cite this article: Deenadayal M. Understanding the endometrium at menopause: A sonologist's view. *J Mid-life Health* 2021;12:66-78.