

Available online at www.sciencedirect.com

ScienceDirect

journal homepage: www.elsevier.com/locate/radcr

Case Report

Tension pneumocephalus – A rare complication of cerebrospinal fluid leak

Jennifer Healy, BS^{a,*}, Matthew Grant, MD^b, Stephen Melnyk, MD^b, Brian Boldt, DO^b

^a Uniformed Services University, 4301 Jones Bridge Road, Bethesda, MD 20814, USA

^b Department of Radiology, Madigan Army Medical Center, 9040A Jackson Avenue, Joint Base Lewis-McChord, WA 98431, USA

ARTICLE INFO

Article history:

Received 3 October 2018

Revised 26 October 2018

Accepted 26 October 2018

Available online 15 December 2018

Keywords:

Tension pneumocephalus

Craniectomy

CSF leak

Decompression

ABSTRACT

Three months following a craniectomy and cranioplasty indicated for intraparenchymal hemorrhage, a 74-year-old male suffered a cerebrospinal fluid leak complicated by delayed tension pneumocephalus and declining neurologic status demonstrating a particularly rare complication of neurologic trauma and surgery. While with symptoms of a space occupying mass is the most common presentation, the patient presented cerebrospinal fluid leak prompting CT imaging and diagnosis. Urgent surgical decompression is necessary and was performed resulting in improved mental status.

Published by Elsevier Inc. on behalf of University of Washington.

This is an open access article under the CC BY-NC-ND license.

(<http://creativecommons.org/licenses/by-nc-nd/4.0/>)

Introduction

Pneumocephalus is a common benign finding following craniotomies and is managed conservatively [1]. However, tension pneumocephalus (TP), defined by the accumulation of intracranial air producing mass effect under tension resulting in neurologic deterioration, is a neurosurgical emergency requiring prompt decompression in order to prevent rapid deterioration, herniation, and death [2,3]. Although rare and reported to occur in only 0.1%–0.2% of all craniotomies, it is important to recognize and treat TP, as the management of benign post-operative pneumocephalus and TP differ greatly [2]. Although

most cases are early onset (occurring within 7 days) following craniotomy, delayed onset (occurring after 7 days) can occur months or even years following surgical intervention [2–4]. This patient presented with cerebrospinal fluid (CSF) leak complicated by delayed TP and declining neurologic status 3 months following craniectomy.

Case report

A 74-year-old male with a past medical history significant for Parkinson's disease suffered a ground level fall resulting in in-

Competing Interests: The authors have declared that no competing interests exist.

Disclaimer: The views expressed are those of the author(s) and do not reflect the official policy of the Department of the Army, the Department of Defense or the U.S. Government.

* Corresponding author.

E-mail addresses: jennifer.b.healy@gmail.com, Jennifer.healy@usuhs.edu (J. Healy).

<https://doi.org/10.1016/j.radcr.2018.10.030>

1930-0433/Published by Elsevier Inc. on behalf of University of Washington. This is an open access article under the CC BY-NC-ND license. (<http://creativecommons.org/licenses/by-nc-nd/4.0/>)

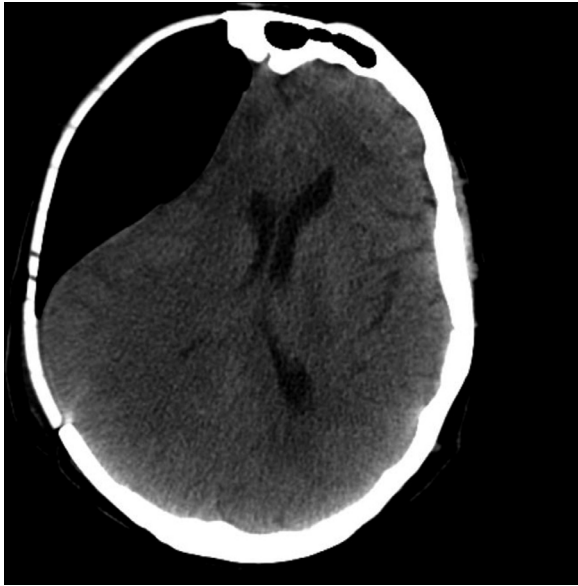

Fig. 1 – Axial noncontrast CT (NCCT) head at the level of the midbrain demonstrating large amount of extra-axial air resulting in midline shift.

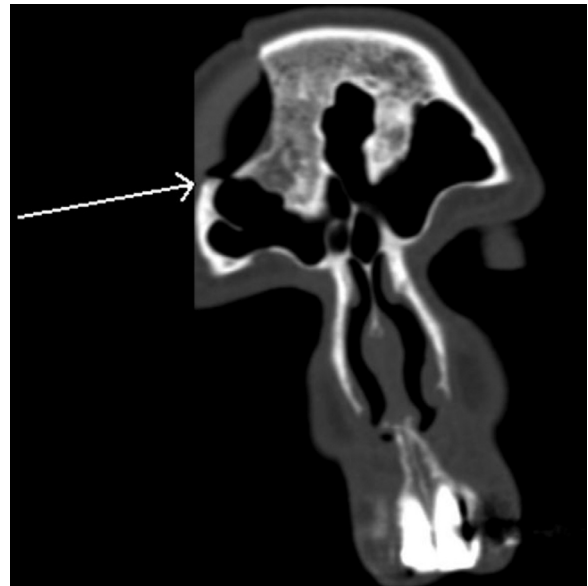


Fig. 2 – Axial NCCT head at the level of the lateral ventricles demonstrating large amount of extra-axial air resulting in midline shift.

traparenchymal hemorrhage requiring craniectomy, followed by cranioplasty 3 months later. Although initially recovering well, he was brought back to the hospital complaining of “liquid leaking from his nose,” later confirmed to be CSF with a positive beta-2 transferrin test. He was in stable condition, but subsequently admitted to the intensive care unit for management of his CSF leak. On hospital day 2, he developed a rapid decline in his neurologic status with increased somnolence. A head CT was then performed, showing a large amount of extra-axial air and associated mass effect, concerning for TP. Additionally, a bone defect was discovered along the anterior margin of the craniectomy, which communicated with the right frontal sinus. A burr hole and pressure bolt were quickly placed, followed by serial pressure releases. The patient’s mental status gradually improved and the pressure bolt was removed on hospital day 4. Unfortunately, the patient’s hospital course was later complicated by infection requiring removal of his cranioplasty plate, whereby simultaneous correction of his CSF leak was performed. He remained in the intensive care unit for treatment of his infection until medically stable, when he was discharged back to his skilled nursing facility for further recovery.

Discussion

TP is a rare potentially life-threatening complication following craniotomies and head trauma. It can present in either the early or delayed postoperative/posttraumatic period. The majority of cases occur secondary to trauma, with a variety of other etiologies as well [1–4]. Additional important causes include shunt procedures and craniofacial surgery (in particular skull base surgery, endoscopic sinus surgery, and sub-

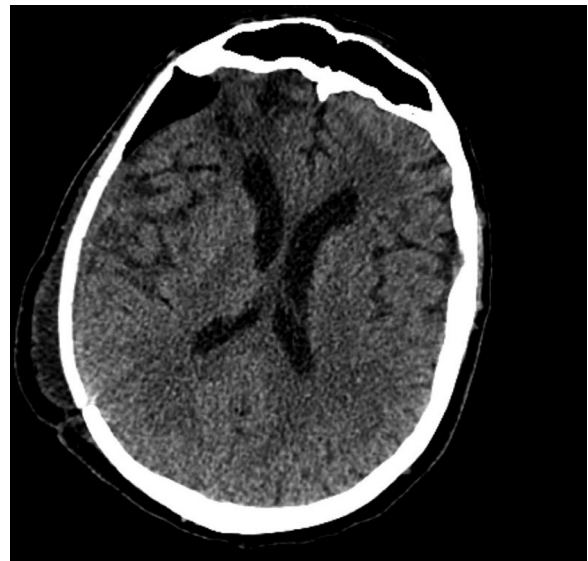


Fig. 3 – NCCT head coronal reformat demonstrating a bone defect in the floor of the right anterior cranial fossa which communicates with the right frontal sinus.

dural hematoma evacuation), with less likely causes including spinal anesthesia, infection (meningitis and abscess with gas producing organisms), tumors, and radiotherapy. Known pneumocephalus can become under tension with increased altitude or N₂O anesthesia [2–4].

The development of TP requires both an abnormal pathway for air to enter the cranium and an additional factor promoting air inflow [2]. Two primary mechanisms are proposed: the “inverted soda bottle phenomenon,” whereby a continuous CSF leak produces negative intracranial pressure

and allows for the accumulation of air replacing the fluid, and the “ball-valve mechanism,” whereby air enters the cranium through a defect whenever extracranial air pressure exceeds intracranial air pressure (such as from sneezing), and the exit of air is prevented by overlying tissue [4]. This aberrant air can accumulate in any intracranial compartment, with the subdural compartment being most common [3].

The clinical symptoms are similar to those of a space occupying mass, which can be variable but primarily manifest with headache, vomiting, confusion, and lethargy [2–4]. Neurologic findings may include hemiparesis, cranial nerve palsies, and aphasia. If unrecognized, TP may progress to herniation, coma, and death [3].

CT is the gold standard to confirm clinically suspected TP. In contrast to benign pneumocephalus, TP will demonstrate mass effect on the underlying brain. Most commonly, subdural air separates and compresses the frontal lobes, widening the interhemispheric space between the frontal lobe tips referred to as the “Mt Fuji” sign. Further, subdural air rupturing through the subarachnoid membrane referred to as the “air bubble sign” is indicative of tension [4]. The appearance, however, is varied depending on the location and quantity of air, with the end result being mass effect and herniation similar to that seen with extra-axial hemorrhage and other masses.

Although several immediate therapies (such as administration of highly concentrated oxygen and placement in the Fowler position of 30°) can be provided to alleviate symptoms,

urgent surgical decompression is critical [4]. CT may assist with placement of the intracranial device for air evacuation [4]. The combination of clinical and CT findings, along with rapid air escaping during intervention and improved neurologic status confirms the diagnosis [4]. However, once the air is evacuated, any dural defect which may have allowed air to enter the cranium must be repaired, as this is the only way to definitively resolve the condition [2]. Prognosis is relatively good if the condition is recognized early (Figs. 1-3).

REFERENCES

- [1] Dabdoub CB, Salas G, Silveira Edo N, Dabdoub CF. Review of the management of pneumocephalus. *Surg Neurol Int* 2015;6:155.
- [2] Wang A, Solli E, Carberry N, Hillard V. Delayed tension pneumocephalus following gunshot wound to the head: a case report and review of the literature. *Case Rep Surg* 2016;2016:7534571.
- [3] Sweni S, Senthilkumaran S, Balamurugan N, Thirumalaikolundusubramanian P. Tension pneumocephalus: a case report with review of literature. *Emerg Radiol* 2013;20(6):573–8.
- [4] Sprague A, Poulgrain P. Tension pneumocephalus: a case report and literature review. *J Clin Neurosci* 1999;6(5):418–24.