

# Recent developments in the surgical management of perianal fistula for Crohn's disease

Cristina B. Geltzeiler, Nicole Wieghard, Vassiliki L. Tsikitis

Oregon Health and Science University, USA

## Abstract

Perianal manifestations of Crohn's disease (CD) are common and, of them, fistulas are the most common. Perianal fistulas can be extremely debilitating for patients and are often very challenging for clinicians to treat. CD perianal fistulas usually require multidisciplinary and multimodality treatment, including both medical and surgical approaches. The majority of patients require multiple surgical interventions. CD patients with perianal fistulas have a high rate of primary non-healing, surgical morbidity, and high recurrence rates. This has led to constant efforts to improve surgical management of this disease process.

**Keywords** Crohn's disease, perianal, perirectal, fistula, surgery

*Ann Gastroenterol* 2014; 27 (4): 320-330

## Introduction

Perianal manifestations affect anywhere from 20-54% of patients with Crohn's disease (CD) and this proportion may be even higher in referral-based practice populations [1-11]. Though perianal CD can be present ranging anywhere from over a decade prior to diagnosis of CD to over 30 years after the initial diagnosis of CD, it is usually diagnosed concurrently or within a few years of diagnosis [2,6,10-14].

Perianal CD is a predictor of overall severity of CD and, with its presence, there is an increased risk of postoperative recurrence, an increased risk of requiring surgical intervention, and a shorter time between recurrences [3,15-17]. The more distal intestinal luminal CD lesions are at higher risk of developing associated perianal disease [6]. Approximately 20% of patients with perianal CD have other sites of disease in the small bowel or ileocolic area, while the remainder have manifestations in the colon and rectum [3,6]. In a small percentage of patients, CD symptoms manifest only in the anorectum [18]. Perianal lesions usually develop and/or flare temporally with intestinal recurrences of the disease [10,19].

Perianal CD can be extremely debilitating for patients, and is often very challenging for clinicians to treat. Substantial multidisciplinary medical and surgical care is required [2].

The most common manifestation of perianal CD is perirectal/perianal fistula (50-87% of all perianal lesions); others include fissure, anal canal stricture, rectovaginal fistula, and abscess [2,3,13]. Over half of CD patients with perianal disease have more than one perianal lesion [3,12,20,21].

Perianal CD fistulas can be classified as simple or complex. A simple fistula is a low lesion with a single external opening, whereas a complex fistula is one that recurs, or one with multiple tracts, high above the sphincter complex [8,12]. Patients with CD are at a higher risk of developing complex fistulizing disease, which is inherently more difficult to treat [12]. Multiple surgical treatments are usually required to achieve healing, with a median of six procedures for complex fistulas and median of three for simple fistulas. Furthermore, up to 38% of complex perianal fistulas will require major surgical intervention, including defunctioning stoma or proctectomy [12,22-24]. The ultimate goals of treatment are to define the anatomy, drain sepsis, and gain permanent closure of the fistulous tracts [25,26]. To achieve healing, complex fistulas usually require combined surgical and medical management [8].

Whether the fistula is simple or complex, up to 90% of patients with perianal CD will require operative treatment, and many will require more than one operative intervention [11,27]. When operations for perianal CD are performed, it is often difficult to achieve complete healing. In addition, there are increased risks of devastating complications, including septic complications, anal stenosis, and incontinence [9,28].

Patients with perianal CD are at a high risk of incontinence, due to the complex nature of their disease, frequent diarrhea, and need for multiple operative interventions that put the sphincter complex at risk. Patients with perianal CD are also at risk for prolonged fistula healing and frequent recurrences. It is not uncommon for a CD fistula to take many months, and even years to heal. More than 20% of patients do not achieve complete fistula healing in most studies [12,21]. Similarly, fistula

Department of Surgery, Division of Gastrointestinal and General Surgery, Oregon Health and Science University, USA

Conflict of Interest: None

Correspondence to: Cristina B. Geltzeiler, MD, 3181 SW Sam Jackson Park Rd. Mailcode L223A Portland, OR 97239, USA, Tel.: +1 503 494 1424, Fax: +1 503 494 8884, e-mail: budde@ohsu.edu

Received 8 April 2014; accepted 18 May 2014

recurrences are common, occurring on average in 20-35% of cases, even with intensive combination therapy [12,21]. Many recurrences occur years after initial closure, sometimes up to five years later, yet many studies are not able to provide long-term follow up [6,11,12,21,29,30].

Interestingly, in some cases when intestinal CD lesions are operatively removed, the associated perianal disease will resolve. In one series of 43 patients, there was a 47% spontaneous healing rate of the perianal disease after resection of intestinal lesion; however, 35% of these recurred within 2.5 years [6]. This stresses the importance of delineating any other active intestinal disease that may need treatment prior to operative treatment of perianal disease [31]. It is also crucial to assess anatomy, sphincter function, continence, patient nutritional status, and quality of life [31].

### Combination therapy

A combined medical and surgical approach to treatment is integral to the care of CD perianal fistulas [8]. Medical treatment includes antibiotics, immunomodulators, and biologic medications [26,32-36]. After being approved for use in CD in 1998, and with further reinforcement of their efficacy in perianal CD fistulas in 1999, biologic therapies are being widely used by gastroenterologists in all practice settings [37-40]. The most commonly used biologic therapy is infliximab (IFX), an anti-tumor necrosis factor (TNF)- $\alpha$  drug [37]. Adalimumab is another anti-TNF- $\alpha$  medication indicated in cases refractory or intolerant to IFX [26,41].

According to the National Institute for Health and Care Excellence guidelines, biologics should be reserved for CD that has failed conventional therapy or in the presence of severe, active fistulizing disease [42,43]. This is echoed by the European evidence-based consensus on CD [36]. IFX treatment of perianal CD after local surgical drainage resulted in an overall 55% closure. Duration of fistula closure is limited, however, with a median of three months of continued fistula closure [39]. Recurrence rates were 17% at one year and 40% at five years [39,44]. There seems to be some benefit to continuation with IFX maintenance therapy, which resulted in a 36% response rate at 54 weeks, compared to 19% in the placebo group [45].

In the adolescent population, response to IFX may be slightly improved, as there was a 70% complete response, with a 23% recurrence rate after seton drainage and IFX. These patients, however, had their setons left in much longer than their adult counterparts. In addition, many of this cohort were switched to adalimumab treatment [46].

Despite major advances in medical treatment, biologic medications and immunomodulators do not seem to significantly change the biology or long-term prognosis of patients with perianal CD, and surgical treatment remains a necessity [31,34,38,39,47]. There is a significant nonresponse rate, 20-35% in most series. Even with closure of perianal fistula after IFX, many patients require further surgical intervention for recurrence, development of anal stenosis, or abscess formation.

Anal stenosis is postulated to be due to scarring from rapid healing while on IFX [1,38]. In a series of nine patients with perianal fistulizing CD, Poritz *et al* demonstrated an initial 44% complete response rate to perianal fistulas; however, another 44% went on to require surgical intervention [38].

Prior to treatment with biologic medications, most patients have a surgical exam under anesthesia (EUA) with drainage of local infection and seton placement to keep fistulous tracts open. There are some, however, who have questioned whether this is necessary [1,47]. In a study by Regueiro *et al*, patients who had an EUA with seton placement prior to biologic medical therapy had better initial response, lower recurrence rate, and longer time to recurrence, when compared to those treated with biologic therapy alone [47]. Other authors have demonstrated similar results with other pre-IFX operative treatments, including fistulotomy, fibrin glue administration, rectal advancement flap procedure, or defunctioning stoma [1,20].

IFX as a treatment is not without risk. Multiple serious adverse reactions have been reported including serum sickness, severe septic infections, drug-induced lupus, and malignancies [38,40,48]. It remains unclear how long IFX should be continued in patients as maintenance therapy [1,20,45]. Relapses are common after discontinuation of therapy [33,49], with only 34% of patients maintaining perianal remission at one year after stopping IFX treatment [49]. It is also important to weigh the cost of biologic therapies for the treatment of perianal CD, as they are the largest healthcare expense involved with this disease process [50].

### EUA and imaging

EUA is a diagnostic procedure, but it is often a therapeutic and preventative procedure as well [32,33]. The goals of treatment are to define the anatomy, drain perianal sepsis, and attempt to prevent septic recurrence, while maintaining continence and quality of life [33]. When performing an EUA, it is prudent to include the scrotum or vagina in field, as it is possible for fistulizing disease to involve these areas. Gentle probing and use of methylene blue or hydrogen peroxide to define fistulous tracts is commonly successful [33].

Recently, there has been more frequent use of magnetic resonance imaging (MRI) to help characterize fistulizing disease [51]. MRI is often performed prior to EUA to help delineate anatomy and identify any additional occult abscesses or fistulous tracts prior to operative exploration [33]. Endoscopic ultrasound (EUS) and transperineal ultrasound have also similarly been used and have shown to be successful with experienced ultrasonographers [17,32,52]. Fistulography as a diagnostic modality is no longer used in this disease process [32,36].

MRI, EUS and EUA all have similar accuracy in identifying fistula tracts. When two of the three tests are combined, accuracy is 100% [53]. The European Crohn's and Colitis Organisation (ECCO) consensus guidelines currently advise obtaining an MRI initially in complex fistulizing CD [32,36].

In addition, proctoscopy is recommended to determine if concomitant active rectal disease is present for diagnostic, prognostic, and therapeutic planning [32,36].

### Incision and drainage of abscesses

The most common indication for operative intervention with perianal CD is septic complications, which include abscesses or undrained fistulas [31]. All clinically symptomatic abscesses require incision and drainage [8,27,36]. This is usually required urgently or emergently to control sepsis [7]. Small (<1 cm), clinically occult abscesses that are demonstrated on imaging can generally be treated with medical therapy alone [51].

It is important to recognize the relationship between an abscess and, most likely, an associated fistulous tract in CD patients. In one small series by Williamson *et al*, all patients who underwent drainage of abscesses only failed treatment [21]. Conflicting results were found by Michelassi *et al*, who demonstrated complete healing in 68%, with only 32% going on to develop fistulizing disease [27]. It is important to note that perianal abscesses have been reported to represent a complication of IFX treatment, possibly due to cutaneous end closure prior to internal opening closure [38]. In a population-based study, Jones *et al* found that since the approval of biologics for use in CD, the incidence of anal fistula repair has remained stable, but perianal abscess incision and drainage has increased threefold [54].

### Seton placement

A seton is a silastic loop or suture that is placed in a fistulous tract and left in place. Setons are used to keep fistulous tracts open, allowing them to drain in order to prevent reaccumulation of undrained sepsis. As long as non-cutting setons are used, the risk of sphincter damage or compromising continence are low. Also, setons can be left in place long-term while medical treatments are used. Unfortunately, when setons are removed, there is a high recurrence rate of recurrent local sepsis, up to 70% [18,55]. Removing setons may have initial short-term healing success, but if followed longer, most patients will have recurrence, especially in the absence of additional treatment [56]. For this reason, some advocate permanent seton placement in this patient population [8,12,18,55,57].

If removal of a seton is planned, optimal timing of when to remove it is unclear. If setons are removed too early, there is a high risk of development of recurrent perianal abscess. If one is not removed quickly enough, however, the presence of a foreign body will prevent complete fistula healing [38,46]. Furthermore, timing of seton placement and removal in coordination with IFX use is controversial [32,36,38].

Seton drainage is often used as a temporary control of fistula drainage until the patient's condition is appropriate to undergo a definitive fistula closure [24].

### Fistulotomy

For low-lying, asymptomatic, simple fistulae, no treatment is necessary, as the risks of a procedure outweigh the benefits [8]. However, if a simple fistula is symptomatic, seton placement or fistulotomy are usually appropriate [5,12,18,19,26,27,31,32,36,58,59].

As CD patients have a high risk of recurrence, usually undergo multiple operative procedures and are at risk of incontinence, many clinicians are hesitant to perform fistulotomies in this patient population. However, fistulotomy procedures with low, simple fistulas have been demonstrated to have an excellent response rate with minimal complications [5,57]. It is important to note that this patient population may have delayed healing and increased risk of recurrence compared to patients without CD. It is not uncommon to achieve complete healing six months after this procedure [5,57].

Fistulotomy is generally contraindicated in patients with complex fistulas, as they have an unacceptably high risk for incontinence, non-healing of wounds, and need for proctectomy [10,32,60]. Similarly, when macroscopic rectal involvement is present, patients have a decreased rate of healing [8,10]. Caution should also be used in patients who have diarrhea, women with anterior fistulas, and patients with short anal canals [8].

Incontinence rates after fistulotomy have been variably reported in the literature anywhere from 0-50% [5,9,18,35,57,61]. Some authors advocate partial fistulotomy with seton placement as an alternative, as this procedure minimizes sphincter compromise [21,57]. Others advocate the use of laser ablation to unroof fistula tracts, with similar results to fistulotomy [62,63].

### Fecal diversion

Fecal diversion consists of stoma formation to divert the fecal stream away from wounds to allow healing. This approach is often used in anticipation of restoration of bowel continuity once complete healing is achieved. In a series of 86 patients with perianal CD, 62% required fecal diversion at some point during care, and approximately 50% of patients required permanent fecal diversion [3]. In another study of 31 patients who underwent fecal diversion and drainage of local sepsis for their perianal disease, 81% went into early remission, although 68% of these relapsed at a median of 23 months after diversion. A total of 25% of patients had long-term remission, but only 10% were able to restore intestinal continuity [64]. Similarly, dismal results were found in other smaller studies [65,66]. This reflects the fact that fecal diversion does not alter the course of disease. Disease often recurs after closure of ostomy, and disease recurrence has also been reported while patients are still diverted. Restoration of intestinal continuity is uncommon [67,68]. Predictors of the need for permanent fecal diversion are presence of colonic disease, anal canal stricture and increased number of surgical interventions [3].

In contrast, in a series of 14 patients who had fecal diversion in addition to local therapy and medical treatment,

only two (14%) developed symptomatic recurrence of their perianal disease, with a median 22-month follow up [59]. This suggests that fecal diversion possibly should be used only as an adjunct to other treatments, and not as a definitive treatment in itself. This is supported by another series of 97 patients with perianal CD. In this series, 53% of patients required temporary fecal diversion, but 47% of these were successfully closed after the fistula was treated, using a rectal advancement flap [24].

### Fibrin glue

Fibrin glue is applied to the fistulous tract in attempts to promote healing and closure. The advantage of this therapy is the overall very low complication rate and the almost zero risk of incontinence. In a randomized multicenter trial of highly selected CD patients, fibrin glue was associated with a 38% success of closure rate, as opposed to 16% in the observation-alone group at eight-week follow up [69]. The benefit in this trial was more pronounced in the patients with simple fistulas, as compared to complex ones. Additionally, 15% of the successfully closed fistulas recurred at 16 weeks. Very limited or no response to fibrin glue has also been observed by others [70,71]. In a French trial of 14 patients with CD, there was clinical resolution of 57% of fistulas after 23 months of follow up. When evaluated endoscopically, however, only 14% had endoscopic resolution, suggesting that these tracts may be quiescent, but at risk to recur in the future [22,72-75].

A group in Spain combined adipose-derived stem cells with fibrin glue injection and found improved results compared to fibrin glue alone; 71% healing versus 14% in the glue alone cohort. However, recurrence increased by 17.6% at one year of follow up, and with further follow up at three years, only 28% were free of recurrence [76,77].

A summary of outcomes in the literature of fibrin glue injection are listed in Table 1. Despite little success with fibrin glue in healing CD perianal fistulas, some advocate its use as an option due to very few complications, including absence of incontinence. The risks and benefits should be weighed and individualized, as the glue is usually applied under anesthetic and does incur cost.

### Fistula plug

The anal fistula plug is a porcine intestinal submucosal xenograft that is bioabsorbable. It is inserted into the perianal fistulous tract, with the objective of promoting fistulous tract closure while preserving continence [78-80]. There was an 80% closure rate of perianal fistulas with a median of ten months follow up in a series of 20 CD patients by O'Connor *et al.* Presence of multiple fistulous tracts was a risk factor for procedure failure. In this series, use of anti-TNF- $\alpha$  therapy did not correlate with outcomes [79]. A subsequent systematic review of anal fistula plug use in 42 patients with perianal CD demonstrated a 55% success rate of the procedure.

This was similar to the success rate in the non-CD patient population [80]. There were no reports of incontinence; however, abscess formation has been reported. A summary of outcomes in the literature of fistula plug are listed in Table 1. It remains unclear how to select CD patients for this procedure as long-term follow-up data is limited; however, McGee *et al* demonstrated that longer fistula tract length was associated with improved fistula closure in non-CD patients [81].

### Endorectal mucosal advancement flap

Endorectal mucosal advancement flap is a procedure that uses endogenous tissue to close the internal fistula opening. The use of this procedure is performed to avoid dividing sphincter muscle, but incontinence has been described as a complication to the procedure [59,74]. There is an option of performing a second flap procedure if an initial operation fails; however, multiple flap repairs have an increased risk of incontinence [27,30,82]. Proctitis is a contraindication to the procedure due to poor healing. In addition, repair has been shown to be less successful if there is active CD elsewhere in the GI tract that is not well controlled. During the initial healing period in high-risk patients, it is common for surgeons to use a protective stoma [83].

Prior to receiving an advancement flap, most patients have undergone a period of infection control with a draining seton, with or without a diverting stoma [84]. Once the acute inflammation and infection have subsided, patients undergo the operation. Success rates have been variable and have been reported to be anywhere from 25-64% [18,21,29,30,59,82,83]. In a systematic review, however, the overall success of endorectal advancement flaps in CD was found to be 64%, compared to 81% in non-CD counterparts. The incontinence rate of the procedure was slightly lower in patients with CD than in those non-CD counterparts, at 9.4% and 13.2% respectively [85].

Although active proctitis is a contraindication to the procedure, van der Hagen *et al* demonstrated good results with preoperative IFX treatment for patients with active proctitis in a pilot study. If the proctitis resolved, the patient was indicated for flap procedure. In this small patient cohort with limited follow up, there was only a 10% recurrence rate and a 10% rate of incontinence in the pre-treated patients, compared to 29% recurrence and incontinence rates in the group that did not have IFX prior to flap procedure [86]. This study suggests that with modern biologic therapy, we may be able to expand indications for this potentially definitive operation.

If anal stenosis is present, precluding attempted rectal advancement flap, rectal sleeve advancement has been reported to be successful in a very limited number of cases [87].

### Ligation of the intersphincteric tract (LIFT) procedure

A fairly new technique that has also shown some early success in healing complex perianal fistulas while preserving continence is the LIFT procedure [88]. In a series of 15 CD patients, Gingold *et al* demonstrated a 67% wound healing

**Table 1** Fibrin glue and fistula plug summary of literature

Reference	N	Study design	Rate of healing	Follow-up time	Complications (other than failure to close)
<b>Fibrin glue</b>					
Abel <i>et al</i> , 1993 [70]	2	Non-randomized	0/2	6-10 mos.	None reported
Park <i>et al</i> , 2000 [107]	2	Non-randomized, prospective	1/2	6 mos.	None reported
Cintron <i>et al</i> , 2000 [108]	6	Non-randomized, prospective	2/6	52 wks.	None reported
Lindsey <i>et al</i> , 2002 [109]	2	Randomized, fibrin glue or "standard treatment"-either seton, fistulotomy, or advancement flap	2/2, 1 required 2 treatment interventions	12 wks.	None reported
Sentovich, 2003 [110]	5	Non-randomized	3/5	22 mos.	None reported
Zmora <i>et al</i> , 2003 [71]	7 (2 of these with advancement flap)	Non-randomized, retrospective	2/7, 1 with advancement flap	12.1 mos.	None reported
Loungnarath <i>et al</i> , 2004 [111]	13	Non-randomized, retrospective	4/13	26 mos.	None reported
Vitton <i>et al</i> , 2005 [75]	14	Non-randomized	10/14, clinical healing 2/14, radiographic healing	12-26 mos.	None reported
Singer <i>et al</i> , 2005 [112]	3	Randomized to fibrin glue with abx (1 pt) or glue with abx and internal fistula opening closure (2 pts)	0/3	27 mos.	None reported
de Parades <i>et al</i> , 2008 [113]	11	Non-randomized, prospective	7/11	11.7 mos.	None reported
Grimaud <i>et al</i> , 2010 [69]	36	Randomized to glue or observation	11/34 (2 pts lost to follow up)	16 wks.	4 Abscesses
Chung <i>et al</i> , 2010 [114]	1	Non-randomized, retrospective	0/1	12 wks.	None reported
<b>Fibrin glue with ASC</b>					
Garcia-Olmo <i>et al</i> , 2009 [76]	14	Randomized to ASC (7 pts) or Fibrin Glue (7 pts)	5/7 ASC 1/7 fibrin glue	8 wks.	1 Abscess (fibrin glue group)
Lee <i>et al</i> , 2013 [115]	32	Non-randomized Phase II trial	23/32	12 mos.	None reported
<b>Fistula Plug</b>					
O'Connor <i>et al</i> , 2006 [79]	20	Non-randomized, prospective	16/20	10 mos.	None reported
van Koperen <i>et al</i> , 2007 [116]	1	Non-randomized, prospective	1/1	7 mos.	None reported
El-Gazzaz <i>et al</i> , 2008 [117]	13	Non-randomized, retrospective	2/13	7.4 mos.	7 Abscesses
Ky <i>et al</i> , 2009 [118]	14	Non-randomized, prospective	4/14	6.5 mos.	3 Abscesses
Schwandner <i>et al</i> , 2009 [119]	9	Non-randomized, prospective	7/9	9 mos.	1 Abscess
Zubaidi <i>et al</i> , 2009 [120]	2	Non-randomized, prospective	1/2	12 mo.	None reported
Chung <i>et al</i> , 2010 [114]	4	Non-randomized, retrospective	3/4	12 wks.	None reported
Lupinacci <i>et al</i> , 2010 [121]	3	Non-randomized, prospective	1/3	8.1 mos.	None reported

N, number of Crohn's disease patients included; Mos, months; Wks, weeks; Abx, antibiotics; Pt(s), patient(s); ASC, adipose-derived stem cells

rate at one-year follow up without any fecal incontinence. None of the five midline fistulas in this series were successfully healed with this approach, but there was a 90% success rate with lateral fistulas. The procedure was also more effective

in patients with longer tracts (average length of tracts that resulted in successful procedure was 34 mm as opposed to 20 mm in failed procedures). Interestingly, even after successful LIFT procedure, there was a 20% incidence of new

fistula formation [23]. Additional studies of this procedure are needed in the CD population to verify it as a viable and safe option in this patient population.

## Other treatments

### Hyperbaric oxygen

When combined with surgical and medical treatment, hyperbaric oxygen treatment has been used with some success in a few case reports [85-87].

### Topical tacrolimus

While there seems to be a role for topical tacrolimus in healing refractory perianal CD ulceration, this treatment does not seem to be successful, and may actually be harmful in the setting of perianal fistulizing CD [89-91]. In a placebo-controlled trial by Hart *et al*, topical tacrolimus did not result in any improvement in fistulizing disease in the six patients in the treatment arm. In addition, two patients in the treatment arm developed abscesses, thought to be a complication of the drug in this setting [90]. A summary of outcomes in the literature of topical tacrolimus are listed in Table 2.

### Local biologic injection

Injection of biologic medications locally surrounding the fistulous tract is a procedure usually performed in the operating room under general or spinal anesthesia [92-94]. In a study of 15 patients with refractory perianal fistulizing disease treated with local injection of IFX, 67% had closure of their fistulas at a mean of 18-month followup. Twenty percent of these patients, however, had adverse events, including incontinence and anal

stricture [93].

There have been improved results reported with local injection of adalimumab [92,94]. In a series of 9 patients with CD perianal fistula, Tonelli *et al* demonstrated improvement in 3/9, or complete cessation of drainage in 6/9 patients with a 17-month median follow up; and there were no adverse events in this group [94]. A summary of outcomes in the literature of local biologic injection are listed in Table 2. Further clinical trials are necessary, but this remains a promising treatment option for patients who are otherwise refractory to, or who have contraindications to infusional biologic therapy.

### Proctectomy

Proctectomy is usually used as the last resort option in an attempt to heal perianal fistulizing CD. In a series by Bell *et al*, the median number of treatments attempted for healing prior to proctectomy was 12, with a median time from presentation with perianal disease to proctectomy of 6.3 years [12]. Proctectomy rate has been variably reported anywhere from 12-38% of patients with perianal fistulizing CD [5,7,12,18,21,27,55]. Multiple operations and multiple complications increase the risk of proctectomy [27,31]. In addition, Crohn's colitis with rectal sparing, but presence of perianal fistulizing disease, resulted in a 46% proctectomy rate. Colonic disease with rectal involvement required proctectomy in 89% of patients with perianal fistulas [6].

When a proctectomy is required for disease control in this patient population, there is often difficult healing of the perineal wound [9,31]. In one series, only 23% healed at six months, as opposed to healing in 50% of CD patients without perianal disease [10]. Myocutaneous flap coverage after proctectomy for perianal CD has demonstrated good results in improved healing. It is advisable to perform the flap at the initial operation for proctectomy for wound coverage. The literature suggests better outcomes with rectus abdominus flap than with gracilis flap [95,96].

**Table 2** Topical and intralesional treatments summary of literature

Reference	N	Study design	Rate of healing	Follow-up time	Complications (other than failure to close)
Topical tacrolimus					
Casson <i>et al</i> , 2000 [89]	1	Case report	1/1	9 mos.	None reported
Hart <i>et al</i> , 2007 [90]	6	Randomized to topical tacrolimus or placebo	1/6	12 wks.	2 Abscesses
Local biologic injection					
Poggioli <i>et al</i> , 2005 [93]	15, infliximab	Non-randomized	10/15	18 mos.	1 Worsening stenosis 1 Rectourethral fistula development 1 Incontinence
Asteria <i>et al</i> , 2006 [122]	11, infliximab	Non-randomized, pilot study	4/11	10.5 mos.	None reported
Tonelli <i>et al</i> , 2012 [94]	12, adalimumab	Non-randomized, pilot study	6/9	17 mos.	None reported

N, number of Crohn's disease patients included; Mos., months; Wks., weeks

**Predictors of recurrence**

The presence of active proctitis increases not only the risk of having perianal fistulizing disease but also portends increased risk of refractory, recurrent disease that will require proctectomy [5,7,12,27,31,66]. Hurst *et al* demonstrated a 67% proctectomy rate in patients with perianal fistulizing disease and gross evidence of proctitis versus 11% in those with fistulizing disease but without macroscopic rectal involvement [7].

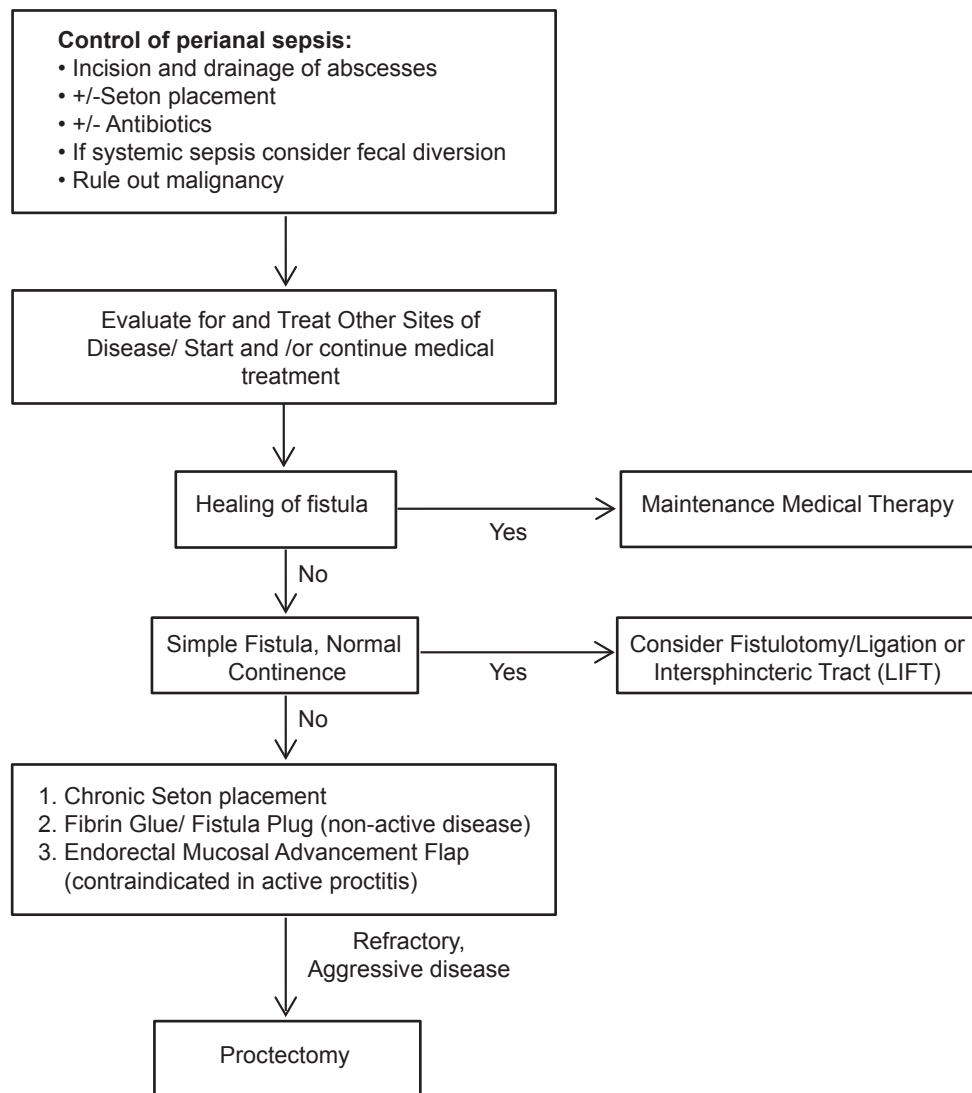
Crohn's colitis is also a very strong predictor of treatment failure with a recurrence rate of 84-100% [6,10,57-59]. Uzzan *et al* attempted treatment for severe Crohn's colitis with associated perianal disease with ileal diversion and biologic medications in a series of three patients. All three patients failed therapy and ultimately required permanent stoma [97].

In addition to proctitis and Crohn's colitis, complex fistulas and absence of fecal diversion, are also risk factors for symptomatic recurrence [59]. In all CD lesions, but especially

a refractory lesion, one must always have a high index of suspicion for development of carcinoma in fistula tracts. Biopsy or curettage with pathologic evaluation of fistulous tracts should be performed if there is any suspicion of malignancy [8,98,99].

**Hidradenitis suppurativa (HS)**

It is important to note the association and diagnostic difficulty of perianal HS and perianal CD [100]. HS is a chronic apocrine sweat gland disorder that can cause abscesses, sinuses, and fistulas in the perineum and other areas where apocrine glands are present such as the axillae [100,101]. The association of this pathology with CD is largely unknown but reported retrospectively anywhere from 0.6-38% [100,102,103]. The diagnostic distinction can be quite difficult as areas of HS can have associated granulomas, a histologic feature of CD [100]. In



**Figure 1** Proposed algorithm for the treatment of perianal fistulas due to Crohn's disease

addition, HS responds to treatment with biologic medications, further complicating the distinction [103]. Diagnostic vigilance is important as aggressive surgical excision has the most favorable operative outcome, generally the opposite approach than that for perianal CD lesions [100,104]. Wide excision of HS lesions is usually feasible even within the CD population as HS generally does not involve or extend to the sphincter complexes [104]. Of importance, perianal HS has also been associated with development of squamous cell carcinoma after longstanding lesions. Early diagnosis with aggressive treatment of HS lesions may prevent malignant transformation [105,106].

### Concluding remarks

Even with modern medical and surgical advancements for treatment of perianal CD, it remains challenging to treat. Most of the literature to guide our practice is based on small case series, often with limited follow up. With most of the existing case reports and series it is hard to draw conclusions, especially considering the variability of disease presentation. There is still no one definitive or long-term effective treatment for all perianal CD. Recurrences are high and surgical treatments must be individualized in order to minimize risks. A proposed algorithm is shown in Fig. 1. It is imperative that perianal CD fistulizing disease is approached with a multidisciplinary team comprising surgeons, gastroenterologists, radiologists and pathologists.

### Acknowledgements

The authors would like to acknowledge Mary Kwatkosky-Lawlor for her assistance in the editing of this review.

### References

- Antakia R, Shorthouse AJ, Robinson K, Lobo AJ. Combined modality treatment for complex fistulating perianal Crohn's disease. *Colorectal Dis* 2013;**15**:210-216.
- Eglinton TW, Barclay ML, Gearry RB, Frizelle FA. The spectrum of perianal Crohn's disease in a population-based cohort. *Dis Colon Rectum* 2012;**55**:773-777.
- Galandiuk S, Kimberling J, Al-Mishlab TG, Stromberg AJ. Perianal Crohn disease: predictors of need for permanent diversion. *Ann Surg* 2005;**241**:796-801.
- Lakatos PL, Golovics PA, David G, et al. Has there been a change in the natural history of Crohn's disease? Surgical rates and medical management in a population-based inception cohort from Western Hungary between 1977-2009. *Am J Gastroenterol* 2012;**107**:579-588.
- Halme L, Sainio AP. Factors related to frequency, type, and outcome of anal fistulas in Crohn's disease. *Dis Colon Rectum* 1995;**38**:55-59.
- Hellers G, Bergstrand O, Ewerth S, Holmstrom B. Occurrence and outcome after primary treatment of anal fistulae in Crohn's disease. *Gut* 1980;**21**:525-527.
- Hurst RD, Molinari M, Chung TP, Rubin M, Michelassi F. Prospective study of the features, indications, and surgical treatment in 513 consecutive patients affected by Crohn's disease. *Surgery* 1997;**122**:661-667.
- Judge TA, Lichtenstein GR. Treatment of fistulizing Crohn's disease. *Gastroenterol Clin North Am* 2004;**33**:421-454.
- Keighley MR, Allan RN. Current status and influence of operation on perianal Crohn's disease. *Int J Colorectal Dis* 1986;**1**:104-107.
- Nordgren S, Fasth S, Hulten L. Anal fistulas in Crohn's disease: incidence and outcome of surgical treatment. *Int J Colorectal Dis* 1992;**7**:214-218.
- Schwartz DA, Loftus EV, Jr., Tremaine WJ, et al. The natural history of fistulizing Crohn's disease in Olmsted County, Minnesota. *Gastroenterology* 2002;**122**:875-880.
- Bell SJ, Williams AB, Wiesel P, Wilkinson K, Cohen RC, Kamm MA. The clinical course of fistulating Crohn's disease. *Aliment Pharmacol Ther* 2003;**17**:1145-1151.
- Gray BK, Lockhartmummery HE, Morson BC. Crohn's disease of the anal region. *Gut* 1965;**6**:515-524.
- Sangwan YP, Schoetz DJ, Jr., Murray JJ, Roberts PL, Collier JA. Perianal Crohn's disease. Results of local surgical treatment. *Dis Colon Rectum* 1996;**39**:529-535.
- Buisson A, Chevaux JB, Allen PB, Bommelaer G, Peyrin-Biroulet L. Review article: the natural history of postoperative Crohn's disease recurrence. *Aliment Pharmacol Ther* 2012;**35**:625-633.
- Michelassi F, Balestracci T, Chappell R, Block GE. Primary and recurrent Crohn's disease. Experience with 1379 patients. *Ann Surg* 1991;**214**:230-238.
- Ruffolo C, Citton M, Scarpa M, et al. Perianal Crohn's disease: is there something new? *World J Gastroenterol* 2011;**17**:1939-1946.
- Faucheron JL, Saint-Marc O, Guibert L, Parc R. Long-term seton drainage for high anal fistulas in Crohn's disease--a sphincter-saving operation? *Dis Colon Rectum* 1996;**39**:208-211.
- Buchmann P, Keighley MR, Allan RN, Thompson H, Alexander-Williams J. Natural history of perianal Crohn's disease. Ten year follow-up: a plea for conservatism. *Am J Surg* 1980;**140**:642-644.
- Talbot C, Sagar PM, Johnston MJ, Finan PJ, Burke D. Infliximab in the surgical management of complex fistulating anal Crohn's disease. *Colorectal Dis* 2005;**7**:164-168.
- Williamson PR, Hellinger MD, Larach SW, Ferrara A. Twenty-year review of the surgical management of perianal Crohn's disease. *Dis Colon Rectum* 1995;**38**:389-392.
- Ardizzone S, Maconi G, Colombo E, Manzionna G, Bollani S, Bianchi Porro G. Perianal fistulae following infliximab treatment: clinical and endosonographic outcome. *Inflamm Bowel Dis* 2004;**10**:91-96.
- Gingold DS, Murrell ZA, Fleshner PR. A prospective evaluation of the ligation of the intersphincteric tract procedure for complex anal fistula in patients with Crohn disease. *Ann Surg* 2013; (in press).
- Mueller MH, Geis M, Glatzle J, et al. Risk of fecal diversion in complicated perianal Crohn's disease. *J Gastrointest Surg* 2007;**11**:529-537.
- Feagan BG, Panaccione R, Sandborn WJ, et al. Effects of adalimumab therapy on incidence of hospitalization and surgery in Crohn's disease: results from the CHARM study. *Gastroenterology* 2008;**135**:1493-1499.
- Panes J, Gomollon F, Taxonera C, Hinojosa J, Clofent J, Nos P. Crohn's disease: a review of current treatment with a focus on biologics. *Drugs* 2007;**67**:2511-2537.
- Michelassi F, Melis M, Rubin M, Hurst RD. Surgical treatment of anorectal complications in Crohn's disease. *Surgery* 2000;**128**:597-603.
- Cracco N, Zinicola R. Is haemorrhoidectomy in inflammatory bowel disease harmful? an old dogma reexamined. *Colorectal Dis* 2014;**16**:516-519.



29. Makowiec F, Jehle EC, Becker HD, Starlinger M. Clinical course after transanal advancement flap repair of perianal fistula in patients with Crohn's disease. *Br J Surg* 1995;**82**:603-606.
30. Mizrahi N, Wexner SD, Zmora O, et al. Endorectal advancement flap: are there predictors of failure? *Dis Colon Rectum* 2002;**45**:1616-1621.
31. Fichera A, Michelassi F. Surgical treatment of Crohn's disease. *J Gastrointest Surg* 2007;**11**:791-803.
32. Caprilli R, Gassull MA, Escher JC, et al. European evidence based consensus on the diagnosis and management of Crohn's disease: special situations. *Gut* 2006;**55**:i36-i58.
33. de Zoeten EF, Pasternak BA, Mattei P, Kramer RE, Kader HA. Diagnosis and treatment of perianal Crohn disease: NASPGHAN clinical report and consensus statement. *J Pediatr Gastroenterol Nutr* 2013;**57**:401-412.
34. Present DH, Korelitz BI, Wisch N, Glass JL, Sachar DB, Pasternack BS. Treatment of Crohn's disease with 6-mercaptopurine. A long-term, randomized, double-blind study. *N Engl J Med* 1980;**302**:981-987.
35. Sandborn WJ, Fazio VW, Feagan BG, Hanauer SB. AGA technical review on perianal Crohn's disease. *Gastroenterology* 2003;**125**:1508-1530.
36. Van Assche G, Dignass A, Reinisch W, et al. The second European evidence-based Consensus on the diagnosis and management of Crohn's disease: Special situations. *J Crohns Colitis* 2010;**4**:63-101.
37. Kornbluth A. Infliximab approved for use in Crohn's disease: a report on the FDA GI Advisory Committee conference. *Inflamm Bowel Dis* 1998;**4**:328-329.
38. Poritz LS, Rowe WA, Koltun WA. Remicade does not abolish the need for surgery in fistulizing Crohn's disease. *Dis Colon Rectum* 2002;**45**:771-775.
39. Present DH, Rutgeerts P, Targan S, et al. Infliximab for the treatment of fistulas in patients with Crohn's disease. *N Engl J Med* 1999;**340**:1398-1405.
40. St Charles M, Smith SR, Beardsley R, Fedder DO, Carter-Pokras O, Cross RK. Gastroenterologists' prescribing of infliximab for Crohn's disease: a national survey. *Inflamm Bowel Dis* 2009;**15**:1467-1475.
41. Colombel JF, Schwartz DA, Sandborn WJ, et al. Adalimumab for the treatment of fistulas in patients with Crohn's disease. *Gut* 2009;**58**:940-948.
42. Carter MJ, Lobo AJ, Travis SP. Guidelines for the management of inflammatory bowel disease in adults. *Gut* 2004;**53**:V1-V16.
43. National Institute for Health and Clinical Excellence (NICE). Infliximab (review) and adalimumab for treatment of Crohn's disease. 2010;1-43.
44. Bouguen G, Siproudhis L, Gizard E, et al. Long-term outcome of perianal fistulizing Crohn's disease treated with infliximab. *Clin Gastroenterol Hepatol* 2013;**11**:975-981.
45. Sands BE, Anderson FH, Bernstein CN, et al. Infliximab maintenance therapy for fistulizing Crohn's disease. *N Engl J Med* 2004;**350**:876-885.
46. Hukkinen M, Pakarinen MP, Piekkala M, Koivusalo A, Rintala R, Kolho KL. Treatment of complex perianal fistulas with seton and infliximab in adolescents with Crohn's disease. *J Crohns Colitis* 2014;**8**:756-762.
47. Regueiro M, Mardini H. Treatment of perianal fistulizing Crohn's disease with infliximab alone or as an adjunct to exam under anesthesia with seton placement. *Inflamm Bowel Dis* 2003;**9**:98-103.
48. Colombel JF, Loftus EV, Jr., Tremaine WJ, et al. The safety profile of infliximab in patients with Crohn's disease: the Mayo clinic experience in 500 patients. *Gastroenterology* 2004;**126**:19-31.
49. Domenech E, Hinojosa J, Nos P, et al. Clinical evolution of luminal and perianal Crohn's disease after inducing remission with infliximab: how long should patients be treated? *Aliment Pharmacol Ther* 2005;**22**:1107-1113.
50. Chaparro M, Zanotti C, Burgueno P, et al. Health care costs of complex perianal fistula in Crohn's disease. *Dig Dis Sci* 2013;**58**:3400-3406.
51. Shenoy-Bhangle A, Nimkin K, Goldner D, Bradley WF, Israel EJ, Gee MS. MRI predictors of treatment response for perianal fistulizing Crohn disease in children and young adults. *Pediatr Radiol* 2014;**44**:23-29.
52. Maconi G, Tonolini M, Monteleone M, et al. Transperineal perineal ultrasound versus magnetic resonance imaging in the assessment of perianal Crohn's disease. *Inflamm Bowel Dis* 2013;**19**:2737-2743.
53. Schwartz DA, Wiersema MJ, Dudiak KM, et al. A comparison of endoscopic ultrasound, magnetic resonance imaging, and exam under anesthesia for evaluation of Crohn's perianal fistulas. *Gastroenterology* 2001;**121**:1064-1072.
54. Jones DW, Finlayson SR. Trends in surgery for Crohn's disease in the era of infliximab. *Ann Surg* 2010;**252**:307-312.
55. Williams JG, MacLeod CA, Rothenberger DA, Goldberg SM. Seton treatment of high anal fistulae. *Br J Surg* 1991;**78**:1159-1161.
56. Buchanan GN, Owen HA, Torkington J, Lunniss PJ, Nicholls RJ, Cohen CR. Long-term outcome following loose-seton technique for external sphincter preservation in complex anal fistula. *Br J Surg* 2004;**91**:476-480.
57. Williams JG, Rothenberger DA, Nemer FD, Goldberg SM. Fistula-in-ano in Crohn's disease. Results of aggressive surgical treatment. *Dis Colon Rectum* 1991;**34**:378-384.
58. Fuhrman GM, Larach SW. Experience with perirectal fistulas in patients with Crohn's disease. *Dis Colon Rectum* 1989;**32**:847-848.
59. Makowiec F, Jehle EC, Starlinger M. Clinical course of perianal fistulas in Crohn's disease. *Gut* 1995;**37**:696-701.
60. Taxonera C, Schwartz DA, Garcia-Olmo D. Emerging treatments for complex perianal fistula in Crohn's disease. *World J Gastroenterol* 2009;**15**:4263-4272.
61. van der Hagen SJ, Baeten CG, Soeters PB, Beets-Tan RG, Russel MG, van Gemert WG. Staged mucosal advancement flap for the treatment of complex anal fistulas: pretreatment with noncutting setons and in case of recurrent multiple abscesses a diverting stoma. *Colorectal Dis* 2005;**7**:513-518.
62. Bodzin JH. Laser ablation of complex perianal fistulas preserves continence and is a rectum-sparing alternative in Crohn's disease patients. *Am Surg* 1998;**64**:627-631.
63. Moy J, Bodzin J. Carbon dioxide laser ablation of perianal fistulas in patients with Crohn's disease: experience with 27 patients. *Am J Surg* 2006;**191**:424-427.
64. Yamamoto T, Allan RN, Keighley MR. Effect of fecal diversion alone on perianal Crohn's disease. *World J Surg* 2000;**24**:1258-1262.
65. Edwards CM, George BD, Jewell DP, Warren BF, Mortensen NJ, Kettlewell MG. Role of a defunctioning stoma in the management of large bowel Crohn's disease. *Br J Surg* 2000;**87**:1063-1066.
66. Regimbeau JM, Panis Y, Cazaban L, et al. Long-term results of faecal diversion for refractory perianal Crohn's disease. *Colorectal Dis* 2001;**3**:232-237.
67. Grant DR, Cohen Z, McLeod RS. Loop ileostomy for anorectal Crohn's disease. *Can J Surg* 1986;**29**:32-35.
68. Harper PH, Kettlewell MG, Lee EC. The effect of split ileostomy on perianal Crohn's disease. *Br J Surg* 1982;**69**:608-610.
69. Grimaud JC, Munoz-Bongrand N, Siproudhis L, et al. Fibrin glue is effective healing perianal fistulas in patients with Crohn's disease. *Gastroenterology* 2010;**138**:2275-2281.
70. Abel ME, Chiu YS, Russell TR, Volpe PA. Autologous fibrin glue in the treatment of rectovaginal and complex fistulas. *Dis Colon Rectum* 1993;**36**:447-449.
71. Zmora O, Mizrahi N, Rotholtz N, et al. Fibrin glue sealing in the

- treatment of perineal fistulas. *Dis Colon Rectum* 2003;**46**:584-589.
72. Ng SC, Plamondon S, Gupta A, et al. Prospective evaluation of anti-tumor necrosis factor therapy guided by magnetic resonance imaging for Crohn's perineal fistulas. *Am J Gastroenterol* 2009;**104**:2973-2986.
  73. Schwartz DA. Editorial: Imaging and the treatment of Crohn's perianal fistulas: to see is to believe. *Am J Gastroenterol* 2009;**104**:2987-2989.
  74. Sehgal R, Koltun WA. Fibrin glue for the treatment of perineal fistulous Crohn's disease. *Gastroenterology* 2010;**138**:2216-2219.
  75. Vitton V, Gasmi M, Barthet M, Desjeux A, Orsoni P, Grimaud JC. Long-term healing of Crohn's anal fistulas with fibrin glue injection. *Aliment Pharmacol Ther* 2005;**21**:1453-1457.
  76. Garcia-Olmo D, Herreros D, Pascual I, et al. Expanded adipose-derived stem cells for the treatment of complex perianal fistula: a phase II clinical trial. *Dis Colon Rectum* 2009;**52**:79-86.
  77. Guadalajara H, Herreros D, De-La-Quintana P, Trebol J, Garcia-Arranz M, Garcia-Olmo D. Long-term follow-up of patients undergoing adipose-derived adult stem cell administration to treat complex perianal fistulas. *Int J Colorectal Dis* 2012;**27**:595-600.
  78. Johnson EK, Gaw JU, Armstrong DN. Efficacy of anal fistula plug vs. fibrin glue in closure of anorectal fistulas. *Dis Colon Rectum* 2006;**49**:371-376.
  79. O'Connor L, Champagne BJ, Ferguson MA, Orangio GR, Schertzer ME, Armstrong DN. Efficacy of anal fistula plug in closure of Crohn's anorectal fistulas. *Dis Colon Rectum* 2006;**49**:1569-1573.
  80. O'Riordan JM, Datta I, Johnston C, Baxter NN. A systematic review of the anal fistula plug for patients with Crohn's and non-Crohn's related fistula-in-ano. *Dis Colon Rectum* 2012;**55**:351-358.
  81. McGee MF, Champagne BJ, Stulberg JJ, Reynolds H, Marderstein E, Delaney CP. Tract length predicts successful closure with anal fistula plug in cryptoglandular fistulas. *Dis Colon Rectum* 2010;**53**:1116-1120.
  82. Joo JS, Weiss EG, Noguera JJ, Wexner SD. Endorectal advancement flap in perianal Crohn's disease. *Am Surg* 1998;**64**:147-150.
  83. Fazio VW, Aufses AH, Jr. Evolution of surgery for Crohn's disease: a century of progress. *Dis Colon Rectum* 1999;**42**:979-988.
  84. van der Hagen SJ, Baeten CG, Soeters PB, van Gemert WG. Autologous platelet-derived growth factors (platelet-rich plasma) as an adjunct to mucosal advancement flap in high cryptoglandular perianal fistulae: a pilot study. *Colorectal Dis* 2011;**13**:215-218.
  85. Soltani A, Kaiser AM. Endorectal advancement flap for cryptoglandular or Crohn's fistula-in-ano. *Dis Colon Rectum* 2010;**53**:486-495.
  86. van der Hagen SJ, Baeten CG, Soeters PB, Russel MG, Beets-Tan RG, van Gemert WG. Anti-TNF-alpha (infliximab) used as induction treatment in case of active proctitis in a multistep strategy followed by definitive surgery of complex anal fistulas in Crohn's disease: a preliminary report. *Dis Colon Rectum* 2005;**48**:758-767.
  87. Simmang CL, Lacey SW, Huber PJ, Jr. Rectal sleeve advancement: repair of rectovaginal fistula associated with anorectal stricture in Crohn's disease. *Dis Colon Rectum* 1998;**41**:787-789.
  88. Rojanasakul A, Pattanaarun J, Sahakitrungruang C, Tantiphlachiva K. Total anal sphincter saving technique for fistula-in-ano; the ligation of intersphincteric fistula tract. *J Med Assoc Thai* 2007;**90**:581-586.
  89. Casson DH, Eltumi M, Tomlin S, Walker-Smith JA, Murch SH. Topical tacrolimus may be effective in the treatment of oral and perineal Crohn's disease. *Gut* 2000;**47**:436-440.
  90. Hart AL, Plamondon S, Kamm MA. Topical tacrolimus in the treatment of perianal Crohn's disease: exploratory randomized controlled trial. *Inflamm Bowel Dis* 2007;**13**:245-253.
  91. McSharry K, Dalzell AM, Leiper K, El-Matary W. Systematic review: the role of tacrolimus in the management of Crohn's disease. *Aliment Pharmacol Ther* 2011;**34**:1282-1294.
  92. Poggioli G, Laureti S, Pierangeli F, et al. Local injection of adalimumab for perianal Crohn's disease: better than infliximab? *Inflamm Bowel Dis* 2010;**16**:1631.
  93. Poggioli G, Laureti S, Pierangeli F, et al. Local injection of Infliximab for the treatment of perianal Crohn's disease. *Dis Colon Rectum* 2005;**48**:768-774.
  94. Tonelli F, Giudici F, Asteria CR. Effectiveness and safety of local adalimumab injection in patients with fistulizing perianal Crohn's disease: a pilot study. *Dis Colon Rectum* 2012;**55**:870-875.
  95. Collie MH, Potter MA, Bartolo DC. Myocutaneous flaps promote perineal healing in inflammatory bowel disease. *Br J Surg* 2005;**92**:740-741.
  96. Schaden D, Schauer G, Haas F, Berger A. Myocutaneous flaps and proctocolectomy in severe perianal Crohn's disease-a single stage procedure. *Int J Colorectal Dis* 2007;**22**:1453-1457.
  97. Uzzan M, Stefanescu C, Maggiori L, Panis Y, Bouhnik Y, Treton X. Case series: does a combination of anti-tnf antibodies and transient ileal fecal stream diversion in severe Crohn's colitis with perianal fistula prevent definitive stoma? *Am J Gastroenterol* 2013;**108**:1666-1668.
  98. Ky A, Sohn N, Weinstein MA, Korelitz BI. Carcinoma arising in anorectal fistulas of Crohn's disease. *Dis Colon Rectum* 1998;**41**:992-996.
  99. Ogawa H, Haneda S, Shibata C, et al. Adenocarcinoma associated with perianal fistulas in Crohn's disease. *Anticancer Res* 2013;**33**:685-689.
  100. Church JM, Fazio VW, Lavery IC, Oakley JR, Milsom JW. The differential diagnosis and comorbidity of hidradenitis suppurativa and perianal Crohn's disease. *Int J Colorectal Dis* 1993;**8**:117-119.
  101. Vazquez BG, Alikhan A, Weaver AL, Wetter DA, Davis MD. Incidence of hidradenitis suppurativa and associated factors: a population-based study of Olmsted County, Minnesota. *J Invest Dermatol* 2013;**133**:97-103.
  102. Bocchini SF, Habr-Gama A, Kiss DR, Imperiale AR, Araujo SE. Gluteal and perianal hidradenitis suppurativa: surgical treatment by wide excision. *Dis Colon Rectum* 2003;**46**:944-949.
  103. Scheinfeld N. Diseases associated with hidradenitis suppurativa: part 2 of a series on hidradenitis. *Dermatol Online J* 2013;**19**:18558.
  104. Wiltz O, Schoetz DJ, Jr, Murray JJ, Roberts PL, Coller JA, Veidenheimer MC. Perianal hidradenitis suppurativa. The Lahey clinic experience. *Dis Colon Rectum* 1990;**33**:731-734.
  105. Perez-Diaz D, Calvo-Serrano M, Martinez-Hijos E, et al. Squamous cell carcinoma complicating perianal hidradenitis suppurativa. *Int J Colorectal Dis* 1995;**10**:225-228.
  106. Shukla VK, Hughes LE. A case of squamous cell carcinoma complicating hidradenitis suppurativa. *Eur J Surg Oncol* 1995;**21**:106-109.
  107. Park JJ, Cintron JR, Orsay CP, et al. Repair of chronic anorectal fistulae using commercial fibrin sealant. *Arch Surg* 2000;**135**:166-169.
  108. Cintron JR, Park JJ, Orsay CP, et al. Repair of fistulas-in-ano using fibrin adhesive: long-term follow-up. *Dis Colon Rectum* 2000;**43**:944-949.
  109. Lindsey I, Smilgin-Humphreys MM, Cunningham C, Mortensen NJ, George BD. A randomized, controlled trial of fibrin glue vs. conventional treatment for anal fistula. *Dis Colon Rectum* 2002;**45**:1608-1615.
  110. Sentovich SM. Fibrin glue for anal fistulas: long-term results. *Dis Colon Rectum* 2003;**46**:498-502.
  111. Loungnarath R, Dietz DW, Mutch MG, Birnbaum EH, Kodner JJ, Fleshman JW. Fibrin glue treatment of complex anal fistulas has

- low success rate. *Dis Colon Rectum* 2004;**47**:432-436.
112. Singer M, Cintron J, Nelson R, et al. Treatment of fistulas-in-ano with fibrin sealant in combination with intra-adhesive antibiotics and/or surgical closure of the internal fistula opening. *Dis Colon Rectum* 2005;**48**:799-808.
  113. de Parades V, Far HS, Etienney I, Zeitoun JD, Atienza P, Bauer P. Seton drainage and fibrin glue injection for complex anal fistulas. *Colorectal Dis* 2010;**12**:459-463.
  114. Chung W, Ko D, Sun C, Raval MJ, Brown CJ, Phang PT. Outcomes of anal fistula surgery in patients with inflammatory bowel disease. *Am J Surg* 2010;**199**:609-613.
  115. Lee WY, Park KJ, Cho YB, et al. Autologous adipose tissue-derived stem cells treatment demonstrated favorable and sustainable therapeutic effect for Crohn's fistula. *Stem Cells* 2013;**31**:2575-2581.
  116. van Koperen PJ, D'Hoore A, Wolthuis AM, Bemelman WA, Slors JF. Anal fistula plug for closure of difficult anorectal fistula: a prospective study. *Dis Colon Rectum* 2007;**50**:2168-2172.
  117. El-Gazzaz G, Zutshi M, Hull T. A retrospective review of chronic anal fistulae treated by anal fistulae plug. *Colorectal Dis* 2010;**12**:442-447.
  118. Ky AJ, Sylla P, Steinhagen R, Steinhagen E, Khaitov S, Ly EK. Collagen fistula plug for the treatment of anal fistulas. *Dis Colon Rectum* 2008;**51**:838-843.
  119. Schwandner O, Fuerst A. Preliminary results on efficacy in closure of transsphincteric and rectovaginal fistulas associated with Crohn's disease using new biomaterials. *Surg Innov* 2009;**16**:162-168.
  120. Zubaidi A, Al-Obeed O. Anal fistula plug in high fistula-in-ano: an early Saudi experience. *Dis Colon Rectum* 2009;**52**:1584-1588.
  121. Lupinacci RM, Vallet C, Parc Y, Chafai N, Tiret E. Treatment of fistula-in-ano with the Surgisis((R)) AFP(TM) anal fistula plug. *Gastroenterol Clin Biol* 2010;**34**:549-553.
  122. Asteria CR, Ficari F, Bagnoli S, Milla M, Tonelli F. Treatment of perianal fistulas in Crohn's disease by local injection of antibody to TNF-alpha accounts for a favourable clinical response in selected cases: a pilot study. *Scand J Gastroenterol* 2006;**41**:1064-1072.