


Glottic Keratosis: Significance and Identification of Laryngoscopic Findings

Mursalin M. Anis, MD, PhD¹, Jennylee Diaz, MS, CCC-SLP¹, Mausam Patel², Adam T. Lloyd, SLP-D, CCC-SLP, MM¹, and David E. Rosow, MD¹

OTO Open
 2021, Vol. 5(1) 1–6
 © The Authors 2021
 Article reuse guidelines:
sagepub.com/journals-permissions
 DOI: 10.1177/2473974X21994743
<http://oto-open.org>


Abstract

Objective. Glottic keratosis poses a challenge because a decision to biopsy must weigh the likelihood of dysplasia and cancer against the voice outcome after biopsy. We determined the significance of laryngoscopic findings and agreement among clinicians to identify those specific findings.

Study Design. Retrospective case-control study.

Setting. Tertiary care university hospital.

Methods. Adults with glottic keratosis with preoperative office laryngoscopies were included. Preoperative videostroboscopies were reviewed by a blinded reviewer. Multivariable logistic regression was used to examine the correlation between laryngoscopic appearance of glottic keratosis and presence or absence of high-grade dysplasia or carcinoma on biopsies. Consensus among head and neck cancer surgeons to detect specific laryngoscopic findings was evaluated by presenting representative laryngoscopies to a blinded cohort. Interrater reliability was calculated using Fleiss's κ .

Results. Sixty glottic keratotic lesions met inclusion criteria. On logistic regression, both erythroplakia and aberrant microvasculature like vascular speckling were significantly associated with high-grade dysplasia and carcinoma, $P = .002$ and $P = .03$, respectively. Interrater reliability among clinicians to identify erythroplakia and aberrant microvasculature was minimal, $\kappa = 0.35$ and $\kappa = 0.29$, respectively. Interrater reliability was improved with the use of virtual chromoendoscopy.

Conclusion. The presence of erythroplakia and aberrant microvasculature in glottic keratosis is associated with the presence of high-grade dysplasia or carcinoma. Virtual chromoendoscopy can be used to improve reliability for detecting erythroplakia and vascular speckling, and this is a potential area for practice-based learning. Clinicians should identify and consider immediate diagnostic biopsy of suspicious glottic keratosis.

Keywords

glottic keratosis, erythroplakia, angiogenesis, leukoplakia, laryngeal cancer

Received December 5, 2020; accepted January 10, 2021.

Glottic keratosis is used to describe both the clinical appearance of white glottic lesions as well as a histological term to indicate squamous epithelial thickening with keratinization.^{1,2} The clinical appearance of keratosis could be flat or raised, smooth or nodular, localized or diffuse, and surrounded by either normal or inflamed tissue.³ *Keratosis* is often used interchangeably with *leukoplakia*, even though the latter means “white patch.” Keratosis may be associated with phonotraumatic lesions, and these generally have low malignant potential.^{4–6} All other glottic keratoses pose a difficult problem for clinical management. The histology and behavior of glottic keratosis can be frustratingly difficult to predict, as lesions can present on a spectrum anywhere from completely benign growth to invasive malignancy.^{1,7}

It is the macroscopic appearance and its correlation with malignancy that is of special interest to clinicians, due to the potential for guiding decision making at the time of initial laryngoscopic examination. One study classified vocal fold leukoplakia by its gross appearance into 3 subtypes: flat and smooth, elevated and smooth, and rough.⁸ “Rough” leukoplakia was broadly defined as having a wrinkled and corrugated appearance, and presence of carcinoma in rough leukoplakia was shown to be significantly higher than in smooth leukoplakia.⁸ Another study with similar morphologic characterization of 1635 glottic keratosis found that the rate of cancerization among rough keratotic lesions was 2.7 to 7.9 times higher than among smooth keratotic lesions.⁹ Other signs of increased malignant potential of glottic keratosis include presence of erythroplakia, surface granularity,

¹Department of Otolaryngology, University of Miami Miller School of Medicine, Miami, Florida, USA

²University of Miami Leonard M. Miller School of Medicine, Miami, Florida, USA

This article was a podium presentation at the Spring Meeting of the American Broncho-Esophagological Association; May 3, 2019; Austin, Texas.

Corresponding Author:

Mursalin M. Anis, MD, PhD, University of Miami Miller School of Medicine, Clinical Research Building, Fifth Floor, 1120 NW 14 St, Miami, FL 33136, USA.

Email: mursalin.anis@miami.edu



keratosis morphology of increased keratin thickness and increased size, recurrence after conservative removal, and long duration.^{1,3,7} In particular, erythroplakia, which means “red patch,” is considered the most important clinical predictor for either presence of malignancy or progression toward carcinoma.³

Another characteristic of glottic keratosis that has been associated with malignancy is abnormal subepithelial microvasculature.¹⁰ Neoangiogenesis of premalignant and malignant lesions leads to alterations in intraepithelial papillary capillary loops below the basement membrane of the epithelium.¹¹ Different imaging modalities have been developed to more accurately assess microvasculature, including narrow-band imaging (NBI), which uses filtered light to enhance the red-colored blood vessels. By comparison, virtual chromoendoscopy (VC) is a digital image-processing technology that performs computed filtering of an image acquired with white light, but it similarly accentuates subepithelial microvasculature. Both techniques have led to several studies that found a correlation between aberrant microvascular patterns such as vascular speckling and malignant histopathology.¹⁰⁻¹² The present study is predicated on the observation in our prior study that certain keratotic glottic lesions were found to harbor malignancy on histopathology despite having no vascular speckling.⁵ In this study, we sought to determine the relative significance of different laryngoscopic findings based on their correlation with histopathology. The significant laryngoscopic findings could alert clinicians to lesions that need expedient biopsy and treatment. In addition, the agreement between clinicians to detect these laryngoscopic findings in the first place was evaluated to determine any potential areas for practice improvement.

Methods

Patients

This study was approved by the University of Miami Institutional Review Board. Patients who underwent preoperative flexible laryngoscopy, videostroboscopy, and subsequent laryngeal biopsies by the senior author (D.E.R.) were identified in a retrospective chart review between January 1, 2012, and May 31, 2018. Inclusion criteria were patients with glottic keratosis whose preoperative laryngoscopies were accessible. Exclusion criteria were patients with impaired vocal fold mobility, patients who had any prior laryngeal biopsy, patients with prior irradiation to the neck, and patients with keratosis associated with phonotraumatic lesions. Preoperative laryngoscopies were done with a flexible distal-chip laryngoscope (Pentax) and a 70-degree rigid telescope. Occasionally, a rigid telescopic exam provided a sufficient clear view of microvasculature, but more often, flexible distal-chip laryngoscopes (Pentax) were used to get close enough to lesions and surrounding mucosa to clearly distinguish the vascularity. To perform closeup exams, patients had been topically anesthetized. Standardization of preoperative laryngoscopies was done by making sure all laryngeal examinations included in this study had sufficient

clarity to clearly delineate the microvasculature of vocal folds surrounding glottic keratosis.

Videostroboscopies done under white light were reviewed by a blinded laryngologist, and laryngoscopic findings of mass morphology, abnormal microvasculature-like vascular speckling, and vocal fold erythema around keratosis were recorded. Vocal fold erythema was defined as the presence of any shade of redness on the vocal folds around the keratosis. Abnormal microvasculature was defined as encompassing all aberrant microvascular patterns from speckling red dots (vascular speckling) to fragmented tortuous vessels. Mass morphology of a vocal fold lesion was defined as either an exophytic, thick hyperkeratotic lesion on the vocal fold or vocal fold fullness with overlying keratosis. Patient demographics, tobacco usage history, and final histopathology were recorded after assignment of laryngoscopic findings to each lesion. Patients were identified as cases if they had biopsy-proven high-grade dysplasia or carcinoma. Patients were identified as controls if they had benign or low-grade dysplasia on histopathology.

Method of Laryngeal Biopsy

Laryngeal biopsies were done either in the office or in the operating room as previously described. Briefly, in the office setting, atomized 4% lidocaine and oxymetazoline were used for local anesthetization. Biopsies were done with endoscopic biopsy forceps under the guidance of both white-light laryngoscopy and VC using i-scan (Pentax). For operative biopsies, briefly the laryngeal lesion was scrutinized under high magnification of the operating microscope, especially the suspicious areas seen on preoperative laryngoscopy. Biopsies sampled the most irregular, abnormal-appearing focus of a keratotic lesion as previously described.⁴ The KTP laser was then used to photoablate glottic keratosis based on intraoperative pathology, with the goal of preserving superficial lamina propria for optimal phonatory outcome.

Survey of Head and Neck Cancer Surgeons

Twenty-two representative videos of keratotic lesions on flexible laryngoscopy were compiled to create an online survey. The 22 videos included in the survey had 14 videos of laryngoscopies with white light and 8 videos of laryngoscopies employing VC. Videos were chosen so as to represent all 4 laryngoscopic findings of mass morphology, erythema, keratosis distribution, and aberrant microvasculature like vascular speckling in them. Laryngoscopies were done with white light and VC. Each video was followed by 4 specific questions (see Suppl. Figure S1 in the online version of the article). The survey allowed each rater to view each video multiple times. The survey was sent out to a group of fellowship-trained head and neck surgeons. Head and neck cancer surgeons were asked to provide their best responses to the questions on the online survey.

Statistical Analysis

A multivariable logistic regression was done. The dependent variable (end point) was the presence or absence of

high-grade dysplasia or carcinoma; these lesions were cases. Independent variables were age, sex, tobacco use, preoperative laryngoscopic findings of vascular speckling, erythema, and morphology. On histology, lesions diagnosed as either benign or low-grade dysplasia were grouped into a group designated as controls. Logistic regression was done in Microsoft Excel 2016 using the Real Statistics add-in.¹³ Statistical significance of results was chosen a priori to be $P < .05$.

Interrater reliability of head and neck cancer surgeons for each laryngoscopic finding (distribution, morphology, erythema, and vascular speckling) was calculated using Fleiss's κ . Intrarater reliability of each surgeon was estimated from replicates of 10% of the examinations, and Cohen's κ was used because of the categorical values for morphology, distribution, erythema, and abnormal microvasculature.¹⁴ Comparison of ratings by head and neck cancer surgeons using white light vs virtual chromoendoscopy was also calculated using Cohen's κ , with κ values reported along with 95% CIs.

Results

There were 60 glottic keratotic lesions from 60 patients that met the selection criteria. Ninety percent of the patients were males. Average age of the patients was 71 ± 14 years. The percentage of patients who reported alcohol consumption and either current or former tobacco smoking was 62% and 72%, respectively. Fifteen patients underwent office-based biopsy while the rest underwent operative biopsy (**Table 1**). In keeping with the published literature, 11 of the 15 office-based biopsies were done on highly suspicious keratotic lesions that were found on pathology to have either high-grade dysplasia or carcinoma.¹⁵ The remaining 4 lesions underwent office-based biopsy primarily for patient-dependent factors, including patient preference. In general, office-based biopsies were done on highly suspicious glottic keratosis in patients with advanced age or significant comorbidities to avoid the morbidity of general anesthesia. Histopathology of all the glottic keratoses in this study is presented in **Table 1**. Some of the lesions in the high-grade dysplasia group were read as "high-grade dysplasia" by pathologists while others were read as "carcinoma in situ" as had been described elsewhere.¹⁶ One patient had pathology described as "squamous epithelium with mild dysplasia," and this lesion was placed into the low-grade dysplasia group of this study. Two patients had benign squamous papilloma on histology; both of these patients had vascular speckling without any erythema. Papillomatous lesions in these patients were found to have flat morphology in 1 patient and mass morphology in the other.

Laryngoscopic findings of mass morphology, aberrant microvasculature-like vascular speckling, and vocal fold erythema adjacent to glottic keratosis were found in both cases and controls, but together, all 3 findings were only seen in high-grade dysplasia or carcinoma (**Figure 1**). To determine relative significance of specific laryngoscopic findings on preoperative exam and final histopathology, a

Table 1. Biopsy Method and Pathology of Glottic Keratosis.^a

Characteristic	Value
Office-based biopsy	15
Age of patient, mean \pm SD, y	79 ± 14
Pathology	
High-grade dysplasia or carcinoma	11
Low-grade dysplasia	2
Benign polyp with keratosis and inflammation	2
Operative biopsy	45
Age of patient, mean \pm SD, y	68 ± 13
Pathology	
High-grade dysplasia or carcinoma	30
Low-grade dysplasia	4
Benign	11
Hyperplastic squamous mucosa with keratosis	
Squamous mucosa with atypia and inflammation	
Vocal fold polyp with keratosis and inflammation	
Squamous papilloma	

^aValues are presented as numbers unless otherwise indicated.

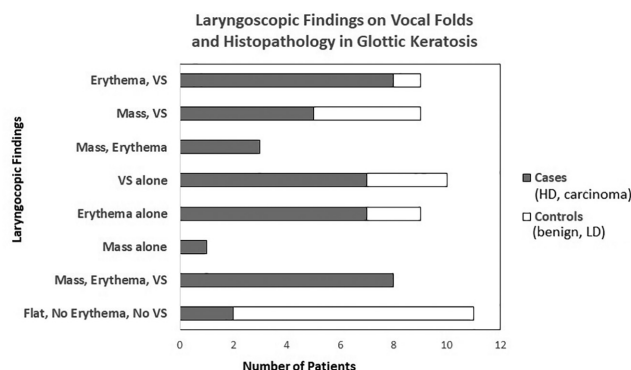


Figure 1. Laryngoscopic findings and histopathology in 60 patients with glottic keratosis. HD, high-grade dysplasia; LD, low-grade dysplasia; VS, aberrant microvasculature-like vascular speckling.

multivariable logistic regression was done. Vocal fold erythema adjacent to keratosis was strongly associated with carcinoma or high-grade dysplasia, $P = .002$. Aberrant microvasculature such as vascular speckling adjacent to keratosis was also associated with high-grade dysplasia or malignancy, $P = .03$. Whether or not a keratotic lesion had mass or flat morphology was not significantly associated with high-grade dysplasia or carcinoma, $P = .2$, in this pilot study.

There was moderate agreement among head and neck cancer surgeons in identifying morphology of keratosis (flat or mass) and distribution of keratosis (focal or diffuse), with Fleiss's κ values of 0.63 and 0.60, respectively (**Table 2**). However, findings of vocal fold erythema and vascular speckling in glottic keratosis had κ values of 0.35 and 0.29, respectively, indicating only fair agreement between raters for these laryngoscopic findings. Examples of vocal fold

Table 2. Interrater Reliability of Head and Neck Surgeons in Evaluating Glottic Keratosis.

Laryngoscopic findings	Fleiss's κ	95% CI
Morphology of keratosis ^a	0.63	0.44-0.81
Distribution of keratosis ^b	0.60	0.42-0.79
Erythema around keratosis	0.35	0.17-0.53
Vascular speckling on keratosis ^c	0.29	0.11-0.47

^aMass morphology or flat morphology of keratosis.

^bDiffuse or keratosis confined to 1 vocal fold.

^cAbnormal microvasculature on or around keratosis. Intrarater reliability = 1 among all 4 head and neck surgeons.

erythema and abnormal microvasculature shown in the survey are presented in Figure 2 and Supplemental Figure S2 (in the online version of the article). Overall intrarater reliability from replicates was calculated to be 1 using Cohen's κ .

Interrater reliability of detecting keratosis morphology, distribution, erythema, and vascular speckling was better with VC than with white light (**Table 3**). For vocal fold erythema and vascular speckling especially, interrater reliability improved with VC. There were replicates of exams with both white light and VC in the survey. There was substantial agreement between white light and VC on keratosis morphology and distribution (Cohen's κ of 0.78 and 0.66, respectively) (**Table 4**). Erythema around keratosis and aberrant microvasculature-like vascular speckling had no agreement between the 2 imaging modes.

Discussion

The first part of this pilot study was to examine the relative importance of laryngoscopic findings of "classic" erythroplakia and aberrant microvasculature in relation to histopathology. The second aspect of this study was to uncover any gap in applying knowledge of specific laryngoscopic findings, which could be a potential topic for practice-based learning. Analysis of blinded examinations of glottic keratoses found that erythroplakia and vascular speckling were both associated with high-grade dysplasia and squamous cell carcinoma on histopathology. However, keratosis morphology of flatness, exophytic thickness, or underlying vocal fold fullness was not associated with high-grade dysplasia or carcinoma in this retrospective pilot study. Although nearly half of laryngeal keratosis is due to benign etiology, the clinical appearance of keratosis is important in detecting keratotic lesions at greatest risk of harboring malignancy or progressing toward it.^{3,17} Erythroplakia and specifically erythrokeratosis, which is the presence of both keratosis and erythroplakia, have been recognized as lesions concerning for malignancy at least as early as 1946.^{1,3} Clerf¹ described glottic keratoses with inflammatory changes on mirror laryngoscopy that on histopathology were suggestive of early carcinoma. Some of these lesions progressed, and subsequent biopsy specimens showed definite infiltration of the basement membrane. They were

surgically treated accordingly. Authors of this study consider the "inflammatory changes" described on mirror laryngoscopy by Clerf to be identical to the laryngoscopic findings of erythema around glottic keratoses found in the present study.

Although mass morphology of glottic keratoses was not associated with high-grade dysplasia or carcinoma in the present pilot study, previous studies had shown that granularity or papillary texture of the keratoses, along with increased keratin thickness and increased size, was associated with greater risk of presence or progression toward carcinoma.³ In this study, all glottic keratoses with laryngoscopic findings of erythema, vascular speckling, and mass morphology were noted to harbor high-grade dysplasia or carcinoma on histology (**Figure 1**). Only 18% of glottic keratoses that were flat without any erythema or abnormal microvasculature were found to have high-grade dysplasia. However, intraoperative microscopic findings of these keratoses identified "papillary" texture and "heaped-up epithelium" indicating thick keratoses that were not appreciated by the blinded reviewer on preoperative flexible laryngoscopy. While these "papillary" lesions proved to be malignant on histology, there were also keratotic lesions in this pilot study that had "papillary" texture with vascular speckling on laryngoscopy that proved to be benign squamous papilloma on pathology. This underscores the importance of both clinical appearance and histopathology in evaluating glottic keratoses.

To determine consensus among head and neck cancer surgeons on specific laryngoscopic findings, a survey of preoperative laryngoscopies was sent to 4 surgeons. An additional laryngoscopic finding of distribution of keratosis, either diffuse or focal, was added to ensure that there was at least 1 finding that raters could agree upon. In general, raters were in agreement with the characterization of both keratosis morphology (flat or mass) and distribution (focal or diffuse) (**Table 2**). There was moderate agreement between raters in identifying keratosis morphology with or without VC (**Table 3**). For characterizing mass morphology, examination with white light alone may be sufficient due to near-complete agreement between the 2 imaging modes (**Table 4**). However, the addition of postprocessing imaging technology improved agreement among raters in characterizing the distribution of keratosis (**Table 3**). When the entire data set was reanalyzed with inclusion of distribution of keratosis as an additional laryngoscopic finding, no association was found between distribution of keratosis and high-grade dysplasia or carcinoma on histopathology (data not shown).

Digital processing imaging technology improved interrater reliability in detecting vocal fold erythema and vascular speckling associated with keratosis (**Table 3**). Improved reliability is most likely due to ease of detection. Since virtual chromoendoscopy is designed to enhance visualization of subepithelial microvascular patterns that are red, erythroplakia and aberrant microvasculature are similarly accentuated as seen with studies using NBI.¹⁸ With white light,

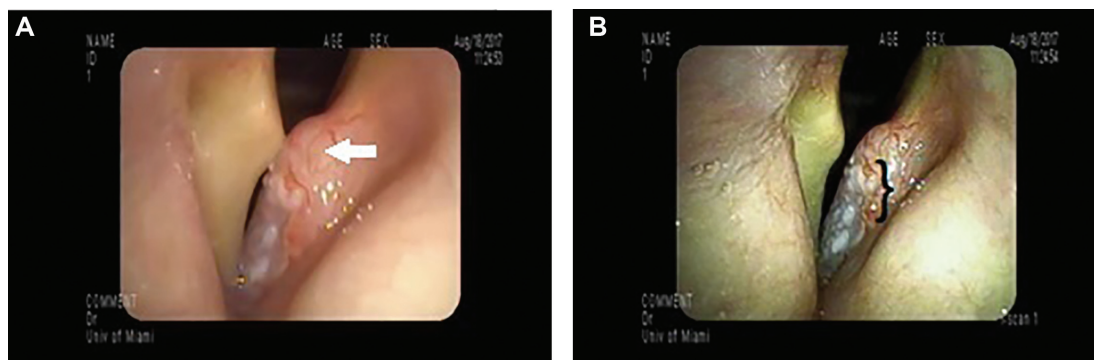


Figure 2. Representative exams from the survey. (A) Keratotic mass (squamous cell carcinoma) with fullness (white arrow) under white light. (B) Lesion under virtual chromoendoscopy enhancing aberrant microvasculature (black bracket) adjacent to keratosis.

Table 3. Interrater Reliability^a With and Without Digital Processing Imaging Technology.

Laryngoscopic findings	White light	Virtual chromoendoscopy
Morphology of keratosis ^b	0.66 (0.43-0.88)	0.73 (0.38-1.1)
Distribution of keratosis ^c	0.53 (0.31-0.75)	0.73 (0.38-1.1)
Erythema around keratosis	0.25 (0.02-0.47)	0.52 (0.17-0.88)
Vascular speckling on keratosis ^d	0.14 (-0.08-0.36)	0.39 (0.04-0.75)

^aFleiss's κ (95% CI).

^bMass morphology or flat morphology of keratosis.

^cDiffuse or keratosis confined to 1 vocal fold.

^dAbnormal microvasculature on or around keratosis.

Table 4. Agreement Between White Light and Virtual Chromoendoscopy.

Laryngoscopic findings	Cohen's κ (95% CI)
Morphology of keratosis ^a	0.78 (0.48 to 1.1)
Distribution of keratosis ^b	0.66 (0.35 to 0.96)
Erythema around keratosis	0.22 (-0.23 to 0.67)
Vascular speckling on keratosis ^c	0.37 (-0.02 to 0.77)

^aMass morphology or flat morphology of keratosis.

^bDiffuse or keratosis confined to 1 vocal fold.

^cAbnormal microvasculature on or around keratosis.

there was fair agreement among raters in detecting erythema around keratosis and no agreement in identifying abnormal microvasculature like vascular speckling. Thus, some form of imaging modality that enhances visualization of redness in laryngoscopy either during image acquisition or postprocessing may be essential to consistently identify erythema and abnormal microvasculature-like vascular speckling, both of which are associated with high-grade dysplasia and carcinoma.^{3,5,13} Even with exams using VC, when specifically prompted to identify abnormal microvasculature around keratosis, the interrater reliability was fair among head and neck cancer surgeons. Perhaps this could be an

area for practice improvement where appearances of erythroplakia and abnormal microvasculature both under white light and VC could be learned by clinicians as part of continuing medical education. That would be essential before routine adoption of VC in evaluation of glottic keratosis.

Aside for limitations inherent in retrospective studies, this pilot study was limited by sample size. A larger sample size may have found an association between keratosis morphology and carcinoma as noted in the literature.^{1,3,7} Second, the findings of minimal to absent interrater reliability in detecting erythroplakia and abnormal microvasculature-like vascular speckling in glottic keratosis need to be reproduced with larger number of questions and raters. Last, there were a few lesions in this study in which the preoperative laryngoscopic findings assessed by the blinded reviewer and the intraoperative microscopic findings did not concur. This underscores the need to correlate laryngoscopic and operative microscopic appearances of glottic keratosis in future studies.

Conclusion

Erythroplakia around keratosis and abnormal microvasculature-like vascular speckling could be used to risk stratify glottic keratoses into lesions that warrant diagnostic biopsy sooner than later. A potential topic for continuing medical education for otolaryngologists and head and neck cancer surgeons could be identification of aberrant microvasculature around glottic keratosis on laryngoscopy and operative microscopy. Either NBI or virtual chromoendoscopy could be used to improve consensus among clinicians to detect erythroplakia and vascular speckling. Finally, clinical appearance and histopathology are both important in evaluating glottic keratosis.

Author Contributions

Mursalim M. Anis, substantial contributions to conception and design, acquisition of data, analysis and interpretation of data, drafting the article and critically revising article for important intellectual content, final approval of the version to be published, and agreement to be accountable for all aspects of the work; **Jennylee Diaz**, substantial contributions to acquisition of data, revising article for important intellectual content, final approval of the version to be published, and agreement to be accountable for

all aspects of the work; **Mausam Patel**, substantial contributions to acquisition of data, drafting article, final approval of the version to be published, and agreement to be accountable for all aspects of the work, **Adam T. Lloyd**, substantial contributions to acquisition of data, revising article for important intellectual content, final approval of the version to be published, and agreement to be accountable for all aspects of the work; **David E. Rosow**, substantial contributions to interpretation of data, critically revising article for important intellectual content, final approval of the version to be published, and agreement to be accountable for all aspects of the work.

Disclosures

Competing interests: None.

Sponsorships: None.

Funding source: None.

Supplemental Material

Additional supporting information is available at <http://journals.sagepub.com/doi/suppl/10.1177/2473974X21994743>

References

1. Clerf LH. Keratosis of the larynx. *JAMA*. 1946;132(14):823-826.
2. Norris CM, Peale AR. Keratosis of the larynx. *J Laryngol Otol*. 1963;77:635-647.
3. Bouquot JE, Gnepp DR. Laryngeal precancer: a review of the literature, commentary, and comparison with oral leukoplakia. *Head Neck*. 1991;13:488-497.
4. Zeitels SM. Premalignant epithelium and microinvasive cancer of the vocal fold: the evolution of phonosurgical management. *Laryngoscope*. 1995;105(3):1-40.
5. Anis MM. Correlating laryngoscopic appearance of laryngeal lesions with histopathology. *Laryngoscope*. 2019;129(6):1308-1312.
6. Lim S, Sau P, Cooper L, McPhaden A, Mackenzie K. The incidence of premalignant and malignant disease in Reinke's edema. *Otolaryngol Head Neck Surg*. 2014;150(3):434-436.
7. Putney FJ, O'Keefe JJ. The clinical significance of keratosis of the larynx as a premalignant lesion. *Ann Otol Rhinol Laryngol*. 1953;62:348-358.
8. Chen M, Cheng L, Li C, et al. Nonsurgical treatment for vocal fold leukoplakia: an analysis of 178 cases. *Biomed Res Int*. 2017;2017:6958250.
9. Zhang N, Cheng L, Chen M, et al. Relationship between laryngoscopic and pathological characteristics of vocal cords leukoplakia. *Acta Otolaryngol*. 2017;137(11):1199-1203.
10. Klimza H, Jackowska J, Tokarski M, Piersiala K, Wierzbicka M. Narrow-band imaging (NBI) for improving the assessment of vocal fold leukoplakia and overcoming the umbrella effect. *PLoS ONE*. 2017;12(6):e0180590.
11. Kraft M, Fostiropoulos K, Gurtler N, Arnoux A, Davaris N, Arens C. Value of narrow band imaging in the early diagnosis of laryngeal cancer. *Head Neck*. 2016;38:15-20.
12. Rzepakowska A, Sielska-Badurek E, Cruz R, et al. Narrow band imaging versus laryngovideoscopy in precancerous and malignant vocal fold lesions. *Head Neck*. 2018;40:927-936.
13. Zaiontz C. Real statistics using Excel. Accessed October 20, 2018. <http://www.real-statistics.com>
14. Gwet K. Intrarater reliability. In: Balakrishnan N, ed. *Methods and Applications of Statistics in Clinical Trials: Vol. 2. Planning, Analysis, and Inferential Methods*. Wiley Online Books, 2013:340-355.
15. Richard AL, Sugumaran M, Aviv JE, Woo P, Altman KW. The utility of office-based biopsy for laryngopharyngeal lesions: comparison with surgical evaluation. *Laryngoscope*. 2015;125(4):909-912.
16. Cho KJ, Song JS. Recent changes of classification for squamous intraepithelial lesions of the head and neck. *Arch Pathol Lab Med*. 2018;142(7):829-832.
17. Isenberg JS, Crozier DL, Dailey SH. Institutional and comprehensive review of laryngeal leukoplakia. *Ann Otol Rhinol Laryngol*. 2008;117(1):74-79.
18. Ximeng Q, Dan Y, Xue Z, et al. Clinical experiences of NBI laryngoscope in diagnosis of laryngeal lesions. *Int J Clin Exp Med*. 2014;7(10):3305-3312.