

## Original Article

# Preliminary study on safe thresholds for temporary internal carotid artery occlusion in aneurysm surgery based on motor-evoked potential monitoring

Jun Tanabe, Tatsuya Ishikawa, Junta Moroi, Akifumi Suzuki

Department of Surgical Neurology, Research Institute for Brain and Blood Vessels-AKITA, 6-10 Senshu-Kubota-Machi, Akita, Japan

E-mail: \*Jun Tanabe - [j.tanabe@akita-noken.jp](mailto:j.tanabe@akita-noken.jp); Tatsuya Ishikawa - [teddyish@akita-noken.jp](mailto:teddyish@akita-noken.jp); Junta Moroi - [moroi@akita-noken.jp](mailto:moroi@akita-noken.jp); Akifumi Suzuki - [akifumi@akita-noken.jp](mailto:akifumi@akita-noken.jp)

\*Corresponding author

Received: 18 November 13 Accepted: 23 February 14 Published: 11 April 14

**This article may be cited as:**Tanabe J, Ishikawa T, Moroi J, Suzuki A. Preliminary study on safe thresholds for temporary internal carotid artery occlusion in aneurysm surgery based on motor-evoked potential monitoring. *Surg Neurol Int* 2014;5:47.Available FREE in open access from: <http://www.surgicalneurologyint.com/text.asp?2014/5/1/47/130560>

Copyright: © 2014 Tanabe J. This is an open-access article distributed under the terms of the Creative Commons Attribution License, which permits unrestricted use, distribution, and reproduction in any medium, provided the original author and source are credited.

## Abstract

**Background:** The study aims were to clarify safe duration for temporary vessel occlusion of the internal carotid artery (ICA) during aneurysm surgery as exactly as possible. We examined safe time duration (*STD*), where brain tissue exposed to ischemia will never fall into even the ischemic penumbra using intraoperative motor-evoked potential (MEP).

**Methods:** In 45 patients, temporary occlusion of the ICA was performed with MEP. We measured *STD* as the duration of temporary vessel occlusion during which MEP changes did not occur. To estimate average *STD*, we calculated the 95% confidence interval for the population mean from sample data for *STD* in patients with MEP changes and in patients without changes.

**Results:** In the proximal-control group, 4 of 38 patients (10.5%) developed intraoperative MEP changes. In 4 patients, the time to MEP change (i.e. *STD*) was  $6.0 \pm 2.5$  min. *STD* was  $3.8 \pm 1.6$  min in the 34 patients without changes. The average *STD* was  $4.0 \pm 0.6$  min. In the trap group (proximal and distal flow control), five of seven patients (60.0%) experienced intraoperative MEP changes (*STD*,  $2.3 \pm 1.0$  min). All patients in the trap group who developed MEP changes showed involvement of the anterior choroidal artery (AChA) in the trapped segment. Average *STD* was  $2.3 \pm 1.1$  min when trapping involving the AChA.

**Conclusions:** Although the study is preliminary based on the limited number of the patients, the 95% upper confidence limit for average *STD* was 4.6 min when the ICA was occluded proximal to the aneurysm, 3.4 min when the ICA was trapped involving the AChA.

**Key Words:** Aneurysm surgery, internal carotid artery trapping, motor-evoked potential, temporary vessel occlusion

**Access this article online****Website:**[www.surgicalneurologyint.com](http://www.surgicalneurologyint.com)**DOI:**

10.4103/2152-7806.130560

**Quick Response Code:**

## INTRODUCTION

Intraoperative aneurysm rupture is known to be associated with increased morbidity and mortality.<sup>[2,19]</sup>

Temporary vessel occlusion is an effective technique not only to manage aneurysm rupture, but also to facilitate dissection and clip application by decreasing the pressure and bulk of an aneurysm, and thus reduce

the risk of procedure-related rupture.<sup>[6,19]</sup> In particular, this approach is helpful when managing aneurysm at the internal carotid artery (ICA), because these aneurysms are high pressure and often adherent to the dura mater at the tentorial edge, from which the aneurysm must be dissected before clipping. However, temporary vessel occlusion is well known to carry an inevitable amount of risk for ischemic brain damage. It is empirically clear that temporary vessel occlusion leads to postoperative conditions in progressing order of no neurological deficits, transient neurological deficits without any cerebral infarction, transient neurological deficits with cerebral infarctions, and permanent neurological deficits with cerebral infarction. The duration available for safe temporary vessel occlusion has already been widely discussed.<sup>[3,10,13,14]</sup> In previous discussions, however, safe duration of occlusion has usually been estimated as the duration in which occlusion can be performed without producing neurological deficits and/or without cerebral infarction.

Monitoring with motor-evoked potential (MEP) has been used to monitor the function of the pyramidal tract during aneurysm surgery under general anesthesia.<sup>[5,16]</sup> Monitoring with MEP has been proven to be more sensitive and objective alternate of neurological symptoms, allowing evaluation of the risk of cerebral ischemia during surgery. Using MEP monitoring, we tried to investigate the safe duration of ICA occlusion in aneurysm surgery.

## MATERIALS AND METHODS

Between January 2007 and January 2012, a total of 279 patients underwent aneurysm clipping surgery with MEP monitoring at our institute. Data from these patients were reviewed for this study. In 45 patients (mean age,  $65.2 \pm 11.2$  years; 5 men, 40 women), temporary occlusion of the ICA was performed. Aneurysms were located at the C2 portion in 3 patients, at the bifurcation of the posterior communicating artery in 41 patients, and at the terminal portion in 1 patient.

Anesthesia was induced with a bolus injection of propofol (1.5-2 mg/kg) and fentanyl (2  $\mu$ g/kg), and maintained with continuous injection propofol (4-10 mg/kg/h) and remifentanyl (0.1-0.3  $\mu$ g/kg/min). All patients were administered a bolus injection of vecuronium bromide (0.1 mg/kg) when intubation was carried out. Muscular relaxation was avoided after induction of anesthesia to allow MEP monitoring. All 41 patients underwent pterional craniotomy using a transylvian approach. After craniotomy, a grid electrode strip with four electrodes (Unique Medical, Tokyo, Japan) was inserted into the subdural space to facilitate electrical stimulation of the hand motor cortex. A cathode needle electrode was inserted at the frontal pole zero electrode location. The electrode providing the largest MEP

amplitude to record a contralateral muscle response was chosen for continuous monitoring of MEP. To elicit MEP, we applied short trains of five rectangular stimuli with an individual pulse width of 0.2 ms and an interstimulus interval of 2 ms. Intraoperatively, stimulation intensity at a maximum level of 25 mA was adjusted to elicit stable motor responses in all target muscles. Compound muscle action potentials were recorded from the contralateral abductor pollicis brevis and abductor digiti minimi brevis using a pair of seal electrodes (Viking 4; Nicolet Biomedical Japan, Tokyo, Japan). We considered that MEP was significantly changed when amplitude decreased to less than 50% as compared with control levels.

We performed temporary vessel occlusion to reduce intraaneurysm pressure and thus facilitate dissection of the aneurysm while avoiding aneurysm rupture. Temporary occlusion was performed when intraoperative aneurysm rupture had occurred before neck clipping.<sup>[6]</sup> When we executed temporary vessel occlusion, we conventionally controlled only proximal flow at the intra- or extracranial ICA. We trapped the aneurysm not only when we decided flow control was insufficient using proximal flow control only, but also when we performed suction-decompression procedures. We tried to restore blood flow for no longer than 5 min if possible. We did not perform any procedure aiming to protect brains from ischemia during temporary vessel occlusion such as; induction of intraoperative hypothermia and hypertension, and intravenous barbiturate administration to produce electroencephalographic burst suppression in any of the patients in this series.

We measured the duration of temporary vessel occlusion in patients without MEP change as safe time duration (*STD*). In patients without any MEP changes, *STD* could be longer than measured values. In patients who developed MEP changes, the duration until MEP change was recorded as *STD*. When we performed temporary vessel occlusion more than once for a patient without MEP changes, the longest occlusion time was adopted as *STD*. In particular, when duration of temporary vessel occlusion exceeded 5 min, we performed the next application for temporary occlusion after restoring flow to the ICA for more than 5 min. To estimate average *STD*, we calculated the 95% confidence interval for the population mean from sample data for *STD* in all patients with MEP changes and in all patients without MEP changes. Average *STD* means estimate value of virtual population mean based on observed value.

For statistical analysis, Student's *t*-test was used. Differences were considered statistically significant at the  $P < 0.05$  level. Receiver-operating characteristics analysis was used to determine sensitivity and specificity for detecting MEP changes.

## RESULTS

Among 45 patients who underwent temporary vessel occlusion of the ICA, 38 (84.4%) received proximal flow control only (proximal-control group). The remaining seven patients (15.6%) underwent proximal and distal flow control to trap the aneurysm (trap group).

In the proximal-control group, 4 (10.5%) of the 38 patients developed significant intraoperative MEP changes [Tables 1 and 2]. *STD* was  $3.8 \pm 1.6$  min in patients without MEP changes. In all the four patients with MEP change, changes occurred during the first attempt at vessel occlusion (occlusion time,  $8.2 \pm 4.6$  min). Time to MEP change (i.e., *STD*) was  $6.0 \pm 2.5$  min. According to receiver-operating characteristic analysis for detecting MEP changes, sensitivity was 0.75 and specificity was

0.71 using a cut-off value of 5.0 min. The average *STD* was  $4.0 \pm 0.6$  min [Figure 1].

In the seven patients of the trap group, five (71.4%) experienced a significant intraoperative MEP change [Tables 1 and 2]. In two of five patients, a suction decompression method was employed. Time to MEP change (i.e., *STD*,  $2.3 \pm 1.0$  min) was significantly shorter than that in the proximal-control group ( $6.0 \pm 2.5$  min;  $P < 0.05$ ). All patients in the trap group who developed MEP change showed involvement of the anterior choroidal artery (AchA) within the trapped segment. In two patients of the trap group not showing MEP changes, in contrast, the AchA was not included within the trapped segments. Average *STD* was  $2.3 \pm 1.1$  min when trapping involved the AchA, and  $4.4 \pm 1.1$  min when the AchA was not involved [Figure 2]. The average *STD* when the ICA was trapped involving the AchA was significantly shorter than the other two ( $P < 0.05$  each).

In the nine patients with significant intraoperative MEP changes (permanent change in one patient, transient in eight), four patients in whom significant MEP changes lasted longer than 10 min have experienced postoperative motor deficits (transient in one; permanent in three). Patients with permanent MEP loss were followed by severe motor deficit. The underlying cause of motor deficit was infarction in the internal capsule in two cases and in the basal ganglia in one case, as evaluated by postoperative CT. The remaining patient did not develop any cerebral infarction. If MEP change was restored within 10 min, no new postoperative motor deficits or infarction according to CT occurred [Table 2].

**Table 1: Summary of 45 patients who underwent aneurysm surgery with temporary carotid artery occlusion\***

Parameters	Value (%)			
	Proximal group		Trap group	
	38		7	
No. of patients	MEP change	No MEP change	MEP change	No MEP change
No. of patients	4 (10.5)	34 (89.4)	5 (71.4)	2 (28.6)
Occlusion time (min)	$8.2 \pm 4.6$ (3.4-15.8)	$3.8 \pm 1.6$ (1.1-6.9); <i>STD</i>	$3.8 \pm 3.2$ (3.0-12.4)	$4.4 \pm 1.5$ (3.4-5.4); <i>STD</i>
Time to MEP change (min)	$6.0 \pm 2.5$ (3.0-10.0); <i>STD</i>	No change	$2.3 \pm 1.0$ (1.0-3.5); <i>STD</i>	No change
Average <i>STD</i> (min)	$4.0 \pm 0.6$		$2.3 \pm 1.1$ (AchA involved) $4.4 \pm 1.1$ (AchA not involved)	

\*Occlusion time and time to MEP change are presented as mean  $\pm$  standard deviation of the mean (range). AchA: Anterior choroidal artery. *STD*: Safe time duration. MEP: Motor-evoked potential. Average *STD* is the confidence interval at the 95% level for the population mean calculated from sample data for *STD* in patients with MEP changes and *STD* in patients without changes

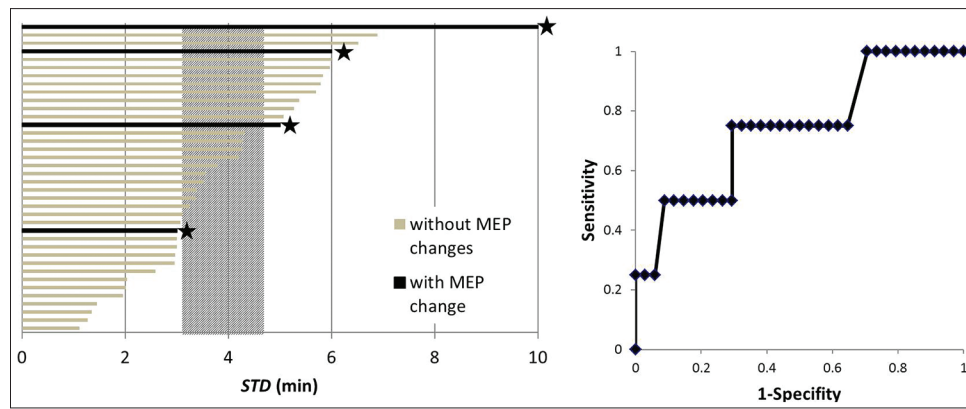
## DISCUSSION

Cerebral vascular occlusion results in a spatial graduation in blood flow attenuation in peripheral brain tissue. At the same time, graduation in brain function also occurs according to not only spatial, but also chronological

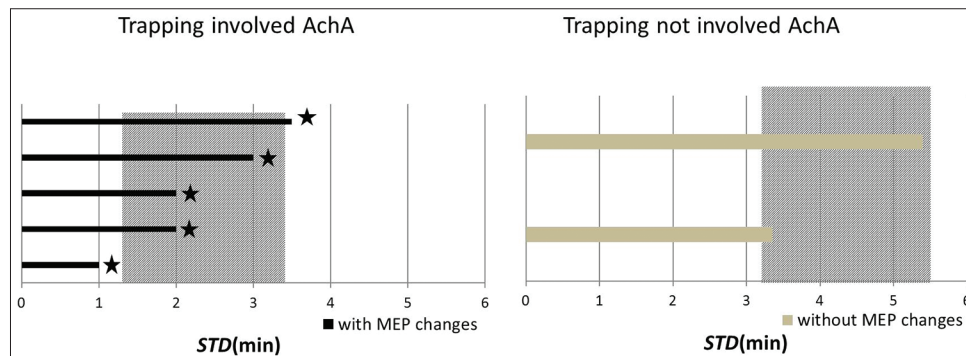
**Table 2: Characteristics of patients with intraoperative changes in MEP**

Case	Age/sex	Aneurysm location	Occlusion type	Occlusion time	Time to MEP change: <i>STD</i> (min)	Recovery time (min)	Motor outcome	Ischemia on postoperative CT
1	57/F	IC-PC	Proximal	15 min 49 s	10	5	Normal	No lesion
2	65/F	IC-PC	Proximal	5 min 34 s	4	3	Normal	No lesion
3	74/F	IC-PC	Trap	4 min 58 s	3	10	Hemiparesis	Internal capsule
4	67/F	IC-PC	Trap	3 min	2	2	Normal	No lesion
5	46/F	C2	Proximal	3 min 22 s	3	6	Normal	No lesion
6	74/F	IC-PC	Trap with suction decompression	3 min 43 s	1	2	Normal	No lesion
7	65/F	IC-PC	Trap	8 min 1 s	2	12	Transient	No lesion
8	83/M	IC-PC	Trap with suction decompression	12 min 21 s	3.5	10	Hemiparesis	Internal capsule
9	47/F	IC-PC	Proximal	6 min	5	Permanent	Hemiparesis	Basal ganglia

*STD*: Safe time duration. IC-PC: Internal carotid-posterior communicating artery aneurysm. MEP: Motor-evoked potential, CT: Computed tomography



**Figure 1:** The histogram demonstrates safe time duration (*STD*) for temporary vessel occlusion in the proximal-occlusion group. The shaded column demonstrates average *STD*, representing the 95% confidence interval for the population mean calculated from sample data for *STD* in patients with motor-evoked potential (MEP) changes and *STD* in patients without changes. ★: MEP changes. Receiver-operating characteristic analysis for detecting MEP changes in proximal group



**Figure 2:** The histogram demonstrates safe time duration (*STD*) for temporary vessel occlusion in the trap group. The shaded column demonstrates average *STD*, representing the 95% confidence interval for the population mean calculated from sample data for *STD* in patients with motor-evoked potential (MEP) changes and *STD* in patients without changes. All patients in the trap group who developed MEP changes showed involvement of the anterior choroidal artery in the trapped segment. ★: MEP changes

factors such as the functionally maintained area, the area of salvageable functional failure (ischemic penumbra), and the area of permanent functional loss (ischemic core). The area of ischemic penumbra is designated to become part of the ischemic core if blood flow cannot be restored within a certain period of time.<sup>[7,19]</sup>

Temporary vessel occlusion that results in brain infarction and ischemic core should clearly be avoided. The ischemic penumbra is also known to not always be safe. For example, when we consider brain infarction in the acute stage, ischemic brain tissue develops postischemic hyperemia after reperfusion.<sup>[9]</sup> Postoperative hyperperfusion syndrome reportedly appears following aneurysm surgery using temporary vessel occlusion.<sup>[1,8]</sup> Temporary vessel occlusion, which creates the ischemic penumbra, can cause transient neurological deficit without developing postoperative brain infarction. This is often observed as hyperperfusion syndrome, which may create some degree of reperfusion injury. *STD* for temporary occlusion is thus defined as not exceeding the duration causing ischemic penumbra.

MEP is known to reflect function of the pyramidal tract and its change expresses functional disorder in the cerebral motor cortex as well as in the neuronal fibers comprising the pyramidal tract. MEP changes occurring due to temporary occlusion of the ICA tell us that dysfunction of the pyramidal tract is developing secondary to insufficient blood supply to cortical and/or perforating arteries supplying the pyramidal tract. Areas of ischemic penumbra can become areas of brain infarction if blood flow is not restored within a certain period of time. Actually, MEP changes lasting more than 10 min have been reported to be followed by postoperative motor deficit, supporting the present results.<sup>[18]</sup>

Postoperative motor paresis is one of the worst adverse events in aneurysm surgery. Although MEP monitoring only detects pyramidal tract dysfunction, the tract acquires high sensitivity to most kinds of potentially hazardous conditions in aneurysm surgery, including temporary vessel occlusion. Monitoring of somatosensory evoked potential (SEP) has been a standard and reliable monitoring method since before MEP monitoring became

available in the neurosurgical field.<sup>[11,15,17]</sup> Neuloh *et al.* demonstrated that the sensitivity of MEP monitoring for postoperative motor deficit is 0.91, whereas the sensitivity of SEP monitoring is 0.17, so impending ischemia may be detected and averted earlier when judgment is made based on MEP deterioration compared with use of SEP changes.<sup>[12]</sup> In addition, SEP monitoring is sometimes less sensitive to ischemia not only in the internal capsule, but also in the cortical motor area, and postoperative motor deficits can occur without changes being seen in SEP.<sup>[5,12,18]</sup>

When we apply the temporary clip for the ICA, tolerance to proximal occlusion is likely dependent on the patients' specific circle of Willis vascular anatomy. Although we understand the importance to examine for differences in the threshold relative to presence or absence of known collaterals, and location of proximal occlusion, it is difficult to accurately estimate collateral before the surgery in the clinical setting, especially at the time of emergent surgery. In this preliminary study, therefore, we have tried to simply estimate *STD* without taking such individual factors into account. The present study tried to investigate the safe duration of temporary vessel occlusion of the ICA as exactly as possible using MEP changes. Average *STD* gives an estimated range of values, which is likely to include an unknown population *STD* for temporary ICA occlusion. We can perform extremely safe temporary vessel occlusion of ICA within the 95% lower confidence limit of average *STD*, but in some cases we cannot perform dissection and clip application within this short duration in a clinical setting. Therefore we think it is reasonable that temporary vessel occlusion should be performed within not more than the 95% upper confidence limit of average *STD*, although MEP changes can occur beyond the lower limit in the trap group when the AchA was involved because all these patients developed MEP changes in this present study. We found that 4.6 min represents the 95% upper confidence limit of the average *STD* when temporary occlusion is applied on the proximal side of the ICA only. This time was shortened to 3.4 min when the ICA was trapped if the AchA was within the trapped segment, and increased to more than 5.5 min when the trapped segment did not involve the AchA.

The *STD* for temporary vessel occlusion presented here is shorter than measures reported in other studies.<sup>[3,10,13,14]</sup> The difference was attributed to monitoring modality and the philosophy underlying assessment. Previous studies have estimated safe occlusion times mainly based on the presence of postoperative brain infarction, neurological deficit, or SEP changes. Retrospective studies based on observation of aneurysm surgery in which temporary vessel occlusion was conducted revealed that the risk of cerebral infarction begins to increase when occlusion time exceeds approximately 20 min.<sup>[3,13]</sup> Mizoi *et al.*

found that the amplitude of SEP was lost approximately 9 min after temporary vessel occlusion. They claimed that the rate of postoperative neurological deficits was very low if recirculation was reestablished within 10 min after the disappearance of SEP.<sup>[10]</sup> We analyzed the confidence interval at the 95% level for the population mean calculated from sample data for *STD* in patients both with and without MEP changes to clarify the *STD* without any risk of falling into penumbra, that is, the average *STD*. This duration represents important baseline knowledge, because intraoperative MEP monitoring is not always available.

Average *STD* was extremely short in the trap group when the AchA was involved. Friedman *et al.* examined patients who developed postoperative stroke in the AchA territory, and found that the clinical syndrome is typified by contralateral hemiparesis. Perforating arteries from the AchA passing from the anterior perforating substance to the posterior limb of the inferior capsule are known to not receive any significant collateral supply.<sup>[4]</sup> Obstruction of the AchA thus easily causes immediate ischemic dysfunction in the pyramidal tract, and MEP monitoring is very helpful to detect blood flow insufficiency within the AchA.<sup>[16]</sup> When we trap the ICA while involving the AchA within the trapped segment, temporary vessel occlusion should be kept much shorter than on other occasions. Spurious, time threshold is actually longer in these patients with trapping without the AchA (5.5 min) than in proximal occlusion group (4.6 min). Although the difference can be significant and meaningful, this result may be reflected by the small number of patients.

All patients who underwent suction decompression developed MEP changes. In one patient, disappearance of MEP occurred within 1 min after trapping, representing an extremely short time compared with the usual manner of occlusion. Suction decompression is conducted to decrease pressure in the aneurysm by sucking blood from the trapped segment. Sucking blood lowers the perfusion pressure of collateral flow, so the artery within the trapped segment falls into stronger ischemia. The suction decompression method may thus carry a significant risk of shortening the *STD*, particularly when the AchA is included within the segment of temporary occlusion. For the same reason, temporary vessel occlusion to manage aneurysm rupture, which theoretically results in lower perfusion pressure, may carry a significant risk of shortening the *STD*, we could not verify that because of too small number of patients who received aneurysm rupture as well as temporary ICA occlusion in this present study.

We have found that, when we use MEP measures to detect the ischemic penumbra, safe-occlusion time for the ICA is shorter than previously proposed. This study showed limitations in the retrospective nature of the study, the small number of subjects, and the

single-centre design, and a larger patient population and further studies are needed to achieve more definitive values.

## CONCLUSIONS

Using intraoperative MEP measures, we examined the *STD* for temporary occlusion of the ICA where brain tissue exposed to ischemia, including the pyramidal tract, never falls into even the ischemic penumbra. The 95% upper confidence limit for the average *STD* is 4.6 min for ICA occluded proximal to the aneurysm, 3.4 min if ICA trapping involved the AchA and 5.5 min if trapping did not involve the AchA.

## ACKNOWLEDGMENTS

The authors thank Kimio Yoshioka for his invaluable support in the acquisition of intraoperative data.

## REFERENCES

1. Araki Y, Andoh H, Yamada M, Nakatani K, Andoh T, Sakai N. Permissible arterial occlusion time in aneurysm surgery: Postoperative hyperperfusion caused by temporary clipping. *Neurol Med Chir* 1999;39:901-6.
2. Batjer H, Samson D. Intraoperative aneurysmal rupture: Incidence, outcome, and suggestions for surgical management. *Neurosurgery* 1986;18:701-7.
3. Charbel FT, Ausman JI, Diaz FG, Malik GM, Dujovny M, Sanders J. Temporary clipping in aneurysm surgery: Technique and results. *Surg Neurol* 1991;36:83-90.
4. Friedman JAI, Pichelmann MA, Piepgras DG, Atkinson JL, Maher CO, Meyer FB, et al. Ischemic complications of surgery for anterior choroidal artery aneurysms. *J Neurosurg* 2001;94:565-72.
5. Horiuchi K, Suzuki K, Sasaki T, Matsumoto M, Sakuma J, Konno Y, et al. Intraoperative monitoring of blood flow insufficiency during surgery of middle cerebral artery aneurysms. *J Neurosurg* 2005;103:275-83.
6. Ishikawa T. What is the role of clipping surgery for ruptured cerebral aneurysms in the endovascular era? A review of recent technical advances and problems to be solved. *Neurol Med Chir* 2010;50:800-8.
7. Jones TH, Morawetz RB, Crowell RM, Marcoux FW, FitzGibbon SJ, DeGirolami U, et al. Thresholds of focal cerebral ischemia in awake monkeys. *J Neurosurg* 1981;54:773-82.
8. Kuroki K, Taguchi H, Yukawa O. Hyperperfusion syndrome after clipping of an unruptured aneurysm. Case report. *Neurol Med Chir* 2006;46:248-50.
9. Marchal G, Young AR, Baron JC. Early postischemic hyperperfusion: Pathophysiological insights from positron emission tomography. *J Cereb Blood Flow Metab* 1999;19:467-82.
10. Mizoi K, Yoshimoto T. Permissible temporary occlusion time in aneurysm surgery as evaluated by evoked potential monitoring. *Neurosurgery* 1993;33:434-40.
11. Momma F, Wang AD, Symon L. Effects of temporary arterial occlusion on somatosensory evoked responses in aneurysm surgery. *Surg Neurol* 1987;27:343-52.
12. Neuloh G, Schramm J. Monitoring of motor evoked potentials compared with somatosensory evoked potentials and microvascular Doppler ultrasonography in cerebral aneurysm surgery. *J Neurosurg* 2004;100:389-99.
13. Ogilvy CS, Carter BS, Kaplan S, Rich C, Crowell RM. Temporary vessel occlusion for aneurysm surgery: Risk factors for stroke in patients protected by induced hypothermia and hypertension and intravenous mannitol administration. *J Neurosurg* 1996;84:785-91.
14. Samson D, Batjer HH, Bowman G, Mootz L, Krippner WJ, Meyer YJ, et al. A clinical study of the parameters and effects of temporary arterial occlusion in the management of intracranial aneurysms. *Neurosurgery* 1994;34:22-8.
15. Schramm J, Koht A, Schmidt G, Pechstein U, Taniguchi M, Fahlbusch R. Surgical and electrophysiological observations during clipping of 134 aneurysms with evoked potential monitoring. *Neurosurgery* 1990;26:61-70.
16. Suzuki K, Kodama N, Sasaki T, Matsumoto M, Konno Y, Sakuma J, et al. Intraoperative monitoring of blood flow insufficiency in the anterior choroidal artery during aneurysm surgery. *J Neurosurg* 2003;98:507-14.
17. Symon L, Wang AD, Costa e Silva IE, Gentili F. Perioperative use of somatosensory evoked responses in aneurysm surgery. *J Neurosurg* 1984;60:269-75.
18. Szélenyi A, Langer D, Kothbauer K, De Camargo AB, Flamm ES, Deletis V. Monitoring of muscle motor evoked potentials during cerebral aneurysm surgery: Intraoperative changes and postoperative outcome. *J Neurosurg* 2006;105:675-81.
19. Taylor CL, Selman WR, Kiefer SP, Ratcheson RA. Temporary vessel occlusion during intracranial aneurysm repair. *Neurosurgery* 1996;39:893-905.