

# Pseudo-Foster Kennedy Syndrome as a Rare Presentation of Vitamin B12 Deficiency

Peyman Petramfar,<sup>1</sup> Farideh Hosseinzadeh,<sup>2</sup> and S. Saeed Mohammadi<sup>2,\*</sup>

<sup>1</sup>Department of Neurology, School of Medicine, Shiraz University of Medical Sciences, Shiraz, IR Iran

<sup>2</sup>Student Research Committee, Shiraz University of Medical Sciences, Shiraz, IR Iran

\*Corresponding author: S. Saeed Mohammadi, Student Research Committee, Shiraz University of Medical Sciences, Shiraz, IR Iran. Tel: +98-9364402630, Fax: +98-7733444844, E-mail: S.Saeed.Mohammadi@gmail.com

Received 2014 October 18; Revised 2015 March 30; Accepted 2015 April 18.

## Abstract

**Introduction:** Pseudo-Foster Kennedy syndrome is a triad consisting of ipsilateral optic atrophy, contralateral optic disc edema, and ipsilateral anosmia in the absence of an intracranial mass. Vitamin B12 plays an important role in DNA synthesis, and its deficiency causes peripheral neuropathy, myeloneuropathy, and, very rarely, optic neuropathy.

**Case Presentation:** In this study, we describe a 34-year-old male who presented with progressive loss of visual acuity and field. Fundoscopy showed optic disc edema with telangiectasia in the right eye, while the left eye had optic disc atrophy. We ruled out nearly all possible and common causes of optic neuropathy, and vitamin B12 deficiency was finally diagnosed. After treatment with vitamin B12, the patient improved.

**Conclusions:** Demyelinating disease, anterior ischemic optic neuropathy, non-arteritic anterior ischemic optic neuropathy, autoimmune disease, and hereditary optic neuropathy could cause optic neuropathy. Normal CBC parameters and the absence of clinical manifestations of vitamin B12 deficiency could not rule out its diagnosis. Careful physical examinations and history-taking with a classical approach led us to the diagnosis of vitamin B12 deficiency and its treatment.

**Keywords:** Vitamin B12 Deficiency, Optic Nerve Disease, Foster-Kennedy Syndrome, Optic Neuropathy, Papilledema, Optic Neuritis

## 1. Introduction

Foster Kennedy described a triad of signs, consisting of ipsilateral optic atrophy, contralateral optic disc edema, and ipsilateral anosmia, as characteristic of a space-occupying lesion in the basofrontal area on the side of optic atrophy (1, 2). These findings, in the absence of an intracranial mass, are known as pseudo-Foster Kennedy syndrome. Several non-tumor causes of ipsilateral disc pallor and contralateral disc edema have been reported, including anterior ischemic optic neuropathy, which is the most common cause (3), occult trauma, optic neuritis, syphilis, and severe arteriosclerosis of the internal carotid arteries (4, 5). Vitamin B12 plays a significant role in the synthesis of DNA and in neurological function. B12 deficiency leads to the failure of myelin basic protein methylation, resulting in myelin injury (6). Vitamin B12 deficiency has been shown to be related to myeloneuropathy and peripheral neuropathy, and is rarely associated with optic neuropathy and weakness in the lower extremities (7). In this study, we report a case of vitamin B12 deficiency, presenting as pseudo-Foster Kennedy syndrome.

## 2. Case Presentation

The patient, a single 34-year-old man in reported good health, was referred with progressive and painless decreased vision in the left eye over the previous one month. He was evaluated by a neurologist, and bedside fundoscopy was performed that showed swelling of the left optic disc. Visual evoked potential (VEP) and brain and cervical magnetic resonance imaging (MRI) with and without gadolinium were performed to check for signs of multiple sclerosis. VEP showed absence of the P100 wave in the left eye and a normal P100 wave in the right eye, which indicated optic neuritis. Treatment for optic neuritis was initiated despite a normal MRI. The patient received 6.5 grams of methylprednisolone intravenously, but no response was observed.

Some days later, the patient developed progressively decreased vision in the right eye, which involved the lower half of the visual field, so he was referred to our department for further evaluation. The patient had no history of Lhermitte's sign, Uhthoff's phenomenon, or collagen vascular disease signs and symptoms, such as oral aphthous ulcer, genital ulcer, photosensitivity, joint swelling, or arthralgia. The patient noted that he had a history of smok-

ing crystal methamphetamine until 4 - 5 years prior to his admission, but stopped using at that time. There was no history of similar or significant diseases in his family. The patient's vital signs and head, ear, nose, throat, chest, heart, abdominal, and neurological exams were all normal, except for visual acuity. In the left eye, visual acuity was a 3-meter finger-count with a general reduction of sensitivity, and a Marcus Gunn pupil was noted. In the right eye, visual acuity was a 6-meter finger-count, with reduced sensitivity in the inferior visual field. Bedside funduscopy showed optic disc edema with telangiectasia in the right eye, while the left eye had optic disc atrophy (Figure 1).

Perimetry was performed, which confirmed the physical examination findings (Figure 2).

The laboratory data were in the near-normal ranges (Table 1).

**Table 1.** Initial Laboratory Results

Results	Patient	Normal
<b>Chemistry</b>		
BUN, mg/dL	17	6 - 23
Creatinine, mg/dL	1.0	0.7 - 1.4
ESR, mm/h	12	0 - 15
<b>Hematology</b>		
WBC, $10^3/\mu\text{L}$	6.48	4.8 - 10.8
RBC, $10^6/\mu\text{L}$	5.55	4.5 - 6.5
HCT, %	45.1	40 - 54
MCV, fl	81.3	81 - 98
MCH, pg	25.9	27 - 32
MCHC, g/dL	31.9	32 - 36
RDW, fl	15.4	10.8 - 14.9
HGB, g/dL	14.4	13.5 - 18.0
Platelets, $10^3/\mu\text{L}$	328	150 - 450
<b>CSF Analysis</b>		
LDH, u/L	25	20 - 72
Protein, mg/dL	35	15 - 60
Sugar, mg/dL	67	50 - 80

Cerebrospinal fluid (CSF) analysis was normal, with an opening pressure of 18 cm H<sub>2</sub>O and no oligoclonal band detected. Transesophageal echocardiography and color Doppler sonography of the carotid and vertebral arteries were performed for evaluation of embolic sources and atherosclerotic changes, and the results were normal. The patient's homocysteine level was also checked, and was 7.0  $\mu\text{mol/L}$  (reference range: 5 - 15  $\mu\text{mol/L}$ ). HIV antibody was checked with the ELISA method, and was negative. Brain

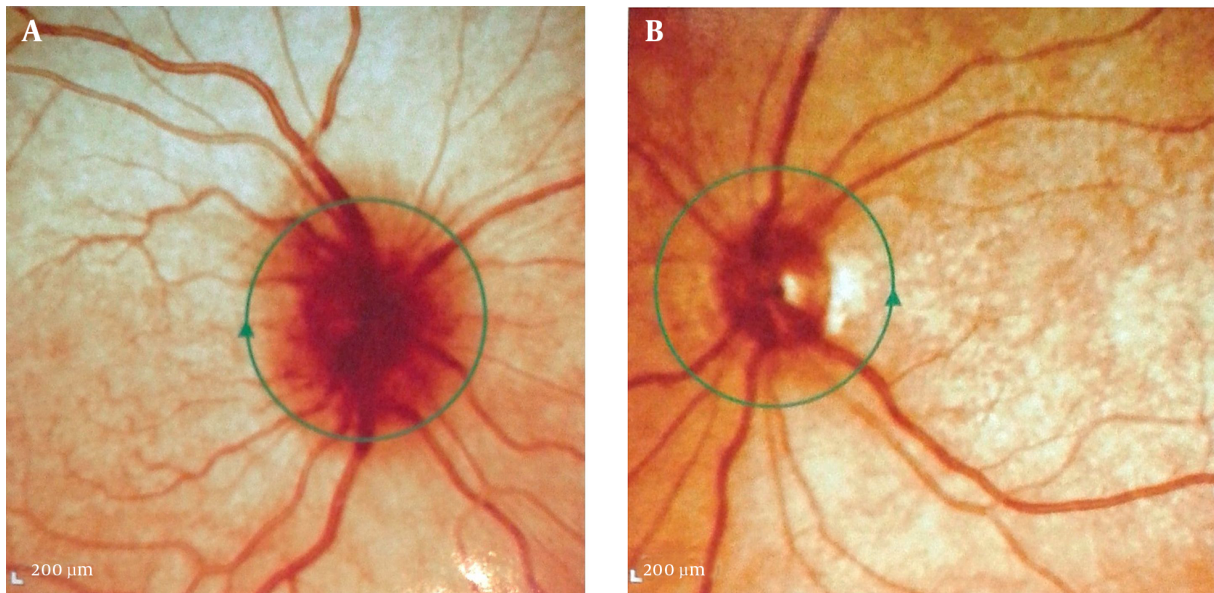
and cervical MRI with and without gadolinium was repeated, with normal findings and no signs of multiple sclerosis plaques or space-occupying lesions. Another probable cause for the patient's condition was vasculitis-induced optic neuritis, so antinuclear antibody (ANA), anti-double-stranded DNA antibody (anti-dsDNA), perinuclear anti-neutrophil cytoplasmic antibody (P-ANCA), cytoplasmic anti-neutrophil cytoplasmic antibody (C-ANCA), and anti-cardiolipin antibody were checked, and were all within normal range. Fluorescein angiography was performed by an ophthalmologist, which ruled out Leber's hereditary optic neuropathy (LHON). The patient lost his eyesight in the course of his hospital stay and became nearly blind, so we began our search for nutritional deficiencies that could cause pseudo-Foster Kennedy syndrome. The patient's folate level was 14.5 ng/mL (normal range: 3.1 - 17.5 ng/mL), but vitamin B12 was 200 pg/mL (reference range: 243 - 894 pg/mL). A peripheral blood smear was assessed by a pathologist and showed hypersegmented neutrophils. Vitamin B12 deficiency was diagnosed, and intramuscular vitamin B12 was administered. The day after starting treatment with vitamin B12, the progression of loss of vision stopped, and over the next several days it regressed. The patient's visual field was improved on physical examination, and for confirmation of the examination, another perimetry was done. This showed improvement of the visual field in both eyes (Figure 3).

The patient's visual acuity was improved to a 6-meter finger-count in both eyes, and funduscopy showed sharp optic discs bilaterally. The patient was followed, and he experienced neither recurrence of visual loss nor further improvement.

### 3. Discussion

Progressive blurred vision in this young man, followed by swelling and atrophy in the optic disc with normal CSF pressure and imaging, led to a diagnosis of pseudo-Foster Kennedy syndrome. Various problems can cause optic neuropathy, such as demyelination, ischemia, and hereditary and nutritional causes. Careful history-taking, physical examination, and clinical evaluation are necessary to rule out a diagnosis of optic neuropathy.

Anterior ischemic optic neuropathy (AION) is categorized into two subtypes: arteritic and non-arteritic (NAION). Patients with NAION are typically older males with systemic vascular risk factors, such as smoking and diabetes, which may cause severe edema and hemorrhage of optic discs as seen on funduscopy (8). However, NAION can occur in young patients without any of those risk factors. Hyperhomocysteinemia has been associated with NAION



**Figure 1.** A, Optic disc edema with telangiectasia in the right eye and; B, optic disc atrophy in the left eye.

in patients who lack routine risk factors for ischemic optic neuropathy (9).

A wide range of autoimmune and infectious diseases can involve the optic nerve, including sarcoidosis, systemic lupus erythematosus, Sjogren's syndrome, Wegener's granulomatosis, and syphilis (10). Autoimmune markers, such as ANA and anti-cardiolipin antibodies, are usually positive in autoimmune optic neuropathy. This is a recurrent condition that responds well to systemic corticosteroids (11).

Early diagnosis of optic neuritis should be considered, as this can be one of the first symptoms of multiple sclerosis (12). Cervical and brain MRI should be done in order to identify the white matter plaques of multiple sclerosis. In about 90% of cases, optic neuritis regresses over time to near-normal visual acuity, and administration of intravenous corticosteroids only accelerates the speed of recovery from the disease, without changing the outcome (8).

Gradual and progressive loss of vision is a hallmark of compressive optic neuropathy, the most common causes of which are meningioma, pituitary adenoma, intracranial aneurysm, and glioma. However, rarely, visual loss with compressive optic neuropathy can be prompted in situations such as a ruptured aneurysm (13).

The hereditary optic neuropathies are a group of diseases in which optic nerve dysfunction can be isolated or can be associated with other neurological dysfunctions. These diseases could be inherited autosomally or via the mitochondrial genome. Patients with dominant optic neu-

ropathy (Kjer type) usually present with symptoms in the first few years of life, with central or cecentral scotomas. The visual loss in these cases is symmetric and bilateral. The classical presentation of LHON is acute, unilateral, painless visual loss with central or cecentral scotomas (14). Weeks or months after involvement of the first eye, the other eye can become involved (15). Fundoscopy in patients with LHON shows telangiectasia in the peripapillary retinal vessels without leaks on fluorescein angiography, and disc-swelling with peripapillary retinal nerve thickening. Because optic disc pallor is an initial sign of LHON, misdiagnosis is common, especially in younger patients diagnosed with optic neuritis and older patients diagnosed with ischemic optic neuropathy. Therefore, careful history-taking, physical examination, and high suspicion are critical for the diagnosis of this disease (16).

Toxic chemicals, drugs, and nutritional deficiencies can affect the optic nerve and cause maculopapillary bundle damage, as mentioned above with regard to LHON, with central and cecentral scotomas in the patient's visual field. Ethambutol, amiodarone, methanol, methotrexate, cyclosporine, vincristine, cisplatin, ethanol, and tobacco can cause toxic optic neuropathy. In addition to these factors, some nutritional deficiencies, such as in thiamine (B1), riboflavin (B2), folate, B12, and B6, can make the patient susceptible to optic neuropathy (17).

The diagnosis and management of vitamin B12-deficient optic neuropathy, a rare entity that has been reported mainly in patients with a history of gastrointesti-



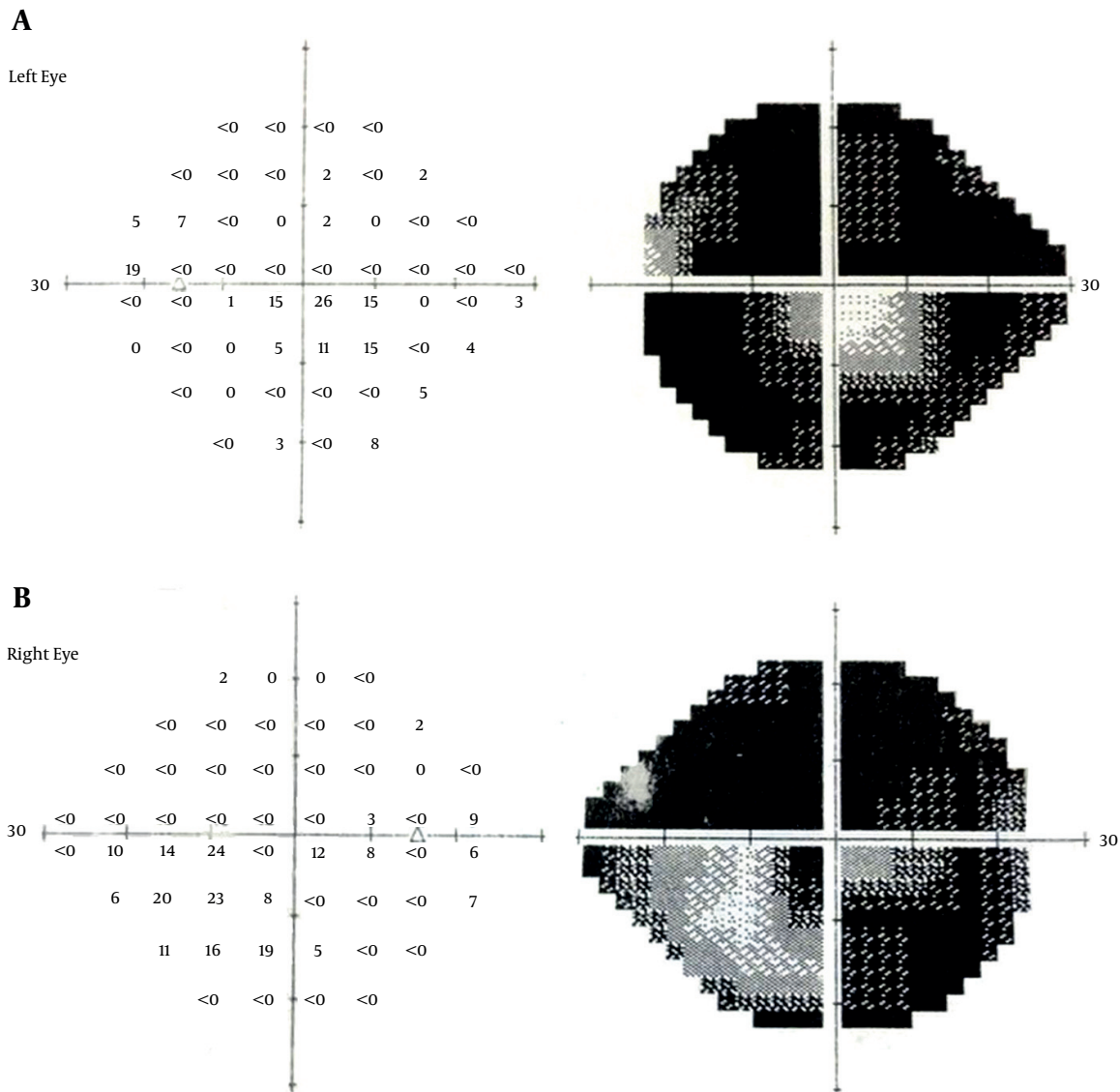


Figure 3. Improvement of Both Eyes' Visual Fields After Treatment

deficiency (20).

In patients suspected to have nutritional deficiencies, MRI of the optic nerves and chiasm is indicated to rule out other important conditions. The visual field should be carefully evaluated, as central or cecocentral scotomas with intact peripheral fields are pathognomonic visual-field defects that can occur with nutritional deficiencies (21). Optic neuropathies caused by nutritional deficiencies, especially vitamin B12 deficiency, are rare but reversible in the early stages. Therefore, patients with unusual patterns of visual loss, or with usual patterns but who are not re-

sponsive to the usual therapies, should undergo investigations to find nutritional causes. However, further studies are needed to establish this approach as a routine guideline in the evaluation of optic neuropathies.

Vitamin B12 deficiency can present with visual disturbances, which demonstrates the possibility of vitamin B12-deficient optic neuropathy even with normal CBC and no other explicit clinical manifestations. Vitamin B12-deficient optic neuropathy has a good prognosis if treatment is started within a few months of the initiation of symptoms. Color vision recovers after visual acuity does,

and recurrences are rare after the recovery from symptoms is complete. Our patient presented with an unusual manifestation of vitamin B12 deficiency, but careful physical examination and history-taking with a classical approach led us to the exact diagnosis and appropriate treatment.

## Acknowledgments

We would like to express our special appreciation and thanks to Dr. Nasrin Shokrpour for improving the use of English in the manuscript.

## Footnote

**Authors' Contribution:** Study concept and design: Peyman Petramfar, S. Saeed Mohammadi, Farideh Hosseinzadeh; acquisition of data: S. Saeed Mohammadi; analysis and interpretation of data: Peyman Petramfar, and S. Saeed Mohammadi; drafting of the manuscript: S. Saeed Mohammadi, Farideh Hosseinzadeh; critical revision of the manuscript for important intellectual content: Peyman Petramfar, S. Saeed Mohammadi; study supervision: Peyman Petramfar.

## References

- Kennedy F. Retrobulbar neuritis as an exact diagnostic sign of certain tumors and abscesses in the frontal lobes. *Am. J. Med. Sci.* 1911;**142**(3):355-68.
- Kennedy F. A further note on the diagnostic value of retrobulbar neuritis in expanding lesions of the frontal lobes: with a report of this syndrome in a case of aneurysm of the right internal carotid artery. *J. Am. Med. Assoc.* 1916;**67**(19):1361-3.
- Gelwan MJ, Seidman M, Kupersmith MJ. Pseudo-pseudo-Foster Kennedy syndrome. *J Clin Neuroophthalmol.* 1988;**8**(1):49-52. [PubMed: 2972751].
- Watnick RL, Trobe JD. Bilateral optic nerve compression as a mechanism for the Foster Kennedy syndrome. *Ophthalmology.* 1989;**96**(12):1793-8. [PubMed: 2560156].
- Schatz NJ, Smith JL. Non-tumor causes of the Foster Kennedy syndrome. *J Neurosurg.* 1967;**27**(1):37-44. doi: 10.3171/jns.1967.27.1.0037. [PubMed: 6028867].
- Weir DG, Scott JM. Brain function in the elderly: role of vitamin B12 and folate. *Br Med Bull.* 1999;**55**(3):669-82. [PubMed: 10746355].
- Saperstein DS, Barohn R. Peripheral neuropathy due to cobalamin deficiency. *Curr Treat Options Neurol.* 2002;**4**(3):197-201. doi: 10.1007/s11940-002-0036-y.
- Beck RW. The optic neuritis treatment trial: three-year follow-up results. *Arch Ophthalmol.* 1995;**113**(2):136-7. [PubMed: 7864737].
- Pianka P, Almog Y, Man O, Goldstein M, Sela BA, Loewenstein A. Hyperhomocystinemia in patients with nonarteritic anterior ischemic optic neuropathy, central retinal artery occlusion, and central retinal vein occlusion. *Ophthalmology.* 2000;**107**(8):1588-92. [PubMed: 10919914].
- Petzold A, Plant GT. Diagnosis and classification of autoimmune optic neuropathy. *Autoimmun Rev.* 2014;**13**(4-5):539-45. doi: 10.1016/j.autrev.2014.01.009. [PubMed: 24424177].
- Frohman L, Turbin R, Bielory L, Wolansky L, Lambert WC, Cook S. Autoimmune optic neuropathy with anticardiolipin antibody mimicking multiple sclerosis in a child. *Am J Ophthalmol.* 2003;**136**(2):358-60. [PubMed: 12888064].
- Beck RW, Trobe JD, Moke PS, Gal RL, Xing D, Bhatti MT, et al. High- and low-risk profiles for the development of multiple sclerosis within 10 years after optic neuritis: experience of the optic neuritis treatment trial. *Arch Ophthalmol.* 2003;**121**(7):944-9. doi: 10.1001/archophth.121.7.944. [PubMed: 12860795].
- Bulters DO, Shenouda E, Evans BT, Mathad N, Lang DA. Visual recovery following optic nerve decompression for chronic compressive neuropathy. *Acta Neurochir (Wien).* 2009;**151**(4):325-34. doi: 10.1007/s00701-009-0192-x. [PubMed: 19255716].
- Kerrison JB. Latent, acute, and chronic Leber's hereditary optic neuropathy. *Ophthalmology.* 2005;**112**(1):1-2. doi: 10.1016/j.ophtha.2004.10.021. [PubMed: 15629812].
- Barboni P, Savini G, Valentino ML, Montagna P, Cortelli P, De Negri AM, et al. Retinal nerve fiber layer evaluation by optical coherence tomography in Leber's hereditary optic neuropathy. *Ophthalmology.* 2005;**112**(1):120-6. doi: 10.1016/j.ophtha.2004.06.034. [PubMed: 15629831].
- Newman NJ. Leber hereditary optic neuropathy: some new observations. *J Neuroophthalmol.* 2011;**31**(1):3-5. doi: 10.1097/WNO.0b013e31820c511d. [PubMed: 21317730].
- Hsu CT, Miller NR, Wray ML. Optic neuropathy from folic acid deficiency without alcohol abuse. *Ophthalmologica.* 2002;**216**(1):65-7. doi: 10.1159/000048300. [PubMed: 11901292].
- Grzybowski A. Problems related to the diagnosis of vitamin B12 deficiency optic neuropathy. *Acta Ophthalmol.* 2014;**92**(1):e74-5. doi: 10.1111/aos.12195. [PubMed: 23826888].
- Scalabrino G. The multi-faceted basis of vitamin B12 (cobalamin) neurotrophism in adult central nervous system: Lessons learned from its deficiency. *Prog Neurobiol.* 2009;**88**(3):203-20. doi: 10.1016/j.pneurobio.2009.04.004. [PubMed: 19394404].
- Larner AJ. Visual failure caused by vitamin B12 deficiency optic neuropathy. *Int J Clin Pract.* 2004;**58**(10):977-8. [PubMed: 15587778].
- Nicholls P. Formate as an inhibitor of cytochrome c oxidase. *Biochem Biophys Res Commun.* 1975;**67**(2):610-6. [PubMed: 1020].