

# Adult Intussusception Secondary to Inflammatory Fibroid Polyp

Nobuhiko Kimura, MD

Michael Hight, DO

James Liang, DO

Ronald Willy, MD

Kimberly Liang, PharmD

Jacob Camp, DO

Naval Hospital Okinawa, Emergency Department, Okinawa, Japan

Section Editor: Sean O. Henderson, MD

Submission history: Submitted April 19, 2015; Accepted April 25, 2015

Electronically published June 23, 2015

Full text available through open access at [http://escholarship.org/uc/uciem\\_westjem](http://escholarship.org/uc/uciem_westjem)

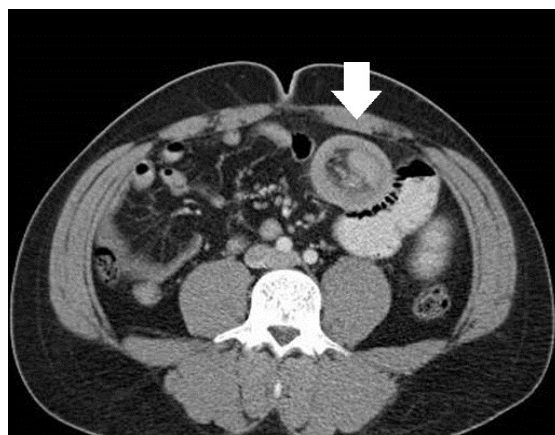
DOI: 10.5811/westjem.2015.4.26399

[West J Emerg Med. 2015;16(4):581–582.]

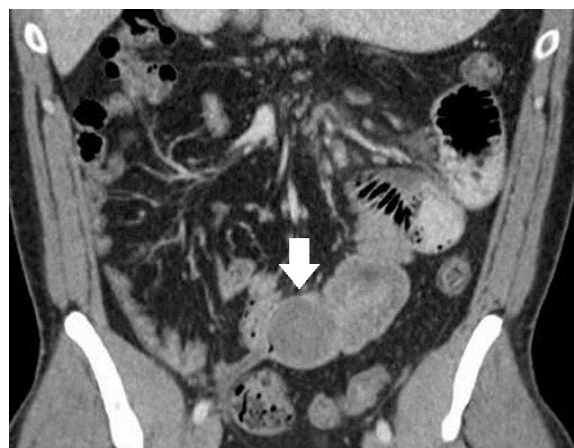A 30-year-old man presented to the emergency department for two weeks of diffuse abdominal pain and an episode of emesis. He denied fever, prior surgery, or any other illnesses. The patient reported going on a “crash diet regimen” one month prior, resulting in an intentional weight loss of 25lbs in 30 days. He also reported two episodes of melena-type bowel movements prior and had an esophagogastroduodenoscopy eight days earlier, which was noted to be normal. On physical examination he was mildly ill-appearing with diffuse abdominal tenderness without peritoneal signs. Computed tomography of his abdomen and pelvis showed a small bowel obstruction in the jejunum. A diagnostic laparoscopy was performed. Operative findings revealed 2.5cm lesion at distal portion of thickened small bowel and intussusception 10-12cm proximal to this. He underwent laparotomy with small bowel resection. Pathological examination of the specimen revealed a 4.0cm inflammatory fibroid polyp.

Intussusception is rare in adults, accounting for 5% of all cases of intussusceptions and 5% of bowel obstructions in adults (Figure 1 and Figure 2).<sup>1</sup> Approximately 90% of cases of intussusception in adults are secondary to a pathologic condition that serves as a lead point for the intussusception, such as carcinomas, polyps, or Meckel's diverticulum, etc.<sup>2</sup>

Inflammatory fibroid polyps (IFPs) are rare, benign tumors that can arise throughout the gastrointestinal tract.<sup>3</sup> The most common site is the gastric antrum (66-75%), followed by the small bowel (18-20%) and colorectal region (4-7%).<sup>4</sup> Gastric and colon IFPs are typically identified incidentally, whereas small intestinal lesions can present with chronic abdominal pain, lower gastrointestinal bleeding, anemia and rarely small bowel obstruction due to intussusception.<sup>5</sup> Although IFPs are rare and benign conditions, surgery is the only solution in case of bowel obstruction.<sup>4</sup> The patient's postoperative course was



**Figure 1.** Axial image-donut sign (arrow) indicative of intussusception: fat, vessels and a segment of small bowel (the intussusceptum) prolapsed into the lumen of another segment of small bowel (the intussuscipiens, the outer ring or donut).



**Figure 2.** Coronal image: 4cm benign inflammatory polyp (arrow) at the distal intussusceptum, the lesion that served as the lead point for the intussusception.

unremarkable, and he was discharged on postoperative day 4.

---

*Address for Correspondence:* Nobuhiko Kimura, MD, United States Naval Hospital Okinawa, Department of Emergency Medicine, PSC 482 FPO AP 96362-1600. Email: dr.kimura84@gmail.com.

*Conflicts of Interest:* By the *WestJEM* article submission agreement, all authors are required to disclose all affiliations, funding sources and financial or management relationships that could be perceived as potential sources of bias. The authors disclosed none.

*Copyright:* © 2015 Kimura et al. This is an open access article distributed in accordance with the terms of the Creative Commons Attribution ([CC BY 4.0](http://creativecommons.org/licenses/by/4.0/)) License. See: <http://creativecommons.org/licenses/by/4.0/>

---

## REFERENCES

1. Wang N, Cui XY, Liu Y, et al. Adult intussusception: a retrospective review of 41 cases. *World J Gastroenterol.* 2009;15(26):3303-8.
2. Marinis A, Yiallourou A, Samanides L, et al. Intussusception of the bowel in adults: a review. *World J Gastroenterol.* 2009;15(4):407-11.
3. Liu TC, Lin MT, Montgomery EA, et al. Inflammatory fibroid polyps of the gastrointestinal tract: spectrum of clinical, morphologic, and immunohistochemistry features. *Am J Surg Pathol.* 2013;37(4):586-92.
4. Akbulut S. Intussusception due to inflammatory fibroid polyp: a case report and comprehensive literature review. *World J Gastroenterol.* 2012;18(40):5745-52.
5. Jacobs TM, Lambrianides AL. Inflammatory fibroid polyp presenting as intussusception. *J Surg Case Rep.* 2013;2013(2).pii:rjt005.