

<b>Access this article online</b>
Quick Response Code:

Website: www.e-tjo.org
DOI: 10.4103/tjo.tjo_59_21

# Subcutaneous tocilizumab for active thyroid eye disease refractory to orbital radiation and systemic steroids in tobacco smokers

Shanlee M. Stevens, Nathan Pirakitikulr, Bradford W. Lee\*

## Abstract:

**PURPOSE:** Tocilizumab (TCZ) through intravenous infusion has been shown to effectively treat active thyroid eye disease (TED) refractory to systemic steroids. TCZ is also available as a self-administered subcutaneous injection, but data demonstrating the efficacy of this formulation are limited. This study investigated the efficacy and safety of subcutaneous TCZ (SC-TCZ) for the treatment of active, moderate-to-severe TED in smokers.

**MATERIALS AND METHODS:** This retrospective clinical case series evaluated the clinical outcomes and adverse effects of SC-TCZ when taken for a minimum of 4 months by patients with moderate-to-severe TED and a current or recent history of cigarette smoking.

**RESULTS:** Three patients received SC-TCZ every 1-2 weeks (4.6-11.2 mg/kg/month). The average pre-to-posttreatment clinical activity score reduction was 5.4, and proptosis was reduced by an average of 2.0 mm. No serious adverse effects were reported.

**CONCLUSION:** SC-TCZ may be a useful and effective therapy for treating challenging cases of inflammatory TED and offers a safe alternative to office or hospital-based infusions. Further studies are needed to better understand optimal dosing regimens and relative efficacy compared to monthly TCZ infusions and other immunotherapies.

## Keywords:

Anti-interleukin-6, thyroid-associated orbitopathy, thyroid eye disease, tobacco, tocilizumab

## Introduction

Systemic corticosteroids and orbital radiation are regarded as mainstay primary treatments for active, inflammatory thyroid eye disease (TED). Early control of inflammation has been demonstrated to reduce disease morbidity and, in some cases, mitigate the stereotypic orbital soft tissue changes associated with TED.<sup>[1]</sup> However, there are cases where patients have persistent inflammation or develop recurrent inflammation following a course of steroids, orbital radiation, and even combination therapy. In particular, exposure

to tobacco smoke is a well-recognized risk factor for prolonged inflammatory activity, more severe disease, and resistance to corticosteroids.<sup>[2]</sup> Among TED patients who smoke, normalization of autoantibodies is delayed on average by 1 year despite treatment with steroids.<sup>[3]</sup>

Immunomodulatory drugs have been used to treat cases of inflammatory TED, oftentimes in corticosteroid resistant cases or when steroids are contraindicated. Numerous agents have been tried as monotherapy and as adjunctive treatment with steroids including azathioprine, methotrexate, rituximab, adalimumab, tocilizumab (TCZ), and teprotumumab.<sup>[4-7]</sup>

This is an open access journal, and articles are distributed under the terms of the Creative Commons Attribution-NonCommercial-ShareAlike 4.0 License, which allows others to remix, tweak, and build upon the work non-commercially, as long as appropriate credit is given and the new creations are licensed under the identical terms.

For reprints contact: WKHLRPMedknow\_reprints@wolterskluwer.com

**How to cite this article:** Stevens SM, Pirakitikulr N, Lee BW. Subcutaneous tocilizumab for active thyroid eye disease refractory to orbital radiation and systemic steroids in tobacco smokers. Taiwan J Ophthalmol 2022;12:39-43.

Department of  
Ophthalmology, Division  
of Oculofacial Plastic and  
Reconstructive Surgery,  
Bascom Palmer Eye  
Institute, University of  
Miami Miller School of  
Medicine, Miami, FL, USA

## \*Address for correspondence:

Dr. Bradford W. Lee,  
Department of  
Ophthalmology, Division  
of Oculofacial Plastic and  
Reconstructive Surgery,  
Bascom Palmer Eye  
Institute, University of  
Miami Miller School of  
Medicine, Miami, FL, USA.  
E-mail: blee@med.miami.  
edu

Submission: 14-12-2021  
Accepted: 30-12-2021  
Published: 28-02-2022

TCZ, a humanized monoclonal anti-interleukin-6 receptor antibody, is one agent currently being used worldwide to treat active TED with excellent results.<sup>[4,5,8]</sup> TCZ has a well-established safety profile and has been approved for a range of autoimmune conditions, including systemic juvenile idiopathic arthritis, polyarticular juvenile idiopathic arthritis, giant cell arteritis, and CAR T-cell-induced cytokine release syndrome.<sup>[9]</sup> TCZ is available as an intravenous (IV) infusion (8 mg/kg)<sup>[4]</sup> or subcutaneous injection (162-mg SC q2 weeks × 4).<sup>[5,8]</sup> These studies have demonstrated that TCZ can effectively reduce TED activity as measured by clinical activity score (CAS) in TED refractory to steroids. However, the range of dosing and duration of TCZ therapy viable for treating TED have not been explored.

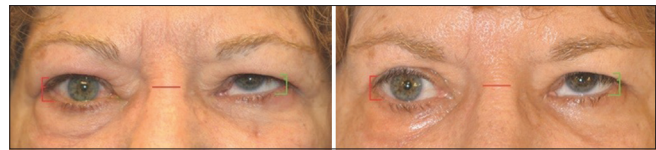
## Materials and Methods

This retrospective case series included three patients with significant smoking history who were treated with subcutaneous TCZ (SC-TCZ) for active TED refractory to orbital radiation and systemic steroids. Unlike prior studies, variable TCZ dosing strategies were used. Patients were followed between 14 and 27 months. Data including pre- and posttreatment CAS, proptosis reduction, and self-reported subjective change in quality of life were extracted from patient charts. The study was performed in compliance with the Health Insurance Portability and Accountability Act of 1996 and adhered to the ethical principles for medical research involving human subjects outlined in the Declaration of Helsinki of 2013. Institutional Review Board approval was waived owing to the small study size.

## Results

### Case 1

A 64-year-old Caucasian female, active smoker with a 28-pack-year smoking history presented with a 2-year history of active inflammatory euthyroid TED, thyroid-stimulating immunoglobulin (TSI) of 2790 (range: 0–139), and a thyroid-stimulating hormone of 0.191 mIU/L. Prior treatments included high-dose oral corticosteroids, thyroidectomy, orbital radiation (20 Gy), and weekly IV methylprednisolone infusions for 4 months. Despite this, the patient had persistent left orbital inflammation and developed new right orbital inflammation while on treatment. On presentation, she appeared proptotic bilaterally with measurements of 24 on the right and 23 on the left by Naugle exophthalmometry. A new compressive optic neuropathy was noted with a newly documented relative afferent pupillary defect (RAPD), and a decrease in color vision measured by Ishihara plates in the left eye was observed. The patient underwent a left three-wall orbital decompression for progressive left



**Figure 1:** These photos show case 1 before (left) and after (right) treatment with subcutaneous tocilizumab 162 mg per week (11.2 mg/kg/month) for 4 months. The photographs demonstrate a reduction in eyelid edema and erythema, conjunctival injection and caruncular edema, and a reduction in left hypertropia. A 2-mm reduction in proptosis OD was measured by Naugle exophthalmometry. The patient is fixating with the right eye; red lines denote position of the right corneal light reflex and green lines denote position of the left corneal light reflex

compressive optic neuropathy. A global CAS of 6 and a TSI of 676 were measured. She was then treated with SC-TCZ 162 mg weekly injections (11.2 mg/kg/month) for 4 months with a reduction overall of CAS to 1, reduction of TSI level to 76, improvement of ocular alignment, and 2 mm of proptosis reduction OD as measured by Naugle exophthalmometry [Figure 1]. The patient subsequently underwent a right lateral wall decompression while continuing SC-TCZ for residual proptosis and hypotropia. Pupil examination and color vision were normal at the time. Three months later, the patient was off SC-TCZ treatment and underwent left strabismus surgery. One month after postoperatively, the patient developed a mild reactivation of orbital inflammation with a global CAS of 4 and was thus treated with a lower dose of SC-TCZ 162 mg injections every 2 weeks (5.6 mg/kg/month) for 4 months with complete resolution of inflammation. The patient reported fatigue and malaise after each injection; however, no laboratory abnormalities, infections, or other adverse effects were noted during her subsequent treatments. The patient was evaluated 1 month after completing SC-TCZ therapy without recurrence of inflammation.

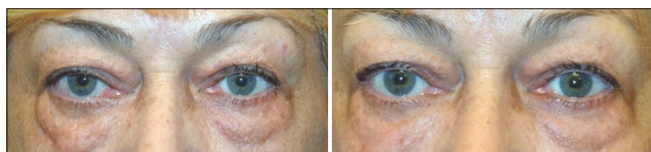
### Case 2

A 49-year-old Hispanic female, active smoker with a 30-pack-year smoking history presented with a distant history of TED following radioactive iodine (RAI) treatment that was previously treated with a bilateral two-wall decompression and oral steroids. After several years of disease stability, she presented with a severe reactivation of TED in the setting of hypothyroidism due to poor adherence with thyroid hormone replacement therapy. The patient presented with bilateral proptosis, chemosis, caruncular edema, and progressive vision loss in the left eye with a left RAPD. Visual acuity was 20/20 in the right and 20/100 in the left. The patient was started on high-dose oral prednisone and underwent an urgent left three-wall orbital decompression including an apical decompression that was not previously performed. The patient tapered off of steroids due to adverse effects but developed recurrent eyelid edema, chemosis, caruncular edema bilaterally, and new vision loss now in the right eye. CAS was 9, and vision had deteriorated from 20/20 to 20/70 with a loss of 12/14 Ishihara plates (previously

full). She was simultaneously treated with SC-TCZ 162 mg injections weekly (8.8 mg/kg/month), a short course of oral prednisone (40 mg daily tapered over several weeks), and adjuvant orbital radiation (20 Gy) followed by a revisional right three-wall orbital decompression. After completing this combination therapy including 4 months of SC-TCZ, CAS was 1. Although color vision had not improved, her visual acuity returned to baseline after treatment. No adverse events were noted while on treatment.

### Case 3

A 62-year-old Caucasian female, active smoker with a 40-pack-year smoking history presented with active TED and a history of RAI treatment in the past. The patient was treated with weekly IV steroid infusions for 4 months, orbital radiation (20 Gy), and peribulbar steroid injections but had persistent inflammatory signs with a CAS of 5 and an elevated TSI of 451. SC-TCZ 162 mg injection every other week (4.6 mg/kg/month) was added to her treatment regimen for 4 months, but due to residual inflammation with a CAS of 4 and a 2 mm increase in proptosis bilaterally, the treatment dose was increased to SC-TCZ 162 mg injections every week (9.2 mg/kg/month). After 2 months of treatment at this higher dose, CAS was reduced to 2 and proptosis improved by mm on each side measured by Naugle exophthalmometry [Figure 2]. During the course of treatment, the patient developed a rise in LDL cholesterol



**Figure 2:** These photos show case 3 before (left) and after (right) treatment with subcutaneous tocilizumab 162 mg every 2 weeks (4.6 mg/kg/month) for 4 months followed by 162 mg per week (9.2 mg/kg/month) for 2 months. The photographs demonstrate a reduction in conjunctival injection and caruncular edema. A 2-mm reduction in proptosis OU was also measured by Naugle exophthalmometry

and triglycerides which were controlled by starting rosuvastatin. No other adverse effects were noted.

## Conclusion

This series examines the use of SC-TCZ for TED specifically in smokers and uses a range of dosing regimens. The three patients described were middle-aged females with a significant smoking history and persistent, active TED despite orbital radiation and systemic steroids [Table 1]. At presentation, all had markedly elevated TSI levels and CAS scores ranging from 5 to 9. All patients self-administered SC-TCZ injections either weekly or every other week (ranging from 4.6 to 11.2 mg/kg/month) and had positive responses as indicated by reduction in CAS and decrease in proptosis.

Dosing was decided by the clinician (BL) based on patient weight, initial disease severity, and response to treatment as judged by interval clinical examination. Case 1 and case 2 were started on a weekly dosing regimen due to severe disease and the presence of optic neuropathy. Case 3 was started on biweekly dosing that was later increased to weekly due to inadequate control of inflammation. All patients were treated for a minimum of 4 months, similar to the treatment duration used in the TCZ-IV clinical trial by Perez-Moreiras *et al.*<sup>[4]</sup> One patient was successfully retreated for recurrence of disease activity following the initial treatment course. Treatment was maintained until each patient achieved CAS < 3 and then discontinued.

SC-TCZ was used concurrently with other treatment modalities in cases 2 and 3, and therefore, the clinical response cannot be solely attributed to a single therapy. In case 2, the adverse effects of high-dose steroid therapy necessitated an adjunctive treatment to achieve remission. In case 3, the patient had previously been treated with steroids, but the reduction in CAS and

**Table 1: Summary of patient characteristics**

	Case 1	Case 2	Case 3
Gender	Female	Female	Female
Age	64	49	62
TSI	676	>500	451
Smoking history	28-pack-year history, current smoker	30-pack-year history, quit within past 1 year	40-pack-year history, current smoker
Prior treatment	IV steroid infusions, total thyroidectomy, orbital radiation, left orbital decompression	Oral steroids, orbital radiation, orbital decompression	IV steroid infusions, orbital radiation, peribulbar steroid injections
TCZ-SC treatment	162 mg weekly (11.2 mg/kg/months) × 4 months, then 162 mg every 2 weeks (5.6 mg/kg/months) × 4 months	162 mg weekly (8.8 mg/kg/months) × 4 months	162 mg every 2 weeks (4.6 mg/kg/months) × 4 months, then 162 mg weekly (9.2 mg/kg/months) × 2 months
Pre-tx CAS score	6/10	9/10	5/10
Post-tx CAS score	1/10	1/10	2/10
Proptosis reduction	2 mm	Unable to assess due to orbital decompression*	2 mm
Adverse effects	Transient fatigue and malaise	None	Increased serum LDL and triglycerides

TSI=Thyroid-stimulating immunoglobulin, TCZ=Tocilizumab, SC=Subcutaneous, CAS=Clinical activity score, LDL=Low-density lipoprotein

proptosis was seen with the stepwise titration of SC-TCZ. These cases demonstrate the potential use of SC-TCZ as an adjunctive therapy. Higher doses and longer treatment durations were used in this study compared to the previously reported case series.<sup>[5]</sup> The authors opted for this dosing strategy due to the anticipated prolonged duration of inflammation given the smoking history.

Large prospective studies are needed to determine the optimal dosing for treating TED, but studies and outcomes for SC-TCZ in the treatment of other rheumatologic diseases suggest that there is significant latitude in safe and effective dosing of TCZ. Specifically, after a 2-year follow-up, the safety profile of SC-TCZ has been shown to be consistent with the known safety profile of TCZ-IV without an increased incidence of known or new side effects.<sup>[9-12]</sup> Prior head-to-head comparison studies have found the tolerability and safety of SC-TCZ at weekly and biweekly dosing to be similar to monthly TCZ-IV.<sup>[13]</sup> No serious adverse events were noted in the present case series. Case 1 reported fatigue and malaise for the first few days after each injection, and case 3 had elevated LDL and triglyceride levels successfully controlled with rosuvastatin. A recent randomized control trial by Lanzolla *et al.* found that addition of atorvastatin to IV steroid therapy improved treatment outcomes in hypercholesterolemic patients with moderate or severe active TED, so it is possible this also contributed to improvement in case 3.<sup>[14]</sup> Despite two patients undergoing surgery while on immunosuppression with SC-TCZ, neither one developed an infection. All patients were monitored with surveillance laboratories throughout their therapy without evidence of neutropenia. We did not observe any other commonly reported minor adverse events such as nasopharyngitis or injection site reactions.<sup>[9]</sup>

All three patients described subjective improvement in quality of life with SC-TCZ therapy, although this was not formally quantified. Specifically, patients reported satisfaction with treatment due to clinical improvement, avoidance of previously experienced steroid-induced side effects, and the convenience of self-administering treatment at home. A prior study that switched patients from TCZ-IV to SC-TCZ found that patients appreciated the fewer time constraints and greater autonomy with self-administration.<sup>[15]</sup> In the face of public health concerns surrounding COVID-19, a significant advantage of SC-TCZ is that time spent in health-care facilities can be minimized. In addition, there are significant cost savings with SC-TCZ compared to other promising immunomodulatory drugs. A 4-month course of biweekly SC-TCZ would cost approximately \$9000<sup>[16]</sup> – less than one-third the cost of an equivalent cycle of TCZ-IV depending on facility fees<sup>[5]</sup> or two-third the cost of a single vial of teprotumumab.<sup>[17]</sup> SC-TCZ

also allows the patient to titrate dosing intervals and treatment duration based on signs, symptoms, and side effects with physician supervision. This is the treatment paradigm that is applied to other autoimmune diseases and has the potential to be successful for patients with inflammatory TED.

The observations from this case series lend support to prior evidence that SC-TCZ is a viable therapy for active, inflammatory disease refractory to steroids and suggests that variable dosing strategies may be used in patients who smoke. While large prospective studies are needed to better evaluate the efficacy, safety, and dosing of SC-TCZ, this study suggests that SC-TCZ may be useful as part of combination therapy in smokers with TED refractory to systemic steroids and orbital radiation. In addition, this study suggests that SC-TCZ can be used at higher doses for longer durations that previously reported without serious adverse effects. Moreover, its ability to be self-administered at home may offer advantages of reduced cost, convenience, social distancing in the era of COVID-19, and the ability for patients to titrate dosing intervals and treatment duration in consultation with their physicians.

### Financial support and sponsorship

This study was financially supported NIH Center Core Grant P30EY014801, Research to Prevent Blindness Unrestricted Grant.

### Conflicts of interest

The authors declare that there are no conflicts of interests of this paper.

### References

1. Ayabe R, Rootman DB, Hwang CJ, Ben-Artzi A, Goldberg R. Adalimumab as steroid-sparing treatment of inflammatory-stage thyroid eye disease. *Ophthalmic Plast Reconstr Surg* 2014;30:415-9.
2. Xing L, Ye L, Zhu W, Shen L, Huang F, Jiao Q, *et al.* Smoking was associated with poor response to intravenous steroids therapy in Graves' ophthalmopathy. *Br J Ophthalmol* 2015;99:1686-91.
3. Roos JCP, Paulpandian V, Murthy R. Serial TSH-receptor antibody levels to guide the management of thyroid eye disease: The impact of smoking, immunosuppression, radio-iodine, and thyroidectomy. *Eye (Lond)* 2019;33:212-7.
4. Perez-Moreiras JV, Gomez-Reino JJ, Maneiro JR, Perez-Pampin E, Romo Lopez A, Rodríguez Alvarez FM, *et al.* Efficacy of tocilizumab in patients with moderate-to-severe corticosteroid-resistant graves orbitopathy: A randomized clinical trial. *Am J Ophthalmol* 2018;195:181-90.
5. Copperman T, Idowu OO, Kersten RC, Vagefi MR. Subcutaneous tocilizumab for thyroid eye disease: Simplified dosing and delivery. *Ophthalmic Plast Reconstr Surg* 2019;35:e64-6.
6. Smith TJ, Kahaly GJ, Ezra DG, Fleming JC, Dailey RA, Tang RA, *et al.* Teprotumumab for thyroid-associated ophthalmopathy. *N Engl J Med* 2017;376:1748-61.
7. Strianese D. Efficacy and safety of immunosuppressive agents for thyroid eye disease. *Ophthalmic Plast Reconstr Surg*

- 2018;34:S56-9.
8. Silkiss RZ, Paap MK, Roelofs KA, Agi J, Weis E. Treatment of corticosteroid-resistant thyroid eye disease with subcutaneous tocilizumab. *Can J Ophthalmol* 2021;56:66-70.
  9. Genentech. Actemra (Tocilizumab) [Package Insert]. U.S. Food and Drug Administration Website; April 2018. Available from: [https://www.accessdata.fda.gov/drugsatfda\\_docs/nda/2017/125276Orig1s114TOC.cfm](https://www.accessdata.fda.gov/drugsatfda_docs/nda/2017/125276Orig1s114TOC.cfm). [Last accessed on 2019 Dec 20].
  10. Kivitz A, Olech E, Borofsky MA, Zazueta B, Navarro-Sarabia F, Radominski SC, *et al*. Two-year efficacy and safety of subcutaneous tocilizumab in combination with disease-modifying antirheumatic drugs including escalation to weekly dosing in rheumatoid arthritis. *J Rheumatol* 2018;45:456-64.
  11. Atsumi T, Fujio K, Yamaoka K, Tomobe M, Kuroyanagi K, Kameda H. Safety and effectiveness of subcutaneous tocilizumab in patients with rheumatoid arthritis in a real-world clinical setting. *Mod Rheumatol* 2018;28:780-8.
  12. Mallalieu NL, Wimalasundera S, Hsu JC, Douglass W, Wells C, Penades IC, *et al*. Intravenous dosing of tocilizumab in patients younger than two years of age with systemic juvenile idiopathic arthritis: Results from an open-label phase 1 clinical trial. *Pediatr Rheumatol Online J* 2019;17:57.
  13. Lauper K, Mongin D, Iannone F, Klami Kristianslund E, Kvien TK, Nordström D, *et al*. Comparative effectiveness of subcutaneous tocilizumab versus intravenous tocilizumab in a pan-European collaboration of registries. *RMD Open* 2018;4:e000809.
  14. Lanzolla G, Sabini E, Leo M, Menconi F, Rocchi R, Sframeli A, *et al*. Statins for Graves' orbitopathy (STAGO): A phase 2, open-label, adaptive, single centre, randomised clinical trial. *Lancet Diabetes Endocrinol* 2021;9:733-42.
  15. Darloy J, Segaud N, Salmon JH, Eschard JP, Goëb V, Deprez X, *et al*. Tocilizumab effectiveness after switching from intravenous to subcutaneous route in patients with rheumatoid arthritis: The RoSwitch study. *Rheumatol Ther* 2019;6:61-75.
  16. Actemra Prices. Coupons and Patient Assistance Programs. Actemra Prices; 2020. Available from: <https://www.drugs.com/price-guide/actemra>.
  17. Mukamal R. New Drug Treats Thyroid Eye Disease without Surgery; 2020.