

The analysis of root canal curvature and direction of maxillary lateral incisors by using cone-beam computed tomography

A retrospective study

Linlin Wang, MS^a, Zhensong Wang, MD^b, Qiang Wang, MD^a, Jingchao Han, MS^a, Hongsheng Tian, MS^{c,*} 

Abstract

The aim of this study was to investigate root canal curvature and direction of maxillary lateral incisors in Shandong, China.

Cone beam computed tomography (CBCT) images of 176 maxillary lateral incisors of 88 patients were collected in Shandong Province, China. Software included with CBCT was used to measure the angle of root canal curvature of maxillary lateral incisors on the maximum bending plane. In addition, the direction of each root canal was recorded. The data were statistically analyzed by SPSS 17.0 software package.

The results showed that all the samples had a single canal (Vertucci's type I). The incidence of straight root canals, curved root canals, and S-type root canals was 39.2%, 58%, and 2.8%, respectively. The difference in the mean angle of root canal curvature failed to identify any differences between the left and right side ($P > .05$). The most curved root canal of maxillary lateral incisors oriented in the palato-distal direction.

The maxillary lateral incisors were mainly curved root canals of which the proportion of moderate curvature was the largest. Software included with CBCT would provide some valuable information for root canal instrumentation of maxillary lateral incisors.

Keywords: cone-beam computed tomography, maxillary lateral incisor, root canal curvature

1. Introduction

At present, root canal therapy is regarded as a fundamental method of treating pulpal and periapical diseases. Comprehensive knowledge of root canal system is the necessary prerequisite for successful root canal therapy, which could avoid complications such as root canal deviation, formation of steps, and separation of instruments.^[1] Root canal curvature is one of the important indices to evaluate the difficulty of root canal therapy.^[2] Usually, maxillary lateral incisors exist with curvature

of different degrees. In clinical practice, digital periapical radiogram serve important function in observing the curved shape of the root canal and evaluating difficulties of root canal treatment before surgery. Some studies used digital periapical radiogram to measure the root canal curvature, but two-dimensional overlap and distortion influence the accuracy of investigations.^[3,4,5] Moreover, multiple prior investigations placed k-files or silver points to measure root canal curvature by X-ray film^[4,6] Hartmann et al^[7] reported that metal wires might not remain centered in the root canal, especially in wide canals, therefore, a file or silver point curvature may not be representative of the actual root canal curvature. To overcome the limitations, three-dimensional imaging techniques were used. In 2000, Peters et al^[8] detailed three-dimensional models of root canal systems by micro-computed tomography (micro-CT). Micro-CT can provide valuable information on root canal curvature in the extracted teeth,^[9] but the micro-CT technique was reported to be time-consuming and higher radiation exposure.^[5] In addition, micro-CT can not reflect the root and canal morphology in a living body.^[10] With rapid advancements in CBCT over the recent years, the postprocessing technique and resolution has risen tremendously. In 2008, Estrela et al^[11] proposed the higher accuracy of CBCT images to identify anatomic and pathologic alterations compared to panoramic and periapical radiographs has been shown to reduce the incidence of false-negative results. CBCT has become an accurate equipment to describe the curvature of root canal in three-dimensional direction.^[12,13]

Therefore, the present study collected CBCT data on maxillary lateral incisors in Shandong, observed the maximal root canal curvature on the maximum bending plane of the root canal and recorded the direction of curved root canal, so as to provide references for clinical practice.

Editor: Hyunjin Park.

The authors have no funding and conflicts of interest to disclose.

The datasets generated during and/or analyzed during the current study are available from the corresponding author on reasonable request.

^aJinan Stomatological Hospital, Binzhou Medical University Hospital, China, ^bThe Second Affiliated Hospital of Shandong University of Traditional Chinese Medicine, China, ^cShandong University of Traditional Chinese Medicine, China.

* Correspondence: Hongsheng Tian, Shandong University of Traditional Chinese Medicine, Wenhua Road NO 42, Shandong Province, Jinan 250011, China (e-mail: hongshengtian@163.com).

Copyright © 2022 the Author(s). Published by Wolters Kluwer Health, Inc. This is an open access article distributed under the terms of the Creative Commons Attribution-Non Commercial License 4.0 (CCBY-NC), where it is permissible to download, share, remix, transform, and buildup the work provided it is properly cited. The work cannot be used commercially without permission from the journal.

How to cite this article: Wang L, Wang Z, Wang Q, Han J, Tian H. The analysis of root canal curvature and direction of maxillary lateral incisors by using cone-beam computed tomography: a retrospective study. *Medicine* 2022;101:1 (e28393).

Received: 12 June 2021 / Received in final form: 15 October 2021 / Accepted: 2 December 2021

<http://dx.doi.org/10.1097/MD.00000000000028393>

2. Materials and methods

2.1. Data collection

This study was approved by our institutional review board, and the exemption of informed consent had been granted because this is a retrospective study. One hundred seventy six maxillary lateral incisors of 88 patients with CBCT in Jinan Stomatological Hospital were collected from January 2018 to July 2019. There were 37 males and 51 females in this study. The range of the patient's age was from 19 to 70, which gave an average age of 34.90 ± 13.55 years old. Inclusion criteria were: the healthy bilateral maxillary lateral incisors, clear image and free of artifacts, completed root formation. Exclusion criteria were: root resorption, treatment of root canal, treatment of apicoectomy.

2.2. CBCT scanning condition

All subjects were performed on a New Tom 5G CBCT scanner (QR Verona, Verona, Italy). The patients were placed in the supine position. Scanning parameters: voltage 110 kV, current 8.34 mA, field of vision 10×10 mm, exposure time 4second.

2.3. Classification standard

According to the Vertucci classification,^[14] The root canal types were recorded and divided into the following 8 types. Type I. A single canal extends from the pulp chamber to the apex. Type II. Two separate canals leave the pulp chamber and join short of the apex to form 1 canal. Type III. One canal leaves the pulp chamber, divides into 2 within the root, and then merges to exit as 1 canal. Type IV. Two separate and distinct canals extend from the pulp chamber to the apex. Type V. One canal leaves the pulp chamber and divides short of the apex into 2 separate and distinct canals with separate apical foramina. Type VI. Two separate canals leave the pulp chamber, merge in the body of the root, and redivide short of the apex to exit as 2 distinct canals. Type VII. One canal leaves the pulp chamber, divides and then rejoins within the body of the root, and finally redivides into 2 distinct canals short of the apex. Type VIII. Three separate and distinct canals extend from the pulp chamber to the apex.

2.4. Measurement methods

Measurements were performed using the method of Schneider.^[15] The root canal orifice was defined as point A and the root canal foramen was defined as point C. The first line a was scribed from point A parallel to the long axis of canal. The point where the line began to leave the long axis of canal was defined as point B. The second line b was drawn from B to C. Angle of intersection of line a and b was measured and recorded (Fig. 1). The same experimenter measured the root canal curvature according to the above method, and took the average value of 3 measurements to reduce bias between observers. According to the Schneider method, the calculated curvature of root canal can be divided into 3 categories: 0–5 degrees of root canal curvature is category I (also known as basically no curvature), 5–20 degrees of root canal curvature is category II (moderate curvature of root canal), and more than 20 degrees of root canal curvature is category III (severe curvature of root canal). The combination of category II and category III is indicated a curved root canal. If there were more than 2 curves, it was recorded as S-shaped root canal. In consideration of it was

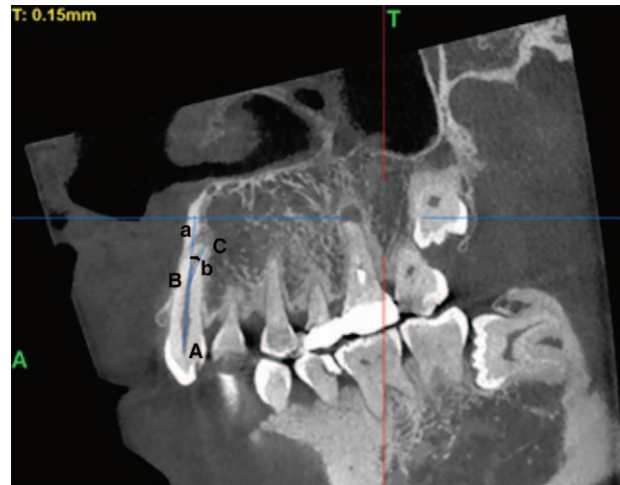

Figure 1. The angle of root canal curvature of maxillary lateral incisors. The angle between the line a and line b was measured.

necessary to find multiple bending planes, the measurement of S-shaped root canal was not carried out in this study. In 3D view, the line a was adjusted perpendicular to the screen, we draw 2 straight lines centered on line a, 1 line paralleled to incisal edge and 1 line was perpendicular to it. The image was divided into 4 quadrants: mesio-palatal direction (including mesial direction); palato-distal direction (including palatal direction); disto-buccal direction (including distal direction); bucco-mesial direction (including buccal direction), then, the direction of line b was recorded (Fig. 2).

2.5. Statistical analysis

Analysis were performed using SPSS statistical 17.0. Descriptive data are presented as mean with standard deviation (SD) frequencies (%) when appropriate. The angle means of root canal curvature of maxillary lateral incisors in the left and right side were analyzed by paired *t* test. A *P* value $<.05$ was considered a statistically significant level.

3. Results

The results showed that the maxillary lateral incisors were all type I root canals in this study. In addition, out of 176 subjects,

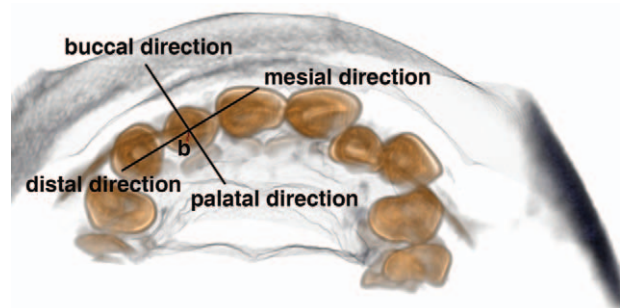


Figure 2. The direction of curved root canal of maxillary lateral incisors. The direction of line b was recorded.

Table 1**Classification of root canal curvature of maxillary lateral incisors between the right and left side.**

Classification	Right maxillary lateral incisors (n=86)	Left maxillary lateral incisors (n=85)	Total maxillary lateral incisors
Category I	34	35	69
Category II	36	32	68
Category III	16	18	34
<i>P</i>		.462	

69 reported straight root canals, 102 reported curved root canals, and 5 reported S-shaped root canals, showing incidence of 39.2%, 58%, and 2.8%. The incidence of moderate curvature and severe curvature of root canals was 38.6% (68/176), 19.3% (34/176), respectively. The classification of root canal curvature of maxillary lateral incisors was shown in Table 1. Moreover, the mean angle of the root canal curvature for the right maxillary lateral incisors was $10.33 \pm 9.98^\circ$ as compared with $11.73 \pm 11.47^\circ$ for the left maxillary lateral incisors. The mean angle of root canal curvature of the maxillary lateral incisors was not significant between the right and left side ($P > .05$) (Table 2). The incidence of curved root canals in 4 quadrants was 11.8% (12/102), 71.5% (73/102), 12.7% (13/102), 3.9% (4/102), respectively.

4. Discussion

To improve the success rate of root canal therapy, it is necessary to understand the knowledge of the root canal anatomy. Root canal preparation is the most critical step in root canal therapy. It is widely considered that the angle of curved root canal is an important factor affecting the success rate of root canal therapy.^[16,17] Numerous methods have been used to measure the curvature of root canal in previous studies, such as digital periapical radiogram, transparent tooth method, microcomputed tomographic imaging and so on. The buccolingual and the mesiodistal root canal curvature were mostly measured by digital periapical radiogram. In the report of Weng et al,^[18] it showed a positive correlation between the incidence of buccolingual root canal curvature and the incidence of mesiodistal curvature, which indicated that the change of root canal curvature is often three-dimensional direction and should not only focus on a certain direction. Furthermore, the root canal file changes the shape of root canal during the process of experiment. In recent years, micro-CT was often used in evaluations of the curvature of root canal in some studies.^[19,20,21] However, the experimental methods for evaluating the curvature of root canal were mostly in vitro studies. Furthermore, it was a hard work to collect large numbers of samples. CBCT is an advanced equipment used in oral medicine, which provides three-dimensional images by a 180 to 360° rotation and offers a lower exposure in comparison with micro-CT. At the same time, as a noninvasive tool, CBCT is

reported as accurate as the staining and clearing technique for evaluating root canal systems.^[22] In addition, maxillary lateral incisors usually have a single root containing a root canal. So, we can measure the degree of root canal curvature of maxillary lateral incisors on the maximum bending plane of the root canal using the inbuilt software MPR. Reconstruction software of CBCT is used to clearly visualize the root canal in vivo. Haridas et al^[13] pointed out that CBCT is a reliable and non-destructive method for the study of root canal morphology. In this study, CBCT was used to measure the degree of root canal curvature of maxillary lateral incisors, which can provide accurate reference data for clinical treatment.

Several of primary studies suggested that type I was the most prevalent in maxillary lateral incisors, which is consistent with this study.^[14,23] The mean curvature of maxillary lateral incisors was 11° in the study by Schäfer et al,^[24] which is similar to this study. The evaluation of the curvature in maxillary lateral incisors by Willersbausen et al^[25] demonstrated that there was no statistical difference in the degree of root canal curvatures incisors between the right and left side. The same observation was found in our observation. Willersbausen et al^[25] also showed that all of the lateral incisors exhibited curvatures. In this study, the incidence of curved root canals was 58%. It must be noted that 2 studies used different classification methods for root canal curvature, which might partially explain this differences. Another explanation is the racial different. Park et al^[26] noted the canal curvature of maxillary lateral incisors that was mainly oriented in the disto-palatal direction, which is in line with our finding. The study has several limitations that may affected the results. One limitation of this study was that CBCT showed limited information of subtle structures such as lateral branch root canal and apical divergence due to its resolution. Another limitation was the measurement of line did not always pass through the actual center of the root canal, we believe that the number of curved canals was underestimated.

In a word, most of the root canal curvature of maxillary lateral incisors showed moderate and severe curvature, which undoubtedly increases the complication and challenge for root canal therapy. It is very necessary to evaluate the angle of curved root canal in advance by CBCT to prevent iatrogenic injury in the process of root canal preparation, so as to improve the success rate of treatment.

Table 2**Root canal curvature of the maxillary incisor between the right and left side ($\bar{x} \pm s$).**

Tooth/Group	n	Root canal curvature (°)
Right maxillary lateral incisors	83	10.33 ± 9.98
Left maxillary lateral incisors	83	11.73 ± 11.47
<i>P</i>		.305

Author contributions

Formal analysis: Zhensong Wang.

Investigation: Qiang Wang.

Methodology: Qiang Wang.

Supervision: Jingchao Han.

Writing – original draft: Linlin Wang.

Writing – review & editing: Linlin Wang, Hongsheng Tian.

References

- [1] Song M, Kim HC, Lee W, Kim E. Analysis of the cause of failure in nonsurgical endodontic treatment by microscopic inspection during endodontic microsurgery. *J Endod* 2011;37:1516–9.
- [2] Hou BX. Complications occurred in root canal mechanical preparation: the reason, prevention and management. *Zhonghua Kou Qiang Yi Xue Za Zhi* 2019;54:605–11.
- [3] Sousa TO, Haiter-Neto F, Nascimento EHL, et al. Diagnostic accuracy of periapical radiography and cone-beam computed tomography in identifying root canal configuration of human premolars. *J Endod* 2017;43:1176–9.
- [4] Backman CA, Oswald RJ, Pitts DL. A radiographic comparison of two root canal instrumentation techniques. *J Endod* 1992;18:19–24.
- [5] Pettiette MT, Metzger Z, Phillips C, Trope M. Endodontic complications of root canal therapy performed by dental students with stainless-steel K-files and nickel-titanium hand files. *J Endod* 1999;25:230–4.
- [6] Luiten DJ, Morgan LA, Baugartner JC, Marshall JG. A comparison of four instrumentation techniques on apical canal transportation. *J Endod* 1995;21:26–32.
- [7] Hartmann RC, Fensterseifer M, Peters OA, et al. Methods for measurement of root canal curvature: a systematic and critical review. *Int Endod J* 2018;52:169–80.
- [8] Peters OA, Laib A, Ruegsegger P, Barbakow F. Three dimensional analysis of root canal geometry by high-resolution computed tomography. *J Dent Res* 2000;79:1405–9.
- [9] Rhodes JS, Ford TR, Lynch JA, et al. Micro-computed tomography: a new tool for experimental endodontology. *Int Endod J* 1999;32:165–70.
- [10] Zhang X, Xiong SJ, Ma Y, et al. A cone-beam computed tomographic study on mandibular first molars in a Chinese subpopulation. *PLoS One* 2015;10:1–9.
- [11] Estrela C, Bueno MR, Sousa-Neto MD, Pecora JD. Method for determination of root curvature radius using cone-beam computed tomography images. *Braz Dent J* 2008;19:114–8.
- [12] Ordinola-Zapata R, Bramante CM, Versiani MA, et al. Comparative accuracy of the clearing technique, CBCT and Micro-CT methods in studying the mesial root canal configuration of mandibular first molars. *Int Endod J* 2017;50:90–6.
- [13] Haridas H, Mohan A, Papisetti S, et al. Computed tomography: will the slices reveal the truth. *J Int Soc Prev Community Dent* 2016;6:85–92.
- [14] Vertucci FJ. Root canal anatomy of the human permanent teeth. *Oral Surg Oral Med Oral Pathol* 1984;58:589–99.
- [15] Schneider SW. A comparison of canal preparations in straight and curved root canals. *Oral Surg Oral Med Oral Pathol* 1971;32:271–5.
- [16] Grande NM, Plotino G, Pecci R, et al. Cyclic fatigue resistance and three-dimensional analysis of instruments from two nickel-titanium rotary systems. *Int Endod J* 2006;39:755–63.
- [17] Zelada G, Varela P, Martín B, et al. The effect of rotational speed and the curvature of root canals on the breakage of rotary endodontic instruments. *J Endod* 2002;28:540–2.
- [18] Weng X, Yu S, Zhao S, et al. Root canal curvature of anterior teeth in the Han nationality in Shan xi province. *J Pract Stomato* 2007;23:808–10.
- [19] Plotino G, Grande NM, Pecci R, et al. Three-dimensional imaging using micro-computed tomography for studying tooth macromorphology. *J Am Dent Assoc* 2006;137:1555–61.
- [20] Yamada M, Ide Y, Matsunaga S, et al. Three-dimensional analysis of mesiobuccal root canal of Japanese maxillary first molar using micro-CT. *Bull Tokyo Dent Coll* 2011;52:77–84.
- [21] Grande NM, Plotino G, Gambarini G, et al. Present and future in the use of micro-CT scanner 3D analysis for the study of dental and root canal morphology. *Ann Ist Super Sanita* 2012;48:26–34.
- [22] Neelakantan P, Subbarao C, Subbarao CV. Comparative evaluation of modified canal staining and clearing technique, cone-beam computed tomography, peripheral quantitative computed tomography, spiral computed tomography, and plain and contrast medium-enhanced digital radiography in studying root canal morphology. *J Endod* 2010;36:1547–51.
- [23] Zeng S, Hu Y, Wang X, et al. In vitro study on the curvatures of root canal of maxillary first premolars among adolescents in Guangdong. *West China J Stomatol* 2012;30:287–91.
- [24] Schäfer E, Diez C, Hoppe W, Tepel J. Roentgenographic investigation of frequency and degree of canal curvatures in human permanent teeth. *J Endod* 2002;28:211–6.
- [25] Willershausen B, Kasaj A, Tekyatan H, et al. Radiographic investigation of location and angulation of curvatures in human maxillary incisors. *J Endod* 2008;34:1052–6.
- [26] Park PS, Kim KD, Perinpanayagam H, et al. Three-dimensional analysis of root canal curvature and direction of maxillary lateral incisors by using cone-beam computed tomography. *J Endod* 2013;39:1124–9.