

# Lymphaticovenous Anastomosis Releases the Lower Extremity Lymphedema-associated Pain

Makoto Mihara, MD\*†‡  
 Hisako Hara, MD\*  
 Han Peng Zhou, MD§  
 Shuichi Tange, MD¶  
 Kazuki Kikuchi, MD‡

**Background:** We investigate the effectiveness of lymphaticovenous anastomosis (LVA) in releasing lymphedema-associated pain.

**Methods:** We performed a retrospective analysis. Subjects of this study included lower extremity lymphedema patients who presented persistent and constant degrees of pain in their lower limbs. LVA was performed under local anesthesia. The preoperative lower extremity pain and postoperative lower extremity pain were surveyed using the visual analog scale on a score from 0 to 10. The circumferences of the limbs were also recorded.

**Results:** A total of 8 patients (16 lower limbs) were included. The subjects included 1 man and 7 women, and their average age was 72 years. The average follow-up period was 17 months. The average preoperative and postoperative visual analog scale scores were 5.3 and 1.8, respectively. Moreover, 7 patients who had records of their lower extremity circumference observed an average changing rate of -4.7% in lower extremity lymphedema index after the surgery.

**Conclusion:** LVA can release the pain in the affected limbs of lymphedema. (*Plast Reconstr Surg Glob Open* 2017;5:e1205; doi: 10.1097/GOX.0000000000001205; Published online 26 January 2017.)

The most common causes of lower extremity pain are of neurological origins, such as lumbar disk herniation and spinal stenosis or of orthopedic origins, such as trauma and osteoarthritis.<sup>1</sup> Cases of lymphedema-associated pain are seldom reported<sup>2,3</sup> and are often confused with postmastectomy pain syndrome.<sup>4,5</sup>

Studies done in the 1960s suggest the use of antidepressant drugs for symptomatic treatment of lymphedema-associated pain.<sup>6</sup> Vascularized lymph node transfer has also been reported to be effective for reducing upper extremity pain after mastectomy.<sup>7</sup> In our clinic, we perform lymphaticovenous anastomosis (LVA) for patients with

lower extremity lymphedema (LEL).<sup>8-10</sup> It is a procedure that involves anastomosing the collecting lymphatic vessels within the subcutaneous tissue to nearby veins using supermicrosurgery techniques to create a bypass to restore lymph flow by directing the lymph from the lymphatic vessels into the veins, thus reducing lymph congestion in the edematous region.

In this retrospective study, we evaluated and compared the degree of lower extremity pain before and after the LVA procedure in LEL patients who presented persistent pain over their clinical course. The purpose of this study is to investigate the effectiveness of LVA in reducing lymphedema-associated pain.

## PATIENTS AND METHODS

We performed a retrospective analysis of the effectiveness of LVA in reducing LEL-associated pain. Subjects of this study included LEL patients who visited the Department of Vascular Surgery, Saiseikai General Hospital, between April 2010 and May 2014 and who presented with persistent and constant degree of pain in their lower limbs over multiple clinic visits for a period of 3 months or longer before the surgery, despite conservative therapy having been performed. Patients who presented with inconsistent degree of pain or whose pain was of orthopedic origin were excluded from this study. Orthopedic surgeons examined

From the \*Department of Lymphatic and Reconstructive Surgery, Saiseikai Kawaguchi General Hospital, Saitama, Japan; †Department of Plastic and Reconstructive Surgery, Tokyo Takanawa Hospital, Tokyo, Japan; ‡Department of Plastic and Reconstructive surgery, Nadogaya Hospital, Chiba, Japan; §Department of Clinical Resident, Fujieda Municipal General Hospital, Fujieda, Japan; and ¶Department of Clinical Resident, NTT East Japan Hospital, Tokyo, Japan.

Received for publication June 21, 2016; accepted December 1, 2016.

Drs. Mihara, Hara, and Zhou contributed equally to this work.

Copyright © 2017 The Authors. Published by Wolters Kluwer Health, Inc. on behalf of The American Society of Plastic Surgeons. This is an open-access article distributed under the terms of the Creative Commons Attribution-Non Commercial-No Derivatives License 4.0 (CCBY-NC-ND), where it is permissible to download and share the work provided it is properly cited. The work cannot be changed in any way or used commercially without permission from the journal.

DOI: 10.1097/GOX.0000000000001205

**Disclosure:** The authors have no financial interest to declare in relation to the content of this article. The Article Processing Charge was paid for by the authors.

the patients who formerly had orthopedic diseases and diagnosed the origin of the pain. Additionally, vascular ultrasonography was performed to rule out any venous anomaly.

Lymphoscintigraphy<sup>11,12</sup> and indocyanine green (ICG) lymphography<sup>13,14</sup> were used for diagnosing LEL. The results of the lymphoscintigraphy were classified based on the Maegawa classification (Table 1).<sup>11</sup> The results of the ICG lymphography were classified based on the Yamamoto classification (Table 2),<sup>13</sup> and patients were labeled as “c” if any dilatation of collateral lymphatic vessels were observed (Table 3). We applied LVA when there were abnormal findings in either ICG lymphography or lymphoscintigraphy. Regions where linear patterns were observed under ICG lymphography were also marked. The pathological classification of the lymphedema was done based on the Classification of International Society of Lymphology.<sup>15</sup> Moreover, we performed preoperative venous ultrasonography to identify and mark the subcutaneous veins suited for the LVA procedure.

The LVA procedure was performed under local anesthesia in all cases. Skin incisions were made at sites of possible lymph congestion as identified by lymphoscintigraphy and ICG lymphography, and the subcutaneous collecting lymphatic vessels were identified and anastomosed to nearby veins under a surgical microscope using 11-0 or 12-0 nylon microsutures. Additionally, we also classified the collecting lymphatic vessels identified during the surgery using the normal, ectasis, contraction, and sclerosis type (NECST) classification<sup>16,17</sup> based on intraoperative microscopic visual observations.

Both preoperative lower extremity pain and postoperative lower extremity pain of each patient were surveyed and recorded using the visual analog scale (VAS) on a score from 0 to 10. The preoperative and postoperative circumferences of the affected limbs were also recorded as a secondary outcome measure of the LVA procedure. Limb circumferences were measured essentially at 6 predefined sites: dorsum of foot, the ankle, 10 cm below the patella, the patella, 10 cm above the patella, and 20 cm above the patella. Because the number of sites measured was not always consistent before and after the surgery, only measurements that were measured both preoperatively and postoperatively were used in the analysis. To decrease the influence of body weight, we applied LEL index to

**Table 2. ICG Lymphographic Classification of Lower Lymphedema Cases (Yamamoto Classification)**

Characteristic Appearance	
0	No edema or dermal backflow images are detected.
1	There is a splash pattern around the groin region.
2	The stardust pattern is limited proximal to the superior border of the patella.
3	The stardust pattern extends distally beyond the superior border of the patella.
4	The stardust pattern is observed throughout the whole limb.
5	A diffuse pattern becomes evident with presence of the stardust pattern.

evaluate the change in circumference.<sup>18,19</sup> LEL index is calculated as follows: LEL index =  $\Sigma(\text{circumference})2/\text{body mass index}$ . The preoperative and postoperative changing rates of the LEL index were then calculated using the equation: changing rate (%) =  $[(\text{postoperative LEL index} - \text{preoperative LEL index})/\text{preoperative LEL index}] \times 100$ . Statistical analysis about preoperative and postoperative VAS scores and limb circumferences was performed using Student's *t* test. All reported *P* values were based on 2-sided tests, and *P* < 0.05 was regarded as significant.

This clinical study was conducted with the approval of the ethical committees at Saiseikai Kawaguchi General Hospital. All patients have provided written informed consent.

## RESULTS

Among a total of 86 LEL cases diagnosed by using lymphoscintigraphy and ICG lymphography during the study period, 8 patients (16 lower limbs) were selected as subjects to this study using the selection criteria mentioned in the Patients and Methods section.

Detailed patient summary is shown in Table 3. The subjects included 1 man and 7 women, with age ranging from 61 to 80 years; their average age was 72 years. Four patients presented with primary lymphedema and the other 4 patients presented with secondary lymphedema whose etiology is shown in Table 1. Pelvic computed tomography imaging or magnetic resonance imaging was performed except for case 8, and pelvic abnormalities such as venous compression or nerve inflammation that may cause limb pain were ruled out. The average postoperative follow-up period was 17 months. CEAP (Clinical manifestation, Etiologic factors, Anatomic distribution, Pathophysiologic dysfunction) level of case 8 was 3 and she did not have skin change.

Preoperative lymphoscintigraphy revealed that 15 out of 16 limbs were in stage 1, of which 12 presented with dilatation of collateral lymphatic vessels (Table 3).

ICG lymphography revealed 14 out of 16 limbs with dilatation of collateral lymphatic vessels. One patient presented diffused pattern in the crus, which indicates severe lymphedema, in addition to the stardust pattern, which indicates mild lymphedema, accompanied by dilatation of the collateral lymphatic vessels in the thigh area (case 7).

A total of 46 collecting lymphatic vessels were used for the LVA procedure, of which 40 were classified as ectasis

**Table 1. Lymphoscintigraphy Classification of Lower Lymphedema Cases (Maegawa Classification)**

Characteristic Appearance	
Normal	No lymph stasis or dermal backflow is detected.
1	There is no obvious dermal backflow. The inguinal lymph nodes are reduced in number and lymph stasis in the lymphatics or collateral lymphatics along the saphenous vein are visible.
2	Lymph stasis in the lymphatics and visible dermal backflow on the thigh can be seen. The inguinal lymph nodes are reduced in number.
3	Dermal backflow in the leg and thigh can be seen.
4	Dermal backflow and lymph stasis in the lymph vessels in the leg can be seen.
5	There is no obvious dermal backflow in either the leg or the thigh.

**Table 3. Patient Characteristics**

Case	Sex	Age	Type of Lymphedema	Past History	BMI	Duration of Edema		Lymphadenectomy	Radiation	ISL Stage		Lymphoscintigraphy		ICG Lymphography	
						Right	Left			Right	Left	Right	Left	Right	Left
1	F	61	Secondary	Uterine cancer	32.69	5 mo	+	-	1	1	1	1	0c	0c	
2	M	76	Secondary	Colorectal cancer	25.91	12 mo	+	+	1	1	1	1	0c	0c	
3	F	69	Primary	(-)	29.95	4 mo	-	-	2a	2a	1	1	0c	0c	
4	F	80	Primary	Lumbar spondylosis	34.2	10 mo	-	-	1	1	1	1	0c	0c	
5	F	75	Primary	Lumbar disk herniation	29.41	11 mo	-	-	1	1	1	1	0c	0c	
6	F	79	Primary	Hysteromyoma + ovarian cyst	28.08	9 y	-	-	1	1	1	1	0c	0	
7	F	64	Secondary	Ovarian cancer	26.58	2 y	+	-	1	2b	1	1	1c	4c	
8	F	71	Secondary	Left lower limb varix	23.43	2 y 4 mo	-	-	1	1	1	1	0	1c	

\*c in the last 2 columns indicates the dilatation of collateral lymphatic vessels. BMI, body mass index; F, female; ISL, International Society of Lymphology; M, male; mo, months; y, years; (-), None; (+), Treatment performed; (-), Treatment not performed.

type (87%) via intraoperative microscopic visual observations (Table 4).

Six of the 8 patients used low-pressure compression stockings (nonmedical use) before the surgery; one patient was able to stop their use due to improvement in pain after the LVA procedure. Of the remaining 2 patients, one (case 2) did not use any preoperative compression stockings due to severe pain and did not start their use after the surgery and the other (case 7) used high-pressure compression stockings (medical use) preoperatively and continued their use after the surgery.

The average preoperative and postoperative VAS scores were 5.3 and 1.8, respectively (Table 5), and the scores were significantly reduced postoperatively ( $P = 0.0003$ ). Moreover, 7 patients who had records of their lower extremity circumference observed an average changing rate of -4.7% in LEL index after the surgery (Tables 5 and 6), which is statistically nonsignificant ( $P = 0.182$ ). The relationship between the difference of preoperative and postoperative VAS scores and the changing rate of preoperative and postoperative LEL indices is shown in Figure 1. The correlation index was -2.7, which indicated low correlation ( $P = 0.45$ ).

**Table 4. The Intraoperative Microscopic Visual Observations of the Lymphatic Vessels Identified for LVA**

Case	Limb	No. LVA	NECST Classification			
			N	E	C	S
1	R	1	0	1	0	0
	L	2	0	1	1	0
2	R	1	0	1	0	0
	L	5	0	4	1	0
3	R	4	0	4	0	0
	L	3	1	2	0	0
4	R	1	0	1	0	0
	L	5	0	5	0	0
5	R	3	0	3	0	0
	L	4	0	4	0	0
6	R	3	0	3	0	0
	L	5	0	5	0	0
7	R	2	0	2	0	0
	L	3	0	1	0	2
8	R	2	0	1	1	0
	L	2	0	2	0	0

Each vessel was classified based on the NECST classification. C, contraction type; E, ectasis type; L, left; N, normal type; NECST, normal, ectasis, contraction, and sclerosis type; R, right; S, sclerosis type.

**Table 5. The Post-LVA Results**

Case	Location of Pain	VAS Score		Changing Rate (%)		Follow-up (mo)
		Pre	Post	Right	Left	
1	Left limb	5	4	-19.40	-18	47
2	Left limb	7	1	7.2	-2.7	13
3	Bilateral limb	5	1	-2	-0.6	17
4	Left limb	5	0	-17.3	-12.7	32
5	Bilateral limb	5	1	-3.3	-2.3	16
6	Bilateral limb	3	0.5	0.9	-0.1	12
7	Left limb	4	0	-3.2	8.2	12
8	Bilateral limb	8	5	NA	NA	18

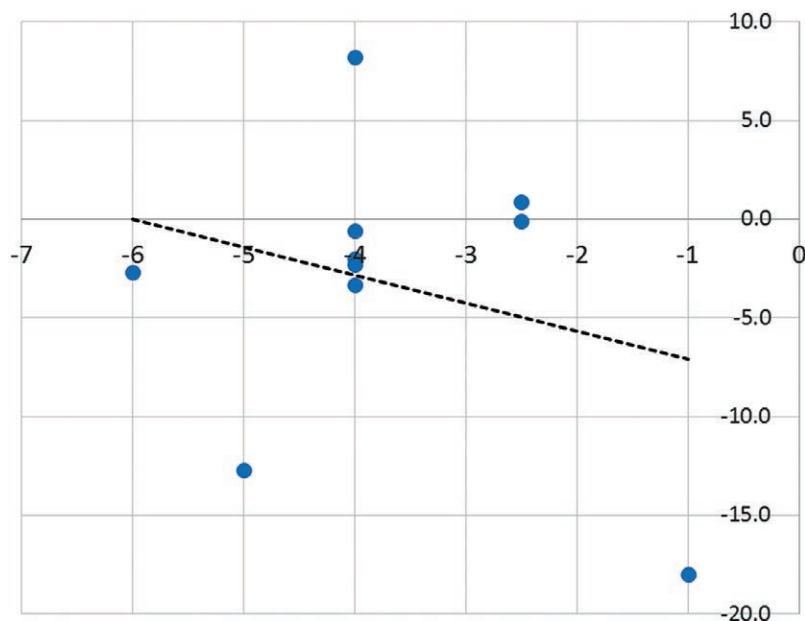
Changing rate was calculated using the equation: changing rate (%) = [(postoperative LEL index - preoperative LEL index) / preoperative LEL index] × 100. NA, not applicable.

**Table 6. Preoperative and Postoperative Circumference Measurement of All Cases**

Case	Pre/Post	20 cm above Knee	10 cm above Knee	Knee	10 cm below Knee	Ankle	Dorsum Foot
1-Right	Pre	*	*	40.5	*	22.5	22
	Post	*	*	36	*	20.5	20.2
1-Left	Pre	*	*	40	*	22	22
	Post	*	*	35.5	.*	21.2	20
2-Right	Pre	*	*	36	*	20.7	22.7
	Post	*	*	35.6	*	21.2	23.5
2-Left	Pre	*	*	36.7	*	24.5	24.5
	Post	*	*	36.5	*	21.4	23.5
3-Right	Pre	*	45.3	39.3	41.2	24.4	25.1
	Post	*	43	40.5	39	24	26
3-Left	Pre	*	45.3	41.9	39.8	25.6	26.3
	Post	*	45	41	29.5	25	26
4-Right	Pre	*	45	40	33.8	23.4	23.5
	Post	*	38.5	34.5	29.5	20.5	20.5
4-Left	Pre	*	44.2	40.3	32.6	27	25.3
	Post	*	39.5	37	30.5	21	21
5-Right	Pre	*	43	38.2	35.2	23.6	22.7
	Post	*	43.2	35.8	34.1	21.7	21.6
5-Left	Pre	*	41.7	38	35.5	24.6	23
	Post	*	42.3	37.2	34	22	21.2
6-Right	Pre	48.3	41	35.3	32.7	22	21.2
	Post	49	41	36	33	21.3	21.5
6-Left	Pre	54.4	43.7	39.6	34.9	22.5	21.5
	Post	54	44	39.8	34.5	23	22.8
7-Right	Pre	50	43.6	39	34.8	22	23
	Post	49.2	41.5	38.4	34.4	25	21.4
7-Left	Pre	55.8	45.3	40.9	41	26.3	23
	Post	58.9	49.7	42.5	42.2	24.3	20.5
8-Right	Pre	*	*	*	*	*	*
	Post	*	*	*	*	*	*
8-Left	Pre	*	*	*	*	*	*
	Post	*	*	*	*	*	*

Limb circumferences were measured at 6 predefined sites: dorsum of foot, the ankle, 10 cm below the patella, the patella, 10 cm above the patella, and 20 cm above the patella. Because the number of sites measured was not always consistent before and after the surgery, only measurements that were measured both preoperatively and postoperatively were used in the analysis.

\* Not applicable.



**Fig. 1.** The relationship between the difference of preoperative and postoperative VAS scores and the changing rate of preoperative and postoperative LEL indices. The vertical scale indicates the changing rate of LEL index and the horizontal scale indicates the difference in VAS scores.

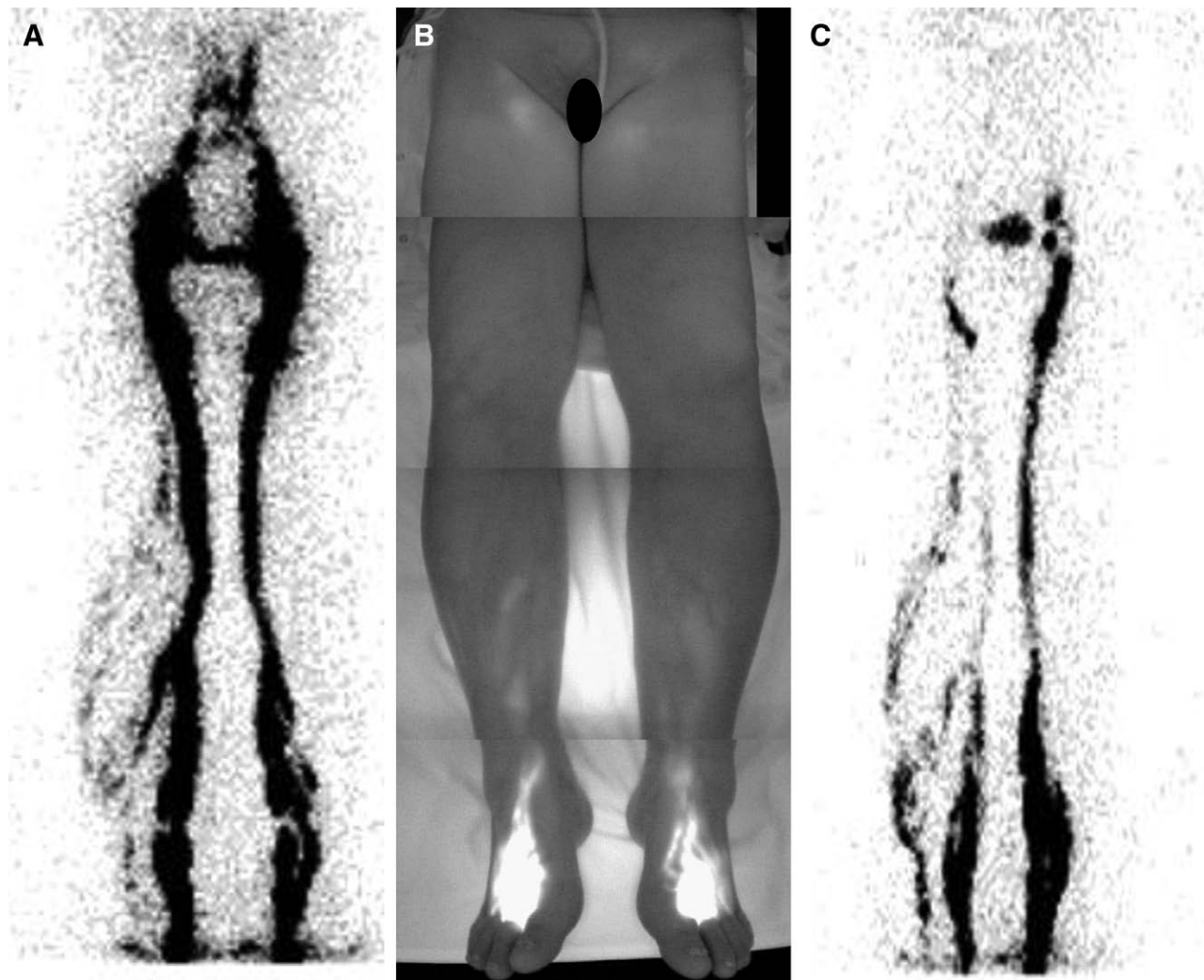
**Case 3**

Case 3 was a 69-year-old female patient with no history of previous illness. The patient presented with LEL and associating lower extremity pain (VAS score: 5) 10 months before the surgery. The patient also consulted the orthopedics department and the possibility that the pain originated from orthopedic causes such as knee or spinal disorders was ruled out. Lymphoscintigraphy (Fig. 2A) and ICG lymphography of her lower extremities revealed bilateral lymphatic vessel dilatation and formation of collateral lymphatic vessels (Fig. 2B). Dermal backflow was not observed. From these results, the patient was diagnosed with lymph congestion in both her lower limbs and was indicated for the LVA procedure. Surgery was performed under local anesthesia and LVA was performed at a total of 4 sites on the right and 3 sites on the left (Fig. 3A). During the procedure, the lymphatic vessels identified at all 4 sites on the right limb were classified as ectasis type (Fig. 3B). Lymphatic vessel identified at one of the 3 sites on the left limb was classified as normal type and the ones at the other 2

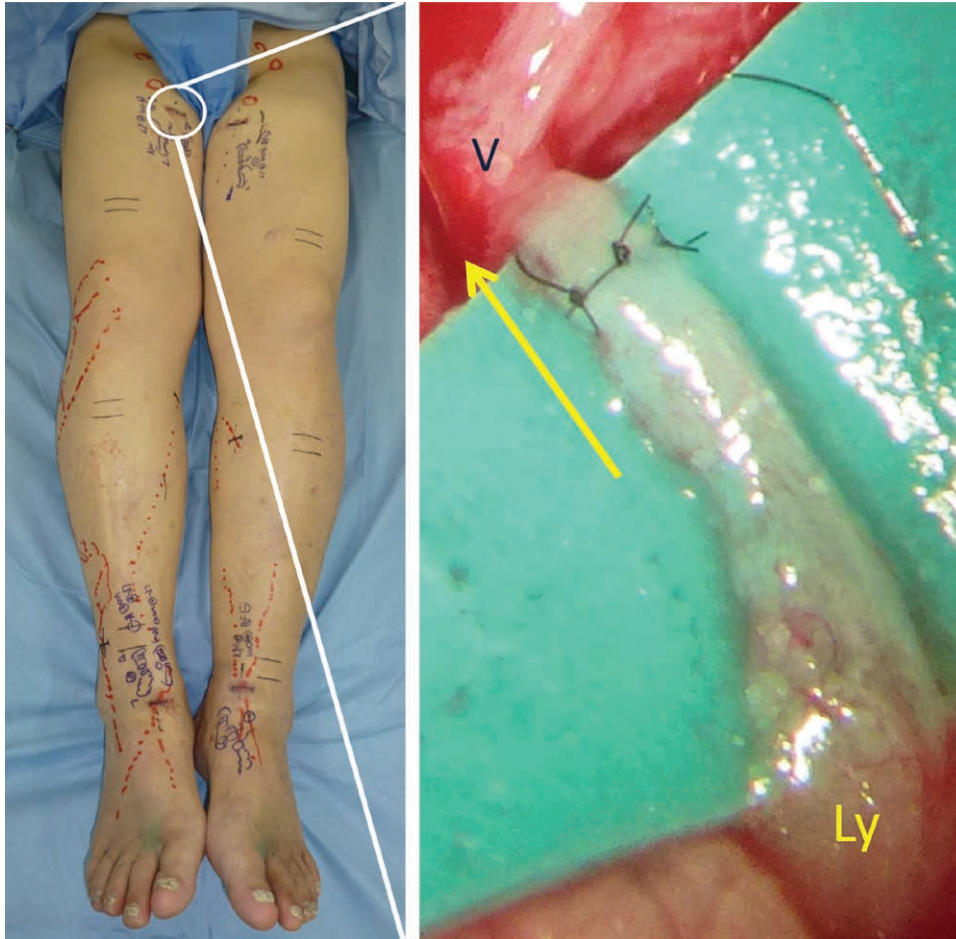
sites were classified as ectasis type. There were no postoperative complications and the pain subsided gradually from 5 to 1 on the VAS over a 17-month postoperative period. The changing rates of limb circumference were  $-2.0\%$  on the right and  $-0.6\%$  on the left, indicating a decrease in tissue edema in both limbs. Postoperative lymphoscintigraphy also showed improved lymph flow and decreased lymph congestion in the regions (Fig. 2C).

**Case 7**

Case 7 was a 64-year-old female patient with a history of ovarian cancer 3 years prior, who had undergone total hysterectomy, bilateral salpingo-oophorectomy, and pelvic lymphadenectomy. The patient received postoperative chemotherapy but was not given any radiation treatments. Bilateral LEL appeared 1.5 years after the surgery along with gradual pain (VAS score: 4) centralized around the left ankle. Her symptoms failed to show improvement despite massage therapies and the use of compression stockings. Lymphoscintigraphy revealed normal lymph flow in the



**Fig. 2.** The lymphoscintigraphy result of case 3 30 minutes after the isotope injection. A, Preoperative lymphoscintigraphy results; lymph congestion and lymphatic vessel dilatation can be observed in the bilateral lower extremities. B, Preoperative ICG lymphography results. C, Postoperative lymphoscintigraphy results; improvement in both lymph congestion and vessel dilatation can be observed.



**Fig. 3.** The LVA procedure of case 3. A, Preoperative markings and a view of the patient's entire lower extremities. B, Intraoperative LVA observation near the interior region of the right thigh; dilatation of the collecting lymphatic vessels can be seen. Ly, collecting lymphatic vessels, ectasis type; Ve, vein.

right limb; however, the left limb presented dermal back-flows that were centralized below the knee (Fig. 4A). ICG lymphography revealed splash pattern on the right limb and a mixture of stardust and diffuse patterns on the entire left limb, with a higher ratio of diffuse pattern in the crus and a higher ratio of stardust pattern in the thigh area (Fig. 4B). The abdominal area also presented splash pattern under ICG lymphography. Surgery was performed under local anesthesia and LVA was performed at a total of 2 sites on the right and 3 sites on the left. The lymphatic vessels identified at both sites on the right were classified as ectasis type. On the other hand, the lymphatic vessels identified at one of the 3 sites on the left were of ectasis type and the ones at the other 2 sites were of sclerosis type. There were no postoperative complications, and the pain gradually but completely disappeared from 4 to 0 on the VAS over a 12-month postoperative period. The changing rates of limb circumference were  $-3.2\%$  on the right and  $+8.2\%$  on the left limb, indicating an improvement in lymph flow on the right only.

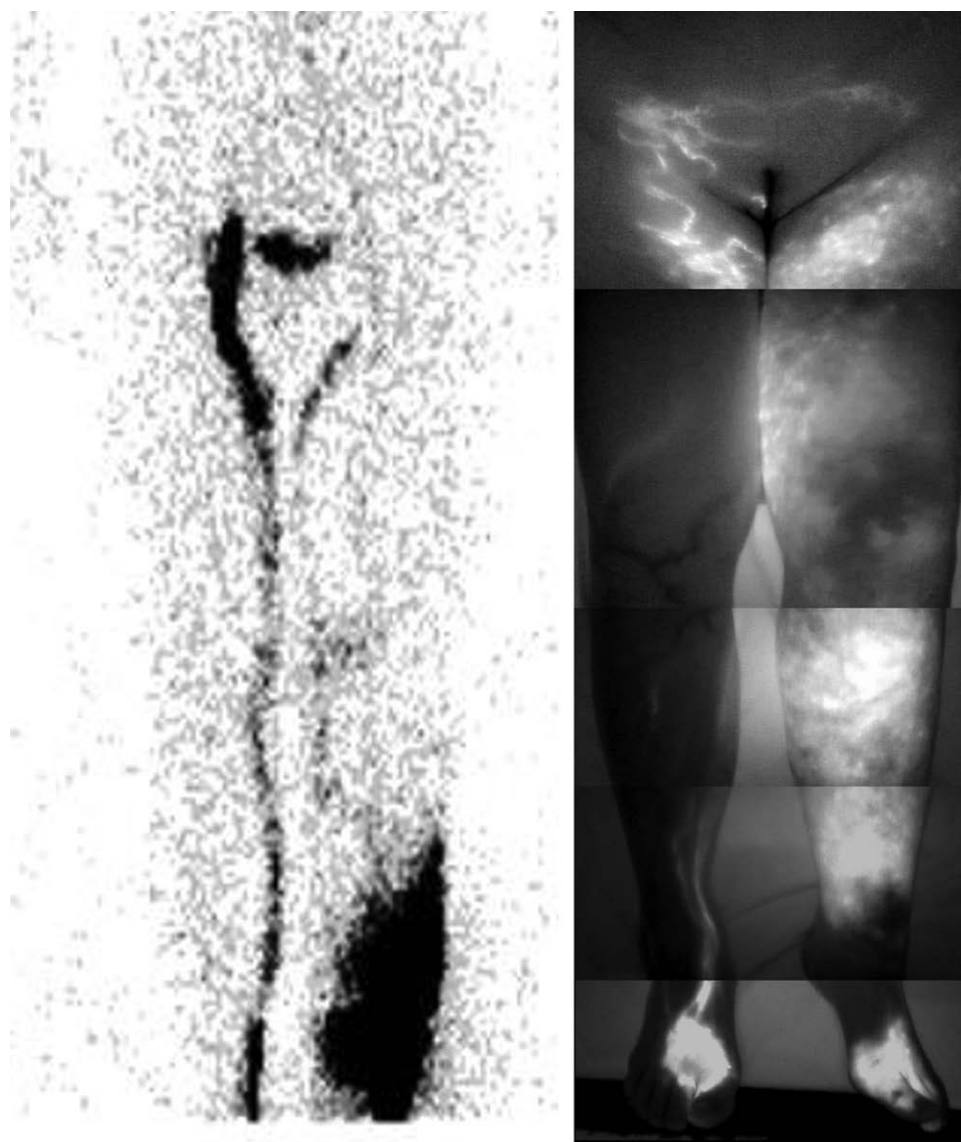
### DISCUSSION

We performed LVA in lymphedema patients presenting with lower extremity pain and observed a significant

decrease in the degree of pain in most patients after the surgery.

It is commonly known that lower extremity pain is often associated with blood congestion or varicose veins; however, the detailed pain-causing mechanism is still poorly understood.<sup>20-22</sup> Some articles have been published to report pain accompanying upper limb lymphedema, and conservative therapy, physiotherapy,<sup>23-26</sup> or surgical treatment was applied.<sup>7,27</sup> In some articles, the cause of pain in upper limb lymphedema is presumed to be neurogenic; however, it has not yet been proven. Similarly, much study has yet to be done to fully understand the physiology behind the pain caused by lymphedema and the pain-reducing mechanism of LVA.

One possible theory suggests that lymph congestion results in an increase of lymph pressure within the lymphatic vessels, which may stimulate the nearby sensory nerves to cause pain. This is supported by our experience that patients often feel pain as the contrast medium is injected into their lymphatic vessels during lymphangiography, suggesting possible existence of nociceptors in the lymphatic vessel walls or in nearby tissues. Moreover, in a previous study done by Hara et al,<sup>17</sup> among the lymph-



**Fig. 4.** The preoperative lymphoscintigraphy and ICG lymphography results of case 7. A, The lymphoscintigraphy result; the right limb appears normal, but the left limb presents dermal backflow centralized in areas below the knee. B, The ICG lymphography result; splash pattern can be seen near the interior of the thigh on the right limb; a mixture of diffuse and stardust patterns is observed on the entire left limb with a higher ratio of diffuse pattern in the crus and a higher ratio of splash pattern in the thigh area; the lower abdominal area shows a splash pattern.

edema patients who had undergone LVA, only 26% of the lymphatic vessels found during the procedure were of ectasis type, whereas our study showed an obviously high 87%. This result may imply that ectasis-type lymphatic vessels are observed more frequently in lymphedema patients with associating pain, which may be the result of increased lymph pressure.

Furthermore, pain still manifested in patients who did not show any significant dermal backflow under lymphoscintigraphy. ICG lymphography is an examination with a high sensitivity as described in several papers, and it can detect the lymphatic dysfunction presented as splash pattern which cannot be detected by lymphoscintigraphy. However, even if there is not a splash pattern, stage 1 in lymphoscintig-

raphy indicates lymphatic stasis or increased lymphatic inner pressure.<sup>11</sup> The morphologic changes in the collecting lymphatic vessels, which are caused by increased lymphatic inner pressure, have already started even in the linear pattern area.<sup>16,17,28</sup> In fact, we observed the abnormally dilated lymphatic vessels intraoperatively. Stage 1 in lymphoscintigraphy is thought to indicate this condition and seems to be sufficient for diagnosing lymphedema. From the results of this study, it may be feasible to infer that a lack of dermal backflow in a lymphedema region suggests a buildup of lymph pressure within the lymphatic vessels, which may have been released as the lymph congestion aggravates and overflows out of the vessels, causing the dermal backflow to appear, resulting in a decrease in lymph pressure and reliev-

ing the pain caused by elevated lymph pressure.<sup>16</sup> LVA can improve lymph flow in a lymphedema region by releasing the elevated lymph pressure via the venous bypass,<sup>8–10</sup> thus relieving the pain in the region.

Another theory suggests that lymph congestion may create tension forces upon the subcutaneous tissue and the epidermis, which is recognized subjectively by the patient as pain. Therefore, performing LVA to reduce the lymph pressure may result in relieving the stress on the surrounding tissue, causing a positive effect in reducing pain in the region. This may be supported by the fact that manual lymph drainage using complex physical therapy is known to have an effect in reducing pain in patients.<sup>25,26</sup>

Because most patients subjected to this study did not present with severe cases of edema before the LVA procedure, the increase in the circumference was originally very small, which may be the reason why there was no significant correlation between the change in VAS scores and the change in LEL indices.

Usually, sensitivity of ICG lymphography is higher than that of lymphoscintigraphy,<sup>14</sup> but the description was completely opposite (Table 1). One reason for this result may be the physical appearance of the patients. Most of the patients were obese (an average body mass index of 28.8) and the subcutaneous tissue was so thick that ICG lymphography could not make images of lymphatic vessels. On the contrary, lymphoscintigraphy can draw the lymphatic vessels in deep layer, although the resolution is lower than that of ICG lymphography. A combination of ICG lymphography and lymphoscintigraphy is thought to be the best way to diagnose early-stage lymphedema.

Our limitations were that because of the retrospective nature of the study we were unable to evaluate pain in individual sites of the affected limb or the duration of the pain and thus were not able to make proper assessment of the LVA effectiveness. Also, evaluating patient pain based on the VAS score inevitably relies on the patient's subjective symptoms. Preintervention and postintervention analog scale of pain may be somewhat biased for the intervention itself and should have been compared with another intervention. Although we do not have any data to show preconservative and postconservative treatment VAS scores, all of the present cases did not experience improvement in their pain with conservative treatment and thus proceeded to LVA. At least, pain in their lymphedematous limbs decreased after LVA and the patients could reduce the amount of antidepressant drugs. Future studies must be pursued prospectively with a larger number of subjects and with an objective method to measure pain to improve the reliability of the results.

There is another limitation in this study. The changing rates in the right leg of case 2 and the left leg of case 7 were positive, which indicates the worsening of lymphedema. The pain in lymphedema often occurs in the very early stage and decreases when lymphedema deteriorates. It is difficult to know whether the postoperative pain relief is due to LVA or deterioration of lymphedema. In the future, a study in which 2 groups, postoperatively improved lymphedema group and postoperatively worsening lymphedema group, will be compared is needed.

In conclusion, the LVA procedure was effective in reducing the degree of lower extremity pain in lymphedema patients.

**Makoto Mihara, MD**

Department of Lymphatic and Reconstructive Surgery  
Saiseikai Kawaguchi General Hospital  
5-11-5 Nishi-Kawaguchi, Kawaguchi-Shi  
Saitama 332-0021, Japan  
E-mail: mihara.plasticsurgery@gmail.com

## ACKNOWLEDGMENTS

We are grateful for the total cooperation received from Eri Saeiki, Izumi Masuda, Sachiko Kimura, Kyoko Hasegawa, Hiroshi Minezaki, Takiko Suzuki, Naomi Yamada, Noriyuki Murai, and Shigeru Harasawa (Saiseikai Kawaguchi General Hospital).

## REFERENCES

1. Provan JL, Moreau P, MacNab I. Pitfalls in the diagnosis of leg pain. *Can Med Assoc J.* 1979;121:167–171.
2. Elumelu-Kupoluyi TN, Adenipekun AA, Ntekim AI. Pain associated with secondary lymphedema among cancer patients. *J Palliat Care.* 2013;29:253–257.
3. Jeong HJ, Sim YJ, Hwang KH, et al. Causes of shoulder pain in women with breast cancer-related lymphedema: a pilot study. *Yonsei Med J.* 2011;52:661–667.
4. Taghian NR, Miller CL, Jammallo LS, et al. Lymphedema following breast cancer treatment and impact on quality of life: a review. *Crit Rev Oncol Hematol.* 2014;92:227–234.
5. Hormes JM, Bryan C, Lytle LA, et al. Impact of lymphedema and arm symptoms on quality of life in breast cancer survivors. *Lymphology.* 2010;43:1–13.
6. Gulluoglu BM, Cingi A, Cakir T, et al. Factors related to post-treatment chronic pain in breast cancer survivors: the interference of pain with life functions. *Int J Fertil Womens Med.* 2006;51:75–82.
7. Becker C, Pham DN, Assouad J, et al. Postmastectomy neuropathic pain: results of microsurgical lymph nodes transplantation. *Breast.* 2008;17:472–476.
8. Narushima M, Mihara M, Yamamoto Y, et al. The intravascular stenting method for treatment of extremity lymphedema with multiconfiguration lymphaticovenous anastomoses. *Plast Reconstr Surg.* 2010;125:935–943.
9. Yamamoto T, Koshima I, Yoshimatsu H, et al. Simultaneous multi-site lymphaticovenular anastomoses for primary lower extremity and genital lymphoedema complicated with severe lymphorrhea. *J Plast Reconstr Aesthet Surg.* 2011;64:812–815.
10. Mihara M, Hara H, Furniss D, et al. Lymphaticovenular anastomosis to prevent cellulitis associated with lymphoedema. *Br J Surg.* 2014;101:1391–1396.
11. Maegawa J, Mikami T, Yamamoto Y, et al. Types of lymphoscintigraphy and indications for lymphaticovenous anastomosis. *Microsurgery.* 2010;30:437–442.
12. Sundaram PS, Subramanyam P. Lymphoscintigraphy in the evaluation of limb edema. *Clin Nucl Med.* 2013;38:891–903.
13. Yamamoto T, Narushima M, Doi K, et al. Characteristic indocyanine green lymphography findings in lower extremity lymphedema: the generation of a novel lymphedema severity staging system using dermal backflow patterns. *Plast Reconstr Surg.* 2011;127:1979–1986.
14. Mihara M, Hara H, Araki J, et al. Indocyanine green (ICG) lymphography is superior to lymphoscintigraphy for diagnostic imaging of early lymphedema of the upper limbs. *PLoS One.* 2012;7:e38182.
15. International Society of Lymphology. The diagnosis and treatment of peripheral lymphedema: 2013 Consensus Document of



- the International Society of Lymphology. *Lymphology*. 2013;46:1–11. Review.
16. Mihara M, Hara H, Hayashi Y, et al. Pathological steps of cancer-related lymphedema: histological changes in the collecting lymphatic vessels after lymphadenectomy. *PLoS One*. 2012;7:e41126.
  17. Hara H, Mihara M, Seki Y, et al. Comparison of indocyanine green lymphographic findings with the conditions of collecting lymphatic vessels of limbs in patients with lymphedema. *Plast Reconstr Surg*. 2013;132:1612–1618.
  18. Yamamoto T, Matsuda N, Todokoro T, et al. Lower extremity lymphedema index: a simple method for severity evaluation of lower extremity lymphedema. *Ann Plast Surg*. 2011;67:637–640.
  19. Yamamoto T, Yamamoto N, Hayashi N, et al. Practicality of the lower extremity lymphedema index: lymphedema index versus volumetry-based evaluations for body-type-corrected lower extremity volume evaluation. *Ann Plast Surg*. 2016;77:115–118.
  20. Holzheimer RG, Stautner-Brückmann C. Calf pain in runners may be caused by venous insufficiency. *Eur J Med Res*. 2008;13:218–220.
  21. Worley CA. 'It hurts when I walk:' venous stasis disease—differential diagnosis and treatment. *Dermatol Nurs*. 2006;18:582–583.
  22. Beard RW, Highman JH, Pearce S, et al. Diagnosis of pelvic varicosities in women with chronic pelvic pain. *Lancet*. 1984;2:946–949.
  23. Bulley C, Coutts F, Blyth C, et al. A morbidity screening tool for identifying fatigue, pain, upper limb dysfunction and lymphedema after breast cancer treatment: a validity study. *Eur J Oncol Nurs*. 2014;18:218–227.
  24. Jud SM, Fasching PA, Maihöfner C, et al. Pain perception and detailed visual pain mapping in breast cancer survivors. *Breast Cancer Res Treat*. 2010;119:105–110.
  25. Hamner JB, Fleming MD. Lymphedema therapy reduces the volume of edema and pain in patients with breast cancer. *Ann Surg Oncol*. 2007;14:1904–1908.
  26. Carroll D, Rose K. Treatment leads to significant improvement. Effect of conservative treatment on pain in lymphoedema. *Prof Nurse*. 1992;8:32–33, 35–36.
  27. Teo I, Novy DM, Chang DW, et al. Examining pain, body image, and depressive symptoms in patients with lymphedema secondary to breast cancer. *Psychooncology*. 2015;24:1377–1383.
  28. Hara H, Mihara M, Ohtsu H, et al. Indication of lymphatico-venous anastomosis for lower limb primary lymphedema. *Plast Reconstr Surg*. 2015;136:883–893.