



Contents lists available at ScienceDirect

## International Journal of Surgery Case Reports

journal homepage: [www.casereports.com](http://www.casereports.com)

## Osteoid osteoma of scapular glenoid: A case report

Zeinab H.F. Amin<sup>a</sup>, Reem S. Al-Rasheedi<sup>a</sup>, Mona H. Sairafi<sup>b</sup>, Yousef Alrashidi<sup>a,\*</sup><sup>a</sup> Department of Orthopedics, College of Medicine, Taibah University, Al-Madinah, Saudi Arabia<sup>b</sup> Madinah Maternity and Children's Hospital, Al-Madinah, Saudi Arabia

## ARTICLE INFO

## Article history:

Received 19 September 2020

Received in revised form 26 October 2020

Accepted 27 October 2020

Available online 1 November 2020

## Keywords:

Osteoid osteoma

Scapula

Glenoid

Shoulder

Case report

## ABSTRACT

**INTRODUCTION:** Osteoid osteoma is a benign tumor of bone that predominantly affects young age group. It can affect any bone, but lower extremities are more commonly involved more than the upper extremities and it rarely affects the scapular glenoid.

**PRESENTATION OF CASE:** The present case is an 18-year-old female patient who suffered from chronic right forearm and shoulder nocturnal pain for 5 years, which was sometimes relieved by non-steroidal anti-inflammatory drugs intake. Prior to referral to orthopedic clinic, she was diagnosed as a case of a regional pain syndrome, managed by medical treatment without significant improvement. The diagnosis of an inferior glenoid osteoid osteoma was established radiologically. The patient was managed successfully by percutaneous radiofrequency ablation and the pain disappeared gradually after 2 weeks of the procedure.

**DISCUSSION:** The presence of lesions in unusual locations along with an atypical medical history could misinterpret and delay the diagnosis. Osteoid osteoma could be difficult to detect with plain radiographs; thus, advanced imaging is crucial if such lesion is suspected.

**CONCLUSION:** The scapular glenoid osteoid osteoma should be considered as part of the differential diagnosis of chronic shoulder pain especially if there is no response to initial medical treatment. Awareness of atypical presentations of scapular osteoid osteoma is required to avoid delay in diagnosis and treatment.

© 2020 The Author(s). Published by Elsevier Ltd on behalf of IJS Publishing Group Ltd. This is an open access article under the CC BY-NC-ND license (<http://creativecommons.org/licenses/by-nc-nd/4.0/>).

## 1. Introduction

Osteoid osteoma (OO) is a benign bone tumor that was first described by Bergstrand in 1930 [1]. It has been estimated that OO accounts is about 5% of all bone tumors and 11% of benign bone tumors [2]. The lesion is usually smaller than 1.5–2 cm and can be identified radiologically by presence of nidus. Histologically, the nidus is osteoid-rich with a highly loose and vascular connective tissue. The nidus may contain a variable amount of calcification [3].

The most known locations of OO are lower extremities and 80–90% of cases were reported to involve the cortices of the shafts of long bones. OO may affect the metaphyseal and epiphyseal regions of bones of the appendicular and axial skeletons, particularly the humerus, femur, and tibia [4]. Scapular OO have been only reported in case reports and in few cases within large case-series [5]. Up to our knowledge, only few cases of scapular glenoid have been reported in literature [6–8]. In the paper in hand, the authors describe an unusual scapular glenoid OO case with atypical medical history, which was misdiagnosed and treated initially as regional pain syndrome. The case was successfully treated by Computerized

Tomography (C.T.) scan-guided radiofrequency ablation. This case has been reported in line with the SCARE criteria [9].

## 2. Case report

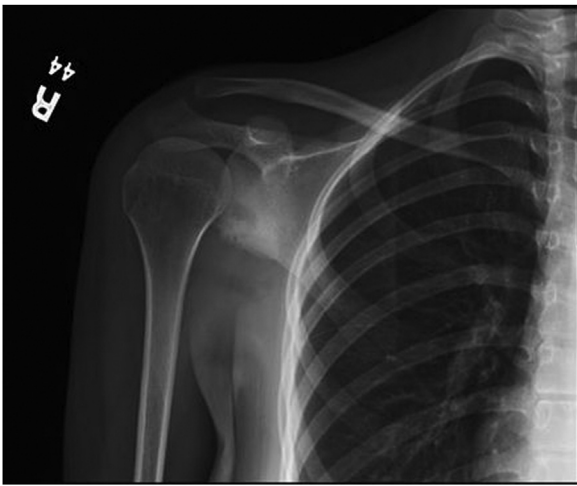
An 18-year-old otherwise healthy woman was referred to the orthopedic clinic with a complaint of right forearm and shoulder pain for 5 years. The pain started in the right forearm, which was intermittent, nocturnal, and progressive. Few months later, the pain started in the right shoulder and became constant and burning in nature, relived by non-steroidal anti-inflammatory drugs (NSAIDs) particularly Ibuprofen, aggravated by movement, and associated with excessive sweating in the right arm during the pain attack. The severity of pain was 7/10. Prior to her visit to orthopedic clinic, she has been labelled as a case of a regional pain syndrome and managed with a course of medical treatment and physiotherapy without significant improvement. The patient has unremarkable family history. The initial plain imaging of shoulder and cervical spine during past visits did not show any abnormalities.

On examination, the right shoulder showed painful range of motion, namely: abduction, flexion, and extension. No obvious shoulder swelling point tenderness or skin changes of shoulder region.

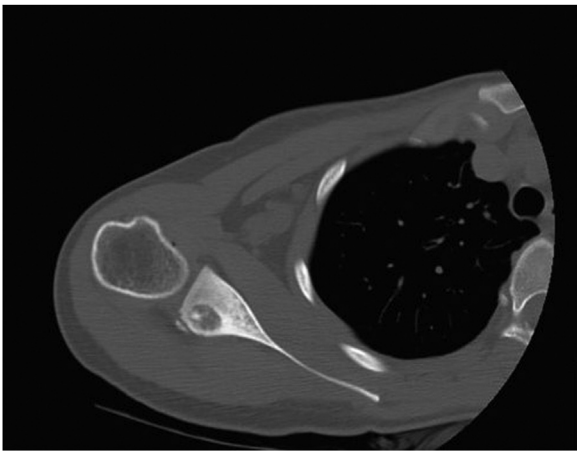
Plain x-ray of right shoulder showed an ill-defined lucency at the inferior glenoid with intact articular surface with no erosion, nor periosteal reaction or mass lesion (Fig. 1). Non-enhancement

\* Corresponding author at: College of Medicine, Taibah University, P.O. Box 30001, Al-Madinah, 41411, Saudi Arabia.

E-mail address: [yrashidi@taibahu.edu.sa](mailto:yrashidi@taibahu.edu.sa) (Y. Alrashidi).



**Fig. 1.** Antero-posterior (AP) Plain x-ray shows an ill-defined lesion at the glenoid without erosion nor periosteal reaction.

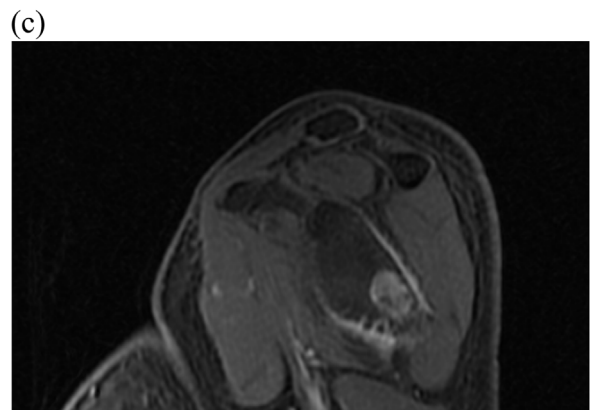
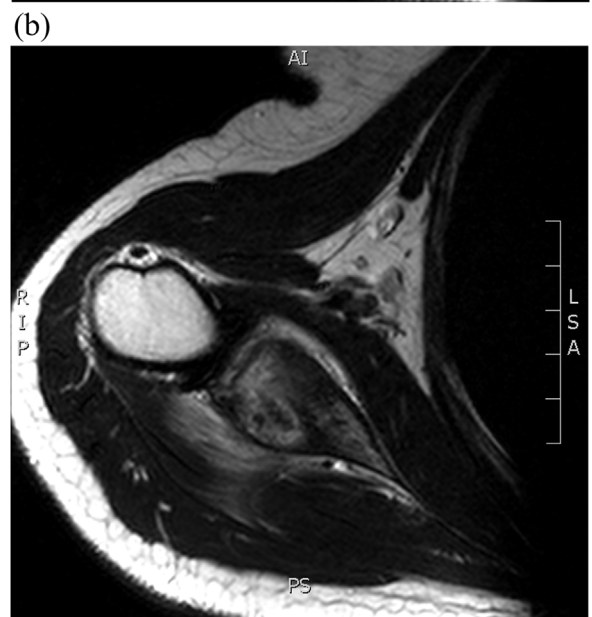
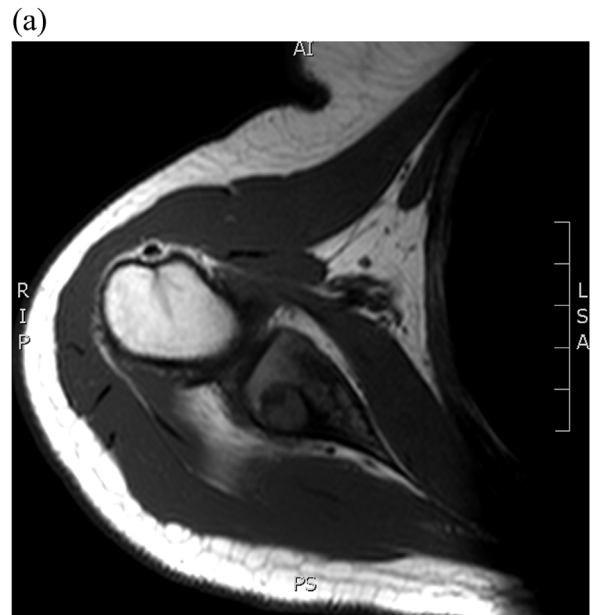
**Fig. 2.** CT scan shows a well-defined osteolytic lesion in the inferior glenoid with central nidus, which is typical of osteoid osteoma.

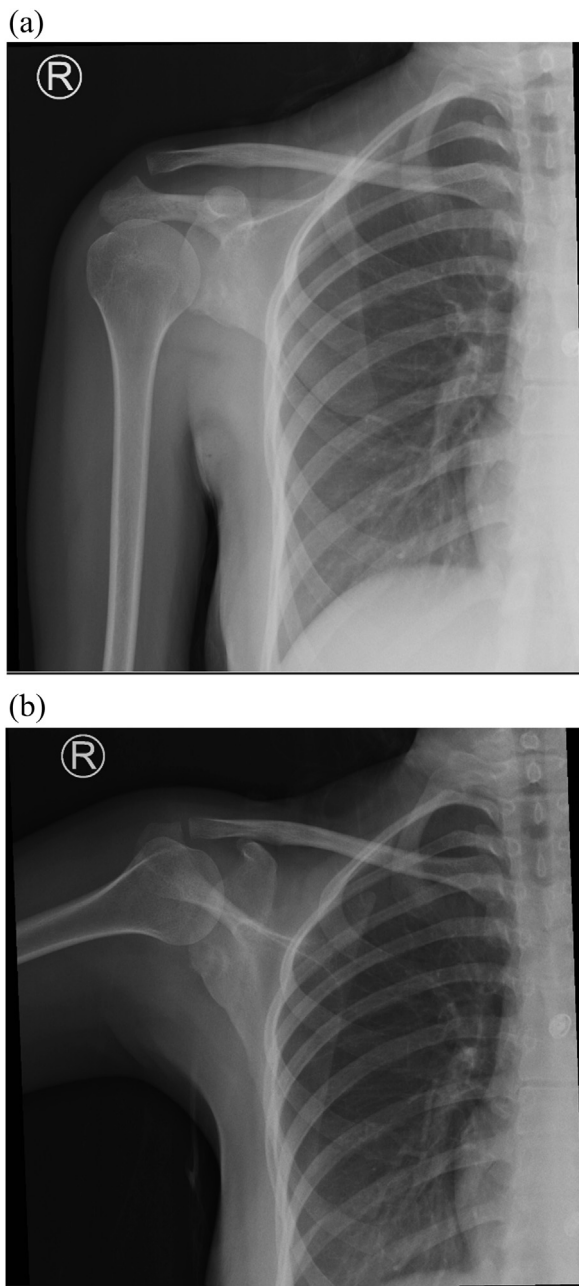
CT scan of the right shoulder revealed a well-defined lytic lesion with peripheral sclerotic involving the posterior inferior aspect of the glenoid with adjacent sclerosis and cortical thickening (central nidus), which is typical of osteoid osteoma. The lesion measures about  $1.4 \times 1.2$  cm in maximum diameter. No definite periosteal reaction or soft tissue component to suggest aggressive lesion (Fig. 2).

Magnetic resonance imaging (MRI) of the shoulder with contrast revealed well defined round lesion involving infero-posterior aspect of glenoid. The lesion demonstrates high T2, low T1 and avid enhancement on postcontrast image apart from small anterior portion that is not enhanced in postcontrast image and corresponding to area of low T2 signal intensity. Overall measurement of the lesion is about  $1.2 \times 1.3 \times 1.1$  cm in maximum dimension. There is adjacent mild bone marrow edema. There is no cortical destruction or soft tissue component to suggest aggressive feature. Area of rim signal alteration and irregularity involving inferior aspect of glenoid likely reactive changes. Unremarkable appearance of right shoulder joint with maintained glenohumeral joint. No other lesion is seen. The rotator cuff muscles are grossly unremarkable (Fig. 3).

The option of management of lesion by percutaneous CT-guided radiofrequency ablation had been discussed with a musculoskeletal radiologist before consideration of any surgical option. An informed consent was taken from the patient. The procedure was done under general anesthesia by a consultant in interventional radi-



**Fig. 3.** Magnetic resonance imaging (MRI) images of the shoulder. **A:** T1 axial cut of the joint. It shows low signal intensity lesion in the glenoid. **B:** T2 axial cut. It shows high signal intensity mainly at the periphery. **C:** Postcontrast T1 sagittal cut. It demonstrates an intense enhancement of the lesion.



**Fig. 4.** Follow-up plain radiographs. A: Anteroposterior view of right shoulder. B: Scapular view of the right shoulder.

ology. There were no reported post-intervention complications. A temporary arm sling was applied, and PRN (per needed) oral pain killers were prescribed. The patient tolerated the procedure and the pain gradually disappeared after 2 weeks of the procedure. The patient was followed for two and half years and had no pain nor restriction of shoulder motion. She is highly satisfied with the way of treatment. Plain x-rays of the last follow-up visit are shown in (Fig. 4).

### 3. Discussion

The case in hand was successfully treated by percutaneous radiofrequency ablation in contrary to similar cases reported in literature. Kelly et al. reported a case which was treated by an arthroscopic resection of the OO lesion located in the anterior cortex of the glenoid in a 30-year-old man [7]. Another case

reported by Malavolta et al., in which a 36-year-old female was treated by an arthroscopic excision of the lesion [8]. Mosheiff et al. described a successful treatment by a guided needle biopsy of the lesion in an 18 year old man [10]. Open excision with or without grafting of the lesion has been reported in literature [11–13].

Treatment strategies of OO include conservative treatment with NSAIDs, invasive percutaneous treatments (thermal, mechanical, or chemical ablation) and open surgical methods (curettage and en bloc resection techniques). The anatomical localization is the most important factor in decision-making of treatment method. Therefore, the best therapeutic approach should be selected case by case [14]. The radio frequency ablation (RFA) is a noninvasive treatment that has good results and the patient can go back to normal function shortly after treatment [15,16]. The surgical excision of the nidus is another choice of treatment but it has a technical and rehabilitation difficulties in case of unusual anatomic site [7].

OO is a benign tumor that can occur anywhere in the skeleton. The scapular body, coracoid and glenoid have been reported in literature as possible locations of OO [8,14,17,18]. The scapular OO is not often a part of the differential diagnosis of chronic pain of shoulder because its rarity [19]. The pain severity and distribution may vary and thusly extraordinary shoulder lesions are suspected, while OO is rarely taken into account [5,20].

The presence of lesions in unusual locations along with an atypical medical history can misinterpret the diagnosis with impingement syndrome, osteomyelitis, Brodie's abscess, inflammatory arthritis, eosinophilic granulomas and benign bony cysts [8,20]. Therefore, a delay in diagnosis is expected. For example, Ishikawa et al. described a case of a 17-year-old girl with painful shoulder joint motion which was diagnosed initially as a case of scapular osteomyelitis in association with synovitis. She had no improvement of symptoms over a two-month-period since initiation of antibiotics and NSAIDs. Interestingly, night pain was first reported by the patient after two months of her first visit. A CT scan showed an anterior glenoid OO, which was eventually excised surgically [11]. In another study by Ghosh et al., a 7-year-old child who had neurological symptoms at presentation and a clinical picture that mimic neuralgic amyotrophy. Hopefully, further work-up to rule out other differential diagnoses revealed a scapular body OO on CT and MRI scans [17]. AlGhoozi et al. described a two-year delay in diagnosis of scapular coracoid OO. The patient was labelled as a case of impingement syndrome, which did not show clinical improvement after an arthroscopic decompression and three corticosteroid injections [18]. Our case is another example of atypical medical history, which lead to five-year delay in treatment. The patient complained of forearm pain initially when she was 13, followed by shoulder pain few months later and associated with excessive sweating in the arm during pain attacks. She was labelled as a case of regional pain syndrome without significant clinical improvement. During that period, she was on follow-up in pediatric rheumatology and neurology clinics. Beside plain x-rays, no shoulder CT scan was considered. Such a delay in diagnosis in our case could be attributed, in part, to young age, presence of neurological symptoms and delay in appearance of radiological signs of the lesion [17].

The diagnosis of OO often is difficult to detect with plain X-rays. Technitium 99m-methyl diphosphonate (Tc99 m MDP) bone scan has a high sensitivity for localization of any osteoblastic lesion including the OO [21]. However, the detection of the lesion is usually difficult with planner images and correlative SPECT (Single Photon Emission Computed Tomography) imaging has a role in the diagnosis, especially in unusual sites of the lesions. The suspicion of OO has to increase if high signal intensity on T2-weighted MRI images is seen with or without presence of central nidus [20,22].

#### 4. Conclusion

Awareness of atypical presentations of scapular osteoid osteoma is required to avoid delay in diagnosis and treatment. It should be considered as part of the differential diagnosis of chronic shoulder pain especially if there is no response to initial medical treatment.

#### Declaration of Competing Interest

The authors report no declarations of interest.

#### Funding

None.

#### Ethical approval

Ethical approval is not necessary for case reports in our locality.

#### Consent

Written informed consent was obtained from the patient for publication of this case report and accompanying images. A copy of the written consent is available for review by the Editor-in-Chief of this journal on request.

#### Author's contribution

ZA: Data collection, writing the manuscript, and critical review of final draft.

RA: Writing the manuscript and critical review of final draft.

MS: Writing the manuscript and critical review of final draft.

YA: Study concept, writing the manuscript and critical review of final draft (Guarantor).

#### Registration of research studies

N/A.

#### Guarantor

Yousef Alrashidi.

#### Provenance and peer review

Not commissioned, externally peer-reviewed.

#### References

- [1] H. Bergstrand, Über Eine Eigenartige, Wahrscheinlich Bisher Nicht Beschriebene Osteoblastische Krankheit In Den Langen Knochen Der Hand Und Des Fusses, *Acta Radiol. os-11* (6) (1930) 596–613.
- [2] P. Kitsoulis, G. Mantellos, M. Vlychou, Osteoid osteoma, *Acta Orthop. Belg.* 72 (2) (2006) 119–125.
- [3] D.N. Hakim, T. Pelly, M. Kulendran, J.A. Caris, Benign tumours of the bone: a review, *J. Bone Oncol.* 4 (2) (2015) 37–41.
- [4] M.H. Ebrahimzadeh, H. Ahmadzadeh-Chabock, A.R. Ebrahimzadeh, Osteoid osteoma: a diagnosis for radicular pain of extremities, *Orthopedics* 32 (11) (2009) 821.
- [5] F.A. Kaempffe, Osteoid osteoma of the coracoid process. Excision by posterior approach. A case report, *Clin. Orthop. Relat. Res.* (301) (1994) 260–262.
- [6] F. Franceschi, A. Marinozzi, R. Papalia, U.G. Longo, G. Gualdi, E. Denaro, Intra- and juxta-articular osteoid osteoma: a diagnostic challenge, *Arch. Orthop. Trauma Surg.* 126 (10) (2006) 660–667.
- [7] A.M. Kelly, R.M. Selby, E. Lumsden, S.J. O'Brien, M.C. Drakos, Arthroscopic removal of an osteoid osteoma of the shoulder, *Arthroscopy* 18 (7) (2002) 801–806.
- [8] E.A. Malavolta, J.H. Assunção, D.C.S. Rebolledo, M.E.C. Gracitelli, L.F.M. Correia, A.A. Ferreira Neto, et al., Osteoid osteoma of the glenoid: arthroscopic treatment, *Orthop. Traumatol. Surg. Res.* 101 (8) (2015) 977–980.
- [9] R.A. Agha, M.R. Borrelli, R. Farwana, K. Koshy, A.J. Fowler, D.P. Orgill, The SCARE 2018 statement: updating consensus Surgical CAse REport (SCARE) guidelines, *Int. J. Surg.* 60 (2018) 132–136.
- [10] R. Mosheiff, M. Liebergall, I. Ziv, G. Amir, D. Segal, Osteoid osteoma of the scapula. A case report and review of the literature, *Clin. Orthop. Relat. Res.* (262) (1991) 129–131.
- [11] Y. Ishikawa, K. Okada, N. Miyakoshi, S. Takahashi, Y. Shimada, E. Itoi, et al., Osteoid osteoma of the scapula associated with synovitis of the shoulder, *J. Shoulder Elbow Surg.* 14 (3) (2005) 329–332.
- [12] H.H. Pourfeizi, J.G. Sales, A. Elmi, A. Tabrizi, Osteoid osteoma of a scapula: a case report in a 34 years old woman, *Med. J. Islam. Repub. Iran* 26 (3) (2012) 143–146.
- [13] O. Poyanli, K. Unay, K. Akan, K. Ozkan, D. Temiz, Subchondral osteoid osteoma of the glenoid, *Chir. Organi Mov.* 93 (Suppl. 1) (2009) S79–81.
- [14] D. Bozic, M. Josipovic, I. Bohacek, T. Smoljanovic, I. Bojanic, Osteoid osteoma of the coracoid process: case report with literature review, *Acta Clin. Croat.* 55 (3) (2016) 505–509.
- [15] S. Akhlaghpour, A. Tomasian, A. Arjmand Shabestari, M. Ebrahimi, M.R. Alinaghizadeh, Percutaneous osteoid osteoma treatment with combination of radiofrequency and alcohol ablation, *Clin. Radiol.* 62 (3) (2007) 268–273.
- [16] D. Motamedi, T.J. Learch, D.N. Ishimitsu, K. Motamedi, M.D. Katz, E.W. Brien, et al., Thermal ablation of osteoid osteoma: overview and step-by-step guide, *Radiographics* 29 (7) (2009) 2127–2141.
- [17] P.S. Ghosh, S. Mitra, M. Moodley, Pearls & oysters: osteoid osteoma of the scapula masquerading as neuralgic amyotrophy, *Neurology* 79 (2) (2012) e7–9.
- [18] D. AlGhoozi, H. Goma, R. Awad, F. Alkhalifa, Osteoid osteoma of the base of the coracoid process – a case report, *Int. J. Surg. Case Rep.* 66 (2020) 162–164.
- [19] M.C. Glanzmann, S. Hinterwimmer, K. Woertler, A.B. Imhoff, Osteoid osteoma of the coracoid masked as localized capsulitis of the shoulder, *J. Shoulder Elbow Surg.* 20 (8) (2011) e4–7.
- [20] A. Ogose, F.H. Sim, M.I. O'Connor, K.K. Unni, Bone tumors of the coracoid process of the scapula, *Clin. Orthop. Relat. Res.* (358) (1999) 205–214.
- [21] R.S. Iyer, T. Chapman, F.S. Chew, Pediatric bone imaging: diagnostic imaging of osteoid osteoma, *Am. J. Roentgenol.* 198 (5) (2012) 1039–1052.
- [22] B.G. Lee, N.S. Cho, Y.G. Rhee, Unusual shoulder synovitis secondary to an osteoid osteoma without a nidus in the coracoid process: delayed appearance of a nidus, *J. Orthop. Sci.* 15 (6) (2010) 825–828.

#### Open Access

This article is published Open Access at [sciencedirect.com](https://www.sciencedirect.com). It is distributed under the [IJSCR Supplemental terms and conditions](https://creativecommons.org/licenses/by/4.0/), which permits unrestricted non commercial use, distribution, and reproduction in any medium, provided the original authors and source are credited.