

An Assessment of the Medial Angle of Inserted Subaxial Cervical Pedicle Screw during Surgery: Practical Use of Preoperative CT Scanning and Intraoperative X-rays

Hong Bum KIM,¹ Moon Kyu LEE,³ Young-Seok LEE,⁶ Jun-Young SOHN,⁵ Sang Ku JUNG,⁴ and Jin Hoon PARK²

¹Department of Neurological Surgery, Asan Medical Center, University of Ulsan College of Medicine, Seoul, Korea;

²Department of Neurological Surgery;

³Department of Neurology; ⁴Department of Emergency Medicine;

⁵Department of Anaesthesiology, Gangneung Asan Hospital, University of Ulsan College of Medicine, Gangneung, Korea;

⁶Department of Neurological Surgery, Gyeongsang National University School of Medicine, Jinju, Korea

Abstract

The most important factor for cervical pedicle screw placement (CPS) is creating a sufficient medial angle. We aimed to know the medial angle of the inserted subaxial CPS during surgery using intraoperative AP X-rays. From March 2012 to September 2014, we performed posterior cervical fusions using CPS on 75 patients, including a total of 389 CPS insertions. Using preoperative CT scanning, we determined the θ_{lat} (i.e., an angle between a vertical line and a line to connect the planned entry point and the axial middle point of the pedicle) and θ_{med} (i.e., an angle between a vertical line and a line to connect a new medial entry point and the axial middle point of the pedicle; this angle was regarded as minimally acceptable and a safe medial angle). The actual inserted medial angle (θ_{ins}) was checked and we determined whether it was between the θ_{med} and θ_{lat} in the accurately placed CPS, and not in the laterally violated CPS. We measured the horizontal distance of the CPS body (l ; using an intraoperative AP X-ray). If the actual screw length (L) was known, we could calculate the medial angle (θ_{AP}) as $\sin^{-1} l / L$. We checked the θ_{AP} and θ_{ins} for all of the same levels. Intra- and inter-observer agreement was analyzed. Among 368 accurately inserted CPSs, we found that 360 of the θ_{ins} values were greater than or equal to the θ_{med} on the same level ($P < 0.001$). The intra-observer agreements were 0.781 and 0.847. The inter-observer agreements were 0.917 and 0.949. It was important that θ_{ins} was greater than or equal to the θ_{med} . Our suggested formula, $\theta_{\text{AP}} = \sin^{-1} l / L$, seems to be useful for predicting the medial angle of the inserted CPS and for comparing it with θ_{med} during surgery based on an AP X-ray and preoperative CT scan.

Key words: cervical spine, cervical pedicle screw, medial angle, AP X-ray, CT scan

Introduction

Several studies have demonstrated the biomechanical superiority of cervical pedicle screw placement (CPS). Despite its biomechanical benefits, possible neurovascular complications and technical difficulties remain a great concern with this procedure.^{1–6} According to previous reports, most pedicle perforations occur in the lateral direction, which might cause injury to the vertebral artery (VA).^{7–9} These observations indicate

that the most important factor for CPS is creating a sufficient medial angle. To identify a sufficient medial angle for a CPS, we have focused previously on the interpretation of intraoperative anterior–posterior (AP) radiographical images after screw insertion.⁸

We previously showed the five safety steps for CPS, which were 1) the planning of the screw entry point using the preoperative CT scan, 2) the achievement of enough of a medial angle for screw insertion through the use of a curved pedicle probe, 3) the ability to detect pedicle breach with a ball tip probe, 4) the proper conversion to a lateral

mass screw when a breech is felt, and 5) the ability to properly interpret the intraoperative AP X-ray images after screw insertion. The final safety step indicates the last chance to remove or reposition a misplaced CPS. We recommended that a screw tip should be medial to a point located laterally to the midline by an amount of one-quarter of the distance from the midline to the lateral border of the lateral mass on the AP X-ray. Because we usually used 28–30 mm length screws in the majority of patients in previous series, the above recommendation was useful.^{8,9)} However, when smaller length screws below 28 mm were used, due to the CPS with the maximally permissible small medial angle, the presence of a previous anterior instrument, an anterior column unstable fracture, the lack of enough longer screw preparation, or small-sized vertebra, we couldn't apply the above suggestion. In addition, not every surgeon uses a 28–30 mm length screw like ours.³⁾ This reason led us to find a more widely applicable method, thereby resulting in us analyzing our retrospective data. Herein, we aimed to suggest a more advanced and sophisticated method to identify a sufficient convergence during surgery using preoperative computed tomography (CT) scans and intraoperative AP X-rays.

Materials and Methods

Patient population and surgical technique

From March 2012 to September 2014, a single surgeon performed posterior cervical fusion surgeries using CPS on 75 consecutive patients (64 males, 11 females, mean age 56.5 years [range, 23–81]). The initial diagnoses were 40 trauma, 28 degenerative diseases, three discitis/osteomyelitis, three pathologic fractures, and one deformity. The trauma cases involved fracture and/or dislocation, and degenerative cases involved cervical spondylotic myelopathy, ossification of posterior longitudinal ligament, or foraminal stenosis. Preoperative computed tomography (CT; 1 mm slices) with angiography was performed in all patients. Pedicle screw insertion with a freehand technique was primarily considered if the outer diameter of the cervical pedicle was greater than 3.0 mm on an axial CT scan.

The entry point of the screw was determined as the notch level in the sagittal plane and medial to the lateral border of the superior articular process by an amount of one-quarter of its width; *i.e.*, lateral one-quarter facet point, in the axial plane. A small pilot hole was made at the predetermined entry point with a 1.8 mm diameter match-head type burr. A small, curved pedicle probe (2.5 mm diameter) was slowly inserted vertically into the global lamina plane

with a medial trajectory through the cortical hole, and the tip was placed at the thick medial cortical pedicle wall. The tip of the pedicle probe was then pushed medially with movement in an upward and downward direction to locate the cancellous channel of the pedicle. Upon locating the cancellous channel, the medially directed force of the probe led to an insertion depth of approximately 30 mm. After forming a track with the curved probe, ball tip probe palpation was performed. Next, a straight pedicle probe (2.5 mm diameter) was inserted to make the track wider and straighter. This process also increased the ease of subsequent ball tip probe insertion, tapping, and screw placement. The depth of the ball tip probe was measured after tapping, and screw length was determined according to its measurement. After tapping with a 3.5 mm diameter tap, a screw was inserted. Screw diameter ranging from 3.5 to 4.0 mm was selected based upon preoperative CT measurements from the axial images. During ball tip probe palpation after pedicle probe insertion or tapping, feedback that suggested incorrect placement of the screw led to abandonment of the CPS procedure and conversion to a lateral mass screw placement. A more detailed technical description including our abnormal ball tip palpation technique was described in the previous article.^{8,9)}

Following screw insertion, portable anterior posterior (AP) and lateral X-rays were performed. The lateral X-rays of C6 and C7 usually did not provide useful information due to the shoulder shadow; however, the AP X-rays were effective in providing confirmation of the screw position. For identifying enough of a medial angle of CPS, it was more important to achieve the true AP X-ray image during surgery. We carefully checked symmetrical bilateral pedicle and midline alignment of the spinous process, and a recheck of the X-ray was done unless true AP was identified.

Screw position analysis on CT scan

Within 5 days of surgery, postoperative CT scans in all patients were performed to identify the pedicle screw location. The breech rate was analyzed based on both the sagittal and axial planes. In the axial plane, lateral wall perforation was defined according to the following definition: Grade 1, perforation into the VA foramen with the external edge of the screw deviated out of the lateral pedicle, but not violating the largest diameter of the VA foramen; Grade 2, the screw laterally deviated into the largest diameter of the VA foramen, but not completely occluding it; or Grade 3, complete occlusion of VA foramen.^{8,9)}

Using the preoperative CT scan, we drew a single line (D_{lat}) on the pedicle level to connect our planned

entry point, which is at the lateral one-quarter facet point. We measured an angle (θ_{lat}) between D_{lat} and a vertical line to the ground. Then, we drew another line (D_{med}) on the pedicle level to connect a half facet point; *i.e.*, the medial entry point. We also measured an angle (θ_{med}) between D_{med} and a vertical line to the ground. If the distance of D_{med} was less than 26 mm, which we regarded as a minimally acceptable screw length without perforation of the anterior cortex, we moved above the new medial entry point slightly to the lateral side, and then drew the D_{med} again. We considered a safe medial angle to range from θ_{med} to θ_{lat} (Fig. 1A). Additionally, we measured the actual inserted angle of the pedicle screw (θ_{ins}) using a postoperative CT scan (Fig. 1B). We analyzed whether the θ_{ins} was between θ_{med} and

θ_{lat} in the accurately placed CPS, and not in the laterally violated CPS, using the Fisher's exact test.

Next, we measured the horizontal distance of the CPS body (I) on an intraoperative AP X-ray with a picture archiving and communication system (PACS) (PetaVision 2.1, Gangneung, Korea). To measure I correctly, achievement of a true AP image was important. After magnifying the AP image 2.5 times in the PACS to perform this delicate measurement, a mid-vertical line was drawn using the information of spinous and uncinete process location. Then, a lateral vertical line connecting the lateral border of lateral masses was also drawn parallel to the mid-vertical line. We also drew another medial vertical line crossing the screw tip and parallel to the mid-vertical and lateral vertical lines. The length of I was measured from the medial vertical line to the base of the screw shaft. Mid-point on the most highly dense area, which was intersected between the screw head and the base of the screw shaft, was used and regarded as the one of both ends of I (Fig. 2A).

If we knew the actual length of the screw (L), we could calculate the medial angle (θ_{AP}) using the inverse value of the sine function *i.e.*, $\theta_{AP} = \sin^{-1} I / L$ (Fig. 2B). The above inverse sine value can be calculated easily with a calculator in Microsoft Windows 7.0. If we select scientific calculator in the Mode menu and click the **Inv** button, we can easily find the **sin⁻¹** button. After measuring I and L and calculating I / L with the scientific calculator, pushing the **sin⁻¹** button shows us θ_{AP} value.

Thus, we determined the θ_{AP} for each inserted CPS based on the method described above, and compared it with the θ_{ins} for all of the same levels (Fig. 2A and C). Each of these θ_{AP} and θ_{ins} values were measured by two different spinal surgeons. Thus, we analyzed an inter-observer agreement in the θ_{AP} and θ_{ins} values with an interclass coefficient (ICC). In addition, we also analyzed an agreement between the different measurement methods such as θ_{AP} and θ_{ins} from each surgeon.

The surgical application of the above formula

Because we did not develop the above formula before 49 patients (non-formula group), we only depended on the four preceding safety steps for CPS of which the length was less than 28 mm. However, we could use the final safety step, an X-ray confirmation of screw position, for the other 26 patients (formula group) even in the shorter screw. We only used our new formula for assessing the position of the screw which was less than 28 mm (ranging from 14 mm to 26 mm). It was not necessary for us to apply our formula for screws which

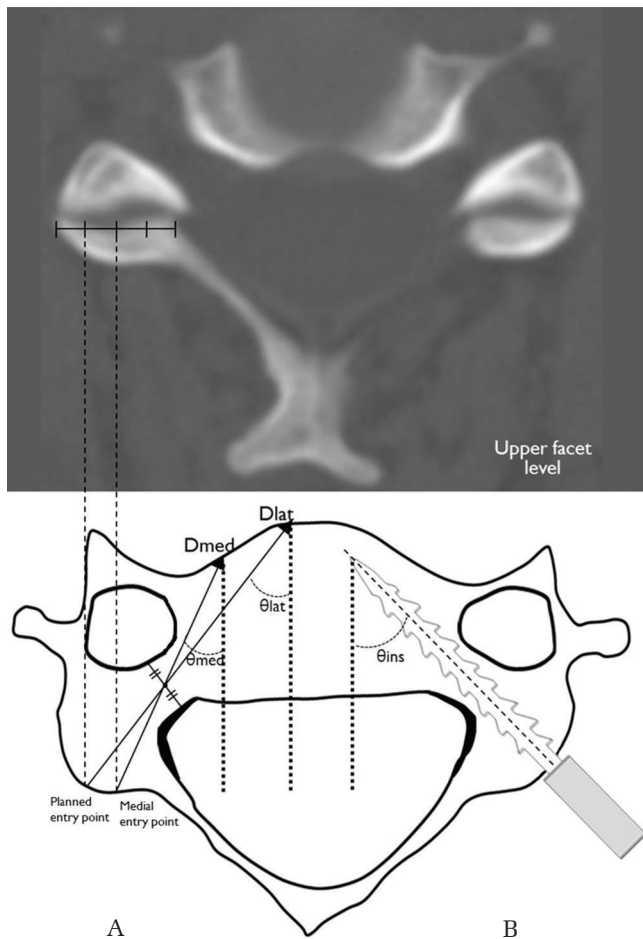


Fig. 1 (A) A line, D_{lat} , connected the planned entry point and the axial middle point of the pedicle, shown by preoperative axial CT imaging. θ_{lat} angle between D_{lat} and a vertical line to the ground. A line and D_{med} connect a new medial entry point and the axial middle point of the pedicle. θ_{med} , angle between D_{med} and a vertical line to the ground. (B) θ_{ins} , medial angle of the actually inserted CPS as assessed by postoperative CT imaging.

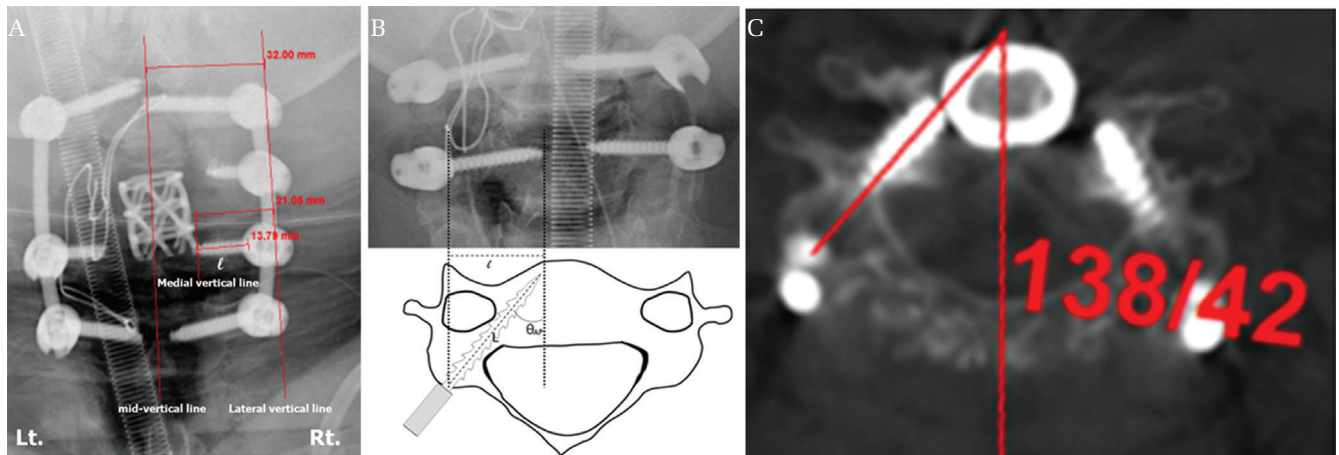


Fig. 2 (A) Intraoperative AP X-ray of 66-year-old female patient with infective spondylitis on C4-5 level. Because of the anterior cage, the use of a longer screw seems to be impossible during CPS on the C3-4-5-6 level. The length of the screw used was 20 mm on the right C5 level. If we apply the previous AP X-ray interpretation method on the right C5 screw (i.e., the screw tip should be medial to a point located laterally to the midline by an amount of one-quarter of the distance from the midline to the lateral border of the lateral mass on AP X-ray), this screw should be regarded as out of pedicle (i.e., $21.05/32 = 0.66 < 0.75$). This misinterpretation led us to develop another widely applicable method. After magnifying the AP image 2.5 times in the PACS to perform the delicate measurement, a mid-vertical line is drawn using the information of spinous and uncinete process location. Then, a lateral vertical line connecting the lateral border of lateral masses is also drawn, parallel to the mid-vertical line. We also draw another medial vertical line crossing the screw tip, and parallel to the mid-vertical and lateral vertical lines. The CPS body length of I is measured from the medial vertical line to the base of the screw shaft. Mid-point on the most highly dense area, which is intersected between the screw head and the base of the screw shaft, is used and regarded as the lateral end of I . (B) Horizontal distance of the CPS body (I) as shown by intraoperative AP X-ray. If the actual length of a screw (L) is known, the medial angle (θ_{AP}) can be calculated using the inverse value of the sine function, $\theta_{AP} = \sin^{-1} I / L$. (C) The postoperative axial CT scan of the same patient of Figure 2-A on the C5 level shows an accurate position of CPS, and θ_{ins} of the right side screw is 42 degrees. If we calculate θ_{AP} from Figure 2-A, $\theta_{AP} = \sin^{-1} I / L = \sin^{-1} (13.79/20) = 43.5$. Because this θ_{AP} was much bigger than θ_{med} (34°), we regarded this screw as safe during the operation and identified nearly the same value with θ_{ins} (42°) after surgery.

ranged from 28 to 30 mm, because we could identify the screw position with the previously described fifth step. Thus, we compared the accuracy rate of those shorter screws between the formula and non-formula group.

Results

There were no patients who showed symptoms related to VA injury or stenosis. There was one patient with a superficial wound infection as a surgical morbidity. The total number of planned CPS insertions was 417, and a lateral mass screw conversion occurred for 27 screws (4, 10, 8, and 5 on C3, C4, C5, and C6, respectively), as well as one conversion into a laminar screw on C7. Thus, the conversion rate was 6.71% ($28/417$) and the total number of actually inserted CPSs was 389 (48, 71, 88, 106, and 76 on C3, C4, C5, C6, and C7, respectively). A total of 21 lateral wall violations constituted 16 grade I (0, 6, 5, 2, and 3 on C3, C4,

C5, C6, and C7, respectively) and five grade II violations (0, 2, 1, 1, and 1 on C3, C4, C5, C6, and C7, respectively). There was no superior or inferior wall violation. The accuracy rate was 94.6% ($368/389$) and the results were similar to those we reported previously.^{8,9)}

Among the 368 accurately inserted CPSs in our current study series, we identified 360 θ_{ins} that were greater than or equal to θ_{med} on the same level. Although the θ_{ins} value for eight screws was less than the θ_{med} value, they did not violate the lateral pedicle wall. Among 21 screws that violated the lateral wall, we also identified 19 θ_{ins} values that were less than the θ_{med} value. Although the θ_{ins} values of two screws were greater than that of θ_{med} , they violated the lateral pedicle wall (Fig. 3). The relation between θ_{ins} and θ_{med} according to the accuracy of CPS showed statistical significance ($P < 0.001$, Table 1).

The ICC of all surgical levels which indicated the agreement between θ_{AP} and θ_{ins} in surgeon A was

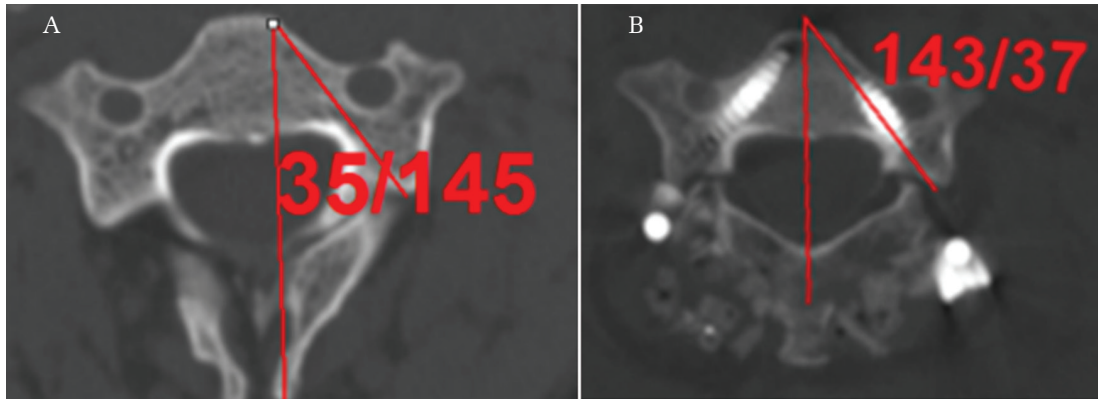


Fig. 3 (A) Preoperative CT scan of 32-year-old male patient shows θ_{med} is 35 degrees on the left C3 level. (B) Postoperative CT scan shows grade I lateral wall violation despite θ_{ins} is 37 degrees and bigger than θ_{med} . Compared to right side screw, the left side screw seems to be thicker (i.e., 4.0 mm diameter screw). We believe that we could avoid this small amount of lateral violation, if we would use thinner screws (i.e., 3.5 mm diameter screw).

Table 1 The relation between θ_{ins} and θ_{med} according to the accuracy of CPS

	Number of PS with $\theta_{ins} \geq \theta_{med}$	Number of PS with $\theta_{ins} < \theta_{med}$	P values
Accurately located pedicle screw (n = 368)	360	8	
Laterally misplaced pedicle Screws (n = 21)	2	19	<0.001

CPS: Cervical pedicle screw placement, PS: pedicle screw.

Table 2 The agreement between θ_{AP} and θ_{ins}

	Kappa value of surgeon A		Kappa value of surgeon B	
	Right	Left	Right	Left
C3	0.889	0.776	0.797	0.565
C4	0.714	0.811	0.764	0.751
C5	0.712	0.762	0.835	0.831
C6	0.76	0.733	0.759	0.87
C7	0.816	0.716	0.9	0.826
Total	0.781		0.847	

0.781 (Table 2). That value of surgeon B was 0.847. The ICC of all surgical levels which indicated the agreement between surgeon A and B in θ_{AP} was 0.917. That value of θ_{ins} was 0.949 (Table 3).

A total of 53 screws which were less than 28 mm were used. There were 39 screws in the non-formula group, and 14 screws were used in the formula group. Although there were seven (Six grade I and one grade II) screws which laterally violated in the

Table 3 The agreement between surgeon A and B

	Kappa value of θ_{AP}		Kappa value of θ_{ins}	
	Right	Left	Right	Left
C3	0.831	0.869	0.947	0.945
C4	0.952	0.89	0.938	0.952
C5	0.944	0.919	0.933	0.951
C6	0.894	0.898	0.919	0.957
C7	0.891	0.907	0.928	0.912
Total	0.917		0.949	

non-formula group, there was no violated screw in the formula group.

Discussion

To identify a sufficient medial angle for a screw, we previously showed that the limit of acceptability in a screw position could be designated as follows: on an AP X-ray, the screw tip should be medial to a point located laterally to the midline by an amount of one-quarter of the distance from the midline to the lateral border of the lateral mass.⁸⁾ Because we usually used a 28–30 mm length screw, it may be proper to use such an interpretation method. However, it would not be proper if we had used a pedicle screw with a much smaller length. Actually, we could not apply the above interpretation in 39 screws of 49 patients, thus we could not help depending on only preceding four safety steps. Although we could reposition four screws of lengths of 28–30 mm according to our previous X-ray interpretation method, this application was impossible for the shorter screws; and resulted in seven lateral wall violations, which was a bigger

rate (7/39, 17.9%) compared to our overall violation rate (5.4%). For that reason, we struggled to find a widely applicable method that would result in no violation in the 14 shorter screws ranging from 14 to 26 mm. However, we agree that our learning curve also contributes to reducing such a violation to a certain degree. After feeling that our new AP X-ray interpretation method was useful, this retrospective study was designed to show its wide applicability among all screws used.

Thus, we aimed in our present study to determine the acceptable range of a safe medial angle using a preoperative CT scan; and to calculate the medial angle of the inserted CPS using AP X-rays, despite the different CPS lengths used in surgery. If the medial angle calculated using an AP X-ray was less than an acceptable safe medial angle range determined by a preoperative CT scan, we could remove the inserted CPS or reposition it. We found that 360 θ_{ins} values among 368 accurate CPS insertions were greater than or equal to the θ_{med} on the same level. To identify a sufficient medial angle, we believe that the relationship between θ_{ins} and θ_{lat} is not important. We also agree that some possible errors can exist, and that the other eight of our CPS insertions were accurate, despite having a smaller θ_{ins} value than the θ_{med} value. This phenomenon can occur when the pedicle diameter is much bigger than the screw diameter, or when the inserted CPS penetrates the anterior cortex much more than in our preoperative prediction. We assumed that the smallest acceptable CPS length was 26 mm in our determination of the medial entry point, and we plotted the D_{med} and θ_{med} . Thus, we argue that a more medially located entry point and penetration of the anterior cortex, which is located more laterally than preoperatively near the expected anterior cortical point, can achieve an accurate CPS placement with a smaller medial angle than the preoperatively expected angle. Despite having a θ_{ins} value that was greater than the θ_{med} value, two screws violated the lateral pedicle wall. These two events occurred when we used a 4.0 mm diameter CPS and it seemed not to violate the lateral wall if it used the 3.5 mm diameter screw. When we determined θ_{med} and θ_{lat} , we used a thin line for drawing D_{med} and D_{lat} without considering the screw thickness. This means that a much thicker line may make the θ_{med} bigger, because thicker D_{med} should be close to the axial pedicle axis. In addition, we could achieve the maximal pedicle wall expansion, when we insert a screw through the axial pedicle axis. According to those two reasons, we believe

that a CPS with a greater diameter may require a greater medial angle than θ_{med} .

A previous article also used an AP X-ray for assessing the accurate screw position during surgery. They suggested that the screw tip should locate medially to the uncinated process and the AP distance adjusted according to the different screw length.¹⁰⁾ We agree with their opinion and believe that the above method is reasonable and useful. However, their adjustment process seems to us more complex to follow. We believe that our method is more simple and straightforward and showed higher inter- and intra-observer agreement.

The ICC (0.781 of surgeon A and 0.847 of surgeon B) between θ_{ins} and θ_{AP} indicate that we can easily apply the θ_{AP} instead of the θ_{ins} only using X-rays during surgery. In addition, the measurements of θ_{AP} and θ_{ins} by two different surgeons showed high agreement (ICC: 0.917 and 0.949). However, the Kappa value of surgeon B on the left side C3 level was only 0.565; that seems to be quite lower than others (Table 2). We agree that the measurement error would possibly be made, especially during the I measurement and this might result in an incorrect θ_{AP} , although we magnified the AP image 2.5 times to reduce this error. In addition, we should consider the possibility that lateral misplacement could occur despite having a θ_{ins} value that was greater than the θ_{med} value, even though it was a low rate (2/362). Because of those limitations, we did not only depend on this fifth step, but considered X-ray confirmation as one of five safety steps. Although our X-ray identification methods can give us objective information even in the short-length screw, all five safety steps should be kept and regarded as equally important during a CPS procedure. Then, we believe that this fifth step may be useful and a supplementary measurement tool for safe CPS procedure.

Thus, the determination of a minimally acceptable medial angle (θ_{med}) using a preoperative CT scan and calculation θ_{AP} using AP X-rays during surgery can lead us to know whether our inserted CPS has enough of a medial angle even in the various screw lengths at less cost. We believe that its usage with more cases will yield more accurate and reliable information.

Conclusion

It was important that the actually inserted medial angle was greater than or equal to the θ_{med} with 97.8% (360/368) accuracy. Our suggested formula, $\theta_{\text{AP}} = \sin^{-1} I / L$, seems to be useful for predicting the medial angle of the inserted CPS and for comparing

it with θ_{med} during surgery based on an AP X-ray and preoperative CT scan. However, measurement error could happen which seems to be our study limitation. Thus, we should not depend on this fifth step only, but consider the X-ray confirmation as one of five safety steps.

Conflicts of Interest Disclosure

The authors have no financial interest or ethical conflicts to disclose.

References

- 1) Johnston TL, Karaikovic EE, Lautenschlager EP, Marcu D: Cervical pedicle screws vs. lateral mass screws: uniplanar fatigue analysis and residual pullout strengths. *Spine J* 6: 667–672, 2006
- 2) Kotani Y, Abumi K, Ito M, Minami A: Improved accuracy of computer-assisted cervical pedicle screw insertion. *J Neurosurg* 99(3 Suppl): 257–263, 2003
- 3) Abumi K, Ito M, Sudo H: Reconstruction of the subaxial cervical spine using pedicle screw instrumentation. *Spine (Phila Pa 1976)* 37: E349–E356, 2012
- 4) Abumi K, Shono Y, Ito M, Taneichi H, Kotani Y, Kaneda K: Complications of pedicle screw fixation in reconstructive surgery of the cervical spine. *Spine (Phila Pa 1976)* 25: 962–969, 2000
- 5) Kast E, Mohr K, Richter HP, Börm W: Complications of transpedicular screw fixation in the cervical spine. *Eur Spine J* 15: 327–334, 2006
- 6) Yoshimoto H, Sato S, Hyakumachi T, Yanagibashi Y, Masuda T: Spinal reconstruction using a cervical pedicle screw system. *Clin Orthop Relat Res* 431: 111–119, 2005
- 7) Yoshimoto H, Sato S, Hyakumachi T, Yanagibashi Y, Kanno T, Masuda T: Clinical accuracy of cervical pedicle screw insertion using lateral fluoroscopy: a radiographic analysis of the learning curve. *Eur Spine J* 18: 1326–1334, 2009
- 8) Park JH, Jeon SR, Roh SW, Kim JH, Rhim SC: The safety and accuracy of freehand pedicle screw placement in the subaxial cervical spine: a series of 45 consecutive patients. *Spine (Phila Pa 1976)* 39: 280–285, 2014
- 9) Park JH, Roh SW, Rhim SC: A single-stage posterior approach with open reduction and pedicle screw fixation in subaxial cervical facet dislocations. *J Neurosurg Spine* 23: 35–41, 2015
- 10) Lee SH, Kim KT, Suk KS, Lee JH, Son ES, Kwack YH, Oh HS: Assessment of pedicle perforation by the cervical pedicle screw placement using plain radiographs: a comparison with computed tomography. *Spine (Phila Pa 1976)* 37: 280–285, 2012

Address reprint requests to: Jin Hoon Park, MD, PhD,
Department of Neurological Surgery, Gangneung Asan
Hospital, University of Ulsan College of Medicine,
Gangneung, Korea.
e-mail: grandblue@gnah.co.kr