

The McKittrick–Wheelock syndrome: a rare cause of curable diabetes

Benjamin G Challis¹, Chung Thong Lim¹, Alison Cluroe², Ewen Cameron³ and Stephen O’Rahilly¹

¹Metabolic Research Laboratories, Wellcome Trust-MRC Institute of Metabolic Science, Cambridge, UK, Departments of ²Histopathology and ³Gastroenterology, Cambridge University Hospitals Foundation Trust, Addenbrooke’s Hospital, Cambridge, UK

Correspondence
should be addressed
to B G Challis
Email
bc340@medschl.cam.ac.uk

Summary

McKittrick–Wheelock syndrome (MWS) is a rare consequence of severe dehydration and electrolyte depletion due to mucinous diarrhoea secondary to a rectosigmoid villous adenoma. Reported cases of MWS commonly describe hypersecretion of mucinous diarrhoea in association with dehydration, hypokalaemia, hyponatraemia, hypochloraemia and pre-renal azotemia. Hyperglycaemia and diabetes are rarely reported manifestations of MWS. Herein we describe the case of a 59-year-old woman who presented with new-onset diabetes and severe electrolyte derangement due to a giant rectal villous adenoma. Subsequent endoscopic resection of the tumour cured her diabetes and normalised electrolytes. This case describes a rare cause of ‘curable diabetes’ and indicates hyperaldosteronism and/or whole-body potassium stores as important regulators of insulin secretion and glucose homeostasis.

Learning points:

- McKittrick–Wheelock syndrome (MWS) is typically characterised by the triad of pre-renal failure, electrolyte derangement and chronic diarrhoea resulting from a secretory colonic neoplasm.
- Hyperglycaemia and new-onset diabetes are rare clinical manifestations of MWS.
- Hyperaldosteronism and/or hypokalaemia may worsen glucose tolerance in MWS.
- Aggressive replacement of fluid and electrolytes is the mainstay of acute management, with definitive treatment and complete reversal of the metabolic abnormalities being achieved by endoscopic or surgical resection of the neoplasm.

Background

McKittrick–Wheelock syndrome (MWS) is a rare disorder characterised by severe fluid and electrolyte depletion secondary to mucous diarrhoea caused by large rectal tumours, most notably villous adenoma (1, 2, 3). Patients with MWS commonly present with diarrhoea, dehydration and symptoms associated with severe electrolyte depletion, particularly those related to hypokalaemia. Symptomatic hyperglycaemia and new-onset diabetes are very rare manifestations of

MWS. Herein we report a rare case of MWS in a female patient with new-onset diabetes as the initial presentation.

Case presentation

A 59-year-old woman presented with a 1-week history of increasing lethargy, polyuria and polydipsia in the absence of acute weight loss. A review of systems was significant for diarrhoea that had subjectively



resolved 1 week before presentation. The patient had no significant personal or family medical histories, and she took no regular medications. Clinical examination revealed a lean female (BMI 23.3 kg/m²) who was clinically dehydrated, normotensive (125/81 mmHg) and tachycardic (110 beats/min) with reduced power on dorsiflexion of the right ankle.

Investigation

Initial biochemical investigations revealed hyperglycaemia (plasma glucose 27.2 mmol/L) without acidosis or ketosis (blood ketones 0.2 mmol/L), elevated C-peptide (2019 pmol/L) and HbA1c (105 mmol/mol normal reference range (NR) 35–45)). Additional biochemical investigations revealed hyponatraemia (117 mmol/L (NR: 135–145)), hypokalaemia (2.7 mmol/L (NR: 3.5–5.3)) and renal impairment (creatinine 124 µmol/L (NR: 62–115)) (Table 1). Anti-islet and anti-GAD antibody titres were negative. Thyroid function, a short Synacthen test and haematological indices were normal. Electrocardiogram revealed sinus tachycardia and normal QT_c interval.

A provisional diagnosis of type 2 diabetes with diabetic radiculopathy was made, and following intravenous rehydration with potassium-supplemented isotonic saline, basal-bolus insulin therapy (Novorapid–Levemir combination) was commenced (20 units daily).

On review, 3 weeks later, glycaemic control had improved with insulin therapy; however, electrolyte and renal derangement (sodium 124 mmol/L, potassium 3.3 mmol/L,

creatinine 164 µmol/L) persisted despite oral sodium and potassium supplementation. At that time, paired serum and urine osmolalities were 282 and 493 mOsm/kg respectively, and spot urine sodium was 6.2 mmol/L.

Clinical examination revealed progressive neurology with reduced power on dorsiflexion elicited in both right and left ankles prompting urgent magnetic resonance imaging (MRI) of her lumbosacral spine, and the result was normal. Immunoglobulins, vitamin B₁₂, autoantibodies (antinuclear antibody (ANA), anti-neutrophil cytoplasmic antibody (ANCA), anti-extractable nuclear antigens (ENA), DNA, anti-centromere) and complement (C3, C4) levels were all within the normal range. When reviewed 1 month later, however, the neurological and electrolyte abnormalities had completely resolved with stable capillary blood glucose measurements (6.0–11.0 mmol/L) achieved with progressively less total daily insulin that was eventually weaned completely.

Four months later, however, the patient re-presented with lethargy and pre-syncopal episodes associated with mucinous diarrhoea and weight loss. She had orthostatic hypotension and tachycardia (heart rate 110 beats/min), but physical examination, including digital rectal examination, was otherwise unremarkable. Laboratory investigations revealed hyponatraemia (112 mmol/L), hypokalaemia (2.6 mmol/L), hyperglycaemia (13.8 mmol/L) and renal impairment (creatinine 221 µmol/L; urea 41.4 mmol/L). Renin and aldosterone levels were both profoundly elevated at 267 U/L (NR: 5.4–60) and 2676 pmol/L (NR: 100–450) respectively. Fasting gut hormones were normal. The patient

Table 1 Sequential biochemical results. Normal reference ranges (NR) are indicated.

	Normal reference range	Event				
		Initial presentation (0 week)	Follow up (3 weeks)	Readmission (16 weeks)	Follow up (post-resection; 20 weeks)	Follow up (36 weeks)
Sodium (mmol/L)	135–145	117	124	112	138	140
Potassium (mmol/L)	3.5–5.3	2.7	3.3	2.6	3.5	4.1
Creatinine (µmol/L)	62–115	124	164	221	84	83
Urea (mmol/L)	2.5–7.8	9.3	20.2	41.4	–	8.7
Bicarbonate (mmol/L)	21–32	28.5	21	22.8	–	29
Chloride (mmol/L)	95–106	–	–	71	–	–
Corrected calcium (mmol/L)	2.20–2.60	–	2.23	2.13	2.17	–
Phosphate (mmol/L)	0.80–1.50	–	1.27	1.45	0.92	–
Magnesium (mmol/L)	0.70–1.00	–	1.14	1.39	–	–
Serum osmolality (mOsm/kg)	280–300	–	282	280	–	–
Urine sodium (mmol/L)	–	–	6.2	5.4	–	–
Glucose (mmol/L)	–	27.2	11.5	13.8	5.8	–
HbA1c (mmol/mol)	35–45	105	–	63	–	45
C-peptide (pmol/L)	174–960	2019	–	–	–	–
Renin (mU/L)	5.4–60	–	–	267	–	24
Aldosterone (pmol/L)	100–450	–	–	2676	–	351

responded to aggressive volume resuscitation with isotonic saline supplemented with potassium, and basal-bolus insulin was recommenced.

To further investigate diarrhoea and weight loss, abdominal computed tomography (CT) was performed to survey for occult malignancy; this revealed a large, soft tissue mass in a dilated rectum (Fig. 1). Subsequent MRI confirmed the presence of a polypoid mass, arising from the right lateral wall of the rectum with no evidence of adjacent adenopathy or local invasion. Full colonoscopy revealed a 10 cm hemicircumferential granular laterally spreading tumour, from which multiple biopsies were taken, arising 15 cm from the anal verge; the remaining colon was unremarkable. Histopathological examination diagnosed a tubulovillous adenoma with mainly moderate, low-grade dysplasia but focal high-grade dysplasia at the base of some villous formations with no features suggestive of a neuroendocrine neoplasm (Fig. 2).

Treatment

The patient underwent staged piecemeal endoscopic mucosal resection to debulk the polyp and followed by completion transanal endoscopic microsurgery (TEMS).

Outcome and follow-up

Following endoscopic resection of the villous adenoma, electrolytes, renal function and glycaemic control (HbA1c 45 mmol/L) have remained normal, and glucose-lowering therapy is no longer required. Repeat endoscopic

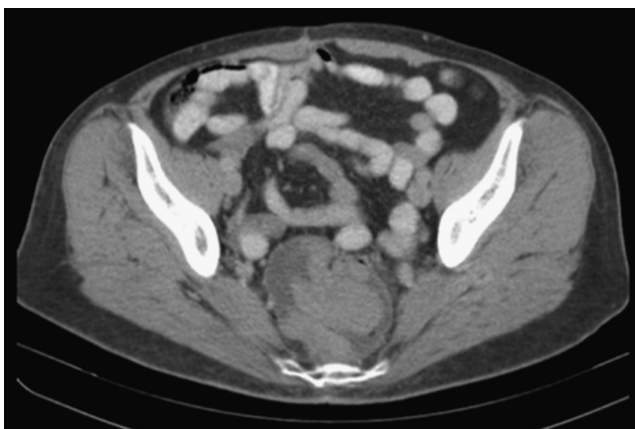


Figure 1
CT of the pelvis demonstrates an 8 cm polypoid mass arising from the right lateral wall of the rectum. The tumour arises 15 cm from the anal verge, and abnormal mesorectal lymph nodes are absent. Appearances are in keeping with a villous adenoma.

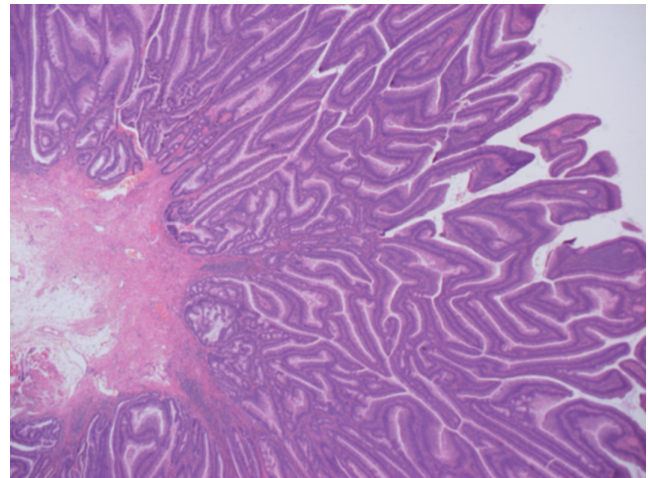


Figure 2
Hematoxylin and eosin-stained photomicrograph shows a tubulovillous adenoma exhibiting moderate to low-grade dysplasia (10× magnification). Tumour invasion is not identified.

investigations revealed recurrence of the sessile polyp, which was managed with further endoscopic mucosal resection. To date, histopathological examination of all biopsied tissue has failed to identify the evidence of invasive malignancy or dysplasia. The patient remains under colonoscopic surveillance.

Discussion

Villous adenomas are neoplasms with malignant potential most commonly found in the rectum and rectosigmoid. The majority of patients with colonic adenomatous polyps are asymptomatic; however, larger polyps (>1 cm) may present with mild gastrointestinal symptoms or rectal bleeding. Rarely, large villous adenomas of the rectum or rectosigmoid cause secretory mucinous diarrhoea characterised by massive fluid loss, acute renal failure and electrolyte depletion due to the secretory capacity of the tumour coupled with minimal absorptive capacity of normal colonic mucosa due to reduced surface area distal to the adenoma. Hyperglycaemia and diabetes are rare manifestations of MWS, and to date, few cases of MWS in association with new-onset diabetes have been reported (4, 5, 6). In these reports, however, ascertaining whether hyperglycaemia was truly a manifestation of MWS is complicated by administration of high-dose glucocorticoids to affected subjects for possible adrenal insufficiency before hyperglycaemia was recognised. The case described herein provides a rare example of diabetes mellitus as the initial presenting feature of MWS in a glucocorticoid naïve patient.



In MWS, profound water and electrolyte derangement have been attributed to local tumoral secretion of prostaglandin E₂ (PGE₂) and/or cyclic mononucleotides. Indeed, indomethacin, an inhibitor of prostaglandin synthesis, has been shown to reduce rectal PGE₂ and rectal fluid loss in patients with secretory villous adenomas (7). The mechanisms underlying glucose intolerance in MWS, however, remain unclear, although some evidence suggests that a causal association with hyperaldosteronism and/or total body potassium depletion may exist.

The renin–angiotensin–aldosterone system (RAAS) is normally activated in response to hyponatraemia and/or intravascular volume depletion, two of the recognised pathological consequences of MWS exhibited in the case we describe. Classically, aldosterone-induced mineralocorticoid receptor (MR) activation stimulates sodium reabsorption in the distal nephron, although extra-renal effects are increasingly appreciated, including those that contribute to worsening glucose tolerance.

In a seminal publication, Conn first described the association of hyperaldosteronism with both impaired glucose tolerance and impaired insulin response to oral glucose administration (8). Several studies have subsequently confirmed these metabolic abnormalities in subjects with aldosterone-producing adenomas, which normalised following adrenalectomy (9, 10). Analyses of several cardiovascular drug trials have provided further clinical evidence that pharmacological blockade of the RAAS has beneficial effects on glucose homeostasis (9) and significantly reduces the incidence of new-onset diabetes (11). To date, numerous mechanisms have been proposed to explain the diabetogenic actions of aldosterone, which include direct effects on glucose-stimulated insulin secretion, impairment of insulin sensitivity in adipocytes and skeletal muscle and reduction of circulating insulin-sensitising adipokines such as adiponectin (12, 13, 14, 15). Collectively, these observations support the premise that in MWS, hyperaldosteronism, in response to profound fluid and sodium loss, may contribute to impaired glucose tolerance and explain the development of hyperglycaemia and diabetes mellitus seen in affected individuals. From the data presented here, however, we cannot exclude the possibility that the metabolic sequelae observed may, at least in part, be mediated through glucocorticoid receptor (GR) activation due to elevated plasma concentrations of aldosterone, a known GR agonist that does not normally display physiologically meaningful GR activity at normal plasma concentrations.

Hypokalaemia *per se* also has a diabetogenic effect and coexisting potassium depletion may confound

interpretation of the aforementioned studies. Indeed, Conn originally implicated aldosterone-induced hypokalaemia as the cause of impaired glucose tolerance in patients with PA; however, restoration of normokalaemia by potassium supplementation only partially reversed the metabolic abnormality (8). That total body potassium status alone may influence glucose homeostasis was demonstrated in a recent study in which patients with primary aldosteronism were found to have potassium levels that negatively correlated with 2 h plasma glucose levels in an oral glucose tolerance test (10). Moreover, thiazide-induced hypokalaemia results in diminished insulin secretion, and a meta-analysis of 29 studies involving 83 thiazide diuretic treatment arms found a significant correlation between the degree of diuretic-induced hypokalaemia and an increase in plasma glucose concentration (16). More recently, a randomised double-blind trial study has shown that the combination of amiloride, a potassium-sparing diuretic, with hydrochlorothiazide prevented glucose intolerance compared with treatment with either drug alone (17). Hypokalaemia has also been implicated as the cause of impaired glucose tolerance in Gitelman syndrome, an autosomal recessive renal tubulopathy characterised by hypokalaemic metabolic alkalosis, hypomagnesaemia, secondary hyperaldosteronism and normal blood pressure (18).

Potassium is an important intracellular cation that is involved in the transfer of high-energy phosphate required for ATP generation, which, in turn, promotes insulin secretion from pancreatic β -cells (8). Thus, hypokalaemia attenuates ATP generation, resulting in impaired insulin secretion, and several studies have demonstrated it to be of clinical significance in humans. For example, in healthy subjects rendered hypokalaemic and subjected to a glucose clamp, Rowe and colleagues found that potassium depletion was associated with impaired insulin secretion and did not impact upon tissue sensitivity (19). Similarly, β -cell responsiveness was diminished in subjects with thiazide-induced hypokalaemia compared with normokalaemic subjects (20). Finally, in subjects with chronic hypokalaemia, biologically less active proinsulin-like components constitute a greater proportion of the total circulating insulin than in normokalaemic subjects (21). Taken together, these observations support the notion that the diabetogenic effects of hypokalaemia are mediated through dysregulated insulin secretion and, in the context of MWS, may act in synergy with hyperaldosteronism to disrupt glucose homeostasis.



It is possible that other tumour-derived peptides may also contribute to the depletion syndrome and metabolic disturbances associated with MWS. For example, guanylin-related peptides, guanylin and uroguanylin, are poorly understood hormones that are secreted by the gastrointestinal tract, including goblet cells. In humans, they serve as potent regulators of intestinal salt and water homeostasis through activation of the guanylate cyclase C receptor (22). Similarly, insulin-like peptide 5 (INSL-5), a gut-derived peptide, which has recently been implicated in energy and glucose homeostasis, is secreted by enteroendocrine cells of the gastrointestinal tract, with highest levels being detected within the colorectum (23). At present, reliable analytical reagents to quantify circulating levels of these peptide hormones are not available; however, it is tempting to speculate that peptides such as these may have causal roles in disorders characterised by secretory diarrhoea and metabolic disturbance, including MWS.

Untreated secretant villous adenoma leads to a mortality of 100% (24). Initial clinical management should involve aggressive fluid resuscitation and correction of electrolyte and metabolic disturbances. Once the patient is stable, more definitive therapies such as endocavitary irradiation, endoscopic resection or surgical removal should be considered. Endoscopic resection is the preferred method if the tumour is amenable to this approach, depending on the size and location of the tumour. When endoscopic resection is not possible, conventional surgery or TEMS may be considered. In cases such as the one we describe, endoscopic resection may be used to reduce tumour volume before proceeding to conventional surgery or TEMS.

Tumour resection and adequate hydro-electrolyte replacement should lead to complete recovery from MWS, except in situations where the sequelae of MWS remain irreversible, such as chronic renal failure or cardiac events secondary to intravascular depletion and electrolyte imbalance. Although rare, it is important to consider MWS as a possible diagnosis in patients with chronic diarrhoea as it is a curable condition and a missed diagnosis may lead to an adverse clinical outcome.

Declaration of interest

The authors declare that there is no conflict of interest that could be perceived as prejudicing the impartiality of the research reported.

Funding

This research did not receive any specific grant from any funding agency in the public, commercial or not-for-profit sector.

Patient consent

Written informed consent was obtained from the patient for publication of this case report.

Author contribution statement

B G C, C T L, E C and S O R cared for the patient. A C provided histopathological input. B G C and C T L wrote the manuscript. All authors read and commented on the manuscript and approved the submitted version.

References

- 1 Older J, Older P, Colker J & Brown R 1999 Secretary villous adenomas that cause depletion syndrome. *Archives of Internal Medicine* **159** 879–880. (doi:10.1001/archinte.159.8.879)
- 2 McCabe RE, Kane KK, Zintel HA & Pierson RN 1970 Adenocarcinoma of the colon associated with severe hypokalemia: report of a case. *Annals of Surgery* **172** 970–974.
- 3 Lepur D, Klinar I, Mise B, Himbele J, Vranjican Z & Barsic B 2006 McKittrick-Wheelock syndrome: a rare cause of diarrhoea. *European Journal of Gastroenterology & Hepatology* **18** 557–559.
- 4 Bamford JK, Galbraith HJ & Pender BW 1965 Villous adenoma of the rectum with electrolyte depletion, diabetes and hypogonadism. *Postgraduate Medical Journal* **41** 186–189. (doi:10.1136/pgmj.41.474.186)
- 5 Eisenberg HL, Kolb LH, Yam LT & Godt R 1964 Villous adenoma of the rectum associated with electrolyte disturbance. *Annals of Surgery* **159** 604–610. (doi:10.1097/0000658-196404000-00021)
- 6 Surwilo J, Gruca Z, Starnawska M & Gorski J 1995 [Electrolyte disturbance and hyperglycemia in villous adenoma of the sigmoid colon-case report]. *Przegląd Lekarski* **52** 69–70.
- 7 Steven K, Lange P, Bukhave K & Rask-Madsen J 1981 Prostaglandin E₂-mediated secretory diarrhea in villous adenoma of rectum: effect of treatment with indomethacin. *Gastroenterology* **80** 1562–1566.
- 8 Conn JW 1965 Hypertension, the potassium ion and impaired carbohydrate tolerance. *New England Journal of Medicine* **273** 1135–1143.
- 9 Luther JM 2014 Effects of aldosterone on insulin sensitivity and secretion. *Steroids* **91** 54–60. (doi:10.1016/j.steroids.2014.08.016)
- 10 Hanslik G, Wallaschofski H, Dietz A, Riestler A, Reincke M, Allolio B, Lang K, Quack I, Rump LC, Willenberg HS, et al. 2015 Increased prevalence of diabetes mellitus and the metabolic syndrome in patients with primary aldosteronism of the German Conn's Registry. *European Journal of Endocrinology* **173** 665–675. (doi:10.1530/EJE-15-0450)
- 11 Al-Mallah M, Khawaja O, Sinno M, Alzohaili O & Samra AB 2010 Do angiotensin converting enzyme inhibitors or angiotensin receptor blockers prevent diabetes mellitus? A meta-analysis. *Cardiology Journal* **17** 448–456.
- 12 Fallo F, Della Mea P, Sonino N, Bertello C, Ermani M, Vettor R, Veglio F & Mulatero P 2007 Adiponectin and insulin sensitivity in primary aldosteronism. *American Journal of Hypertension* **20** 855–861. (doi:10.1016/j.amjhyper.2007.03.012)
- 13 Widimsky J Jr, Sindelka G, Haas T, Prazny M, Hilgertova J & Skrha J 2000 Impaired insulin action in primary hyperaldosteronism. *Physiological Research* **49** 241–244.
- 14 Urbanet R, Pilon C, Calcagno A, Pescechera A, Hubert EL, Giacchetti G, Gomez-Sanchez C, Mulatero P, Toffanin M, Sonino N, et al. 2010 Analysis of insulin sensitivity in adipose tissue of patients with primary aldosteronism. *Journal of Clinical Endocrinology and Metabolism* **95** 4037–4042.
- 15 Sowers JR, Whaley-Connell A & Epstein M 2009 Narrative review: the emerging clinical implications of the role of aldosterone in the



- metabolic syndrome and resistant hypertension. *Annals of Internal Medicine* **150** 776–783. (doi:10.7326/0003-4819-150-11-200906020-00005)
- 16 Zillich AJ, Garg J, Basu S, Bakris GL & Carter BL 2006 Thiazide diuretics, potassium, and the development of diabetes: a quantitative review. *Hypertension* **48** 219–224. (doi:10.1161/01.HYP.0000231552.10054.aa)
- 17 Brown MJ, Williams B, Morant SV, Webb DJ, Caulfield MJ, Cruickshank JK, Ford I, McInnes G, Padmanabhan S, Sever P, *et al.* 2016 Effect of amiloride, or amiloride plus hydrochlorothiazide, versus hydrochlorothiazide on glucose tolerance and blood pressure (PATHWAY-3): a parallel-group, double-blind randomised phase 4 trial. *Lancet Diabetes and Endocrinology* **4** 136–147. (doi:10.1016/S2213-8587(15)00377-0)
- 18 Ren H, Qin L, Wang W, Ma J, Zhang W, Shen PY, Shi H, Li X & Chen N 2013 Abnormal glucose metabolism and insulin sensitivity in Chinese patients with Gitelman syndrome. *American Journal of Nephrology* **37** 152–157. (doi:10.1159/000346708)
- 19 Rowe JW, Tobin JD, Rosa RM & Andres R 1980 Effect of experimental potassium deficiency on glucose and insulin metabolism. *Metabolism* **29** 498–502. (doi:10.1016/0026-0495(80)90074-8)
- 20 Helderma JH, Elahi D & Andersen DK 1983 Prevention of glucose intolerance of thiazide diuretics by maintenance of body potassium. *Diabetes* **32** 106–111. (doi:10.2337/diab.32.2.106)
- 21 Gorden P, Sherman BM & Simopoulos AP 1972 Glucose intolerance with hypokalaemia: an increased proportion of circulating proinsulin-like component. *Journal of Clinical Endocrinology and Metabolism* **34** 235–240. (doi:10.1210/jcem-34-1-235)
- 22 Fiskerstrand T, Arshad N, Haukanes BI, Tronstad RR, Pham KD, Johansson S, Håvik B, Tønder SL, Levy SE, Brackman D, *et al.* 2012 Familial diarrhea syndrome caused by an activating GUCY2C mutation. *New England Journal of Medicine* **366** 1586–1595. (doi:10.1056/NEJMoa1110132)
- 23 Grosse J, Heffron H, Burling K, Akhter Hossain M, Habib AM, Rogers GJ, Richards P, Larder R, Rimmington D, Adriaenssens AA, *et al.* 2014 Insulin-like peptide 5 is an orexigenic gastrointestinal hormone. *PNAS* **111** 11133–11138. (doi:10.1073/pnas.1411413111)
- 24 Davis JE, Seavey PW & Sessions JT 1962 Villous adenomas of the rectum and sigmoid colon with severe fluid and electrolyte depletion. *Annals of Surgery* **155** 806–812. (doi:10.1097/00000658-196205000-00019)

Received in final form 28 March 2016

Accepted 4 April 2016