

 **Case Report** 

# Retroperitoneal Germ Cell Tumor Resection with Primary Inferior Vena Cava Reconstruction

Cesar Cuen-Ojeda, MD, Jesus H. Rivera-Banuelos, MD, Javier E. Anaya-Ayala, MD, MSc, and Carlos A. Hinojosa, MD, MSc

Retroperitoneal tumors (RTs) are frequently found as large masses upon diagnosis. Within the differential diagnosis of RTs, one of the most important are germ cell tumors. We report here the case of a 30 year old man with a recurrent RT involving the inferior vena cava (IVC). Once discussed, he underwent a tumor resection with a primary IVC reconstruction maintaining vessel patency. On histopathology, a mixed germ cell tumor was reported. The patient recovered well and he was discharged from the hospital without complications.


**Keywords:** retroperitoneal tumors, inferior vena cava

## Introduction

Retroperitoneal tumors (RTs) typically develop insidiously; they are generally found as large masses, and often 50% of RTs are larger than 20 cm at the time of diagnosis.<sup>1)</sup> Since most of them are malignant, surgery is indicated. Within the differential diagnosis of RTs, one of the most important are germ cell tumors (GCTs) derived from germ cells. These tumors present in patients between 15 and 35 years. Most GCTs are gonadal, and only 5% present as extra gonadal form.<sup>2)</sup> Teratomas are a frequent subtype of nonseminomatous germ cell tumors (NSGCTs), some of them have a malignant transformation, including: rhabdomyosarcoma, leiomyosarcoma or angiosarcoma,<sup>3)</sup>

*Department of Surgery, Section of Vascular Surgery and Endovascular Therapy, National Institute of Medical Sciences and Nutrition Salvador Zubirán, Mexico City, Mexico*

Received: December 9, 2018; Accepted: February 25, 2019  
Corresponding author: Carlos A. Hinojosa, MD, MSc. Department of Surgery, Section of Vascular Surgery and Endovascular Therapy, National Institute of Medical Sciences and Nutrition Salvador Zubirán, Vasco de Quiroga 15, Sección XVI, Mexico City 14080, Mexico  
Tel: +52-55-5487-0900, Fax: N/A  
E-mail: carlos.a.hinojosa@gmail.com

 ©2019 The Editorial Committee of Annals of Vascular Diseases. This article is distributed under the terms of the Creative Commons Attribution License, which permits use, distribution, and reproduction in any medium, provided the credit of the original work, a link to the license, and indication of any change are properly given, and the original work is not used for commercial purposes. Remixed or transformed contributions must be distributed under the same license as the original.

as the case we present, who has a mixed component.

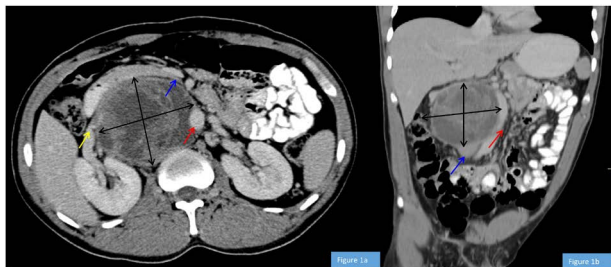Previous studies have favored inferior vena cava (IVC) reconstruction when resection is necessary for RT removal, with very low morbidity and mortality reported.<sup>4)</sup> In our center, these cases are managed by a team of vascular and urology surgeons. We present a case of a 20 cm RT resection with primary IVC reconstruction avoiding the use of prosthetic material while maintaining vessel patency.

## Case Report

A 30 year old male with no previous medical history noted a painless, abnormal growth on his right testicle in 2013. A whole body computed tomography (CT) scan completed at an outside hospital excluded metastases. A right radical orchiectomy was performed, and a teratoma was reported on histopathology. The previous surgery and initial follow-up was done in another institution. In 2016, he complained of abdominal pain, fever and weight loss. A CT scan revealed a retroperitoneal tumor of 75×80 mm, leading to 8 cycles of chemotherapy treatment in 2017 based on ifosfamide 1200 mg/m<sup>2</sup>, cisplatin 20 mg/m<sup>2</sup> and vinblastine 0.11 mg/m<sup>2</sup>. The patient was referred to our institution in January 2018, presenting with an elevated alpha fetus protein (AFP) of 14,604.5 ng/mL. A CT scan revealed a right paramedial retroperitoneal tumor of 19×7.5 cm with involvement of the IVC and aorta. The tumor surrounded the right renal artery (Fig. 1). He received four cycles of etoposide 100 mg/m<sup>2</sup>, cisplatin 20 mg/m<sup>2</sup> and bleomycin 30 U, with partial response measured, with AFP decreasing from 14,604.5 ng/mL to 125 ng/mL after the cycles. In April 2018, one month after the last dose of chemotherapy, a pulmonary thromboembolism and a thrombosis of the bilateral common, external, and internal iliac veins was documented, so rivaroxaban 20 mg per day was started. Lower limb edema and pain did not improve after a month with anticoagulation treatment.

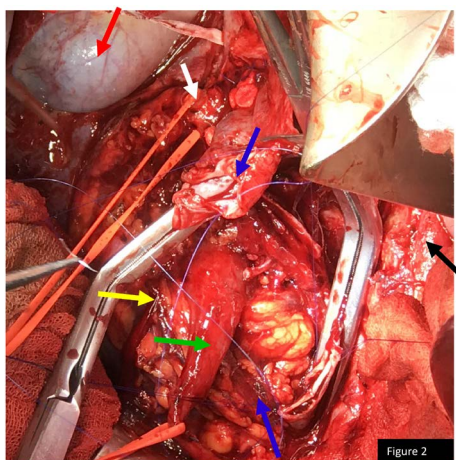
The case was discussed in the hospital, and surgical resection was agreed by the Urology and Vascular Surgery teams. The patient was placed in supine position, and surgery was performed through a vertical midline incision. After accessing the peritoneal cavity, we retracted the small intestine to the patient's left. The lateral peritoneal attachments of the

right colon were incised concomitantly. The second and third portions of the duodenum were also mobilized by incising retroperitoneal attachments, retracting everything to



**Fig. 1** (a) An axial view of the tumor constricting the right renal artery (yellow arrow), pushing the aorta (red arrow) and inferior vena cava (IVC; blue arrow). The tumor size was 19×17.5cm; (b) Coronal view of the tumor deviating the aorta (red arrow), and the infrarenal IVC seen before it gets collapsed by the tumor (blue arrow).

Color figure can be viewed in the online version on J-STAGE and PMC.



**Fig. 2** A surgical bed after tumor resection. The transected inferior vena cava is signposted by the blue arrows being repaired. Right ureter (green arrow), right kidney (yellow arrow), aorta (black arrow), right renal artery (white arrow) and gallbladder (red arrow).

Color figure can be viewed in the online version on J-STAGE and PMC.

the left. Retroperitoneal exposure was achieved, and the underlying IVC was dissected. The suprarenal and infra-renal portions of the IVC were encircled with a vascular tape. Finally, the left and right renal veins were controlled with vessel loops. A retro-caval tumor of 20cm was identified; then IVC was divided a number 11 scalpel for adequate exposure of the tumor. After IVC transection, the tumor was resected. Finally the IVC was primarily end to end re-anastomosed with a prolene 6-0 suture without complications (Fig. 2). On histopathology, a mixed GCTs (70% teratoma with component of rhabdomyosarcoma and 30% of yolk sac tumor) was reported (Fig. 3). The patient was admitted to the intensive care unit for follow-up. His lower limb edema and pain diminished. He was discharged to the outpatient center unit two weeks later for follow-up.

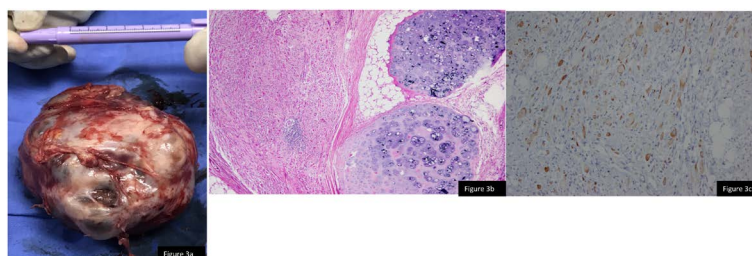
### Discussion

Resection of RT is challenging for surgeons because of their inaccessible location, their difficult exposure during surgery, and difficulty predicting their clinical behavior.

In patients with large tumors, pre-operative biopsy would not be recommended due to the risk of tumor spread during the biopsy procedure.<sup>1)</sup>

The most common age of GCT presentation is between 15 and 35 years old, as was the case with our patient. To diagnose and provide a prognosis for GCTs, it is crucial to order testicular tumor markers; the most common are: AFP, β-human chorionic gonadotrophin, and lactate dehydrogenase. AFP is expressed by trophoblastic elements and yolk sac tumors.<sup>2)</sup> These tumor markers are important for evaluating response to treatment, such as elevation of testicular tumor markers following orchidectomy, which may indicate metastatic disease.<sup>2)</sup> Our patient had elevation of AFP five years after orchidectomy.

Patients with mixed GCT are treated like a NSGCTs. In more than 80% of patients with this kind of tumor, the primary metastatic site is the retroperitoneal nodes. It is also the most frequently involved site of chemoresistant mature teratoma, which holds the potential for malignant



**Fig. 3** (a) A resected tumor measuring 10×9cm; (b) 4× magnification, hematoxylin and eosin stain in which we observe hyaline cartilage that alternates with tissue of heterologous differentiation. (c) 100× magnification, immunohistochemistry which shows positivity in cytoplasm for desmin in cells with rhabdomyosarcoma differentiation.

transformation.<sup>5)</sup> Although systemic chemotherapy is a potential curative treatment in patients with residual masses and elevated AFP, retroperitoneal lymph node dissection (RPLND) remains an important part of treating patients with NSGCTs in the United States of America. In NSGCTs, post-chemotherapy RPLND is indicated for patients with residual masses irrespective of size and normalization of tumor markers<sup>5)</sup>; patients with teratomas and previous chemotherapy suffer malignant transformation more frequently due to resistance, and these recurrences must be treated with large resections.<sup>6,7)</sup>

The goal in surgical management of RTs is to achieve negative surgical borders because, in the presence of a positive surgical border, survival decreases significantly. These tumors involve the IVC and the abdominal aorta in 6–10% and 2%, respectively.<sup>5)</sup> The IVC is commonly compromised by partial or complete compression, wall invasion, and vessel encasing by the tumor.<sup>8)</sup> When the IVC is infiltrated, circumferential resection is necessary since two-thirds of the patients harbor vital cancer or mature teratoma in the infiltrating masses.<sup>5)</sup>

The resection and primary reconstruction of the IVC is a procedure that is not widely mentioned in the literature. A trans-peritoneal exposure is often necessary to expose the infra-renal and peri-renal IVC.<sup>4)</sup> Most of the reports stated that IVC reconstruction is done with polytetrafluoroethylene (PTFE) due to better resistance to abdominal compression. Quinones-Baldrich and Farley<sup>4)</sup> recommend replacing the IVC with a ringed reinforced PTFE graft if there is no infection, arguing that the graft should be smaller than the diameter of the IVC (usually 12–14 mm) to get rapid flow and prevent graft thrombosis. In this case, we decided to perform a primary anastomosis, minimizing the risk of complications such as thrombosis, graft infection, graft erosion, and migration, which are particularly higher in oncologic patients due to immunosuppression.

During the procedure, patients tolerate IVC clamping most of the time. The only important consideration during unclamping is to place the patient in the Trendelenburg position with a Valsalva maneuver to avoid air embolism.<sup>4)</sup> Described, step-by-step techniques to reconstruct the IVC have been reported depending on the localization and percentage of IVC involvement. Some surgeons prefer to ligate the IVC because the procedure is well tolerated if collateral circulation is preserved during the tumor resection. However, there are reports indicating 50% of these patients will experience lower extremity edema, leading to venous gangrene if there are insufficient collateral vessels.<sup>4)</sup> Trying to avoid this postoperative venous hypertension, we favor IVC reconstruction, either with PTFE graft or primary repair. During follow-up, IVC reconstruction is not an absolute indication to anticoagulate. Postoperative anticoagulation is based on clinical indications. All patients

having IVC reconstruction should receive aspirin for life.<sup>4)</sup>

## Conclusion

It is important that RTs have a well established pre-operative plan, and they should be treated by an experienced team of surgeons.

Today, the only current treatment option that prolongs survival in patients with these tumors is wide surgical resection. This patient is an example, as described in the literature, that a primary IVC repair can be done safely, without intraoperative and postoperative complications, leading to a better prognosis for the patient.

## Disclosure Statement

The authors have no conflict of interests.

## Author Contributions

Study conception: CAH

Data collection: CCO, JHRB

Writing: CCO, JAAA

Critical review and revision: all authors

Final approval of the article: all authors

Accountability for all aspects of the work: all authors

## References

- 1) Gemici K, Buldu İ, Acar T, et al. Management of patients with retroperitoneal tumors and a review of the literature. *World J Surg Oncol* 2015; **13**: 143.
- 2) Vasdev N, Moon A, Thorpe AC. Classification, epidemiology and therapies for testicular germ cell tumours. *Int J Dev Biol* 2013; **57**: 133-9.
- 3) Williamson SR, Delahunt B, Magi-Galluzzi C, et al. The World Health Organization 2016 classification of testicular germ cell tumours: a review and update from the International Society of Urological Pathology Testis Consultation Panel. *Histopathology* 2017; **70**: 335-46.
- 4) Quinones-Baldrich WJ, Farley S. Techniques for inferior vena cava resection and reconstruction for retroperitoneal tumor excision. *J Vasc Surg Venous Lymphat Disord* 2013; **1**: 84-9.
- 5) Heidenreich A, Pfister D. Retroperitoneal lymphadenectomy and resection for testicular cancer: an update on best practice. *Ther Adv Urol* 2012; **4**: 187-205.
- 6) Williams SB, Kacker R, Steele GS, et al. Primary vs. post-chemotherapy retroperitoneal lymph node dissection (RPLND) in patients with presence of teratoma at orchiectomy. *Urol Oncol* 2012; **30**: 60-3.
- 7) Caso J, Seigne J, Back M, et al. Circumferential resection of the inferior vena cava for primary and recurrent malignant tumors. *J Urol* 2009; **182**: 887-93.
- 8) Ulbright TM. Germ cell tumors of the gonads: a selective review emphasizing problems in differential diagnosis, newly appreciated, and controversial issues. *Mod Pathol* 2005; **18 Suppl 2**: S61-79.