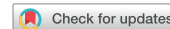
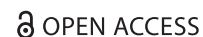
CASE REPORT



Early mobilizing and dangling of the lower leg after one-stage reconstruction of Achilles tendon and overlying tissue defect using an anterolateral thigh flap with vascularized fascia lata

Masayuki Okochi, Masanori Momiyama, Hiromi Okochi and Kazuki Ueda

Department of Plastic and Reconstructive Surgery, Fukushima Medical University, Fukushima, Japan

ABSTRACT

We have treated two patients who had an Achilles tendon and overlying tissue defect using an anterolateral thigh flap with fascia lata. Postoperatively, skeletal suspension of the affected leg and intra-arterial heparin infusion were performed for seven days. Six weeks postoperatively, the patients could walk again.

ARTICLE HISTORY

Received 28 September 2016
Accepted 23 October 2017

KEYWORDS

Achilles tendon; free flap; postoperative therapy; reconstruction; anterolateral thigh flap; rehabilitation



1. Introduction

The Achilles tendon is essential for walking, going up stairs, and standing on tiptoe [1]. Reconstruction of a defect of the Achilles tendon with overlying tissue is challenging. This is because the tendon should have enough strength to bear the whole body weight and should be covered with well-vascularized tissue [2–17]. Many authors have reported one-stage reconstruction of a composite defect of the Achilles tendon and soft tissue using a free flap [2–17]. Recently, early dangling of lower legs after free tissue transplantation for the reconstruction following tumor ablation has been recommended [18,19]. On the other hand, there are no guidelines or reports regarding when dangling of the affected lower leg should be allowed in cases of Achilles tendon reconstruction where the ankle joint cannot be moved immediately after surgery. We have treated two patients who had a defect of the Achilles tendon and overlying tissue using a free anterolateral thigh (ALT) flap with vascularized fascia lata (FL). Postoperatively, intra-arterial infusion of heparin and skeletal suspension of the lower leg were performed. In both of our cases, active motion of the ankle joint was possible three days after surgery. In this report, we describe the details of the operative procedure and postoperative therapy.

2. Operative procedure

After each patient received general anesthesia there were placed in the spine position and wide debridement of the necrotic tendon and soft tissue was performed after which the flap size was determined. Next, the flap was harvested from the side opposite to the affected side. At the proximal side, FL was rolled and fixed to the proximal stump of the Achilles tendon using 4-0 nylon (Keisei Medical Industrial, Japan). At the distal side, FL was folded and fixed to the calcaneus bone using 2.7 mm self-tapping cortex screws (DePuy Synthes Japan, Tokyo, Japan) (Figure 1). During the fixation of FL, the ankle joint was kept in 0° of dorsal flexion.

Flow-through anastomosis was performed between the descending branch of the lateral circumflex femoral and the posterior tibial artery using 9-0 nylon. End-to-side anastomosis was performed between the descending branch of the lateral circumflex femoral vein and the posterior tibial vein, also using 9-0 nylon. The suction drain (J-VAC 10 mm flat drain, Ethicon, Somerville, NJ) was placed through separate incision that was located 3 cm lateral from flap. The flap was sutured using 3-0 Vicryl (Ethicon), 4-0 PDS (Ethicon) and 5-0 Ethilon (Ethicon). An incision was placed at the affected side and the femoral artery was dissected.

CONTACT Masayuki Okochi  oktme-okt@umin.ac.jp  Department of Plastic and Reconstructive Surgery, Fukushima Medical University, 1 Hikarigaoka, Fukushima Japan, 960-1295

© 2017 The Author(s). Published by Informa UK Limited, trading as Taylor & Francis Group.

This is an Open Access article distributed under the terms of the Creative Commons Attribution-NonCommercial License (<http://creativecommons.org/licenses/by-nc/4.0/>), which permits unrestricted non-commercial use, distribution, and reproduction in any medium, provided the original work is properly cited.

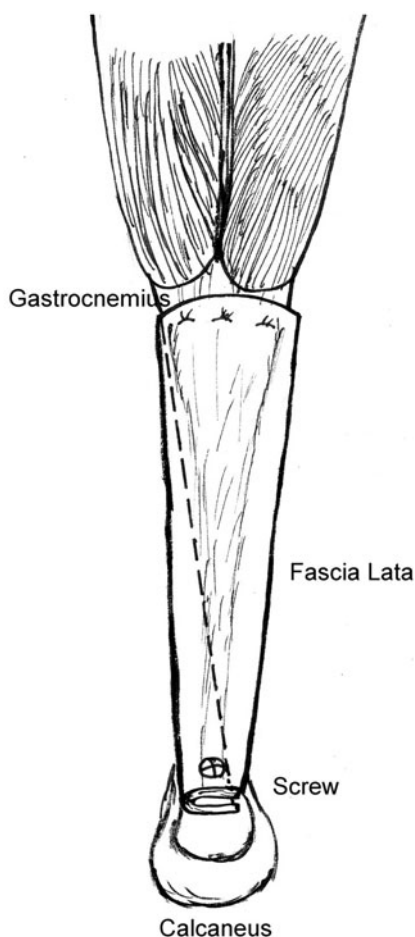


Figure 1. Schematic representation of the fascia fixation. Fascia lata was fixed to the proximal stump of the Achilles tendon and the calcaneus bone using 4-0 surgical nylon and screws, respectively.

From this incision, a 28G Argyle PI catheter (Covidien, Tokyo, Japan) was inserted into the femoral artery. For seven days postoperatively, the lower leg of the affected side was suspended by inserting 2 mm Kirschner wire (Synthes) through the tibia bone (Figure 2).

3. Postoperative therapy and rehabilitation

Postoperatively, we performed continuous trans-arterial infusion of heparin (Mochida Pharmaceutical, Japan) via 28G PI catheter which was inserted into the femoral artery. Until two days postoperatively, the daily dose of heparin was 8000 IU. On postoperative days 3 and 4, 4000 IU and on days 5 and 6, 2000 IU heparin was administered. The activated partial thromboplastin time (APTT) level was checked every 24 h until seven days postoperatively. Prolonged APTT was not observed during this period. Eight days postoperatively, the catheter was removed. No other anti-platelet or anti-coagulant therapy was performed.

At three days postoperatively, active dorsi-flexion was started. Dangling of the affected leg was started at one week postoperatively. On postoperative days 7 and 8, the affected leg was dangled for a duration of 30 min two times a day. On postoperative days 9 and 10, the affected leg was dangled for a duration of 60 min two times a day. On postoperative days 11 and 12, the affected leg was dangled for a duration of 90 min two times a day. From postoperative day 13, the lower leg was dangled without limitation. During rehabilitation, patients could use wheelchair or walk on crutches without weight bearing. Partial-weight bearing rehabilitation was started at four weeks after surgery, with an ankle appliance in 30° of ankle plantar flexion. At five weeks after surgery, full-weight rehabilitation was started using the ankle appliance. At six weeks postoperatively, the patients were able to walk without the ankle appliance.

4. Case reports

Case 1

A 64-year-old woman had an Achilles tendon rupture while climbing a mountain and was admitted to a local hospital. Repair of the Achilles tendon was performed three times. However, her Achilles tendon ruptured the fourth time with skin necrosis after which she was referred to our hospital (Figure 3(a)). Preoperatively, her ankle was fixed in 20° plantar flexion. The blood flow of posterior tibial artery was confirmed using CT angiography. Wide debridement results showed that she had a 3 × 8 cm soft tissue defect and a 6 cm Achilles tendon defect (Figure 3(b)). A 15 × 8 cm ALT flap with 18 × 10 cm FL was then harvested (Figure 3(c)). End-to-side anastomosis was performed between the descending branch of the lateral circumflex femoral vein and the posterior tibial vein. The diameter of the posterior tibial vein was 1.5 mm and the diameter of lateral circumflex femoral vein was 2 mm. The FL was folded and fixed to the calcaneus bone and a skin paddle of the ALT flap was fixed to the soft tissue defect (Figure 3(d)). During fascia fixation, the ankle joint was kept in 0° of dorsal flexion. The donor site of the ALT flap was closed directly. The activated partial thromboplastin time (APTT) level was checked every 24 h until seven days postoperatively. Prolonged APTT was not seen. The postoperative course was uneventful. Seven months postoperatively, scar revision and defatting of the skin paddle were performed. Twelve months postoperatively, the active range of motion of the ankle joint was 55°

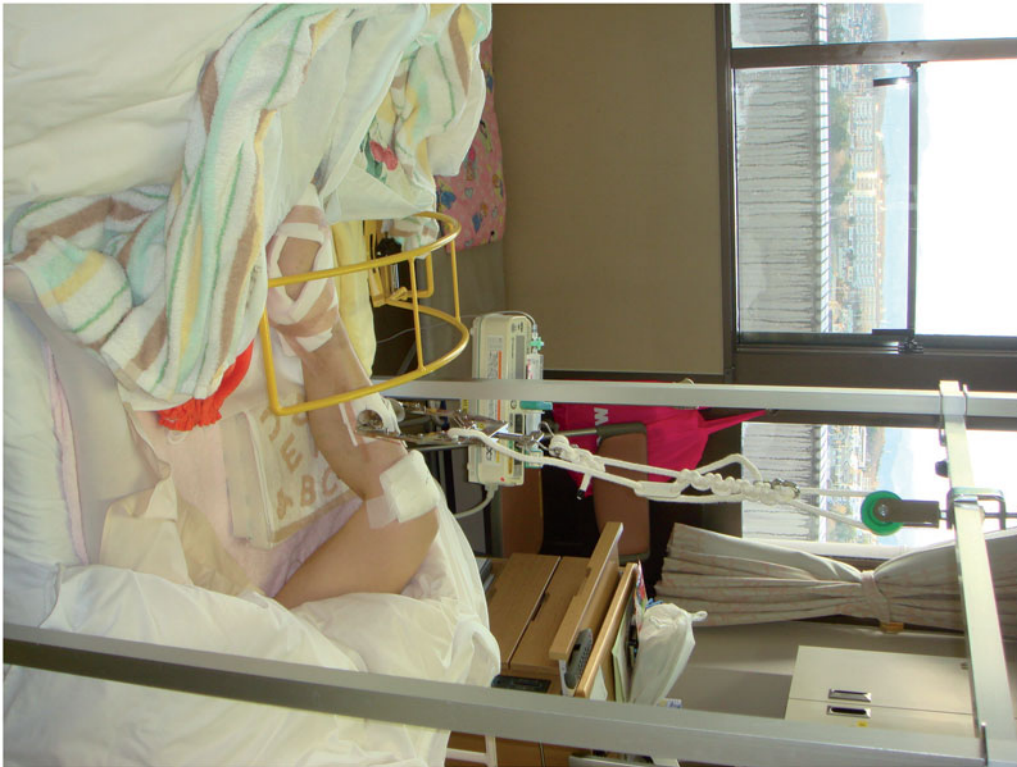

Figure 2. View of the lower extremity after surgery. Skeletal suspension was performed.

(10° dorsiflexion, 45° plantar flexion) (Figure 3(e)) and she had no disability in her daily life.

Case 2

A 60-year-old man was admitted to a local hospital with an Achilles tendon rupture that had occurred while playing table tennis. Repair of the Achilles tendon was performed twice. However, his Achilles tendon ruptured the third time with skin necrosis, and then was referred to our hospital (Figure 4(a)). Preoperatively, his ankle was fixed in 5° plantar flexion. The blood flow of posterior tibial artery was confirmed using CT angiography. Wide debridement results showed that he had a 10 × 8 cm soft tissue defect and a 10 cm Achilles tendon defect (Figure 4(b)). A 15 × 10 cm ALT flap with 20 × 12 cm FL was harvested (Figure 4(c)). End-to-side anastomosis was performed between the descending branch of the lateral circumflex femoral and the posterior tibial vein. The diameter of posterior tibial vein was 1.5 and the diameter of lateral circumflex femoral vein was 2.5 mm, respectively. The FL was folded and fixed to the calcaneus bone and then a skin paddle of the ALT flap was fixed to the soft tissue defect (Figure 4(d)). During FL fixation, the ankle joint was kept in 0° of dorsal flexion. The donor site of the ALT flap was closed directly. The postoperative course was uneventful. Twelve months

postoperatively, scar revision and defatting of the skin paddle were performed. The active range of motion of the ankle joint was 70° (15° dorsiflexion, 55° plantar flexion) (Figure 4(e)). He then was able to play table tennis again.

5. Discussion

The Achilles tendon is essential for walking, going up stairs and standing on tiptoe [20]. The rate of Achilles tendon rupture differs depending on country or race [21,22] and 12–22 patients in 100,000 have Achilles tendon ruptures every year in European countries [21], while there is no report on such rate in Japan. Excellent results of non-operative reconstruction treatment after Achilles tendon rupture have been reported [20]. However, reconstruction of a defect of the Achilles tendon with overlying tissue is still challenging [2–17]. This is because the reconstructed tendon should have enough strength to bear the whole body weight and should be covered with well-vascularized tissue. One-stage reconstruction of a composite defect of the Achilles tendon and soft tissue using a free flap with vascularized FL transfer was introduced by Wei et al. [3]. They harvested a free groin flap with abdominal external oblique muscle fascia. Inoue et al. reported of the reconstruction of the Achilles tendon using a lateral thigh flap with FL [4]. In 1993,

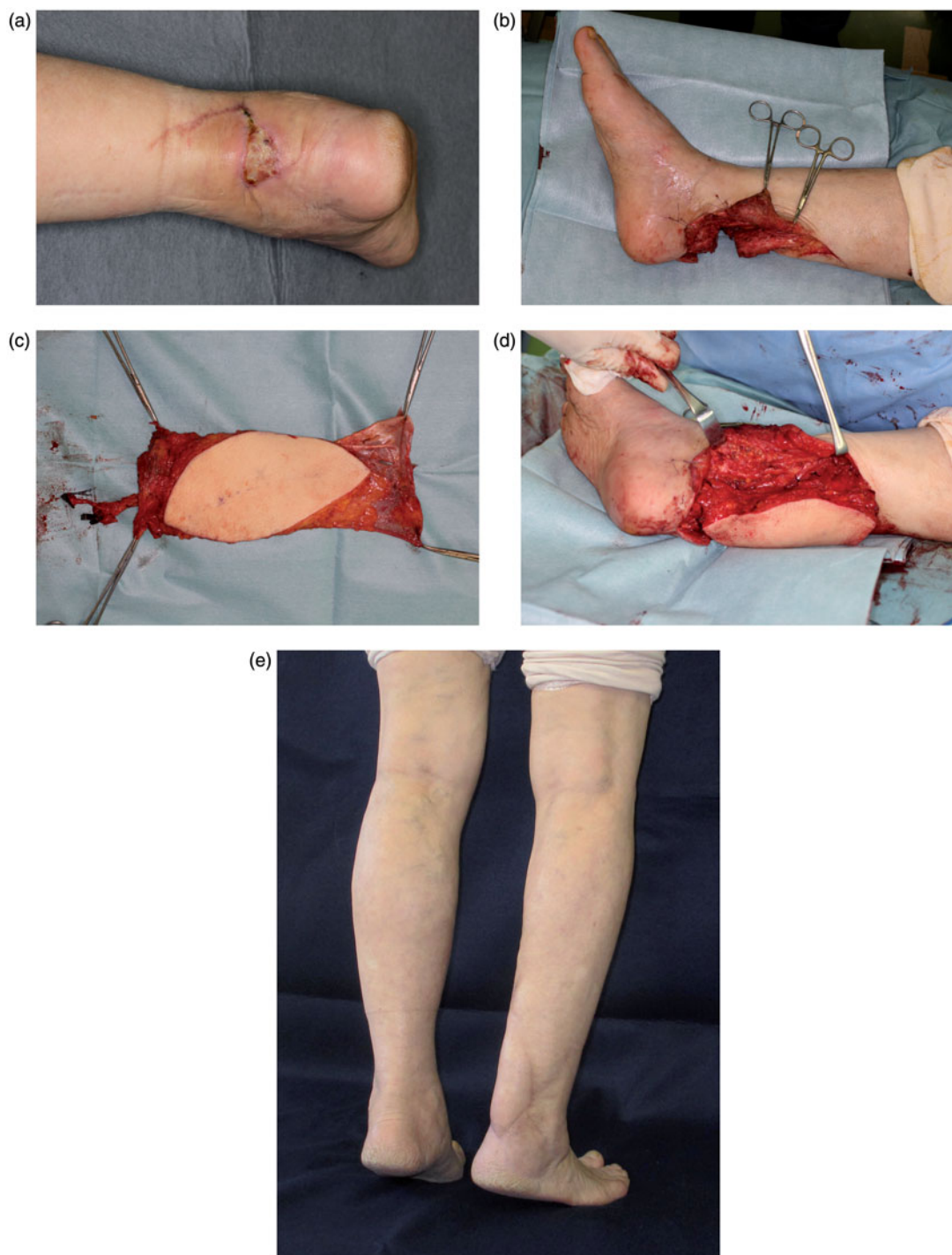


Figure 3. (a) A 64-year-old woman had a chronic ulcer and necrosis of the Achilles tendon. (b) After debridement of soft tissue and the Achilles tendon. (c) Harvesting an anterolateral thigh flap with fascia. A 15×8 cm skin paddle with 18×10 cm fascia lata was harvested from the non-affected side. (d) The vascularized fascia was folded and fixed to the calcaneus bone and the skin paddle of the anterolateral thigh flap was then fixed to the soft tissue defect. (e) One-year postoperative view. The patient could stand on tip toe without help.

Hou et al. reported a lateral upper arm flap with triceps tendon transfer [5] and Stanec et al. reported a forearm flap with brachioradialis tendon transfer in 1999 [6]. We used a free ALT flap with vascularized FL in the one-stage reconstruction, a commonly

performed and reported procedure [15,16]. The advantage of this procedure is that a large and well-vascularized fascia can be harvested with a large skin paddle. However, no guidelines exist regarding postoperative therapy and rehabilitation. Until the year

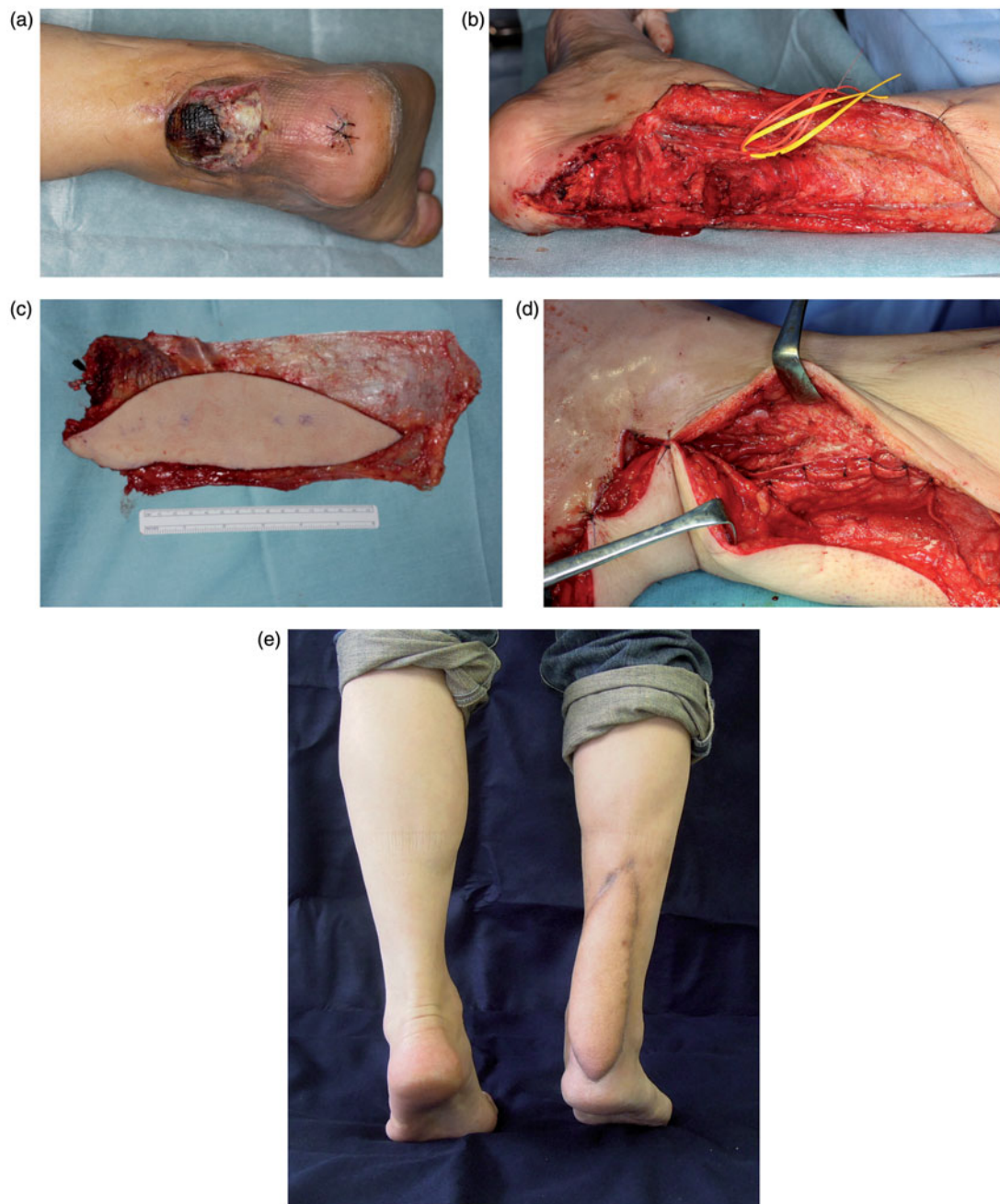


Figure 4. (a) A 60-year-old man had a chronic ulcer and necrosis of the Achilles tendon. (b) After debridement of soft tissue and the Achilles tendon. (c) The anterolateral thigh flap with fascia lata was harvested. A 15×10 cm skin paddle with 20×12 cm fascia lata was harvested from the non-affected side. (d) The vascularized fascia was folded and fixed to the calcaneus bone and the skin paddle of the anterolateral thigh flap was then fixed to the soft tissue defect. (e) One-year postoperative view. The patient could stand on tip toe without help.

2000, many authors reported that patients were not able to walk for more than three months after surgery [2–6,9]. Free tissue transfer for the lower leg has been common, however, patients were not able to walk within two months postoperatively even after 2000 [16–19]. In the present cases, active dorsiflexion was started at three days postoperatively. At one week postoperatively our patients were allowed to dangle the lower leg and were able to walk six weeks after

surgery. Some authors have reported that early dangling of the lower leg after free flap transfer does not increase the risk of free flap failure. In 2013, Jokuszies et al. recommended their lower-leg dangling protocol. In their report, they started dangling of the lower leg at three days postoperatively [18]. In addition, Miyamoto et al. reported that even starting mobilization at one day postoperatively did not cause flap failure and necrosis of skin grafting [19]. In their report,

there was no differences in a survival rate between flap types. However, their cases did not include the cases who received tendon reconstruction using free flap transfer [18,19]. Early dangling of the lower leg is difficult after reconstruction of the tendon as in our cases. We worried that venous congestion might cause insufficient adhesion between the FL and the Achilles tendon because Miyamoto et al. reported that in eight of the 11 cases they had to place the suction drain at the recipient site for up to seven days postoperatively.

Early mobilization of the ankle joint is required to prevent adhesion of the Achilles tendon to the FL. Even in a recent studies authors fixed the ankle joint for more than two weeks postoperatively [16,17]. In our cases, we did not put the patient's leg on a pillow because the reconstructed Achilles tendon and overlying tissue were located at the posterior aspect of the leg. To avoid suppressing deformity due to self-weight of lower leg, skeletal suspension was useful. We believe that the skeletal suspension made it possible to start the dorsal flexion of the ankle joint earlier than other reports.

In 2007, Xipoleas et al. conducted a survey on the postoperative anticoagulant therapy. According to their survey, 11.2% of American Society of Plastic Surgeons members used heparin for postoperative anticoagulation therapy. Among them, 63.6% administered 10,000 or 15,000 U/day of heparin [23]. On the other hand, in our cases, the maximal dose of heparin was 8000 U/day and this dose was decreased every two days because intra-arterial infusion can administer the heparin selectively to flap compare to intravenous infusion or subcutaneous injection. Many authors have reported the reconstruction of Achilles tendon and overlying tissue defect using a free flap [2–17]. However, only few authors mentioned the details of postoperative anticoagulant therapy. Further study is needed in order to determine the effectiveness of postoperative anticoagulant therapy.

Recently, heparin-induced thrombocytopenia (HIT) has become widely known. With the exception of patients who do not have previous heparin exposure within 100 days, HIT usually occurs between 5–10 days following heparin initiation [24]. We performed intra-arterial heparin infusion until seven days postoperatively in the present cases and believe that the risk of HIT was low.

In this study, we were limited by the small number of cases. We believe further study is needed in order to determine the effectiveness of early mobilization of affected leg combined with continuous heparin infusion and skeletal suspension.

One-stage reconstruction of the Achilles tendon and overlying tissue using an ALT flap with FL is a reliable option. To achieve good result, postoperative rehabilitation should be started as early as possible.

Acknowledgements

None of the authors have any potential financial conflict of interest related to this manuscript

Disclosure statement

The authors declare no conflicts of interest associating with this manuscript.

References

- [1] Doral MN, Alam M, Bozkurt M, et al. Functional anatomy of the Achilles tendon. *Knee Surg Sports Traumatol Arthrosc.* 2010;18:638–643.
- [2] Fumarola A. A one-stage reconstruction of a large defect of the tendon Achilles and the overlying skin. *Br J Plast Surg.* 1985;38:403–406.
- [3] Wei FC, Chen HC, Chuang CC, et al. Reconstruction of Achilles tendon and calcaneus defects with skin-aponeurosis-bone composite free tissue from the groin region. *Plast Reconstr Surg.* 1988;81:579–589.
- [4] Inoue T, Tanaka I, Imal K, et al. Reconstruction of Achilles tendon using vascularised fascia lata with free lateral thigh flap. *Br J Plast Surg.* 1990;43:728–731.
- [5] Hou SM, Liu TK. Vascularized tendon graft using lateral arm flap. 5 microsurgery cases. *Acta Orthop Scand.* 1993;64:373–376.
- [6] Stanec S, Stanec Z, Delimar D, et al. A composite forearm free flap for the secondary repair of the ruptured Achilles tendon. *Plast Reconstr Surg.* 1999;104:1409–1412.
- [7] Nazerali RS, Hakimi M, Giza E, et al. Single-stage reconstruction of Achilles tendon rupture with flexor hallucis longus tendon transfer and simultaneous free radial fasciocutaneous forearm flap. *Ann Plast Surg.* 2013;70:416–418.
- [8] Innocenti M, Tani M, Carulli C, et al. Radial forearm flap plus flexor carpi radialis tendon in Achilles tendon reconstruction: surgical technique, functional results, and gait analysis. *Microsurgery.* 2015;35:608–614.
- [9] Lee HB, Lew DH, Oh SH, et al. Simultaneous reconstruction of the Achilles tendon and soft-tissue defect using only a latissimus dorsi muscle free flap. *Plast Reconstr Surg.* 1999;104:111–119.
- [10] Deiler S, Pfadenhauer A, Widmann J, et al. Tensor fasciae latae perforator flap for reconstruction of composite Achilles tendon defects with skin and vascularized fascia. *Plast Reconstr Surg.* 2000;106:342–349.
- [11] Taniguchi Y, Tamaki T. Reconstruction of the Achilles tendon and overlying skin defect with a medical plantar flap and tensor fasciae latae graft. *J Reconstr Microsurg.* 2000;16:423–425.

- [12] Yajima H, Kobata Y, Yamauchi T, et al. Reconstruction of Achilles tendon and skin defects using peroneal cutaneotendinous flaps. *Plast Reconstr Surg.* 2001;107:1500–1503.
- [13] Papp C, Todoroff BP, Windhofer C, et al. Partial and complete reconstruction of Achilles tendon defects with the fasciocutaneous infragluteal free flap. *Plast Reconstr Surg.* 2003;112:777–783.
- [14] DeFazio MV, Han KD, Evans KK. Functional reconstruction of a combined tendocutaneous defect of the Achilles using a segmental rectus femoris myofascial construct: a viable alternative. *Arch Plast Surg.* 2014;41:285–289.
- [15] Lee JW, Yu JC, Shieh SJ, et al. Reconstruction of the Achilles tendon and overlying soft tissue using antero-lateral thigh free flap. *Br J Plast Surg.* 2000;53:574–577.
- [16] Youn SK, Kim SW, Kim YH, et al. The composite anterolateral thigh flap for Achilles tendon and soft tissue defect reconstruction with tendon repair by fascia with double or triple folding technique. *Microsurgery.* 2015;35:615–621.
- [17] Houtmeyers P, Opsomer D, Van Landuyt K, et al. Reconstruction of the Achilles tendon and overlying soft tissue by free composite anterolateral thigh flap with vascularized fascia lata. *J Reconstr Microsurg.* 2012;28:205–209.
- [18] Jokuszies A, Neubert N, Herold C, et al. Early start of the dangling procedure in lower extremity free flap reconstruction does not affect the clinical outcome. *J Reconstr Microsurg.* 2013;29:27–32.
- [19] Miyamoto S, Kayano S, Fujiki M, et al. Early mobilization after free-flap transfer to the lower extremities: preferential use of flow-through anastomosis. *Plast Reconstr Surg Glob Open.* 2014;2:e127.
- [20] Wang D, Sandlin MI, Cohen JR, et al. Operative versus nonoperative treatment of acute Achilles tendon rupture: an analysis of 12,570 patients in a large healthcare database. *Foot Ankle Surg.* 2015;21:250–253.
- [21] Owens B, Mountcastle S, White D. Racial differences in tendon rupture incidence. *Int J Sports Med.* 2007;28:617–620.
- [22] Lantto I, Heikkinen J, Flinkkilä T, et al. Epidemiology of Achilles tendon ruptures: increasing incidence over a 33-year period. *Scand J Med Sci Sports.* 2015;25:e133–e138.
- [23] Xipoleas G, Levine E, Silver L, et al. A survey of microvascular protocols for lower-extremity free tissue transfer I: perioperative anticoagulation. *Ann Plast Surg.* 2007;59:311–315.
- [24] Salter BS, Weiner MM, Trinh MA, et al. Heparin-induced thrombocytopenia: a comprehensive clinical review. *J Am Coll Cardiol.* 2016;67:2519–2532.