


# Efficacy and Tolerability of CyberKnife Stereotactic Robotic Radiotherapy for Primary or Secondary Orbital Lesions: A Single-Center Retrospective Experience

Technology in Cancer Research & Treatment  
Volume 18: 1-5  
© The Author(s) 2018  
Article reuse guidelines:  
sagepub.com/journals-permissions  
DOI: 10.1177/1533033818818561  
journals.sagepub.com/home/tct  


Isacco Desideri, MD<sup>1</sup> , Giulio Francolini, MD<sup>1</sup>, Giulio Alberto Carta, MD<sup>1</sup>, Vanessa Di Cataldo, MD<sup>2</sup>, Laura Masi, MD<sup>2</sup>, Icro Meattini, MD<sup>1</sup>, Pierluigi Bonomo, MD<sup>1</sup>, Mauro Loi, MD<sup>1</sup>, Daniela Greto, MD<sup>1</sup>, Luca Visani, MD<sup>1</sup> , Monica Lo Russo, MD<sup>1</sup>, Roberta Grassi, MD<sup>1</sup>, Maria Ausilia Teriaca, MD<sup>1</sup>, Pietro Garlatti, MD<sup>1</sup>, Cosimo Nardi, MD<sup>3</sup>, and Lorenzo Livi, MD<sup>1</sup>

## Abstract

**Introduction:** Orbital lesions are rare, but are likely to become symptomatic and can impact on patients' quality of life. Local control is often difficult to obtain, because of proximity to critical structures. CyberKnife stereotactic robotic radiotherapy could represent a viable treatment option. **Materials and Methods:** Data on patients treated for intraorbital lesions from solid malignancies were retrospectively collected. All patients underwent treatment with CyberKnife system. We analyzed local control, response rate, symptoms control, progression-free survival and overall survival, acute and late toxicity. **Results:** From January 2012 to May 2017, 20 treatments on 19 patients were performed, with dose ranging from 24 to 35 Gy in 1 to 5 fractions, prescribed at an average isodose line of 79.5% (range: 78-81). After a mean follow-up of 14.26 months (range: 0-58), overall response rate was 75%, with 2 and 4 patients presenting a partial and complete response, respectively. Mean time to best measured response was 15.16 months (range: 2-58). Thirteen patients were alive, with a local control rate of 79%. Mean time to local progression was 5 months (range: 3-7). Three patients reported improvement in symptoms after treatment. Mean planning target volume dose coverage was 97.2% (range: 93.5-99.7). Mean maximum dose (D max) to eye globe, optic nerve, optic chiasm, and lens was 2380.8 cGy (range: 290-3921), 1982.82 cGy (range: 777.3-2897.8), 713.14 cGy (range: 219.5-2273), and 867.9 cGy (range: 38-3118.5). Four patients presented acute toxicity. **Conclusion:** This current retrospective series demonstrated that CyberKnife robotic stereotactic radiotherapy is a feasible and tolerable approach for intraorbital lesions.

## Keywords

CyberKnife, orbital lesions, radiotherapy, solid malignancies, robotic stereotactic radiotherapy

## Abbreviations

CT, computed tomography; LC, local control; MRI, magnetic resonance imaging; OAR, organ at risk; PTV, planning target volume

Received: May 28, 2018; Revised: September 24, 2018; Accepted: October 12, 2018.

<sup>1</sup> Department of Experimental and Clinical Biomedical Sciences, Radiation Oncology Unit, University of Florence, Azienda Ospedaliero-Universitaria Careggi, Florence, Italy

<sup>2</sup> CyberKnife Center, Istituto Fiorentino di Cura ed Assistenza, Florence, Italy

<sup>3</sup> Department of Experimental and Clinical Biomedical Sciences, Radiodiagnostic Unit n. 2, University of Florence, Azienda Ospedaliero-Universitaria Careggi, Florence, Italy

## Corresponding Author:

Isacco Desideri, MD, Department of Experimental and Clinical Biomedical Sciences, Radiation Oncology Unit, University of Florence, Azienda Ospedaliero-Universitaria Careggi, Largo Brambilla 3, Florence 50134, Italy.

Email: isacco.desideri@unifi.it



## Introduction

Primary and secondary orbital lesions occur infrequently, but they can represent an important issue in clinical practice related to their propensity to become symptomatic and their impact on patients' quality of life. Furthermore, local control (LC) is often difficult to obtain, because of proximity to critical structures.<sup>1,2</sup>

Systemic therapies are a cornerstone for metastatic disease treatment, but the integration with a local therapy, aimed to reduce tumor bulk, could help to improve outcomes; CyberKnife robotic radiotherapy could constitute a viable treatment option for this kind of lesions.<sup>3,4</sup>

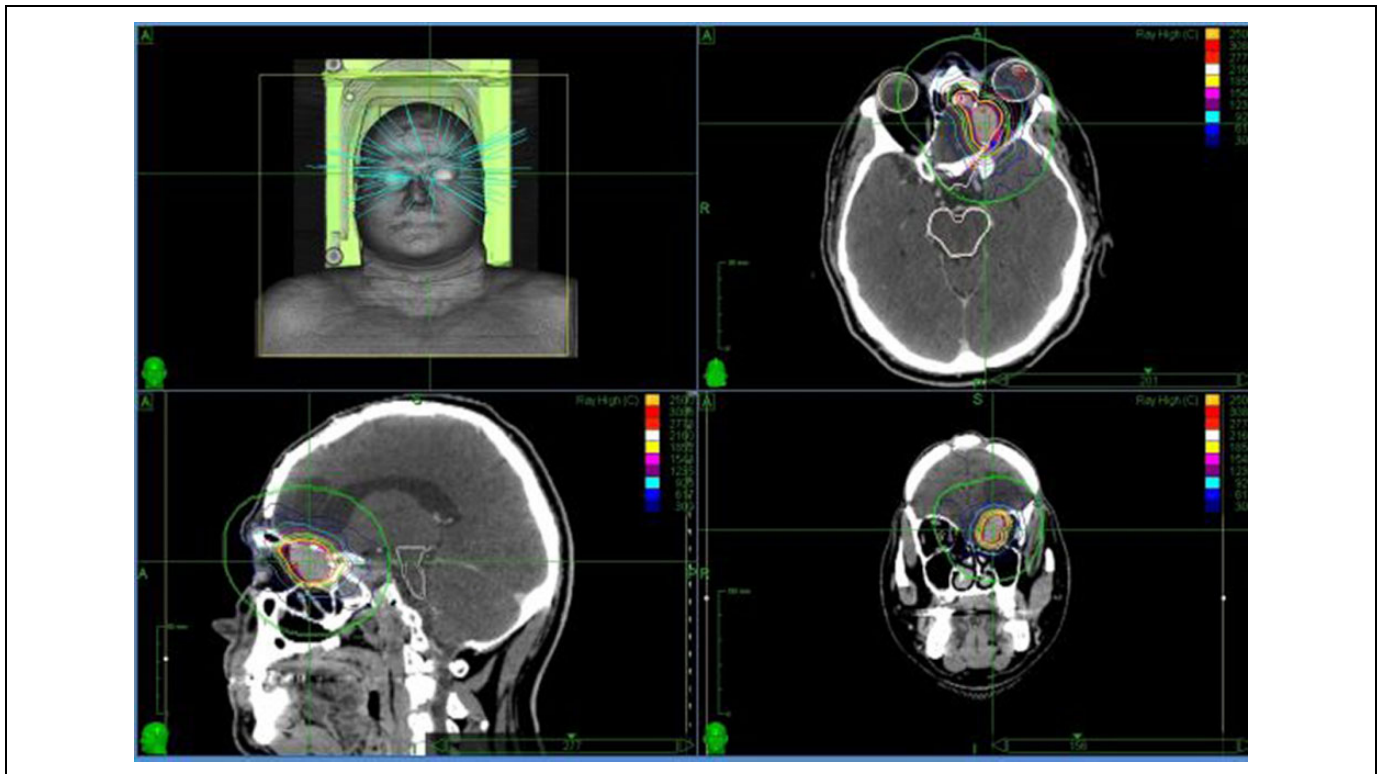
CyberKnife stereotactic body radiotherapy allows to achieve steep dose gradients, with very high biological effective dose on target volumes and effective organs at risk (OAR) sparing, thanks to its peculiar target spatial localization system.<sup>5-7</sup> This is of particular importance considering that optic pathways and ocular adnexa have been shown to be prone to late toxicity after stereotactic radiotherapy in older reports.<sup>7,8</sup>

In this article, a retrospective experience about patients consecutively treated with stereotactic robotic radiotherapy is presented, with the aim to explore the efficacy and tolerability of this treatment option in this setting.

## Materials and Methods

We retrospectively collected data on patients consecutively treated for primary and metastatic intraorbital lesions from

solid malignancies at our institution. Intraorbital lesions were defined as lesions located inside the orbital cavity, excluding those strictly confined to orbital bone structures. All patients underwent treatment with CyberKnife system (Accuray Inc; Figure 1). Planning computed tomography (CT) with and without contrast was obtained with 1.25 mm slice thickness using a multislice scanner (Lightspeed 16 GE Medical Systems, Wisconsin). Gross target volume was delineated on a contrast-enhanced CT scan coregistered with diagnostic magnetic resonance imaging (MRI) to improve morphologic definition of the target. A 1-mm-isotropic expansion was added to delineated target volume to take into account inter- and intrafractional uncertainties and obtain a planning target volume (PTV). All treatment plans were elaborated on MULTIPLAN treatment planning station (version 5.3). Dose constraints for involved OARs were obtained from the American Association of Physicists in Medicine report.<sup>9</sup> Patients were treated in supine position, with the use of a custom mask for immobilization and reproducible setup. Intrafraction motion management was performed by 6-dimensional skull tracking using 2 orthogonal diagnostic kV X-ray sources mounted on treatment room ceiling at a 45° angle to the perpendicular axis (Accuray). The 6D Skull Tracking System enables direct tracking of the bony anatomy of the skull when treating intracranial lesions. Target tracking and motion compensation were accomplished by using image intensity and brightness differences between the digital reconstructed radiography and live images. Simple descriptive statistics were used to analyze LC, response rate,



**Figure 1.** Example of a CyberKnife treatment plan for an orbitaly lesion.

**Table 1.** Baseline Features of Study Population.

Characteristic	
Sex	M: 9 (47%) F: 10 (53%)
Age (mean)	58.4 years (34-85)
Performance status	0: 11 (58%) 1: 6 (31%) 2: 2 (11%)
Lesion	Primary: 6 (32%) Metastatic: 13 (68%)
Histology	- Breast: 4 (21%) - Sarcoma: 3 (16%) - Lung cancer: 2 (11%) - Basalioma: 2 (11%) - Plasmocitoma: 2 (11%) - Lymphoma: 1 (5%) - Colon cancer: 1 (5%) - Apocrine carcinoma: 1 (5%) - HCC: 1 (5%) - Adenoid cystic carcinoma: 1 (5%) - Lacrimal gland adenocarcinoma: 1 (5%)
Side	Right: 4 (21%) Left: 13 (68%) Bilateral: 2 (11%)
Intraorbital structure involvement	Roof: 11 (58%) Medial wall: 10 (53%) Floor: 7 (37%) Lateral wall: 8 (42%)
Previous surgery	Yes: 5 (26%) No: 14 (74%)
Symptomatic lesion	Yes: 14 (74%) No: 5 (26%)
Total	19 (100%)

Abbreviation: HCC, hepatocellular carcinoma.

symptoms control, progression-free and overall survival, acute and late adverse events, assessed using CTCAE scale version 4.0.

## Results

From January 2012 to May 2017, 20 treatments on 19 patients were performed in our institute. Baseline characteristics are highlighted in Table 1. Patients were treated with dose ranging from 24 to 35 Gy in 1 to 5 fractions, prescribed at an average isodose line of 79.5% (range: 78-81). Only one patient did not complete the scheduled treatment due to declining performance status. Overall, median volume of treated lesions was 11.82 cc (range: 2.2-45.1), with an average PTV of 18.15 cc (range: 2.6-70.85). After a mean follow-up of 14.26 months (range: 0-58), overall response rate was 75%, with 2 and 4 patients presenting a partial and complete response, respectively. Mean time to best measured response was 15.16 months (range: 2-58). Thirteen patients were alive, with a LC rate of 79%. Mean time to local progression was 5 months (range: 3-7). Retreatment with CyberKnife was needed in one patient and exenteration in

another one after local progression. Fourteen patients reported symptomatic lesions, while 5 and 3 patients had reduced visual field or impaired visual acuity before treatment, respectively. Overall, 3 patients reported improvement in symptoms after treatment: one patient reported partial recovery of visual acuity, the second pain decrease and reduced eye tearing, and the third reported improvement in visual field and reduced exophthalmos. About dosimetric data, mean PTV dose coverage was 97.2% (range: 93.5-99.7). Mean maximum dose (D max) to homolateral eye globe, optic nerve, lens, and optic chiasm was 2380.8 cGy (range: 290-3921), 1982.82 cGy (range: 777.3-2897.8), 713.14 cGy (range: 219.5-2273), and 867.9 cGy (range: 38-3118.5), respectively. Four patients presented acute toxicity, defined as occurring within 3 months after the end of treatment (2 cases of conjunctivitis, 2 transitory orbital pain, 1 grade 2 xerophthalmia, and 1 grade 2 dermatitis). No severe toxicity was reported at the end of the study period.

## Discussion

Overall, data presented in this retrospective experience show that robotic stereotactic radiotherapy using CyberKnife system was effective and well tolerated in the study population. Three previously published retrospective experiences confirmed that this treatment strategy is a valuable option for intraorbital lesions.<sup>10-12</sup> Hirschbein *et al* reported data about 16 patients treated with dose ranging from 10 to 25 Gy in 2 to 5 fractions: 12 patients had a postoperative MRI showing stable disease or response to radiotherapy, with 5 complete responses (all patients affected by intraorbital lymphoma). All patients affected by pretreatment pain reported symptoms resolution. Visual evaluation was performed in all patients after procedure: 15 and 13 patients reported stable visual field and visual acuity, respectively, and improvement in these parameters was reported in 3 patients.<sup>10</sup> Another retrospective series was published in 2010, presenting outcomes of 14 treated lesions in 13 patients. However, population included in this experience is not directly comparable with the current analysis, considering that patients were affected exclusively by periocular lymphoma, and that ocular lesions (ie, lesions affecting retina, choroid, and conjunctiva) were included. Lesions were treated with a mean treatment dose of 1718 cGy (range: 1350-2250 cGy) in 3 to 5 fractions. Authors reported complete response in all cases, with a favorable toxicity profile.<sup>11</sup> The most recent analysis was conducted on 16 orbital metastases from solid cancers, affecting 14 patients, all treated with single fraction CyberKnife radiosurgery, with dose ranging from 16.5 to 21 Gy. Results showed that 4 patients had partial response, while 1 reported complete response after treatment. Overall, stable disease or response to treatment was documented in 87% of patients. One of 3 patients reporting pretreatment reduction in visual acuity, and 2 of 5 reporting persistent diplopia, had improvement of these deficits after treatment. No serious adverse effects were reported.<sup>12</sup> Previous experiences and current series' main characteristics are summarized in Table 2.

**Table 2.** Summary of Previous Literature Data.

Author, Year	Design	Patients/ Lesions (n)	Histologies	Dose (Gy)/fr	Median Treated Volume (cc)	Outcome	Adverse Events
Hirschbein <i>et al</i> , 2008 <sup>10</sup>	Retrospective	16/16	- Pancreatic adenocarcinoma - Lymphoma - Melanoma - Graves disease - Adenocarcinoma NOS - Chronic orbital inflammation - Breast cancer - Salivary gland - Meningioma	10-25/2-5	5.91 (1.01-30.63)	ORR: 75% Symptoms control: 100%	transient nausea: 1 Herpes Zoster: 1
Bianciotto <i>et al</i> , 2010 <sup>11</sup>	Retrospective	13/14	Lymphoma	13.50-22.5/3-5	14.55 (10.7-54)	ORR:100%	Dry eye: 2 Cataract: 1
Klingenstein <i>et al</i> , 2012 <sup>12</sup>	Retrospective	14/16	-Prostate -Breast -Melanoma -Pancreatic adenocarcinoma -Pharinx carcinoma - Kidney	16.5-21/1	7 (0.2-35)	ORR:87%	None
Current experience	Retrospective	19/20	Breast Sarcoma: 3 - Lung cancer - Basalioma - Plasmocitoma: - Lymphoma - Colon cancer - Apocrine carcinoma - HCC - Adenoid cystic carcinoma - Lacrimal gland adenocarcinoma	24-35/1-5	11.82 (2.2-45.1)	ORR: 75% LC: 79%	Conjunctivitis: 2 Orbital pain: 2, 1 Xeroftalmia: 1 Dermatitis:1

Abbreviations: HCC, hepatocellular carcinoma; LC, local control; ORR, overall response rate.

The current experience is the largest available in this setting. Furthermore, mean follow-up time in this analysis (14.26 months) ensures higher reliability of late toxicity results. Another important feature to highlight in the presented series is the robust definition of target localization. As previously stated, no ocular lesion was included (eg, choroidal lesions), neither bone lesions affecting periorbital structures. Interestingly, median volume of treated lesions in our experience is larger, if compared to previous data from the literature, confirming that Cyberknife radiosurgery may be considered as a treatment option for a wide range of target volumes. Vast majority of patients included in the current series was treated in 5 fractions, while other authors proposed a 16.5 to 25 Gy monofractionated schedule.<sup>12</sup> A direct comparison with other experiences could be difficult, and reported adverse events are uncommon in all available literature.<sup>10-12</sup> Currently, no recommendation exists about correct doses and fractionations in this setting, and these should be carefully evaluated according to proximity of critical structures, histology, and target lesion

volume. Due to challenges posed by normal tissue dose tolerance, other authors treated orbital lesions in their experiences with techniques other than CyberKnife, mainly using Gamma Knife.<sup>13</sup> Recently, a novel IMRT prescription concept termed simultaneous integrated protection (PTV-SIP) for quantifiable and comparable dose prescription to targets very close to OARs have been described.<sup>14,15</sup> This planning technique was not adopted in our series of patients, mainly due to the novelty of this approach and the utilization of a fractionated schedule (commonly consisting of 5 fractions).

However, prospective data are needed to establish standard doses and fractionations to be recommended. Considering the availability of new systemic therapies that can potentially bring to a survival increase, some metastatic patients could become long survivors; local progression in this setting would be a critical issue, and given the strict necessity to respect OAR constraints, a retreatment could be considered challenging in clinical practice. In our series, one patient affected by apocrine carcinoma who had previously undergone stereotactic

radiotherapy was treated again on the same orbital lesion with 25 Gy in a 5 fraction schedule. After a follow-up of 2 years, the patient was alive, but the lesion was further progressed after first treatment and surgically removed through ocular resection. However, no significant adverse event was reported and this treatment strategy probably postponed surgery, providing a benefit in this case. Thus, orbital retreatment could be recommended in highly selected patients.

Limitations of this work are its retrospective nature, the low number and the heterogeneity of included patients. However, data presented here are in line with previous literature and confirm the efficacy of stereotactic body radiotherapy in this setting of patients, with a low number of adverse events.

## Conclusion

Data from our retrospective series demonstrated that CyberKnife robotic stereotactic radiotherapy is a feasible and tolerable approach for intraorbital lesions, and should be considered in clinical practice. However, prospective experiences, aimed to tailor doses and fractionations on the basis of lesions' dimension and localization, are needed to improve the therapeutic ratio of this treatment strategy.

## Authors' Note

I.D. and G.F. contributed equally to the manuscript. The Ethics Committee of the "AREA VASTA CENTRO" waived the need for ethics approval and the need to obtain consent for the collection, analysis, and publication of the retrospectively obtained and anonymized data for this noninterventional study. All procedures performed in studies involving human participants were in accordance with the ethical standards of the institutional and/or national research committee ("Comitato Etico Area Vasta Centro") and with the 1964 Helsinki Declaration and its later amendments or comparable ethical standards. Informed consent was obtained from all individual participants included in the study.



## Declaration of Conflicting Interests

The author(s) declared no potential conflicts of interest with respect to the research, authorship, and/or publication of this article.

## Funding

The author(s) received no financial support for the research, authorship, and/or publication of this article.

## ORCID iD

Isacco Desideri, MD  <https://orcid.org/0000-0002-9880-8387>  
Luca Visani, MD  <https://orcid.org/0000-0002-7079-231X>

## References

1. Goldberg RA, Rootman J, Cline RA. Tumors metastatic to the orbit: a changing picture. *Surv Ophthalmol.* 1990;35(1):1-24.
2. Rudoler SB, Shields CL, Shields JA. Radiation therapy of uveal and orbital metastases. In: Sagerman RH, Alberti WE, eds. *Radiotherapy of Intraocular and Orbital Tumors.* New York, NY: Springer; 2003:87-93.
3. Shields JA, Shields CL, Brotman HK, Carvalho C, Perez N, Eagle RC Jr. Cancer metastatic to the orbit: the 2000 Robert M. Curtis Lecture *Ophthalm Plast Reconstr Surg.* 2001;17(5):346-354.
4. Andrews DW, Bednarz G, Evans JJ, Downes B. Review of 3 current radiosurgery systems. *Surg Neurol.* 2006;66(6):559-564.
5. Adler JR, Chang SD, Murphy MJ, Doty J, Geis P, Hancock SL. The Cyberknife: a frameless robotic system for radiosurgery. *Stereotact Funct Neurosurg.* 1997;69(1-4 pt 2):124-128.
6. Adler JR Jr, Murphy MJ, Chang SD, Hancock SL. Image-guided robotic radiosurgery. *Neurosurgery.* 1999;44(6):1299-1307.
7. Girkin CA, Comey CH, Lunsford LD, Goodman ML, Kline LB. Radiation optic neuropathy after stereotactic radiosurgery. *Ophthalmology.* 1997;104(10):1634-1643.
8. Gordon KB, Char DH, Sagerman RH. Late effects of radiation on the eye and ocular adnexa. *Int J Radiat Oncol Biol Phys.* 1995;31(5):1123-1239.
9. Benedict SH, Yenice KM, Followill D, et al. Stereotactic body radiation therapy: the report of AAPM Task Group 101. *Med Phys.* 2010;37(8):4078-4101.
10. Hirschbein MJ, Collins S, Jean WC, Chang SD, Adler JR Jr. Treatment of intraorbital lesions using the Accuray CyberKnife system. *Orbit.* 2008;27(2):97-105.
11. Bianciotto C, Shields CL, Lally SE, Freire J, Shields JA. CyberKnife radiosurgery for the treatment of intraocular and periocular lymphoma. *Arch Ophthalmol.* 2010;128(12):1561-1567.
12. Klingenstein A, Kufeld M, Wowra B, Muacevic A, Fürweger C, Schaller UC. CyberKnife radiosurgery for the treatment of orbital metastases. *Technol Cancer Res Treat.* 2012;11(5):433-439.
13. Jo KI, Im YS, Kong DS, et al. Multisession Gamma Knife surgery for benign orbital tumors. *J Neurosurg.* 2012;117:102-107.
14. Mazzola R, Fersino S, Aiello D, et al. Linac-based stereotactic body radiation therapy for unresectable locally advanced pancreatic cancer: risk-adapted dose prescription and image-guided delivery. *Strahlenther Onkol.* 2018;194(9):835-842.
15. De Bari B, Porta L, Mazzola R, et al. Hypofractionated radiotherapy in pancreatic cancer: Lessons from the past in the era of stereotactic body radiation therapy. *Crit Rev Oncol Hematol.* 2016;103:49-61.