

# Intraoperative optical coherence tomography-guided subretinal cocktail injection in a case of ruptured retinal artery macro-aneurysm with multilevel bleed

Atul Kumar, M Dheepak Sundar, Rohan Chawla,  
Divya Agarwal, Nasir Hasan

Submacular hemorrhage (SMH) following ruptured retinal artery macro aneurysm (RRAM) has better prognosis as compared to other etiologies. Timely intervention from as early as 24 h to less than 7 days is known to provide better visual outcomes in such cases. A variety of surgical techniques have been described in the treatment of RRAM. In this case report, we describe the advantages of intraoperative optical coherence tomography-guided sub-retinal injection of a cocktail mixture consisting of recombinant tissue plasminogen activator, bevacizumab, and air. Faster visual recovery with an immediate displacement of sub-macular bleed can be achieved with this technique in cases of RRAM-associated SMH.

**Key words:** Retinal artery macro-aneurysm, sub-macular hemorrhage, subretinal injection

Retinal artery macro-aneurysms (RAM), are round or fusiform dilatations of the retinal arteries or arterioles predominantly occurring in hypertensive patients. Nearly, 50% of the RAMs are hemorrhagic in nature.<sup>[1]</sup> The coexistent bleed can either be secondary to the persistent ooze occurring through the thinned out vessels or directly as a result of vessel wall rupture and is known to form an hour-glass shape with extensions to various levels of the retina.<sup>[1]</sup>

The sub-retinal component of these multilevel bleeds are often difficult to be assessed due to the overlying hemorrhage.<sup>[2]</sup> The extent, duration, and thickness of the sub-macular hemorrhage (SMH) prognosticate the long-term visual outcomes in ruptured RAMs.<sup>[2-4]</sup> Several invasive<sup>[2-6]</sup> and noninvasive surgical strategies<sup>[7-9]</sup> have been suggested with

variable outcomes in the management of SMHs associated with RRAMs.

## Case Report

A 51-year-old hypertensive male presented with sudden onset vision loss in his left eye for a period of 4 days. On examination, his best-corrected visual acuity (BCVA) in the right eye (RE) was 20/20 and in the left eye (LE) was finger counting at 3 m. LE fundus showed a multilevel bleed at the macula spanning around four disc diameters [Fig. 1]. Swept-source optical coherence tomography (OCT) (DRI Topcon, Tokyo) could localize the bleed at the sub-internal limiting membrane (ILM), intraretinal, and subretinal levels [Fig. 2a-d]. A focal hypercyanescence at an arteriolar ending which increased in late phase was evident on indocyanine green angiography [Fig. 2e and 2f]. The patient was diagnosed to have RRAM with multilevel bleed and later underwent intraoperative OCT-guided (iOCT-guided) 23 gauge pars-plana vitrectomy with sub-retinal cocktail injection and 20% sulphur hexafluoride (SF6) endotamponade. Proper informed consent and institutional ethical board clearance (IEC-493/02.08.2019) were obtained before the procedure.

After initial core vitrectomy, the posterior vitreous detachment was induced with the help of triamcinolone acetate. The sub-ILM space filled with blood was demarcated with the help of iOCT. The sub ILM blood was aspirated and evacuated with active suction. An extendible 41 gauge needle (DORC, Montagu) was attached to a 1 mL tuberculin syringe loaded with a cocktail mixture of 0.1 mL recombinant tissue plasminogen activator (rtPA) (12.5 µg/0.1 mL), 0.1 mL of bevacizumab (1.25 mg/0.05 mL) and 0.3 mL of air. The 41 gauge needle was slowly injected into the area of maximum thickness of the subretinal bleed under direct visualization with the help of iOCT. The mixture was gently injected into the subretinal space and a bleb was formed [Fig. 3] The vitreous cavity was later filled with 20% SF6 and the patient was given propped up position [Video 1]. The subretinal bleed was displaced from the macula on the next postoperative day. The BCVA at 1-week post-surgery was 20/60 and the SSOCT showed complete displacement of subretinal bleed with partial recovery of outer retinal architecture [Fig. 4]. The BCVA was still maintained at 20/60 at 3 months follow-up without any recurrence.

## Discussion

SMH following ruptured RAM has been reported to have a better prognosis when compared to those following age-related macular degeneration (ARMD).<sup>[7]</sup> Timely intervention from as

Video Available on: [www.ijo.in](http://www.ijo.in)

Access this article online

Quick Response Code:



Website:

[www.ijo.in](http://www.ijo.in)

DOI:

10.4103/ijo.IJO\_1803\_19

Dr. Rajendra Prasad Centre for Ophthalmic Sciences, All India Institute of Medical Sciences, New Delhi, India

**Correspondence to:** Dr. M Dheepak Sundar, House No 6, (Dinesh Saini) 1<sup>st</sup> Floor, Gautam Nagar, Delhi - 110 049, India. E-mail: [dheepocean@gmail.com](mailto:dheepocean@gmail.com)

Received: 29-Sep-2019

Revision: 23-Dec-2019

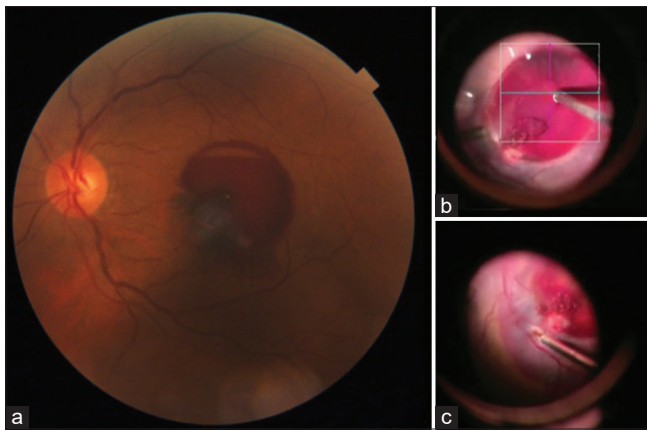
Accepted: 03-Feb-2020

Published: 25-Jun-2020

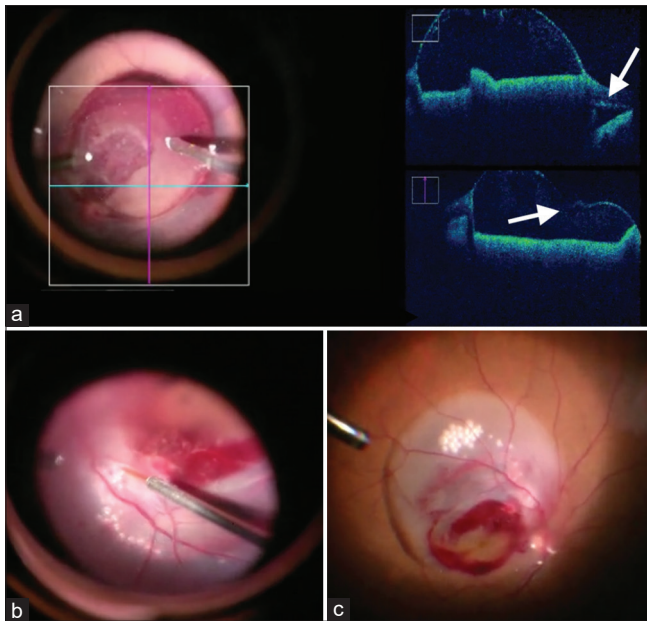
This is an open access journal, and articles are distributed under the terms of the Creative Commons Attribution-NonCommercial-ShareAlike 4.0 License, which allows others to remix, tweak, and build upon the work non-commercially, as long as appropriate credit is given and the new creations are licensed under the identical terms.

**For reprints contact:** [reprints@medknow.com](mailto:reprints@medknow.com)

**Cite this article as:** Kumar A, Sundar MD, Chawla R, Agarwal D, Hasan N. Intraoperative optical coherence tomography-guided subretinal cocktail injection in a case of ruptured retinal artery macro-aneurysm with multilevel bleed. Indian J Ophthalmol 2020;68:1468-70.



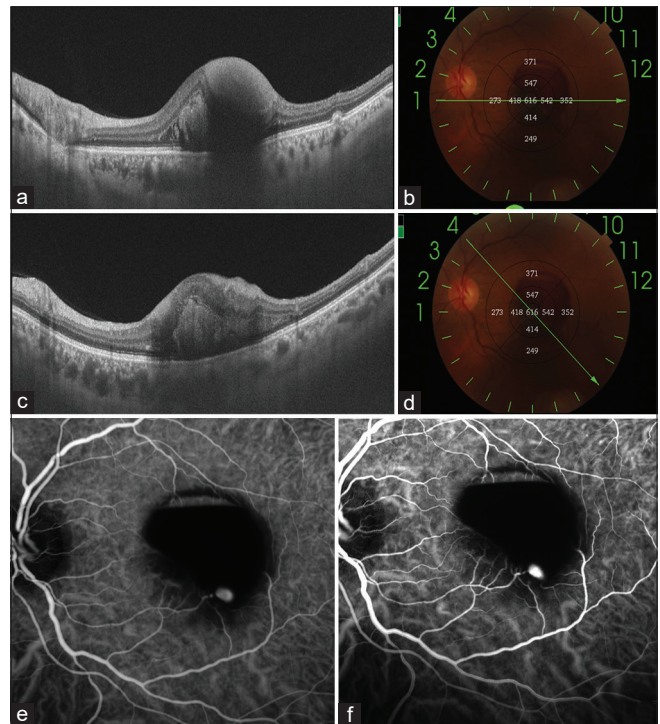
**Figure 1:** (a) Fundus photography showing mild hazy media with a hemorrhagic lesion at the macula consisting of both preretinal and subretinal bleed component (b and c) Intraoperative snapshots showing the preretinal and subretinal bleed more clearly



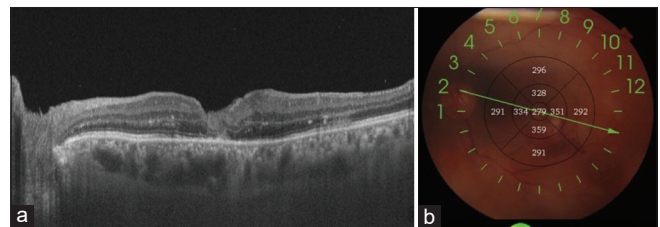
**Figure 3:** Intraoperative snapshot images: (a) showing intraoperative oct-guided visualization of sub-internal limiting membrane (ILM) space. The subretinal elevation caused by the bleed (above arrow) and the ILM dipping caused by the touch of the vitrectomy cutter (below arrow) can be seen. (b) the entry of 41 gauge needle into the subretinal space along with subretinal air bubbles can also be seen (c) this image shows a well-formed subretinal bleb consisting of the fluid-air mixture

early as 24 h to less than 7 days following the onset of symptoms is known to produce better functional outcomes.<sup>[3-5,6]</sup> In cases of RRAM, the multilevel bleed prevents clear-cut demarcation of the subretinal structures.<sup>[2]</sup> SS-OCT offers better penetration<sup>[10]</sup> and could help in such cases to identify the extent and thickness of subretinal bleed and therefore in planning for immediate vitrectomy.

Various techniques have been practiced for the treatment of SMH in RAM, mainly inculcated from those used in CNVM counterparts. Initially, Humayun *et al.* created a tunnel with the help of 36 gauge spatula and injected subretinal rtPA. After a waiting period of 45 min, subretinal space was irrigated



**Figure 2:** (a and b) Swept-source optical coherence tomography (SSOCT) showing the sub-internal limiting membrane bleed and intraretinal bleed (c and d). Subretinal bleed can also be visualized in this SSOCT scan (e and f). Early and late phases of indocyanine green angiography showing blocked hypofluorescence and focal hyperfluorescence visible at the end of an arteriole



**Figure 4:** Postoperative day 7 - Swept-source optical coherence tomography showing partial reorganization of retinal architecture with the absence of subretinal bleed. The best-corrected visual acuity improved up to 20/60

with balanced salt solution (BSS) and the residual bleed was aspirated.<sup>[4]</sup> Zhao *et al.*, instead of mechanical clot aspiration, used perfluorocarbon liquid to displace out the subretinal bleed through a retinotomy.<sup>[3]</sup> Innoue *et al.* and Sonmez *et al.* showed good results with their modification. After tPA injection, without further aspirating the lysed clot, they used gas tamponade and positioning for displacing it.<sup>[5,6]</sup> Intravitreal tPA and pneumatic displacement without vitrectomy have also been used widely with variable results from 60 to 100%.<sup>[8,9]</sup> However, Hillenkamp *et al.* showed superiority of subretinal rtPA and direct displacement of clot over intravitreal rtPA.<sup>[7]</sup>

The technique used in our case was first described by Martel and Mahmoud<sup>[11]</sup> in cases of massive submacular hemorrhage secondary to CNVM. A cocktail consisting of filtered air, rtPA and bevacizumab was injected in the subretinal space. The three different forces acting on the subretinal clot include friction,

buoyancy, and gravity.<sup>[12]</sup> RtpA and the volume of mixture injected, decrease the friction exerted by the subretinal clot. Subretinal air decreases the buoyancy caused by the blood cells in the clot preventing inadvertent subfoveal displacement of the bleed. Postoperative upright positioning enables the gravitational force. The surgical time is also reduced as previously there existed a waiting period of 30 to 45 min for clot lysis and the irrigation and aspiration of the clot were performed later.<sup>[3,4]</sup> The untoward photoreceptor damage caused due to BSS and rtPA irrigation is also prevented. The superior visual outcomes and immediate subretinal bleed displacement with this technique in cases of ARMD-SMH had been earlier described by us.<sup>[13]</sup>

Recurrence of subretinal bleed following primary surgery in RAM has been reported by Zhao *et al.* and Humayun *et al.*<sup>[3,4]</sup> The use of subretinal anti-VEGF in such scenarios might help in treating the disease pathology and in preventing recurrence.

iOCT helps in refining the surgeries by providing real-time demarcation of finer structures.<sup>[14]</sup> In our case, iOCT helped in analyzing the location of sub-ILM bleed and thereby assisted the surgeon in creating an opening with the help of vitrectomy cutter. iOCT also helped in localizing the area of maximum subretinal bleed thickness.

## Conclusion

To conclude, iOCT-guided subretinal cocktail injection can be considered as an alternative and needs to be investigated further in the treatment of RRAM-associated SMH.

### Declaration of patient consent

The authors certify that they have obtained all appropriate patient consent forms. In the form the patient(s) has/have given his/her/their consent for his/her/their images and other clinical information to be reported in the journal. The patients understand that their names and initials will not be published and due efforts will be made to conceal their identity, but anonymity cannot be guaranteed.

### Financial support and sponsorship

Nil.

### Conflicts of interest

There are no conflicts of interest.

## References

1. Rabb MF, Gagliano DA, Teske MP. Retinal arterial macroaneurysms. *Surv Ophthalmol* 1988;33:73-96.

2. Nakamura H, Hayakawa K, Sawaguchi S, Gaja T, Nagamine N, Medoruma K. Visual outcome after vitreous, sub-internal limiting membrane, and/or submacular hemorrhage removal associated with ruptured retinal arterial macroaneurysms. *Graefes Arch Clin Exp Ophthalmol* 2008;246:661-9.
3. Zhao P, Hayashi H, Oshima K, Nakagawa N, Ohsato M. Vitrectomy for macular hemorrhage associated with retinal arterial macroaneurysm. *Ophthalmology* 2000;107:613-7.
4. Humayun M, Lewis H, Flynn HW Jr, Sternberg P Jr, Blumenkranz MS. Management of submacular hemorrhage associated with retinal arterial macroaneurysms. *Am J Ophthalmol* 1998;126:358-61.
5. Inoue M, Shiraga F, Shirakata Y, Morizane Y, Kimura S, Hirakata A. Subretinal injection of recombinant tissue plasminogen activator for submacular hemorrhage associated with ruptured retinal arterial macroaneurysm. *Graefes Arch Clin Exp Ophthalmol* 2015;253:1663-9.
6. Sonmez K, Ozturk F, Ozcan PY. Treatment of multilevel macular hemorrhage secondary to retinal arterial macroaneurysm with submacular tissue plasminogen activator. *Eur J Ophthalmol* 2012;22:1026-31.
7. Hillenkamp J, Surguch V, Framme C, Gabel VP, Sachs HG. Management of submacular hemorrhage with intravitreal versus subretinal injection of recombinant tissue plasminogen activator. *Graefes Arch Clin Exp Ophthalmol* 2010;248:5.
8. Chen CY, Hooper C, Chiu D, Chamberlain M, Karia N, Heriot WJ. Management of submacular hemorrhage with intravitreal injection of tissue plasminogen activator and expansile gas. *Retina* 2007;27:321-8.
9. Hesse L, Schmidt J, Kroll P. Management of acute submacular hemorrhage using recombinant tissue plasminogen activator and gas. *Graefes Arch Clin Exp Ophthalmol* 1999;237:273-7.
10. Stanga PE, Tsamis E, Papayannis A, Stringa F, Cole T, Jalil A. Swept-source optical coherence tomography Angio™ (Topcon Corp, Japan): Technology review. In: *OCT Angiography in Retinal and Macular Diseases*. Vol. 56. Karger Publishers; 2016. p. 13-7.
11. Martel JN, Mahmoud TH. Subretinal pneumatic displacement of subretinal hemorrhage. *JAMA Ophthalmol* 2013;131:1632-5.
12. Stopa M, Lincoff A, Lincoff H. Analysis of forces acting upon submacular hemorrhage in pneumatic displacement. *Retina* 2007;27:370-4.
13. Kumar A, Roy S, Bansal M, Tinwala S, Aron N, Temkar S, *et al.* Modified approach in management of submacular hemorrhage secondary to wet age-related macular degeneration. *Asia-Pacific J Ophthalmol* 2016;5:143-6.
14. Carrasco-Zevallos OM, Viehland C, Keller B, Draelos M, Kuo AN, Toth CA, *et al.* Review of intraoperative optical coherence tomography: Technology and applications. *Biomed Opt Express* 2017;8:1607-37.