



ELSEVIER

Contents lists available at [ScienceDirect](https://www.sciencedirect.com)

Trauma Case Reports

journal homepage: www.elsevier.com/locate/tcr

Multiple intussusceptions after blunt abdominal trauma in a 9-year-old boy: A case report and literature review

Shin Ae Lee^{a,b}, Joong Kee Youn^c, Ye Rim Chang^{a,b,*}

^a Department of Surgery, Seoul National University College of Medicine, Seoul, Republic of Korea

^b Trauma center, Seoul National University Hospital, Seoul, Republic of Korea

^c Department of Pediatric Surgery, Seoul National University Children's Hospital, Seoul, Republic of Korea

ARTICLE INFO

Keywords:

Intussusceptions
Traumatic injuries
Child
Conservative treatment
Case report

ABSTRACT

Traumatic intussusception is exceedingly rare. According to the existing literature, most cases are treated surgically. However, the treatment and prognosis of traumatic intussusception are not well understood, and more research is needed to determine the most beneficial treatment options.

Multiple intussusceptions were found on a computed tomography scan of a 9-year-old boy with multiple severe traumatic injuries resulting from a car accident while riding an electric scooter. Conservative management was performed, and spontaneous reduction was successfully achieved without complications.

This is the first reported case where multiple traumatic intussusceptions in a pediatric patient were managed without surgical intervention. Thus, traumatic intussusception of varied quantity and quality might be managed conservatively, yielding spontaneous resolution with the prerequisites of stable vital signs and no evidence of intestinal ischemia or perforation.

Background

Intussusception is one of the most common causes of abdominal pain in children aged between three months and three years [1]. However, traumatic intussusception is rare. Only 12 cases of pediatric trauma-induced intussusceptions have been reported in the literature [2–13]. Most traumatic intussusceptions were treated surgically, and among them, there were no cases of multiple traumatic intussusceptions treated with conservative management. This case report documents the successful conservative treatment of multiple traumatic small bowel intussusceptions in a 9-year-old boy. In addition, we review the current literature on traumatic intussusception in the pediatric age group.

Introduction

A 9-year-old boy without underlying medical conditions was transferred to the pediatric emergency center through a local emergency room. He collided with a car while riding an electric scooter. On initial physical examination, abrasion and bruising of the right lower flank were observed. His abdomen was soft and flat, but left lower abdominal tenderness and pain were noted on percussion. A small amount of fluid collection was identified in the splenorenal recess upon focused assessment of the traumatic child

* Corresponding author at: Department of Surgery, Trauma Center, Seoul National University Hospital, 101, Daehak-ro, Jongno-gu, Seoul, Republic of Korea.

E-mail address: yerimchang@gmail.com (Y.R. Chang).

<https://doi.org/10.1016/j.tcr.2022.100630>

Accepted 27 February 2022

Available online 4 March 2022

2352-6440/© 2022 The Authors. Published by Elsevier Ltd. This is an open access article under the CC BY-NC-ND license

(<http://creativecommons.org/licenses/by-nc-nd/4.0/>).

Abbreviations

CT Computed tomography

using sonography. The patient was afebrile with a blood pressure of 128/82 mmHg and a pulse rate of 120 bpm. Initial laboratory tests showed a white blood cell count of 13,620/ μ L (segmented neutrophils, 87.3%), hemoglobin level of 10.7 g/dL, platelet count of 297,000/ μ L, and hs-CRP level of 5.48 mg/dL. Thoracoabdominal CT angiography showed hemorrhagic fluid collection around the left renal hilum and two small bowel intussusceptions (jejunojejunal and ileoileal) (Fig. 1). CT scan was taken 2.5 h after the accident. The ileoileal intussusception was consistent with the location of left lower abdominal tenderness, but there was no evidence of bowel wall ischemia or perforation on the CT scan. Also there was no intramural hematoma or bowel wall edema, proximal bowel dilatation of short segments (1.8 cm, 1.9 cm in length) of intussusceptions. Other injuries included right temporal bone fracture with pneumocephalus, right hemotympanum, subarachnoid hemorrhage, right proximal humerus neck fracture, right femur proximal diaphysis comminuted fracture, left second and third metatarsophalangeal fracture, and lung contusion. The injury severity score (ISS) was 22 points, which corresponded to severe trauma.

Under the current treatment guidelines, there were no intra-abdominal organ injuries requiring surgery other than the small bowel intussusceptions. Therefore, after consulting a pediatric surgeon, the patient was managed conservatively with bowel rest and serial abdominal examinations. Surgery was planned if spontaneous reduction was not achieved with conservative management. The patient was admitted to the pediatric intensive care unit for close monitoring. While bowel rest was maintained for 48 h after admission, abdominal pain and tenderness improved as determined by serial clinical examinations. There was no increase in the splenorenal space fluid collection, which was checked using daily follow-up ultrasonography. After 72 h of observation, the patient was transferred to the general ward, and oral feeding was initiated. After feeding, there was no abdominal pain, tenderness, nausea, or vomiting. On the 7th day of hospitalization, an abdominal CT was performed, and it was confirmed that the two small bowel intussusceptions had disappeared. The patient was discharged without complications on the 10th day of hospitalization. There was no evidence of intussusception after three weeks of discharge.

Discussion and conclusions

Intussusception is defined as the telescoping of one portion of the intestine into the other [1]. Most cases occur at the ileocecal junction and are idiopathic. The incidence is associated with a history of upper respiratory tract infections and viral gastroenteritis [1]. According to the Centers for Disease Control and Prevention (CDC) statistics, an incidence rate of 328 cases per 100,000 was reported in children under one year in Korea [14]. Hydrostatic reduction by enema using contrast materials or air is the treatment of choice. If the intussusceptions include peritonitis or bowel obstruction and hydrostatic reduction fails, the operation is indicated [1]. Traumatic intussusception is extremely rare. From 1925 to 2021, 28 cases have been reported in the literature. Only 12 cases described pediatric patients younger than 15 years of age (Table 1) [2–13]. Of these 12 cases, 11 cases discussed small bowel intussusception and one case discussed ileocolic intussusception [2–13]. Only three studies reported multiple intussusceptions. In these cases, patients presented with two, three, and ten intussusceptions, respectively, and underwent surgery [3,4,11]. In the case reported by Hangfei et al., there was no evidence of intussusception on preoperative CT scans except left kidney rupture with hemorrhage. Surgery was decided due to kidney rupture. However, during the operation, 10 small bowel intussusceptions were discovered [11]. Other 2 of 3 cases conducted

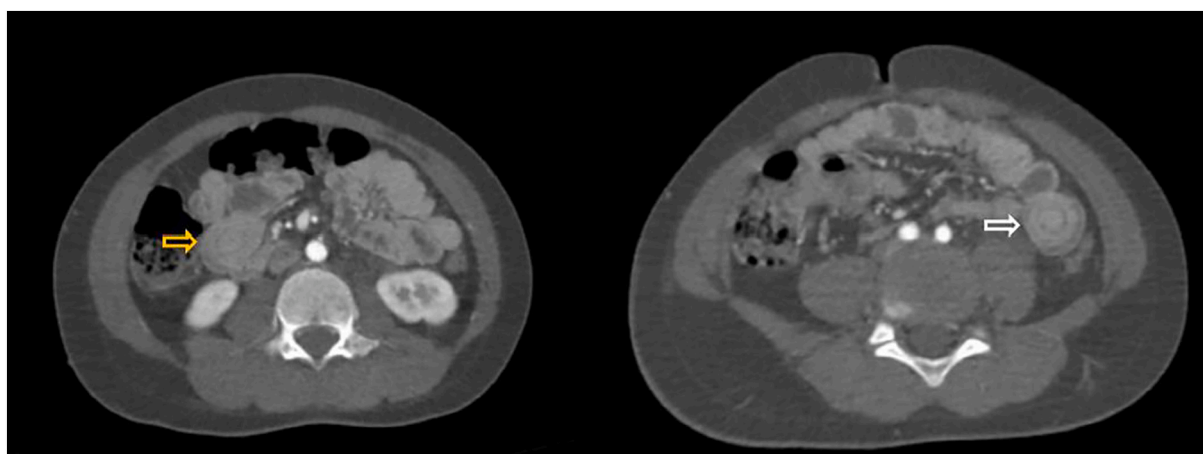


Fig. 1. Abdominal CT scan

CT images show multiple small bowel intussusceptions of the patient (yellow arrow: jejunojejunal intussusception, white arrow: ileoileal intussusception). (For interpretation of the references to colour in this figure legend, the reader is referred to the web version of this article.)

Table 1
Characteristics of 12 children with traumatic intussusception.

Reference	Age	Sex	Location	Number	Mechanism of injury	Symptom	Treatment	Reason for choosing treatment	Outcome
Kennedy [2]	6	M	Ileoileal	1	Motorcycle accident	Abdominal pain, Vomiting	MR	Bruise on abdomen, Persistent symptoms	Uncomplicated
Mitchell [3]	10	F	Jejunojejunal	2	Blunt abdominal trauma	Abdominal pain	MR	Unknown	Uncomplicated
Badertscher [4]	9	M	Ileoileal	3	Motorcycle accident	Abdominal pain	MR	Change of physical examination	Uncomplicated
Isbister [5]	10	M	Jejunojejunal	1	Motorcycle accident	Abdominal pain	MR	Extreme abdominal tenderness with guarding	Uncomplicated
LeBlanc [6]	8	M	Jejunojejunal	1	Bicycle accident	Abdominal pain, Vomiting	MR	Change of physical examination	Uncomplicated
Saxena [7]	4	F	Ileoileal	1	Blunt abdominal trauma	Abdominal pain, Vomiting	BR	Intramural hemorrhage on CT scan	Uncomplicated
Erichsen [8]	6	M	Ileoileal	1	Bicycle accident	Abdominal pain	BR	Persistent symptoms, prestenotic dilatation of bowel on CT scan	Uncomplicated
Lu, Suat J [9]	12	M	Jejunojejunal	1	Blunt abdominal trauma	Abdominal pain, Abdominal distension, Vomiting	Conservative	No signs of peritonitis	Uncomplicated
Rejab [10]	10	M	Jejunojejunal	1	Blunt abdominal trauma	Abdominal pain, Vomiting	BR	Peritoneal collection on CT scan	Uncomplicated
So Ra Kwon [13]	4	F	ileocolic	1	Bicycle accident	Abdominal pain	AR	Preserved enteric perfusion on USG	Uncomplicated
Hangfei [11]	5	M	Jejunojejunal, Ileoileal	10	Tricycle accident	Abdominal pain and distension	MR	Left kidney rupture (no signs of intussusception on CT scan)	Uncomplicated
Present case	9	M	Jejunojejunal, Ileoileal	2	Electric scooter accident	Abdominal pain	Conservative	No signs of peritonitis	Uncomplicated

AR, air reduction; BR, bowel resection; F, female; M, male; MR, manual reduction; USG, ultrasonography.

manual reduction of multiple intussusceptions [3,4]. It is presumed that these cases reported early 1990s, CT scan was not commonly performed at that time. Therefore diagnostic laparoscopy was performed to confirm the cause of post-traumatic abdominal pain.

Since multiple traumatic intussusceptions are very rare in children, the mechanisms of their emergence are not clearly understood. Some proposed mechanisms include local intestinal spasm or edema following pathologic peristalsis, sympathetic hyperactivation, or intramural hematoma after trauma [9,10]. Since the patient in our case had no bowel wall edema or intramural hematoma, we hypothesized that the possible cause of multiple intussusceptions might be sympathetic hyperactivation leading to localized intestinal spasm or pathologic peristalsis.

In 2005, Stockinger et al. suggested that manual reduction without resection is the preferred management for traumatic intussusception in adults and children [15]. As a result, manual reduction or bowel resection was performed in 10 of the 12 cases mentioned above. In 2016, Kwon et al. treated traumatic ileocolic intussusception in a 4-year-old girl with air reduction [13]. Meanwhile, only two patients were treated conservatively: a 12-year-old child in 2009 and a 15-year-old child in 2021 [9,12]. These two patients had traumatic single jejunojejunal intussusception, while the current patient had multiple small bowel intussusceptions.

This case report is the first record of the spontaneous resolution of multiple traumatic intussusceptions in a pediatric patient using conservative management. Most treatments reported in the literature involve surgical interventions, including manual reduction or bowel resection [2–13]. However, there is no established standard for conservative management, which might entail a more advantageous outcome and less burden for the patient than surgical interventions. As in this case, spontaneous reduction could be expected with bowel rest and serial imaging if the following conditions are satisfied:

1. Stable vital signs
2. Absence of other intra-abdominal organ injuries requiring surgery
3. No evidence of bowel ischemia or perforation
4. No signs of peritonitis on physical examination
5. Stable laboratory values

Guidelines for treatment principles of traumatic intussusception need to be further explored by gathering data from additional future cases.

Consent for publication

Written informed consent was obtained from the patient's legal guardian for publication of this case report and any accompanying images. A copy of the written consent is available for review by the Editor-in-Chief of this journal.

Availability of data and materials

The datasets used or analyzed during the current study are available from the corresponding author on reasonable request.

Funding

No funding provided by a third party.

Ethics approval and consent to participate

Ethics approval granted by the Institutional Review Board of Seoul National University Hospital, Seoul, Korea, No: 2110-022-1259

CRedit authorship contribution statement

SA Lee: patient management, literature review, original draft preparation and revision; JK Yoon: provision of advices about management and review of the manuscript; YR Chang: performed patient management, manuscript review and editing; All authors read and approved the final manuscript.

Declaration of competing interest

The authors declare that they have no competing interests.

Acknowledgements

Not applicable.

References

- [1] C.M. Townsend, D.R. Beauchamp, M.B. Evers, K.L. Mattox, Sabiston Textbook of Surgery: The Biological Basis of Modern Surgical Practice, 20th ed., Elsevier, 2015.
- [2] C.H. Kennedy, Ileal intussusception following severe trauma, *Lancet* 1 (1920) 1008–1009.
- [3] D.A. Mitchell, Traumatic intussusception, *Br. Med. J.* 18 (1925) 734.
- [4] V.A. Badertscher, Traumatic triple intussusception of the ileum of a child, *JAMA* 112 (1939) 422–423.
- [5] W.H. Isbister, Enteric intussusception after acute trauma, *Am. J. Surg.* 120 (1970) 101–102.
- [6] K.E. LeBlanc, Jejuno-jejunal intussusception in a hemophiliac: a case report, *Ann. Emerg. Med.* 11 (1982) 149–151.
- [7] A.K. Saxena, K.S. Sodhi, S. Khandelwal, K.L. Rao, S. Suri, Blunt abdominal trauma: an unusual cause of intussusception, *Pediatr. Radiol.* 34 (2004) 364.
- [8] D. Erichsen, H. Sellstrom, H. Andersson, Small bowel intussusception after blunt abdominal trauma in a 6-year-old boy: case report and review of 6 cases reported in the literature, *J. Pediatr. Surg.* 41 (2006) 1930–1932.
- [9] S.J. Lu, P.S. Goh, Traumatic intussusception with intramural haematoma, *Pediatr. Radiol.* 39 (2009) 403–405.
- [10] H. Rejab, A. Guirat, A. Trigui, M. Abdelkader, M.I. Beyrouti, Post-traumatic jejunojejunal intussusception, *Indian J. Surg.* 77 (2) (2015) 159–160.
- [11] Hangfei Jin, Du. Weibing, Multiple intussusceptions after blunt abdominal trauma in a 5-year-old boy: case report and review of nine cases reported in the literature, *Indian J. Surg.* 83 (2021) S204–S206.
- [12] S. Kate, K. Krish, Expectant management of traumatic intussusception, *J. Surg. Case Rep.* 1 (2021) 1–3.
- [13] S.R. Kwon, S.O. Ha, Y.T. Oh, Y.D. Sohn, Air reduction of intussusception after abdominal blunt trauma and a literature review, *Clin. Exp. Emerg. Med.* 3 (1) (2016) 59–62.
- [14] D.S. Jo, B. Nyambat, J.S. Kim, Y.T. Jang, T.L. Ng, H.L. Bock, et al., Population-based incidence and burden of childhood intussusceptions in Jeonbuk Province, South Korea, *Int. J. Infect. Dis.* 13 (2009) e383–e388.
- [15] Z.T. Stockinger, N. McSwain Jr., Intussusception caused by abdominal trauma: case report and review of 91 cases reported in the literature, *J. Trauma* 58 (2005) 187–188.